



## DERMATOFİBROSARKOMA PROTUBERANS (Morfolojik spektrum ve ayırıcı tanı)

Prof Dr Taner Akalın

Ege ÜTF Patoloji AD

25. Ulusal Patoloji Kongresi, 14-17 Ekim 2015, Bursa

### Dermatofibrosarkoma protuberans (DFSP)

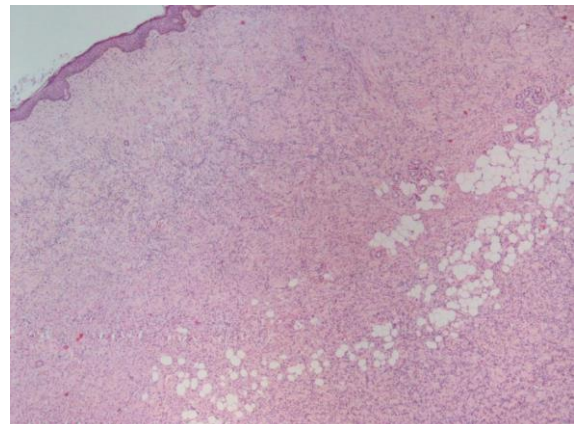
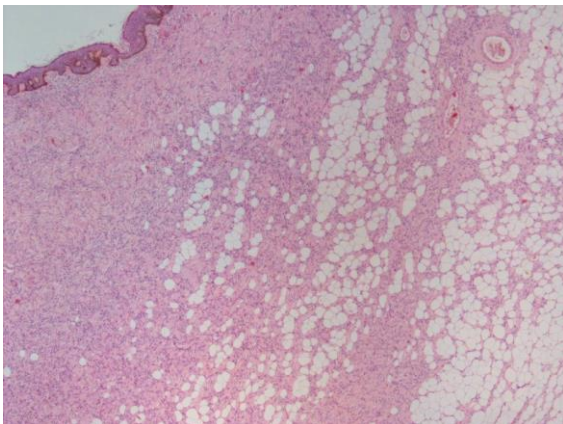
- Sınır maligniteli fibroblastik tm
- Nüks oranı değişken %14 (%0 - 63)  
(çevre normal dokuyu içeren geniş eksizyon veya Mohs cerrahisi önemli)
- Metastaz nadir (%1, fibrosarkomatöz komponent varsa %14)

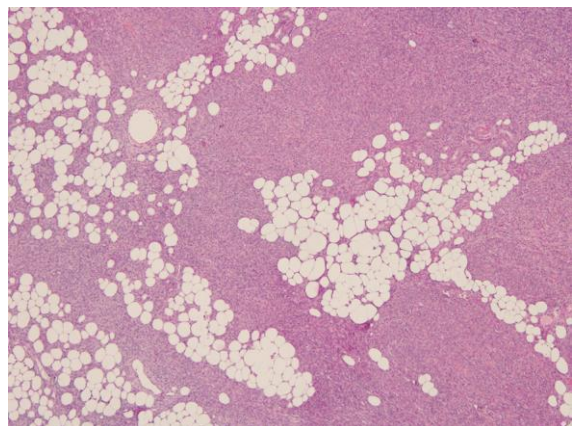
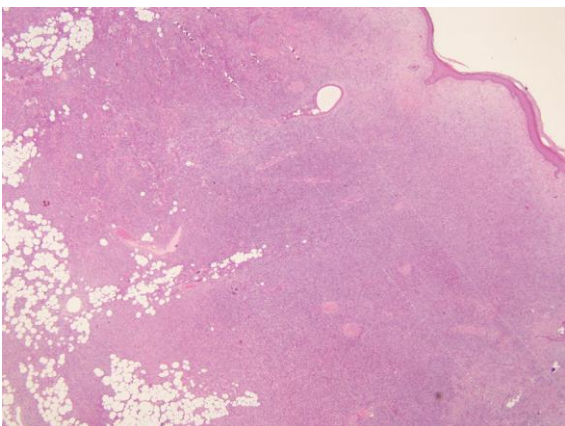
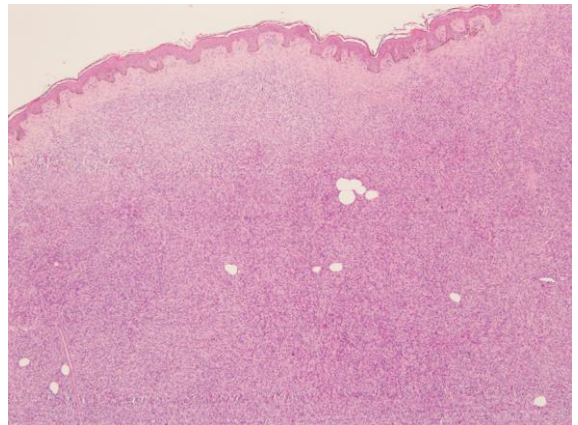
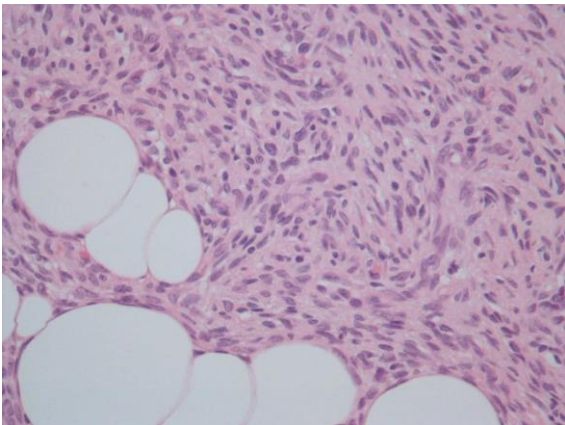
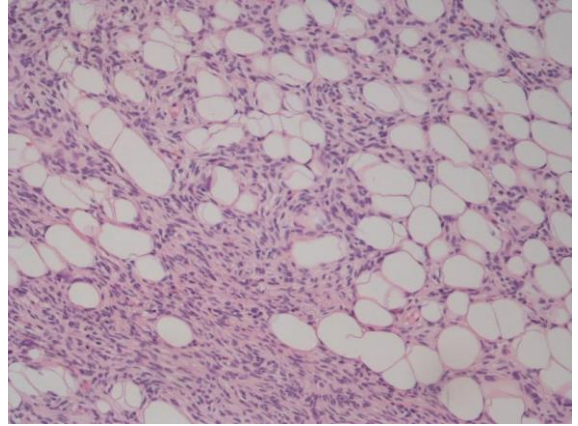
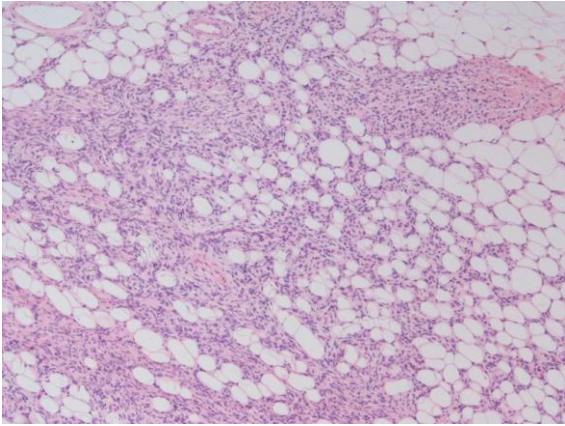
### DFSP, Klinik

- Gövde ve ekstremitte proksimallerinde sık
- Genç ve orta yaş erişkinlerde sık
- Çocuklarda da görülebilir
- Büyük çoğunluğu 2 cm den büyük boyutlu
- Nodüler veya multinodüler gelişim
- Plak /atrofik gelişim gösteren örnekleri var

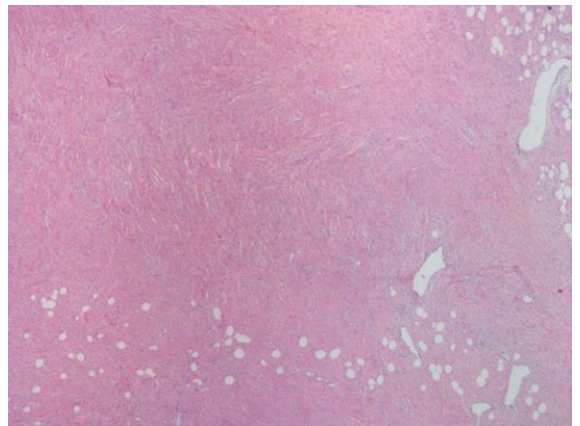
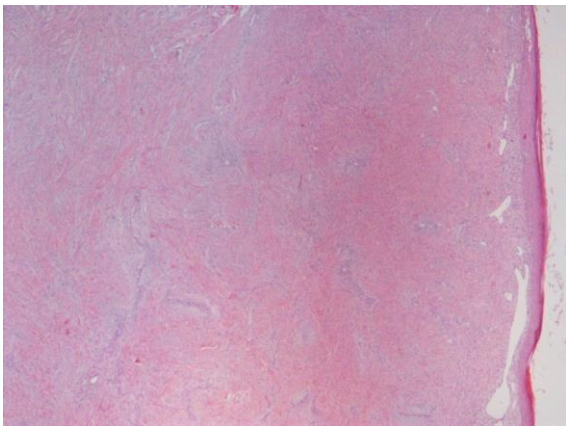
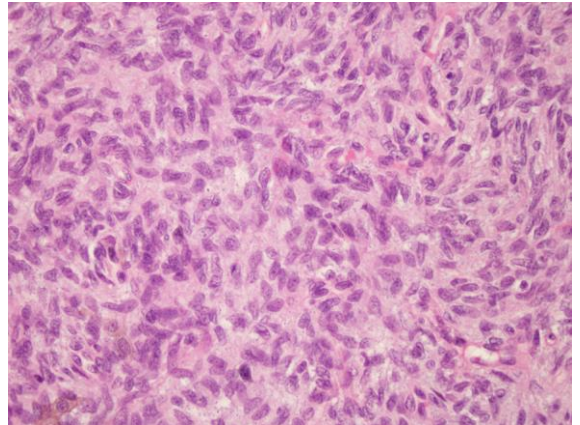
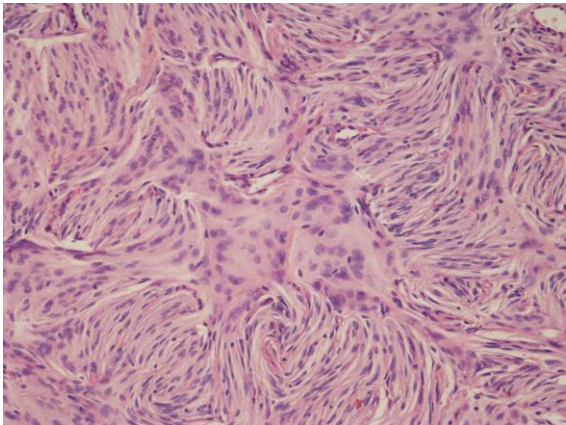
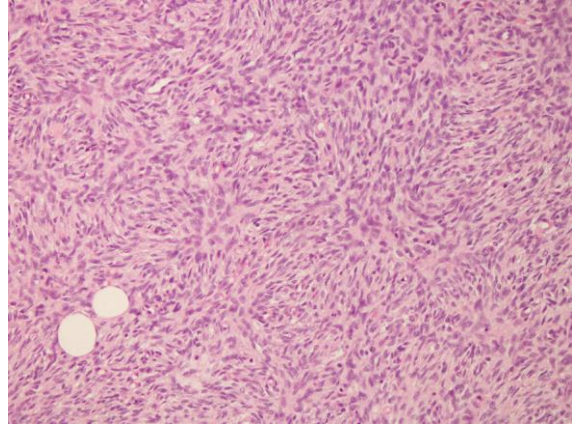
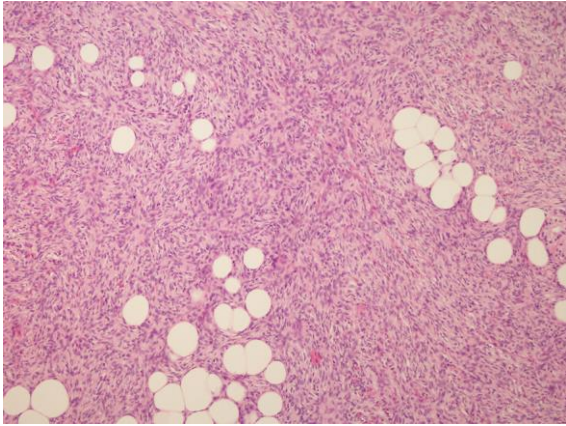
### DFSP, Histopatoloji

- Tipik olarak dermis merkezlidir ve belirgin subkutanöz yağ dokusu invazyonu vardır
- Dermada diffüz infiltratif gelişim gösteren monomorfik içsi/fusiform hücreler
- Nükleer atipi ılımlı, mitotik aktivite yüksek değil
- Storiform patern
- Multinükleer h ler, siderofajlar (polimorfik görünüm), inflamatuvar h ler az veya yok

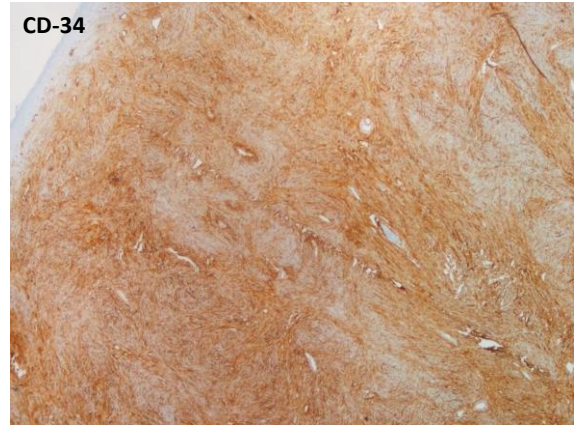
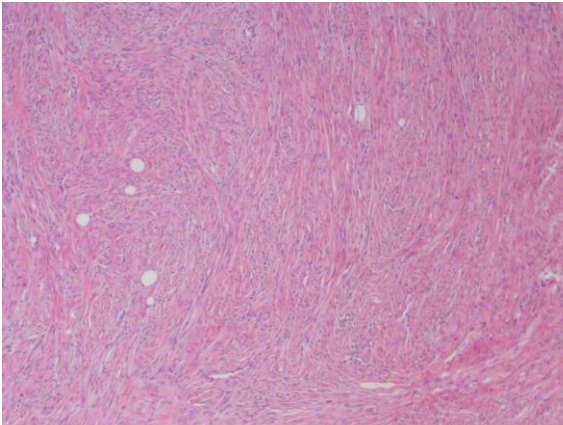
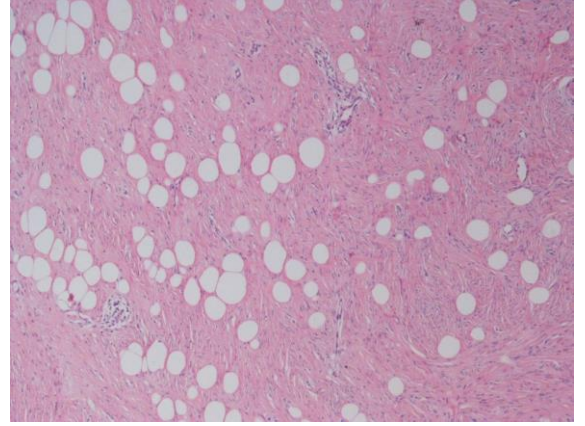
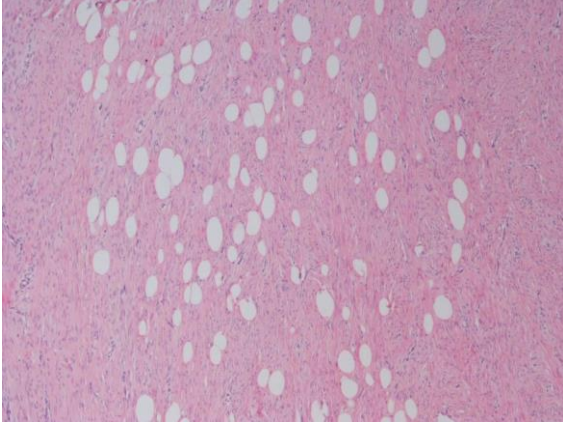






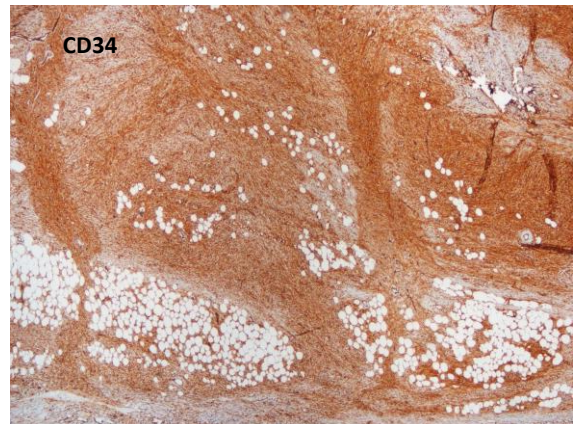




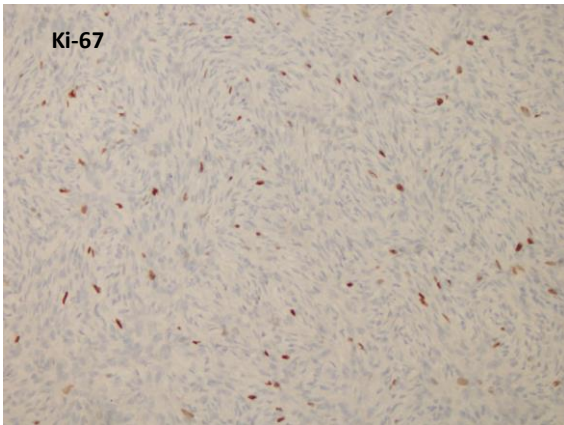
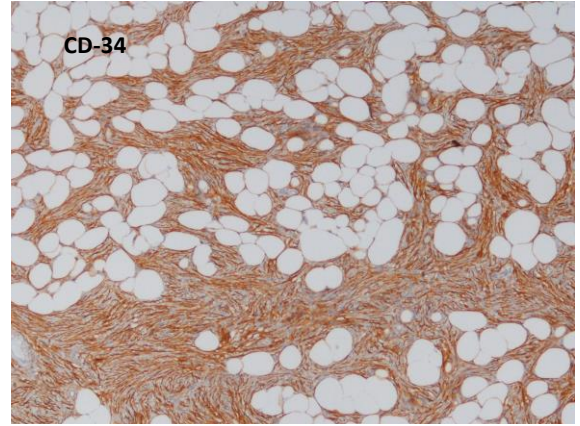
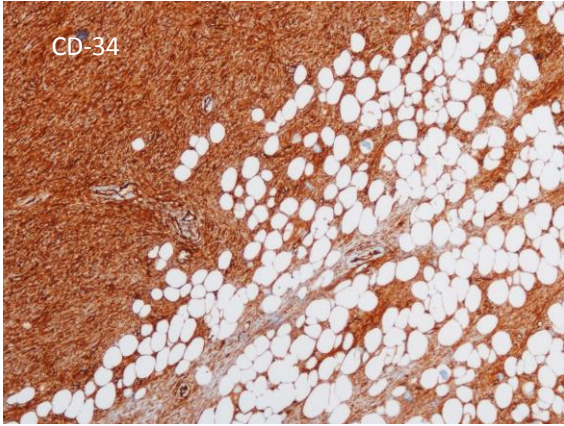


### DFSP İHK ve moleküler bulgular

- **CD34 ile yaygın güçlü pozitif**
- CD34 fibrosarkomatöz alanlarda kaybolur (olguların yaklaşık yarısında)
- FXIIIa ve Stromelysin3 negatif /fokal soluk +
- EMA, CD99 fokal soluk pozitif olabilir
- Karakteristik moleküler bulgu: t(17;22)(q22;q13)  
COL1A1 – PDGFB füzyonu

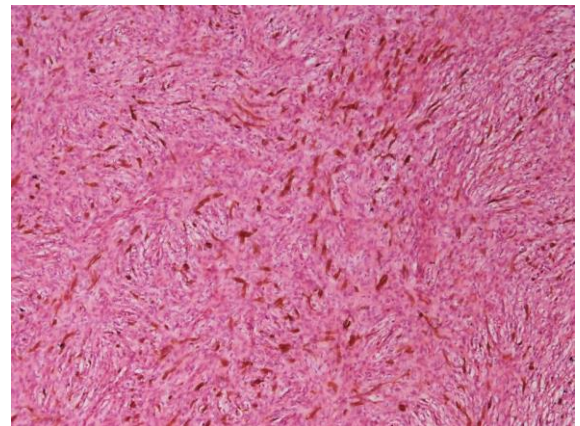
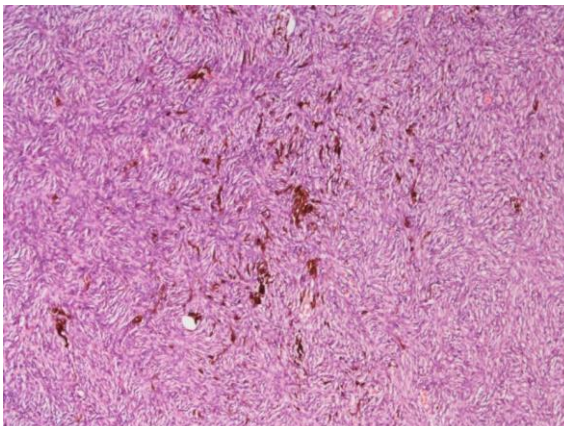






### DFSP Morfolojik Spektrum

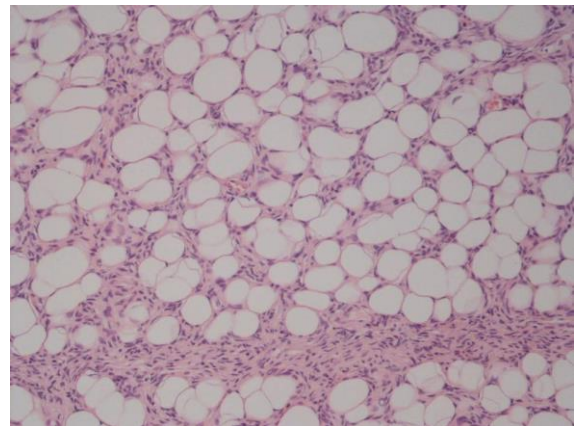
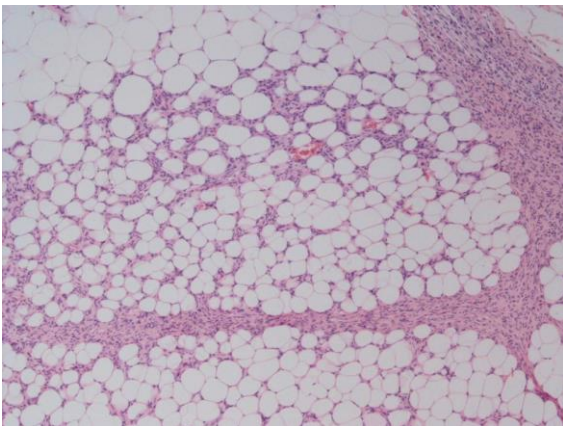
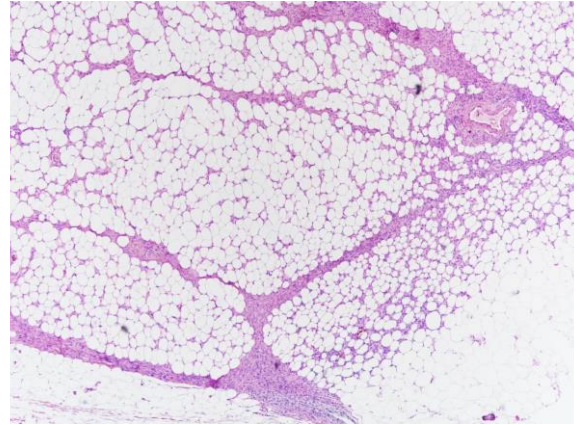
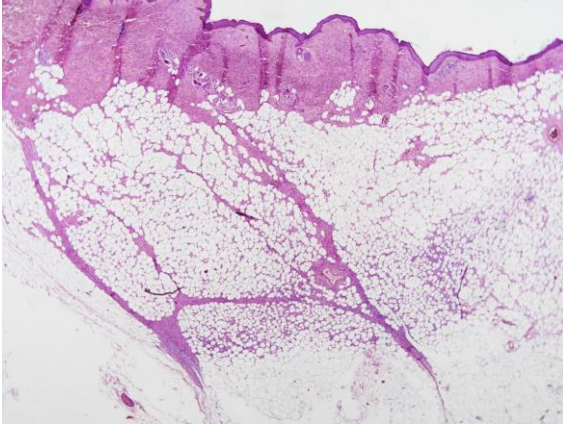
- Pigmentli DFSP
- Plak/atrofik DFSP
- Miksoid DFSP
- DFSP de myomatöz/myofibroblastik diferansias.
- Fibrosarkomatöz DFSP
- Dev hücreli fibroblastom



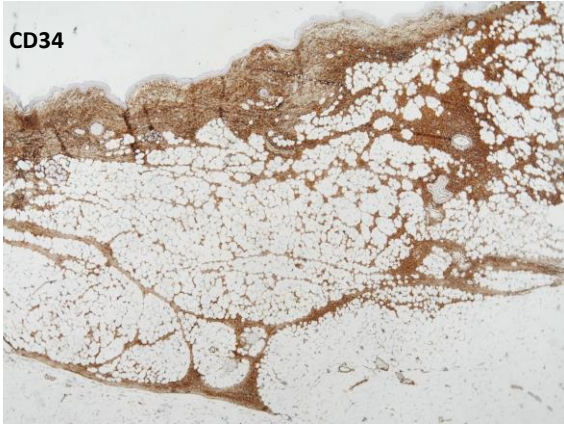
## DFSP

- Pigmentli dermatofibrosarkom (Bednar tümörü) klasik dermatofibrosarkoma protuberansa benzer ancak farklı olarak yoğun melanin yüklü dendritik hücre popülasyonu var
- Prognostik bir önemi yok

- Büyük çoğunlukla 2 cm den büyük boyutlu ancak atrofik/plak veya erken yakalanmış lezyonlar daha küçük boyutlu olabilir

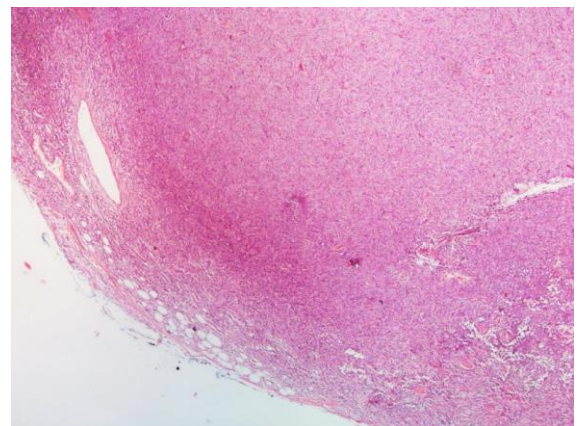
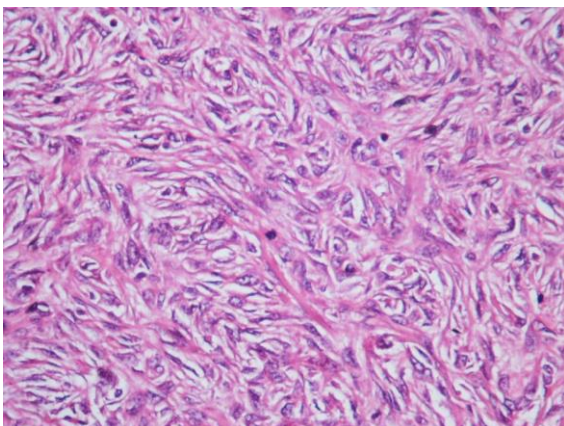
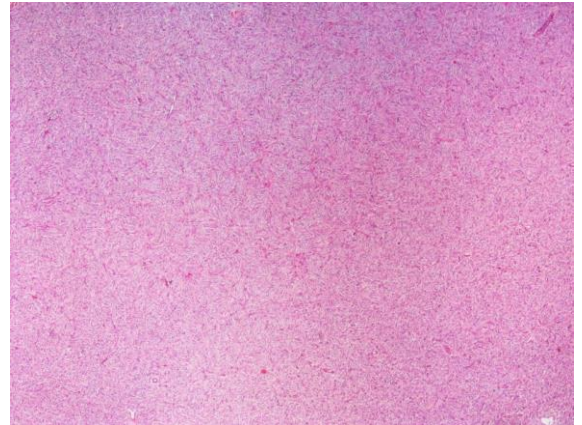
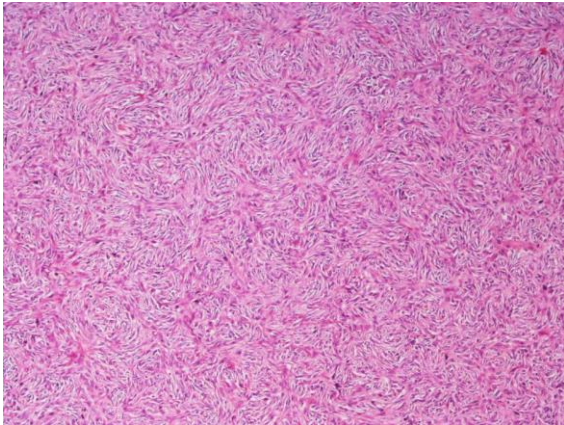




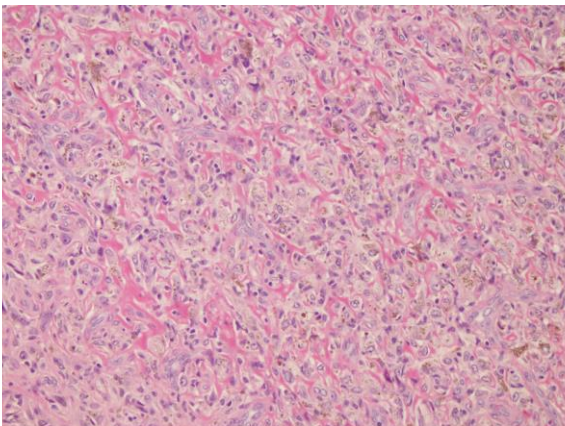
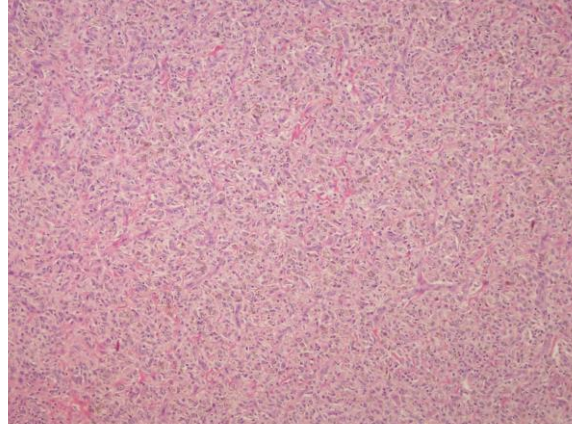
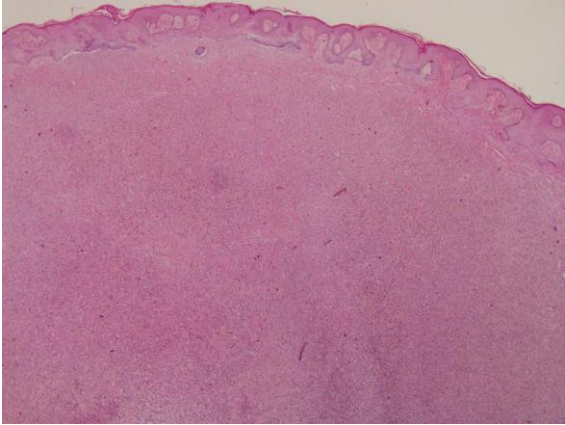
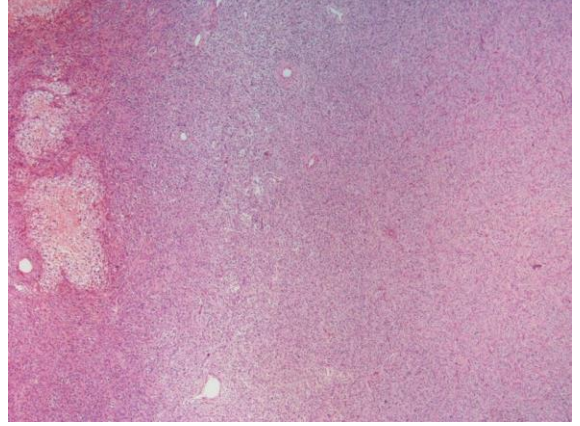
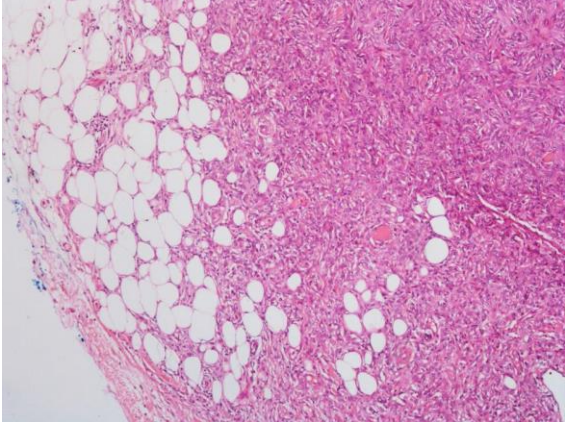


### Dermatofibrosarkoma Protuberans, Ayırıcı Tanı

- Fibröz histiyositom (Dermatofibrom)
  - \* polimorfik hücre popülasyonu
  - \* yağ doku invazyonu yüzeysel
  - \* CD34 negatif

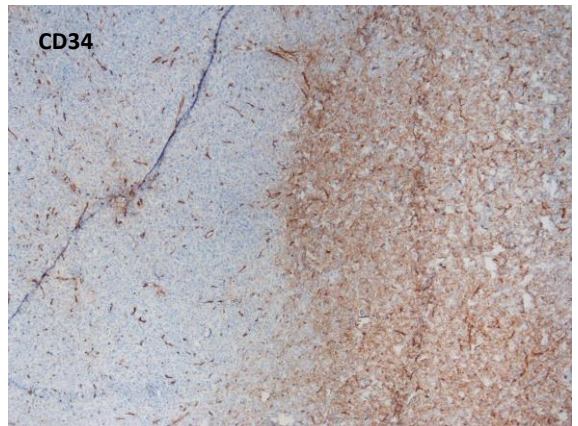
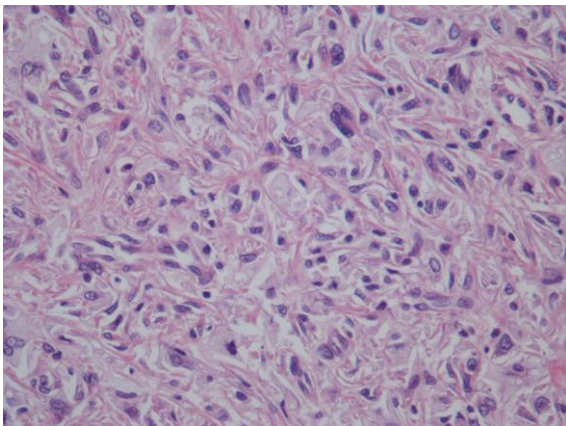
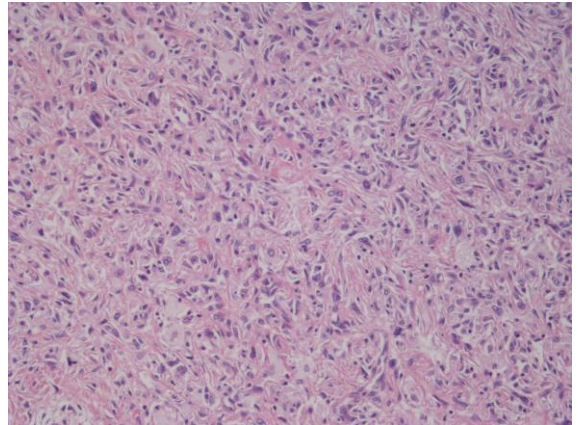
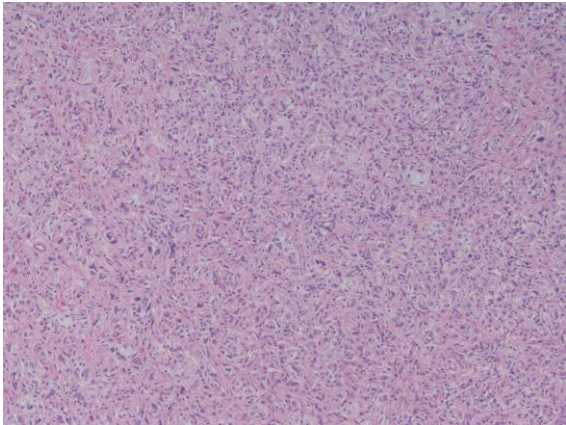
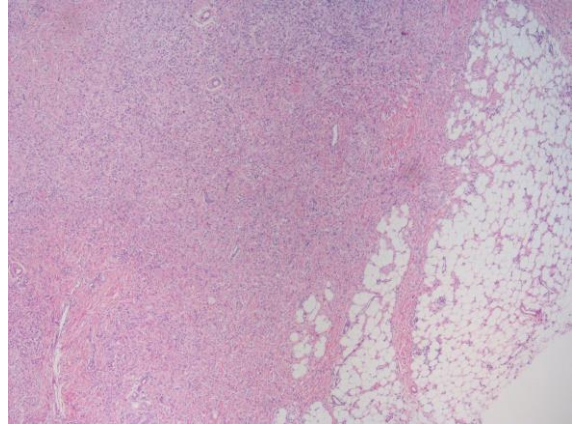
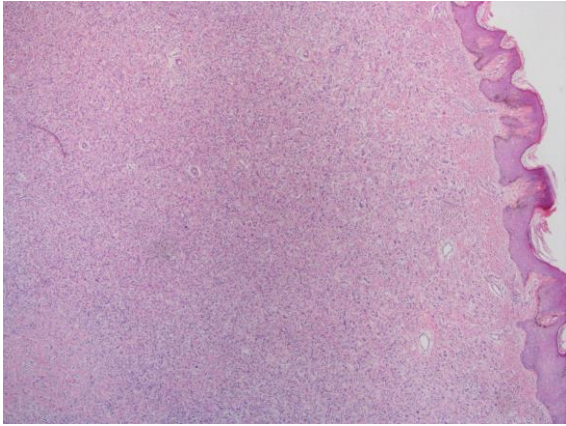




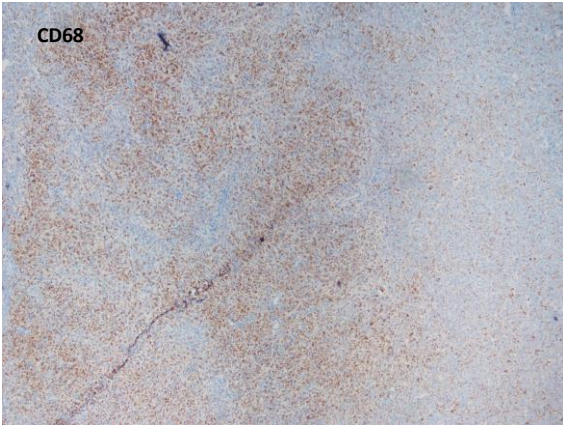
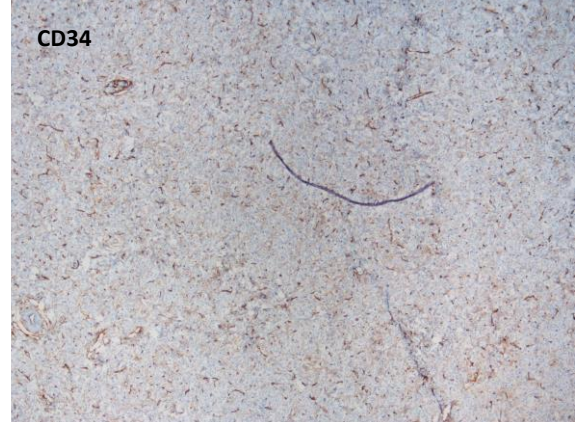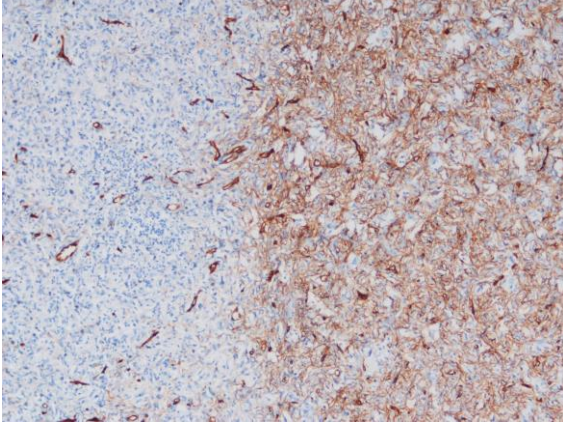


- 40 y K
- Uylukta 3 cm lik eksizyon üzerinde 1,7 cm çaplı lezyon
- Konsültasyon blokları

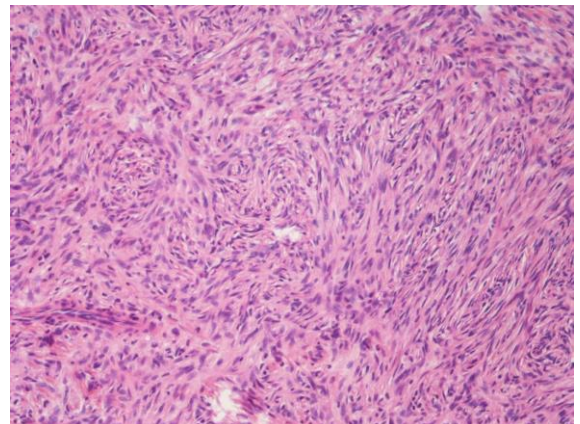
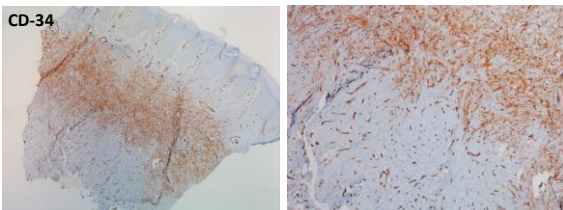
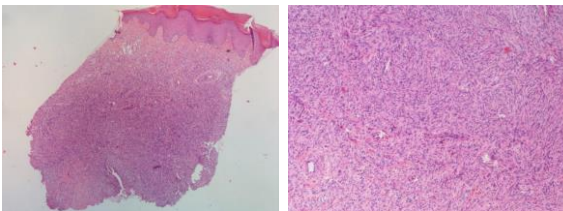






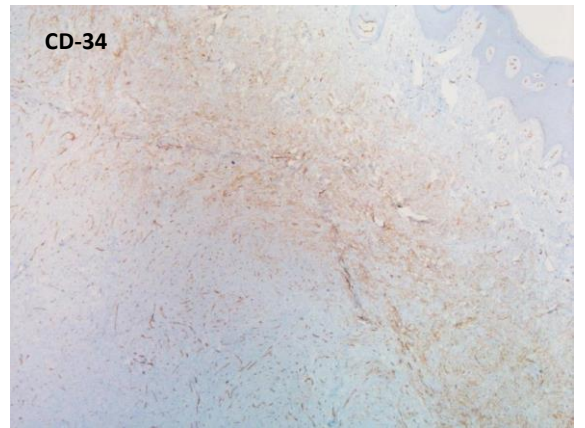
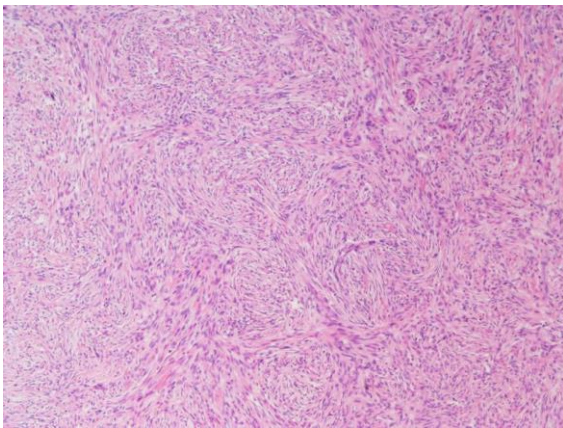
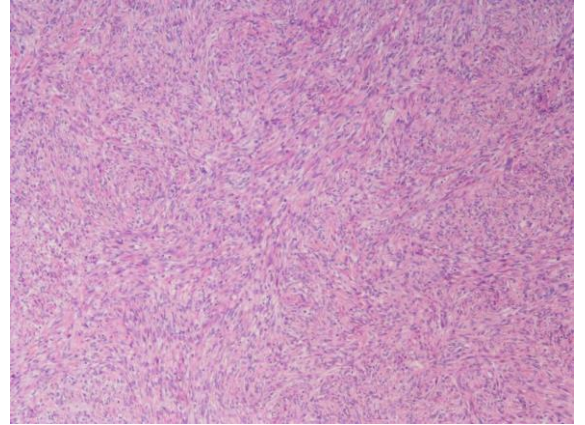
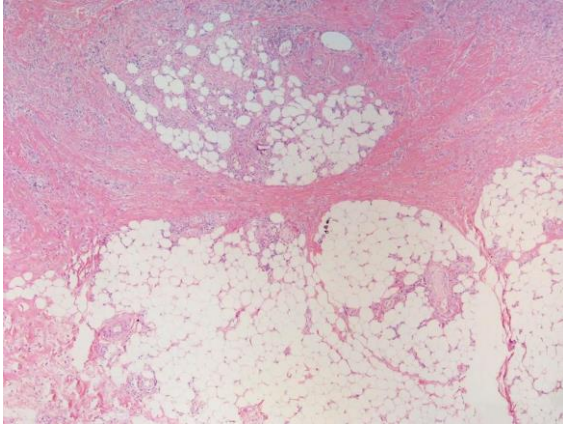
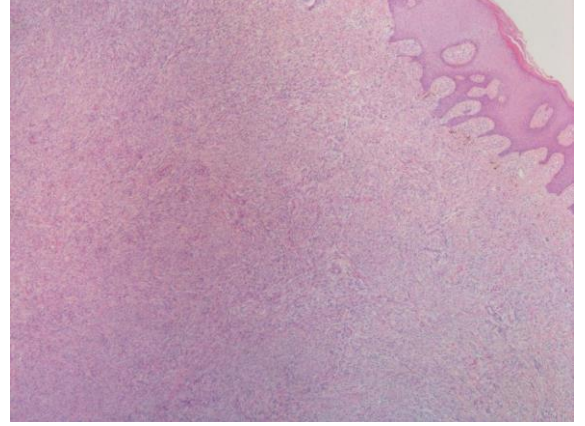


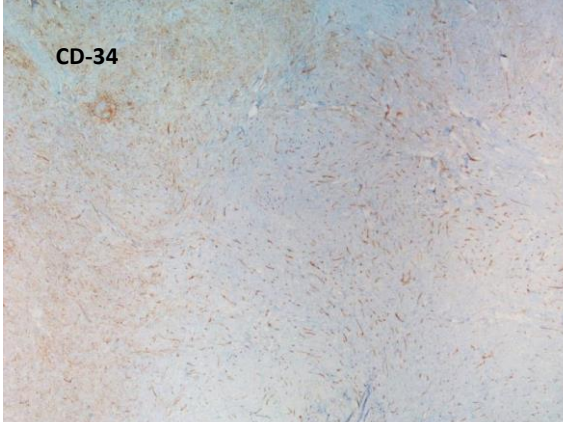
- Dermatofibrom (fibröz histiositom) da
  - \* yüzeysel yağ dokusu invazyonu
  - \* separe bizar hücreler
  - \* fokal soluk CD34 pozitifliği olabilir





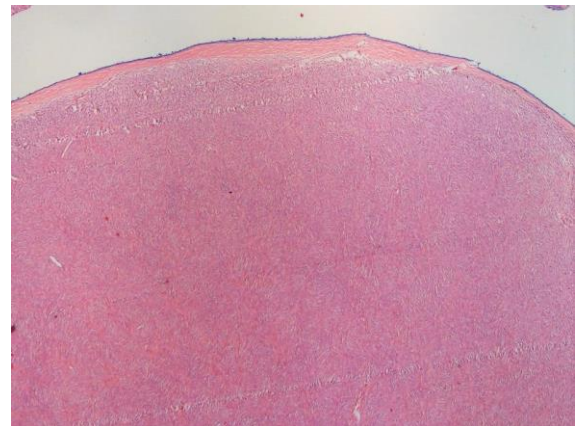
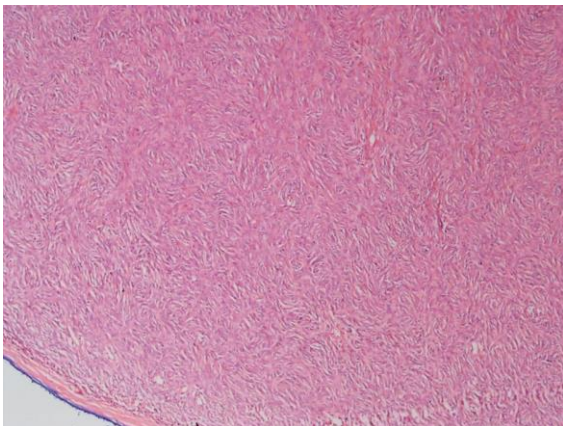
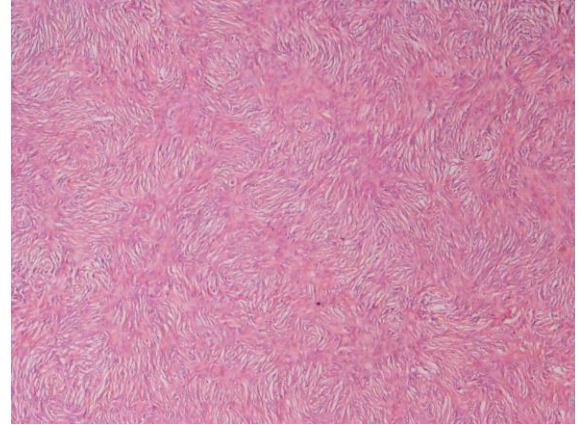
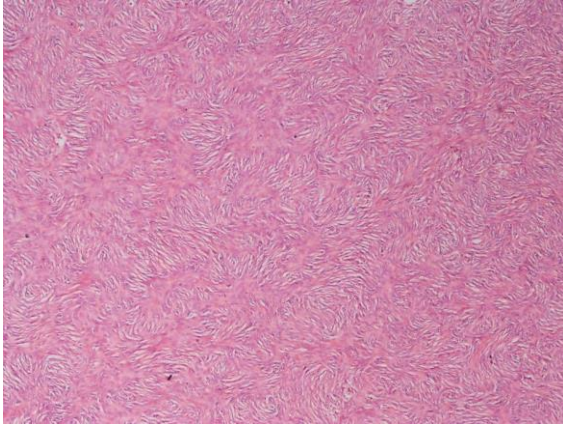
- Tanı: Fibrohistiyositik Tümör
- Yorum: Ön planda sellüler fibröz histiyositom düşünülmüştür ancak DFSP olasılığının kesin ekarte edilebilmesi için eksizyon materyelinin değerlendirilmesi uygun olur.



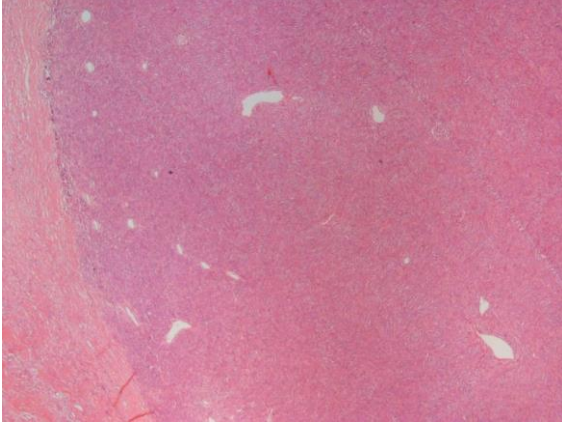


- 100 Sellüler fibröz histiyositom olgusu
- CD 34 6 olguda pozitif
- Düz kas aktini 93 olguda pozitif
- Desmin 32 olguda pozitif

\*Volpicelli ER and Fletcher CDM. J Cutan Pathol 2012; 39: 747







- Derin yerleşimli fibröz histiyositom monoton storiform patern gösterebilir ancak iyi sınırlıdır ve CD-34 negatiftir.

### Dermatofibrom V DFSP, İmmunhistokimya

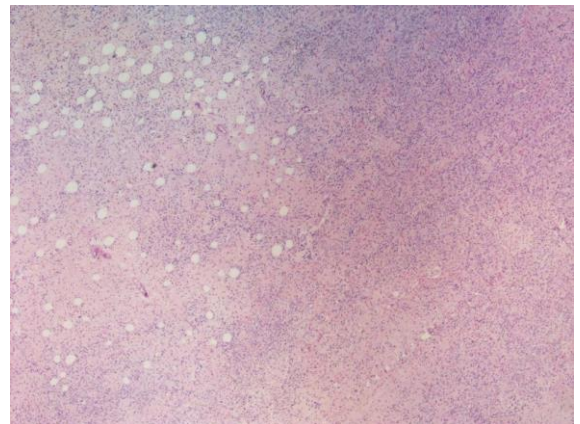
- **CD-34** (DFSP de %90-95 pozitif, DF %95 negatif)
- **Faktör XIIIa** (DF pozitif, DFSP %90 negatif)
- **Stromelysin-3 (MMP-11)**(DF +, DFSP %95 negatif)
- **Apolipoprotein D** (DFSP genellikle pozitif)
- **CD99**
- **D2-40**
- **HMGA1 ve HMGA2**
- **CD163**
- **CD-44**

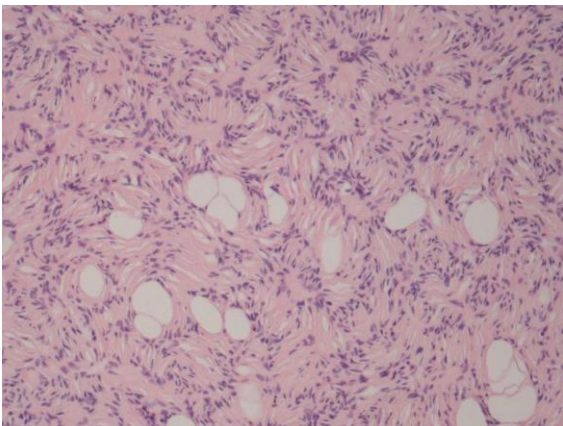
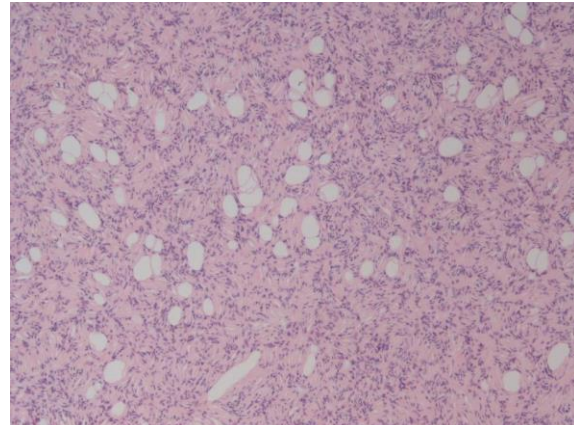
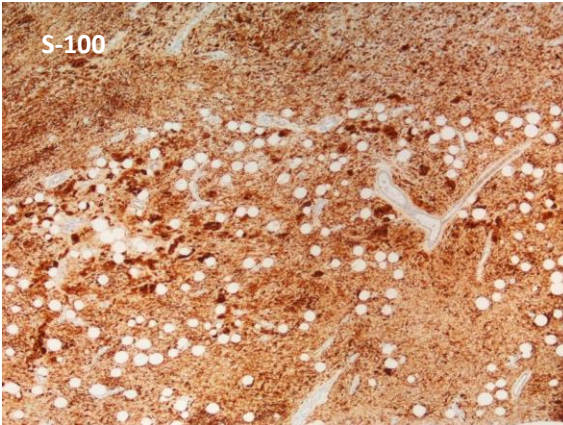
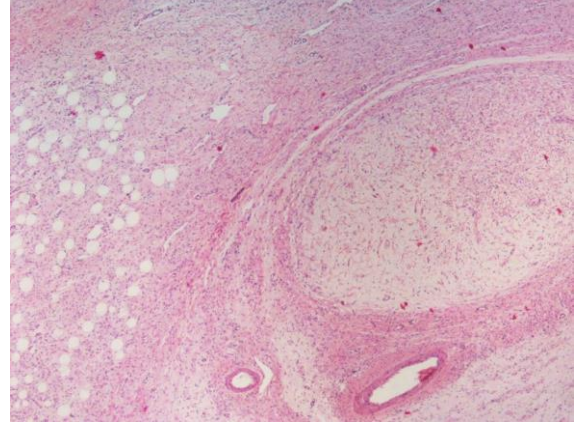
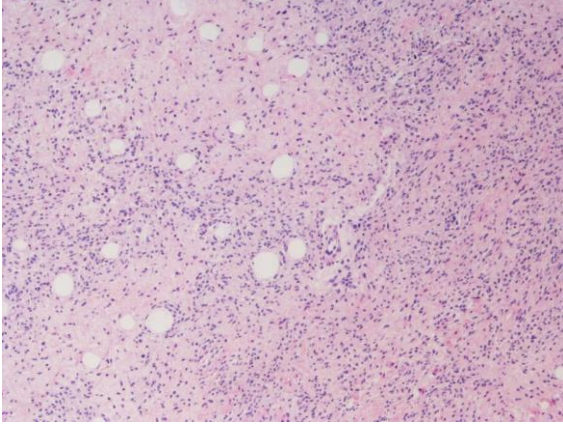
### Subkutanöz yağ dokusu infiltrasyonu görülebilen lezyonlar

- Nörofibrom diffüz tip
- Ksantogranülom (Juvenil)

### Diffüz tip nörofibrom

- Diffüz nörofibrom
  - \* Kısa dalgalı iğsi hücreler
  - \* Meisner benzeri diferansiye yapılar
  - \* S-100 pozitif

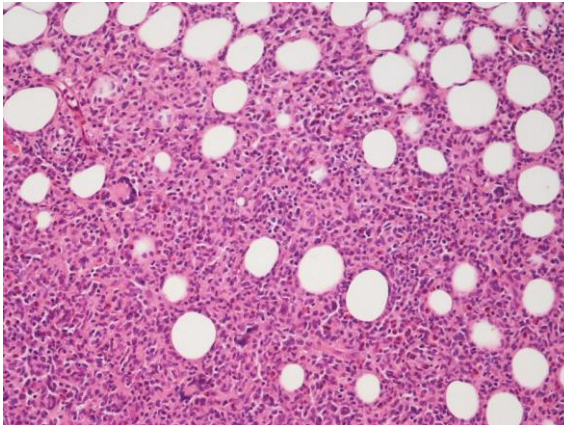
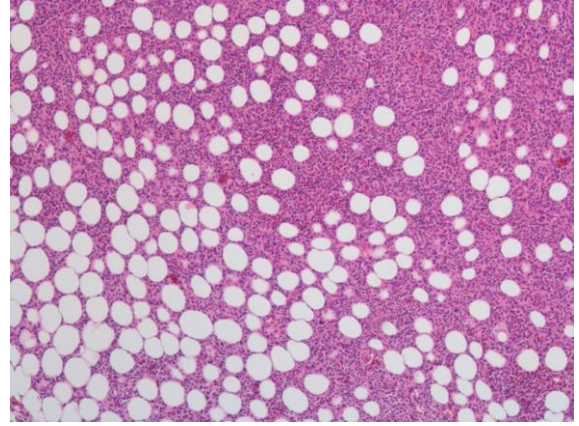
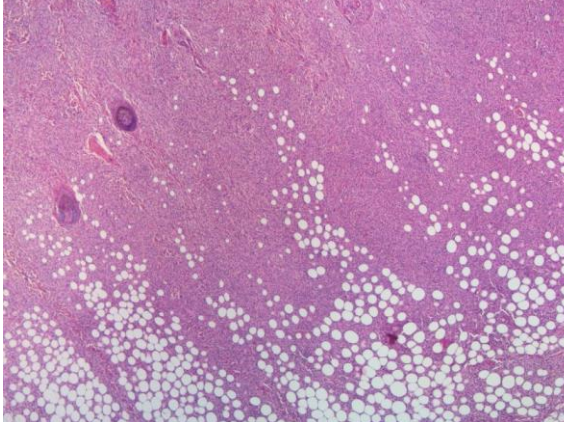




### Ksantogranülom (juvenil)

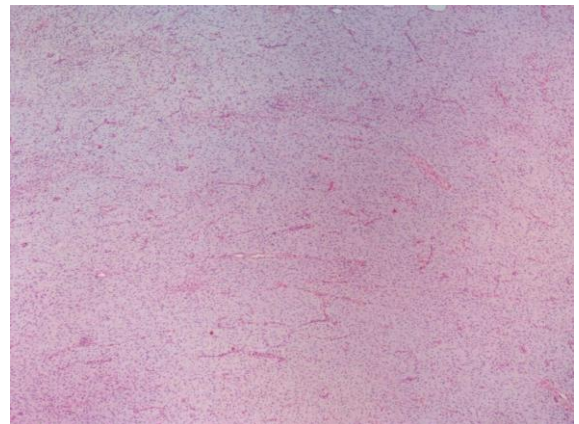
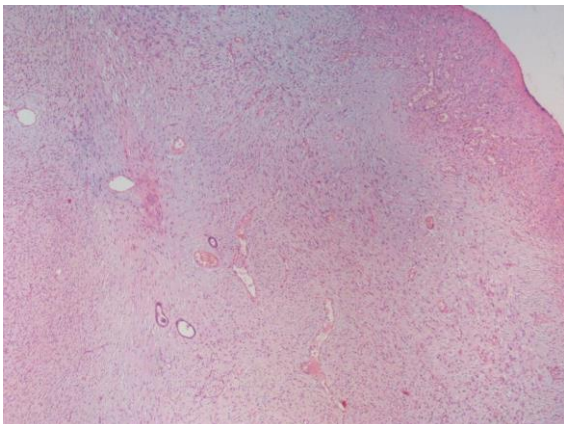
- Genellikle ilk dekat
- Epidermin hemen altından başlar
- Touton tipi multinükleer dev hücreler
- Yangısal hücreler
- CD-34 negatif



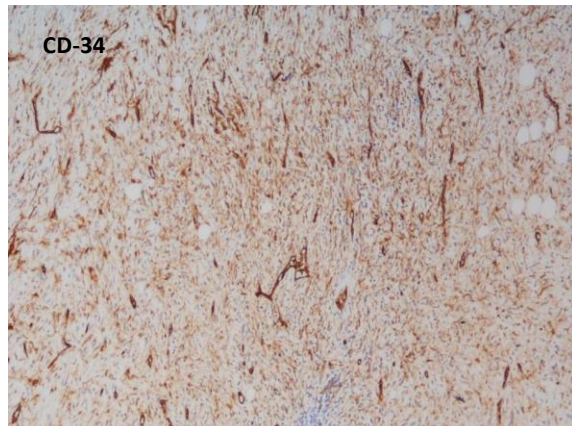
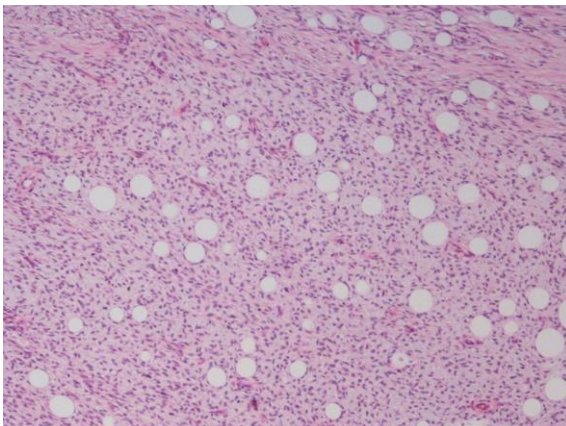
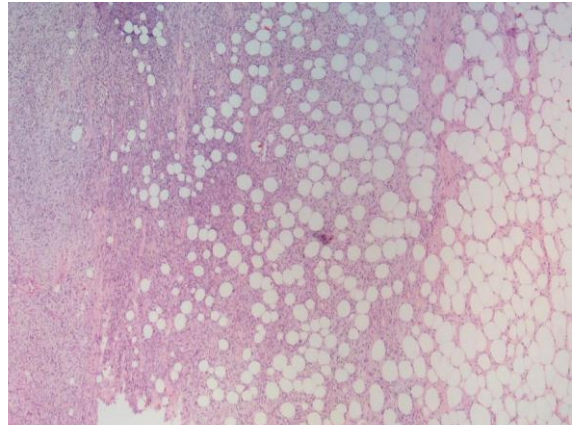
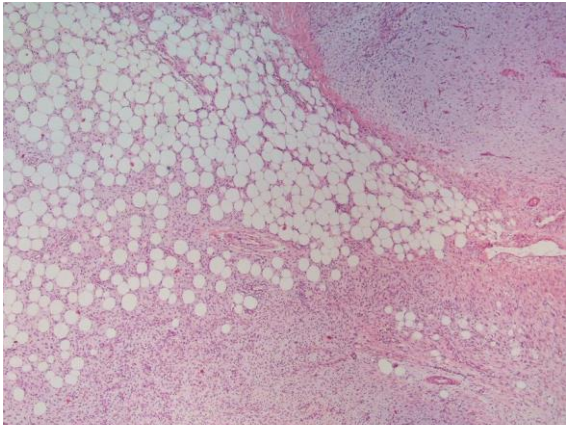
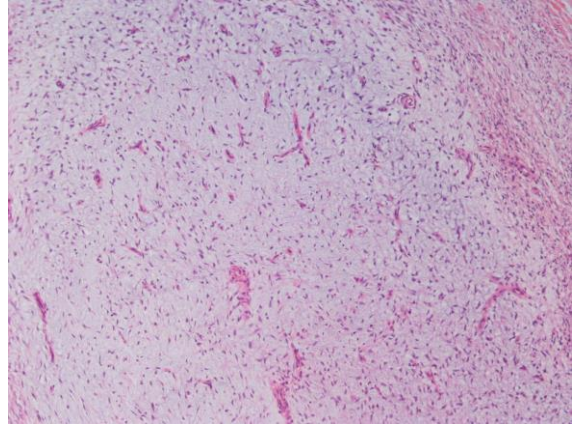
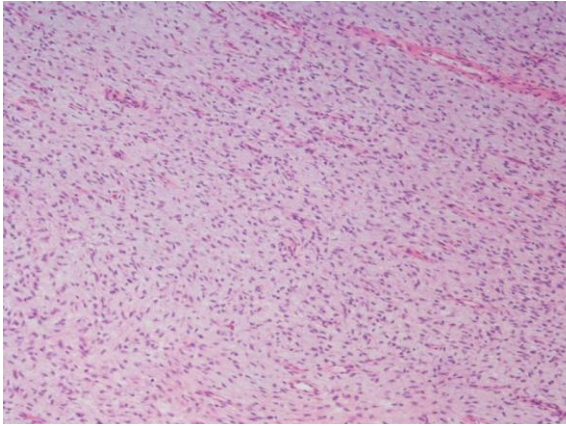


### Miksoid DFSP

- DFSP nin morfolojik varyantı
- Tümörün %50 den fazlasında miksoid zemin var
- 23 miksoid DFSP
- Ortalama 3 cm
- 16 sında tipik DFSP benzeri hüresel alan var
- Tümünde bal peteği tarzında yağ doku invazyonu var
- %95 inde CD34 pozitif ancak konvansiyonel DFSP e göre daha dağınık ve soluk pozitif olabilir
- Reimann, J D.R.; Fletcher, C D.M. Am J Surg Pathol 2007, 31, 1371









## Miksoid DFSP, Ayırıcı tanı

- Yüzeysel anjiomiksom
- Yüzeysel akrall fibromiksom
- Miksoid nörofibrom
- Miksoid soliter fibröz tümör
- Miksoid perinörom
- Düşük dereceli miksofibrosarkom
- Düşük dereceli fibromiksoid sarkom
- Miksoid liposarkom
- Miksoid sinovyal sarkom

## Fibrosarkomatöz DFSP

- DFSP alanlarına komşu kalabalık uzun demetler
- CD34 kaybı(yarisında), p53 ekspresyonu (%25-90)
- **De novo** veya nükslerden sonra görülebilir
- Metastaz olasılığında artış (%14'ünde)
- Primer fibrosarkoma göre met oranı daha düşük
- DFSP + DFSP-FS olgularının yaklaşık %15'i

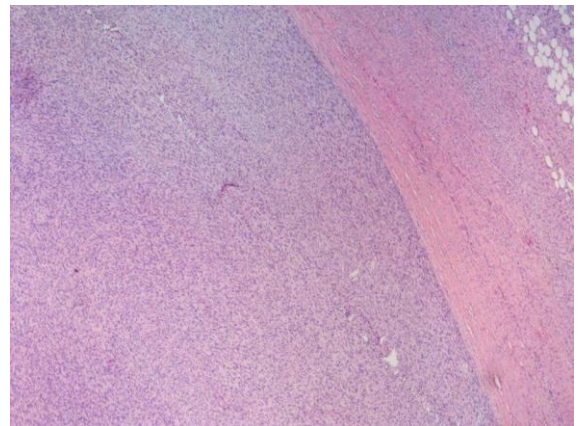
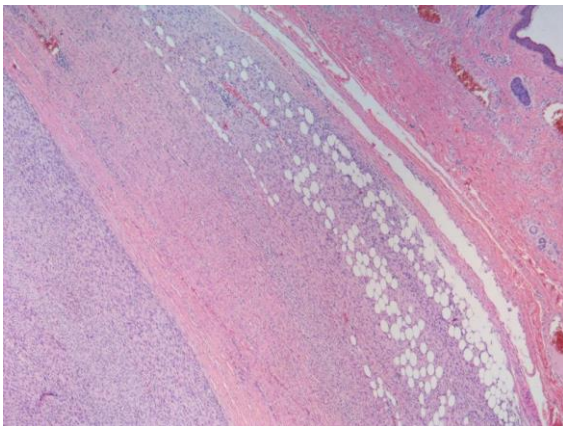
## Fibrosarkomatöz DFSP

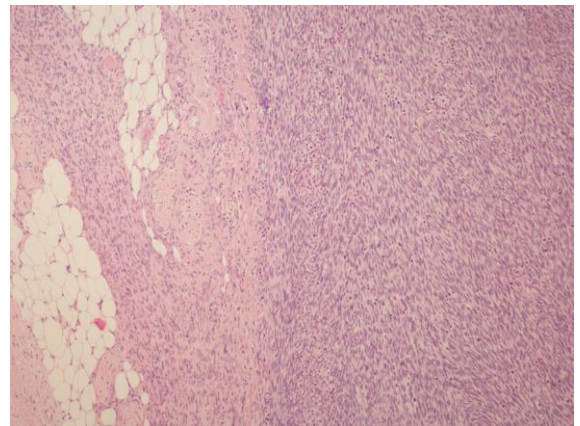
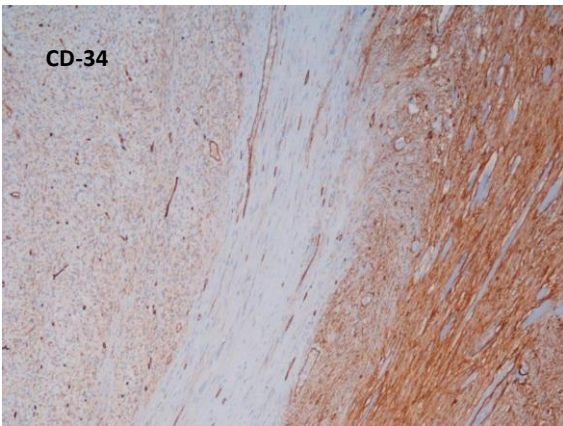
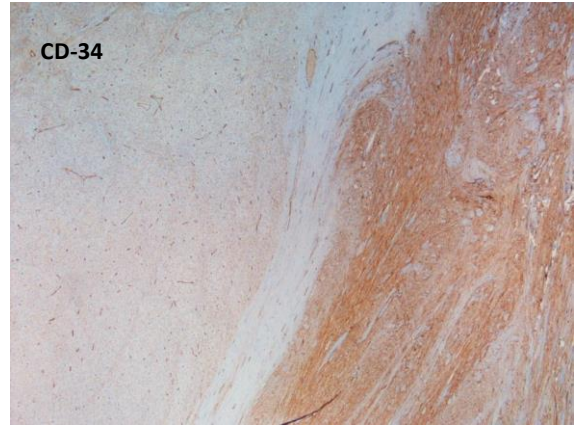
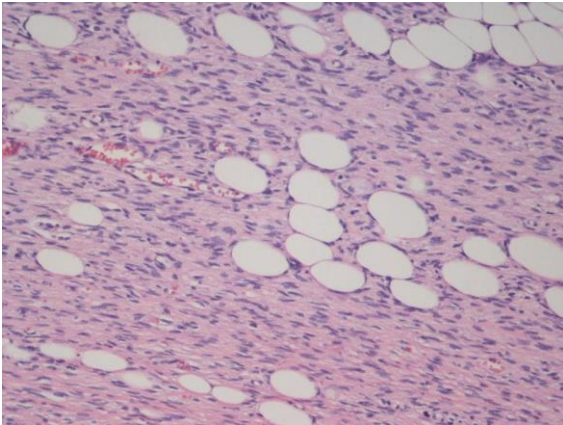
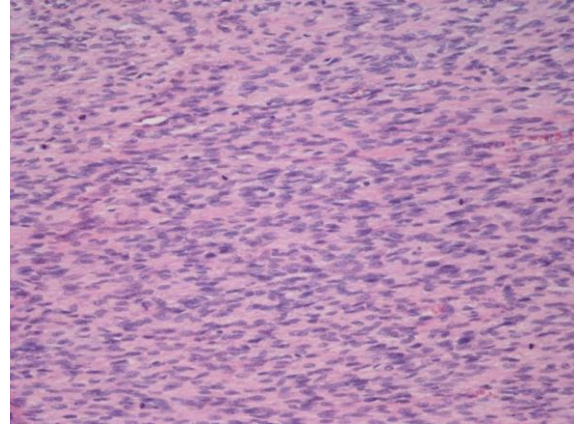
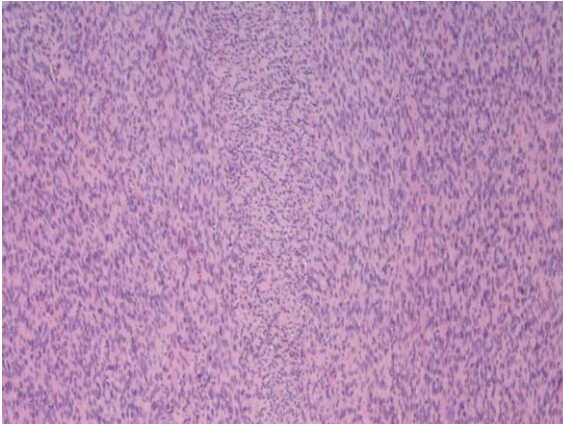
- Tümörün %25 inden azını oluşturabilir (Yaklaşık olguların % 20'sinde)
- DFSP ile keskin geçişli olabilir veya olmayabilir
- Subkutanöz infiltrasyon genellikle ekspansiv
- Mitotik indeks daha yüksek ( 10 BBA da 2 V 7)
- DFSP-FS olgularının büyük çoğunluğu >4 cm

## Fibrosarkomatöz DFSP

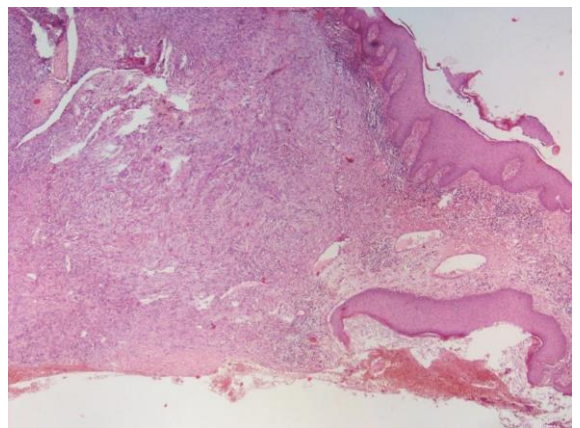
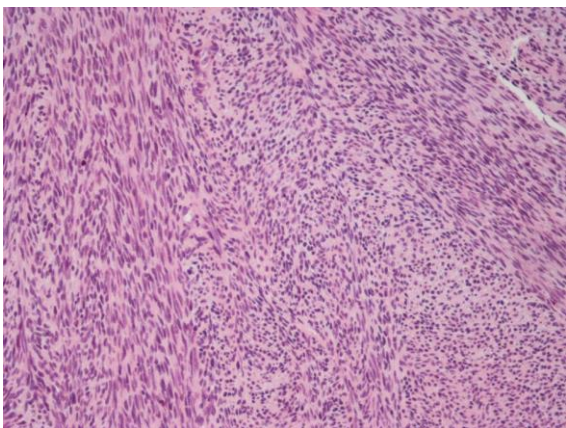
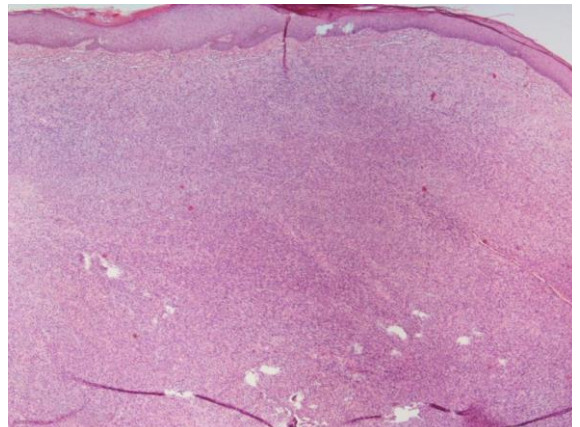
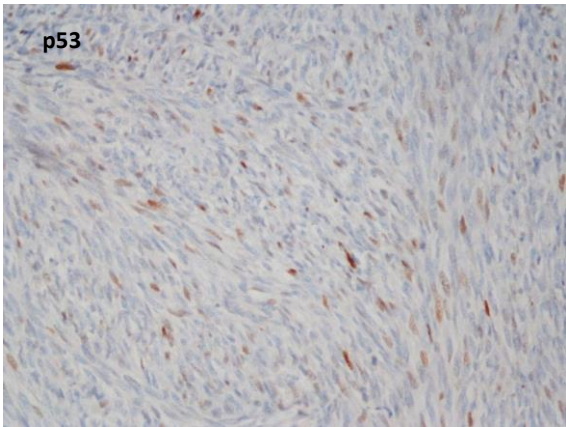
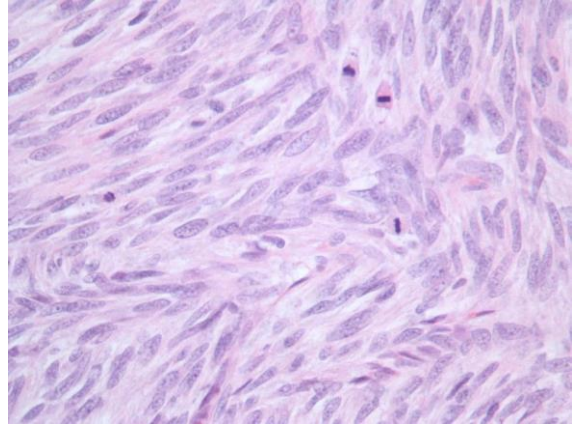
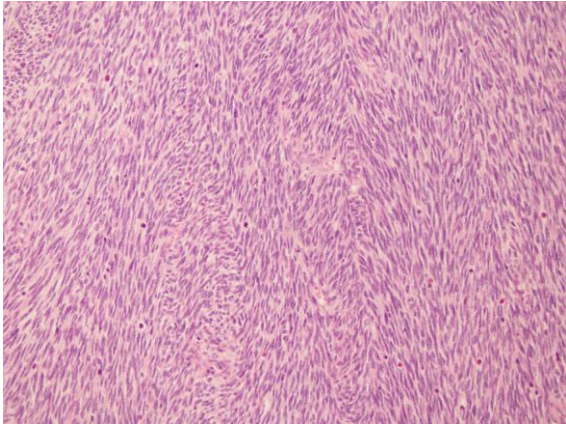
- 225 DFSP-FS, 1422 DFSP olguluk 24 çalışmaya dayanan metanaliz
- Nüks oranı 29,8 V 13,7
- Metastaz oranı %14,4 V %1,1
- Tümöre bağlı ex %14,7 V %0,8
- Fibrosarkomatöz alanların oranları prognostik fark yaratmamış (64 olguya göre)

\* Liang CA et al. J Am Acad Dermatol 2014;71:781

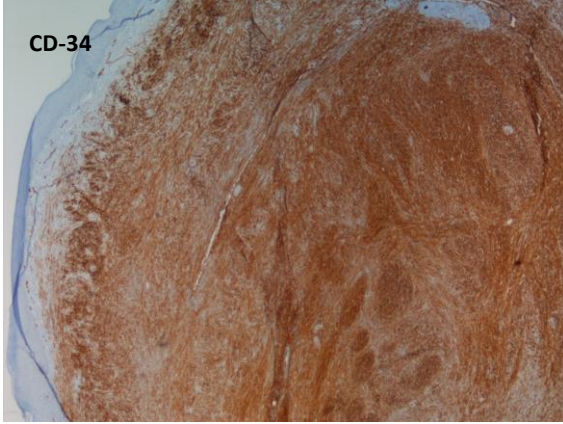








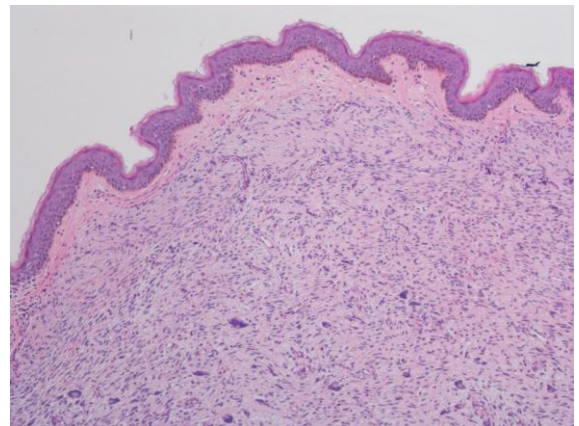
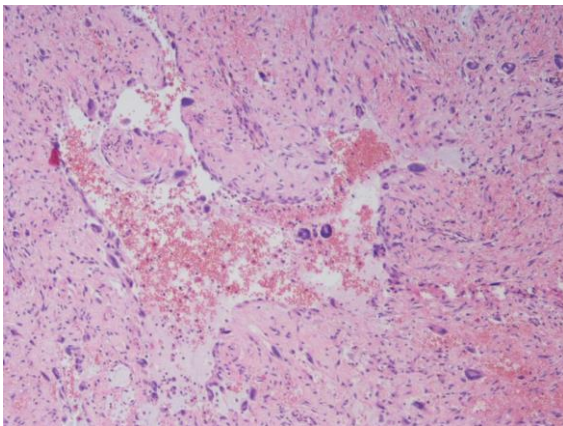
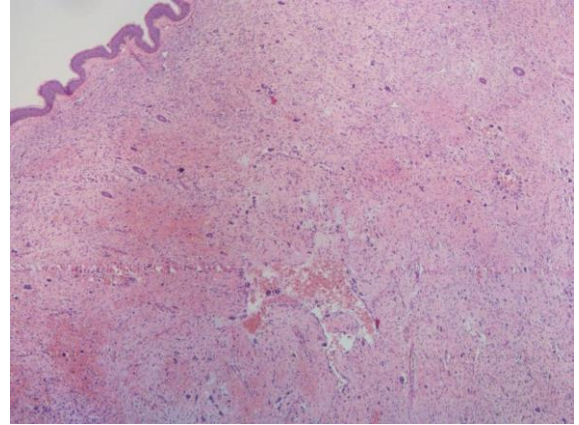




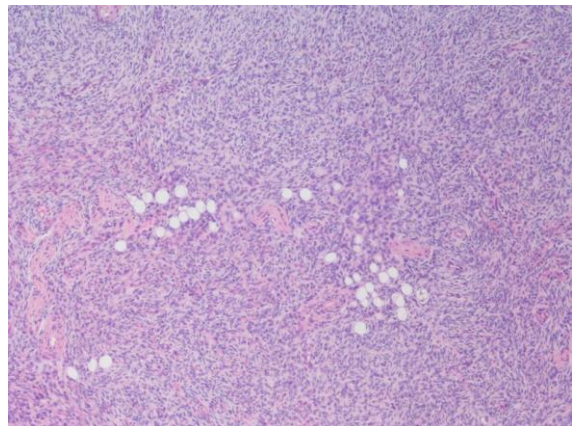
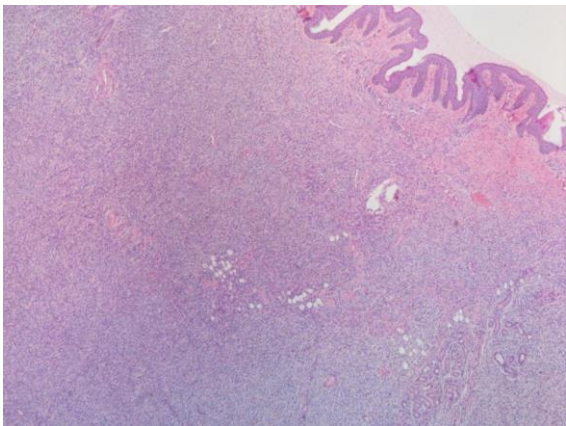
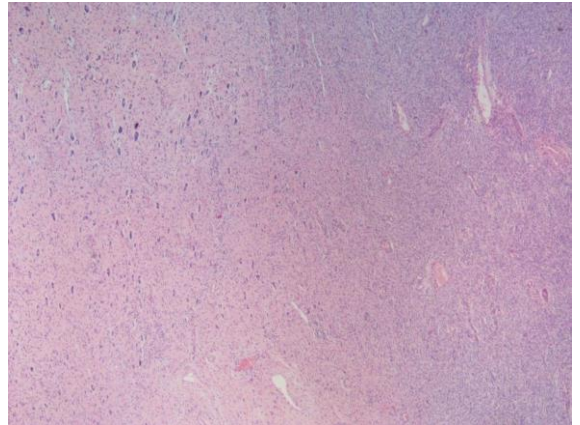
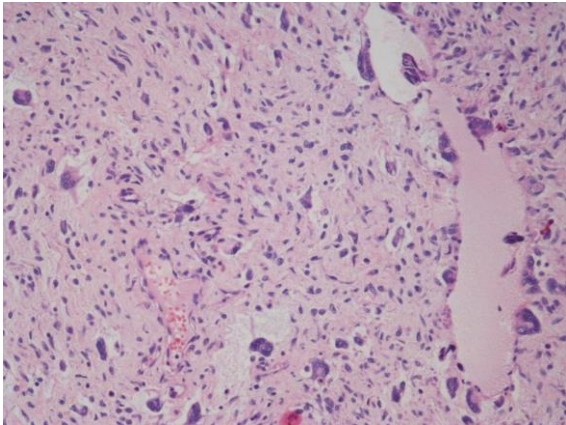
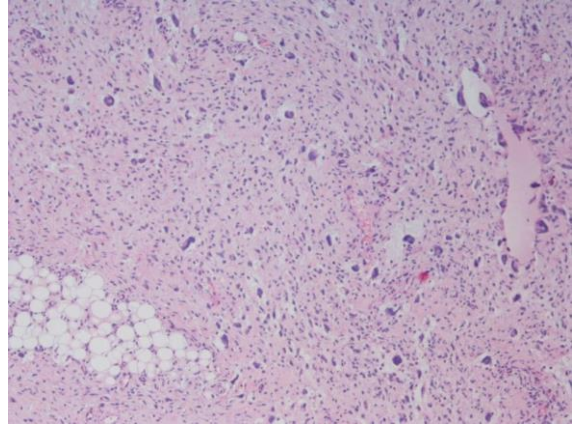
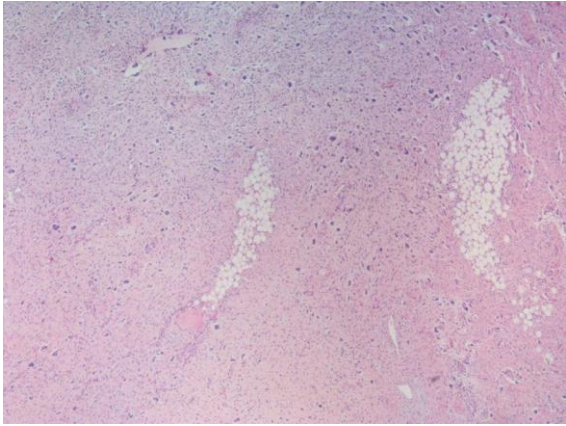
- İnop veya metastatik olgularda hedefe yönelik tedavi (tirozin kinaz inhibitörü (imatinib)) uygulanabilir
- FISH veya RT-PCR ile translokasyon veya COL1A1 - PDGFB füzyonu ortaya konmalıdır

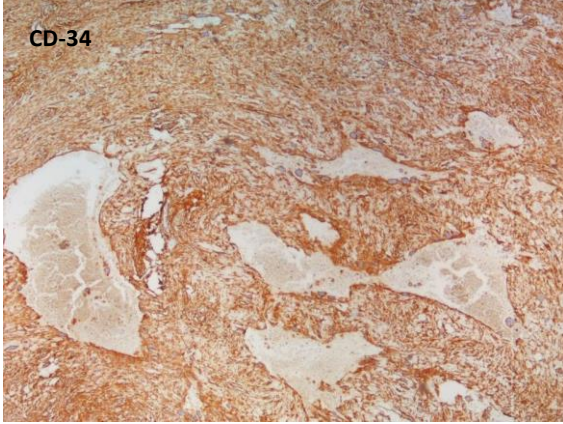
### Dev hücreli fibroblastom

- DFSP in çocuklarda görülen formu
- Morfolojik olarak hiposellüler ve kollagenize zemin daha belirgin
- Damar boşluklarını anımsatan alanları döşeyen multinükleer dev hücreler tipik









- Giant cell fibroblastoma: an update and addition of 86 new cases from the Armed Forces Institute of Pathology, in honor of Dr. Franz M. Enzinger.

• Jha P, et al. Ann Diagn Pathol. 2007 Apr;11(2):81

- 1989 da Enzinger ve Weiss tarafından AFIP arşivinden 28 olgu ile tanımlanmış
- Yirmi yıl sonra AFIP arşivinden 86 yeni olgu
- Ortalama yaş 6, Olguların %62 si ilk dekatta
- 40 yaş üzerinde 10 olgu
- 14 olguda DFSP alanları var (hibrid tm)
- Klinik ve morfoloji 20 yıl önce tanımlanan ile aynı (sadece pv kr yangı ve fasyaya komşu hemoraji)
- Farklı olarak DFSP nin bir spektrumu olduğu İHK ve moleküler bulgu ile kesinleşmiş durumda

## Özet

- DFSP çok nadir met yapan uygun eksize edilmez ise yüksek nüks görülen CD-34 pozitif fibroblastik tm
- Fibrosarkomatöz komponent eklenir ise met oranı %14
- Spesifik moleküler bulgusu ve hedefe yönelik tedavi imkanı var
- Pigmentli, miksoid, plak/atrofik varyantları var
- Ayırıcı tanıda fibröz histiyositom sıkıntılı olabilir



- DFSP de myoid/myofibroblastik nodüller görülebilir
- Kaynaklarda yayınlanmış yaklaşık 30 olgu var
- Bernárdez C et al. Dermatofibrosarcoma Protuberans of the Vulva With Myoid Differentiation
- Am J Dermatopathol 2015;37:e107–e111)



