

-Olgu sunumu-

Dr. Sule CANBERK

Patoloji ve Sitopatoloji Uzmanı

Haydarpaşa Numune Eğitim ve Araştırma Hastanesi

Patoloji Kliniği



25. Ulusal Patoloji Kongresi
6. Sitopatoloji Kongresi

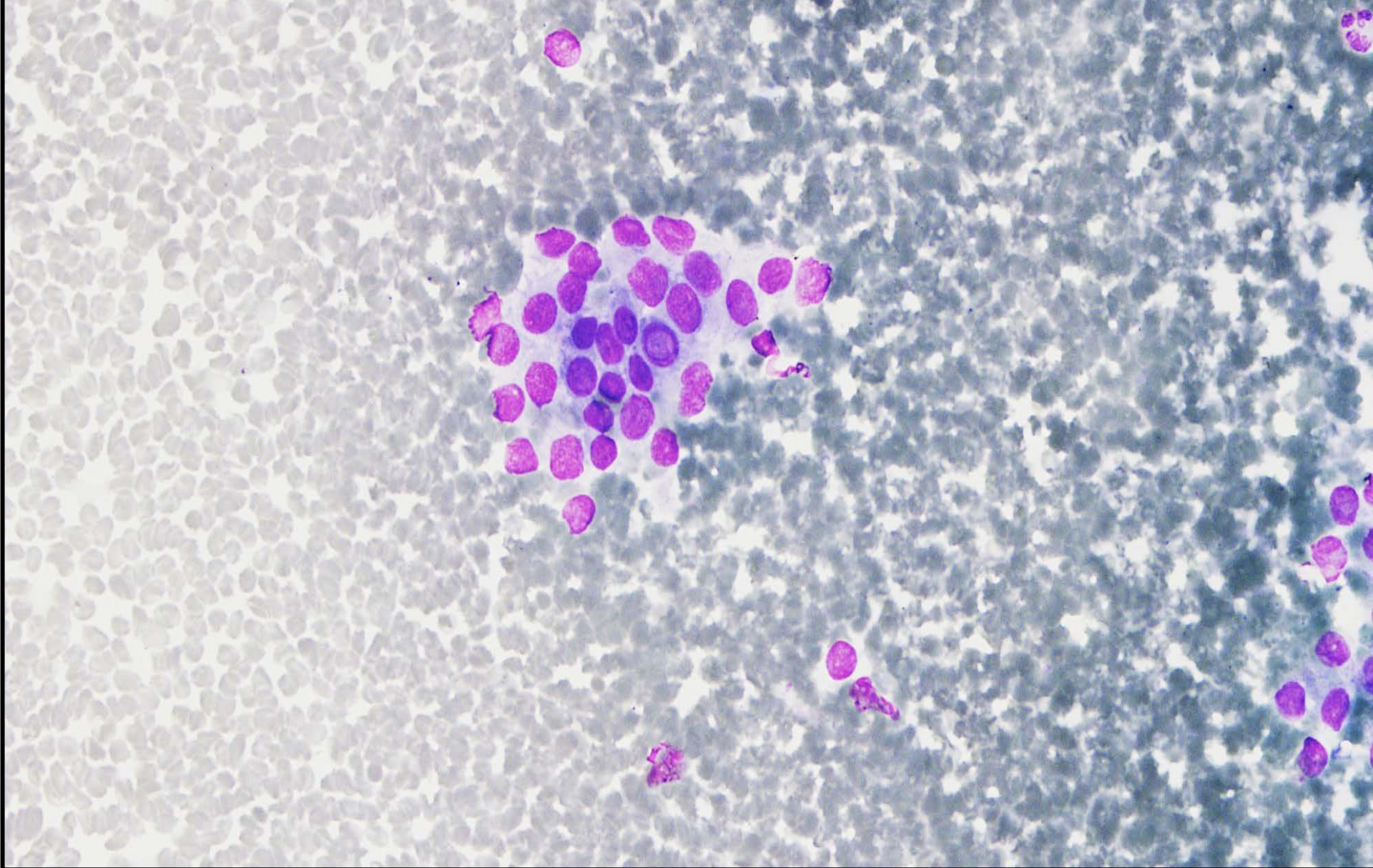
14 - 17 Ekim 2015 / Merinos AKKM - BURSA



Olgu 1

- Tiroid sag lob
- 1.3 mm capli supheli nodul
- TIRADS 4
- Dusuk TSH

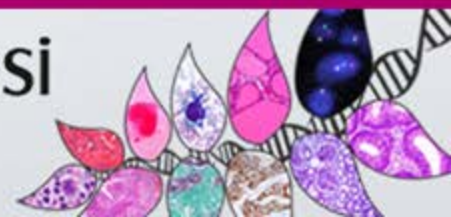

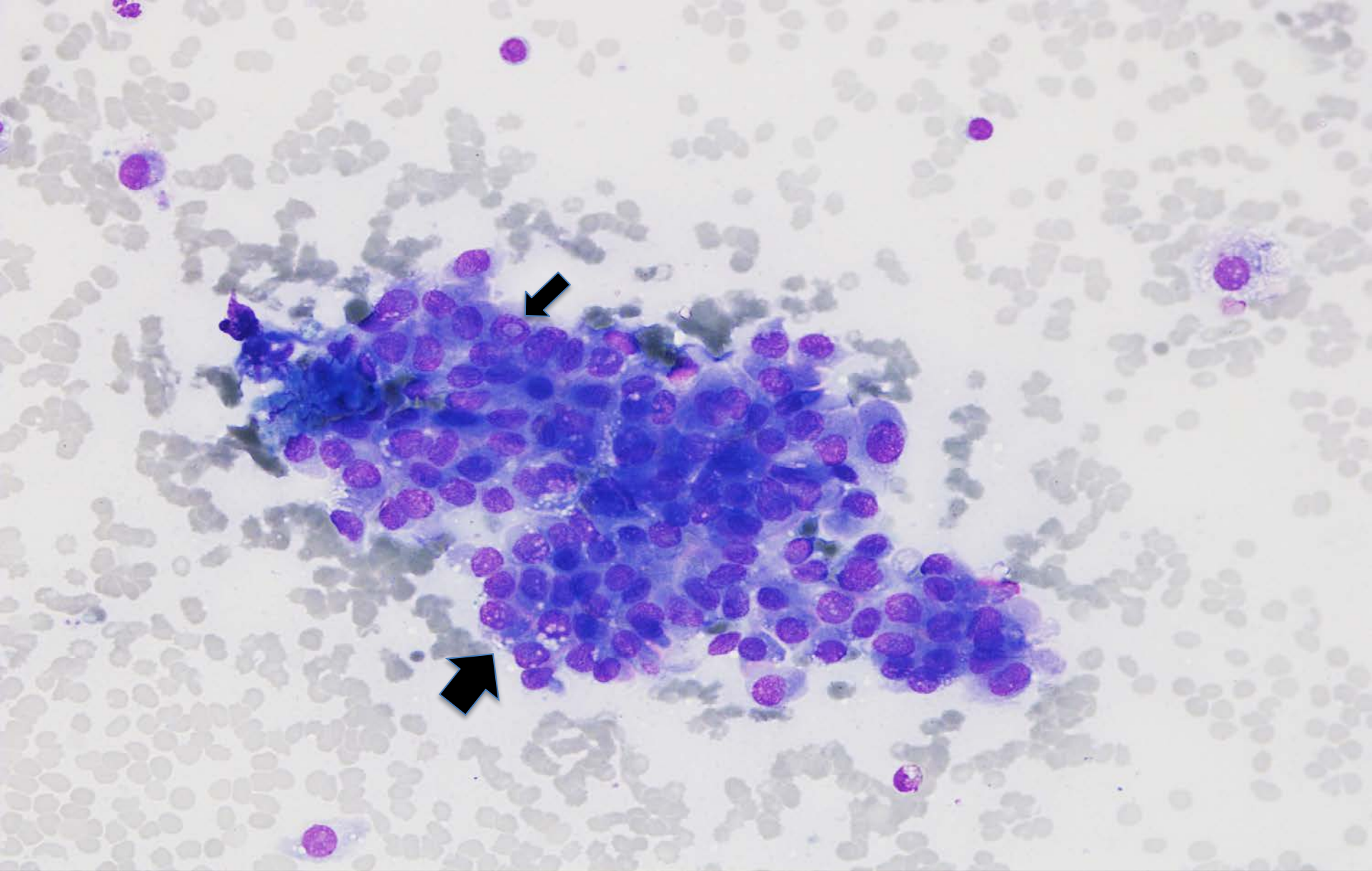


25. Ulusal Patoloji Kongresi

6. Sitopatoloji Kongresi

14 - 17 Ekim 2015 / Merinos AKKM - BURSA

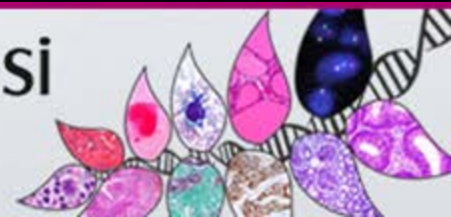

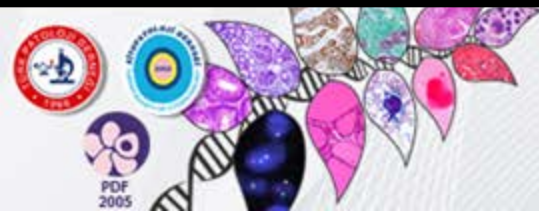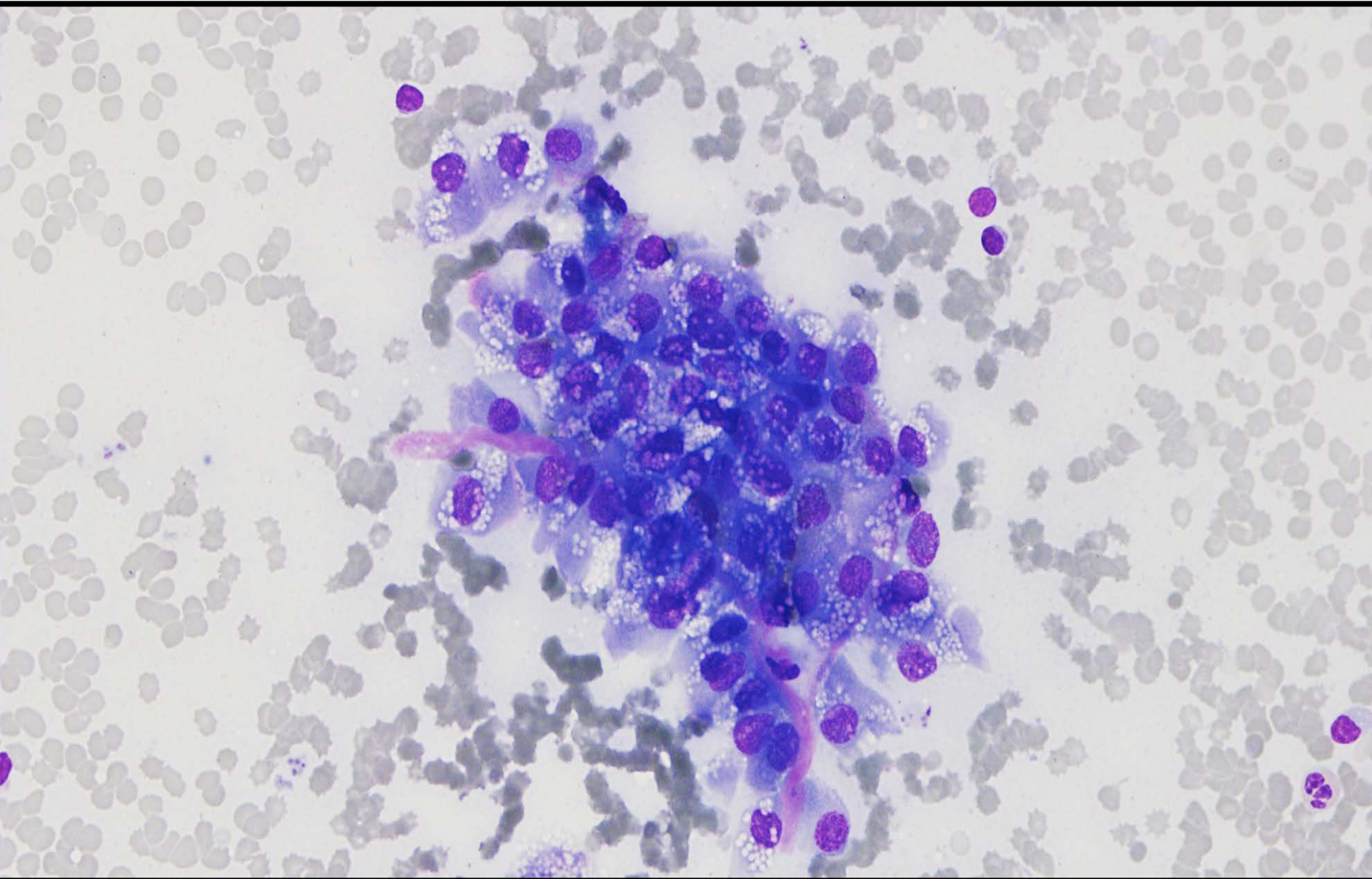


25. Ulusal Patoloji Kongresi

6. Sitopatoloji Kongresi

14 - 17 Ekim 2015 / Merinos AKKM - BURSA

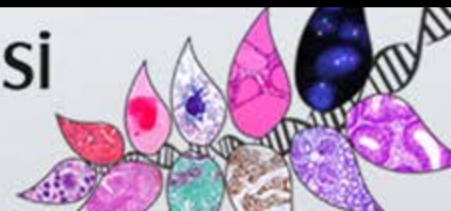

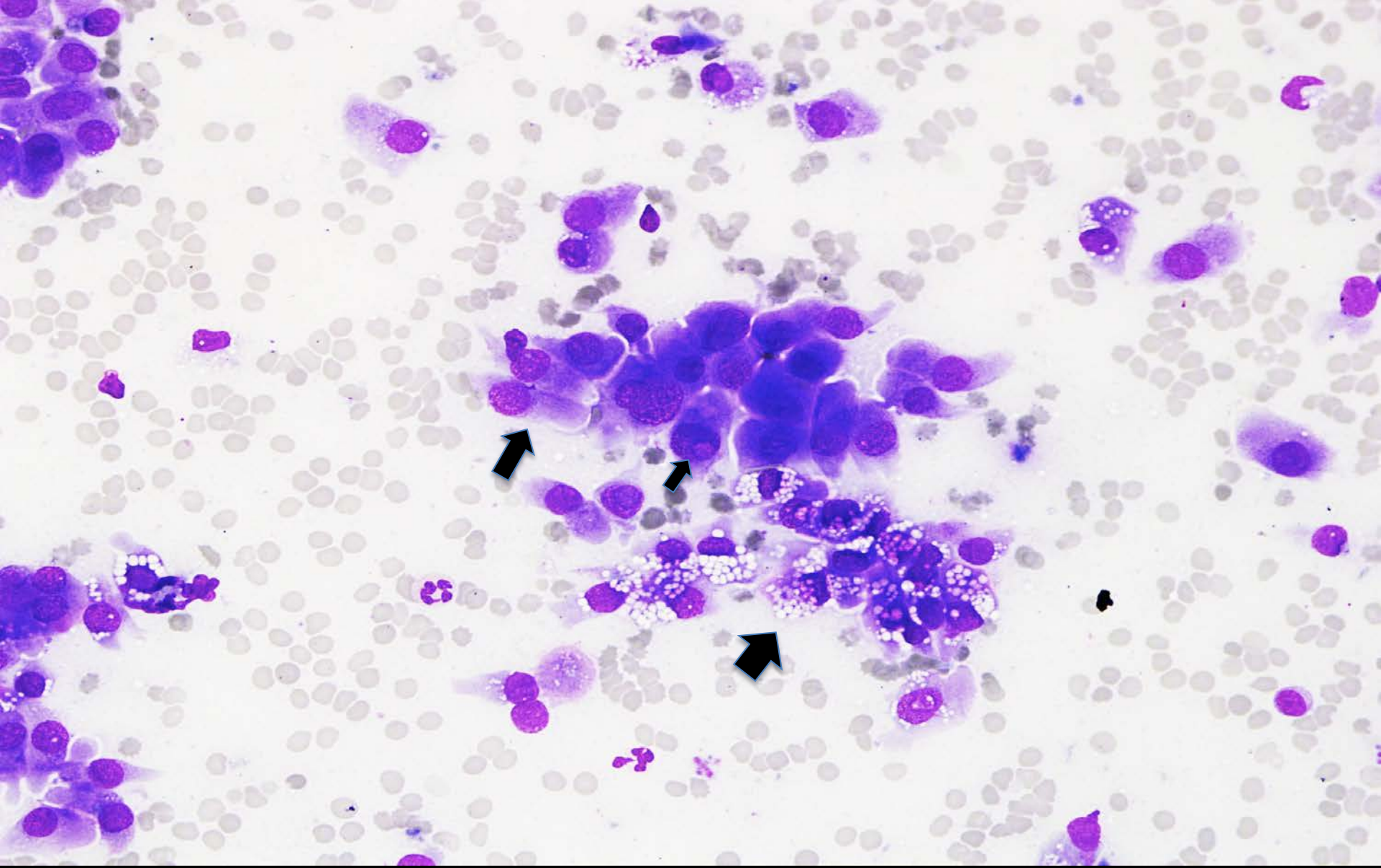


25. Ulusal Patoloji Kongresi

6. Sitopatoloji Kongresi

14 - 17 Ekim 2015 / Merinos AKKM - BURSA





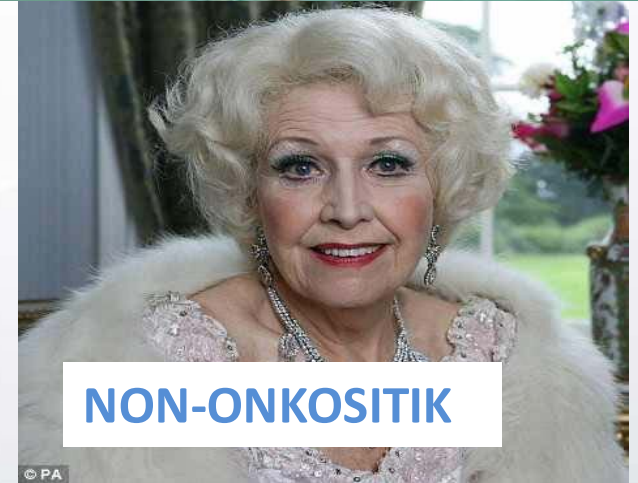25. Ulusal Patoloji Kongresi

6. Sitopatoloji Kongresi

14 - 17 Ekim 2015 / Merinos AKKM - BURSA

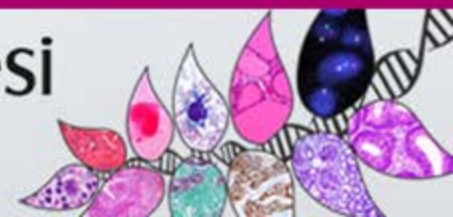

- Onkositik morfoloji
- Ucurtma hucreler
- SIK intranukleer inkluzyon



25. Ulusal Patoloji Kongresi
6. Sitopatoloji Kongresi

14 - 17 Ekim 2015 / Merinos AKKM - BURSA



PTC
demedik
mi?



AYIRICI TANI;

Agresiv
varyantlar????



25. Ulusal Patoloji Kongresi
6. Sitopatoloji Kongresi

14 - 17 Ekim 2015 / Merinos AKKM - BURSA



VARYANTLARI TANIMLAMAK NEDEN ONEMLI?

Klasik PTC

Agresiv
Varyant PTC

ETE

REKURENS

"I "TDV.NE
DIRENC

AKTIVIS LEINF
NODU TUTULUMU
VE UZAK
METASTAZ

5 yillik sag kalim
%97



25. Ulusal Patoloji Kongresi
6. Sitopatoloji Kongresi

14 - 17 Ekim 2015 / Merinos AKKM - BURSA



AYIRICI TANI

PAPILLER TIROID KARSINOMUNUN ONKOSTİK MORFOLOJİDE VARYANLARI

IYI S
ONİ
WA

Review

doi: 10.5146/tjpath.2015.01312

Pitfalls in the Cytological Assessment of Thyroid Nodules

Şule CANBERK¹, Pınar FIRAT², Fernando SCHMITT^{3,4}

Department of Pathology, ¹Haydarpaşa Numune Education and Research Hospital, ISTANBUL, TURKEY; ²Istanbul University, Istanbul Faculty of Medicine, ISTANBUL, TURKEY;

³Department of Pathology and Medicine, Laboratoire National de Santé, LUXEMBOURG

⁴Instituto de Patologia e Imunologia Molecular da Universidade do Porto (IPATIMUP), PORTO, PORTUGAL

ONKOSTİK VARYANT MEDULLER TIROID KARSINOMU



25 Ulusal Patoloji Kongresi
6 Sitopatoloji Kongresi

14 - 17 Ekim 2015 / Merinos AKKM - BURSA



TALL CELL VARYANT PTK

- Poligonal- santral yerlesimli nukleus
- Uzamis, silindirik ve ekzantrik yerlesimli nukleus--- "tail-like cells ", " tad-pole cells"
- 2:1, 3:1---WHO 2004
- Abondan ve iyi sınırlı sitoplazma dolayısıyla, overlapping daha az
- Groove ve intranukleer inklüzyon ("soap-bubble" karakteristik) bol



Review Article

Aggressive Variants of Follicular Cell-Derived Thyroid Carcinomas

A Cytopathologist's Perspective

Ricardo R. Lastra, MD¹; Virginia A. Livolsi, MD²; and Zubair W. Baloch, MD, PhD¹

Received: April 25, 2013
Accepted after revision: June 16, 2013
Published online: September 7, 2013

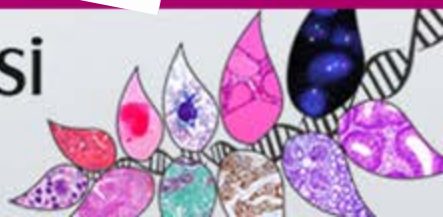Can We Distinguish Papillary Thyroid Nodule Aspirates from the Conventional Assessment of Diagnostic Accuracy

Juan C. Christopher J. VandenBussche^a Yener S. Erozan^a
Dorothy L. Rosenthal^a Armanda D. Tatsas^a Matthew T. Olson^a Rui Zheng^a
Manon Auger^d Syed Z. Ali^{a, b}



25
Patoloji Kongresi
Patoloji Kongresi

14 - 15 / Merinos AKKM - BURSA



Warthin-like PTK

- En
- 2 o
- oln
- var
- Sik
- PAPILLER KOR ICINDE LENFOSITIK INFILTRAT VARLIGI !!!

MINI-SYMPOSIUM: ENDOCRINE PATHOLOGY

Newly described tumours of the thyroid

Z. W. Baloch and V. A. LiVolsi

Department of Pathology and Laboratory Medicine, University of Pennsylvania Medical Center, 3400 Spruce Street, 6 Founders Pavilion, Philadelphia, PA, 19104, USA

“Warthin-like papillary thyroid carcinoma, benign

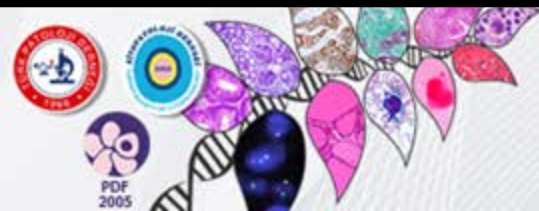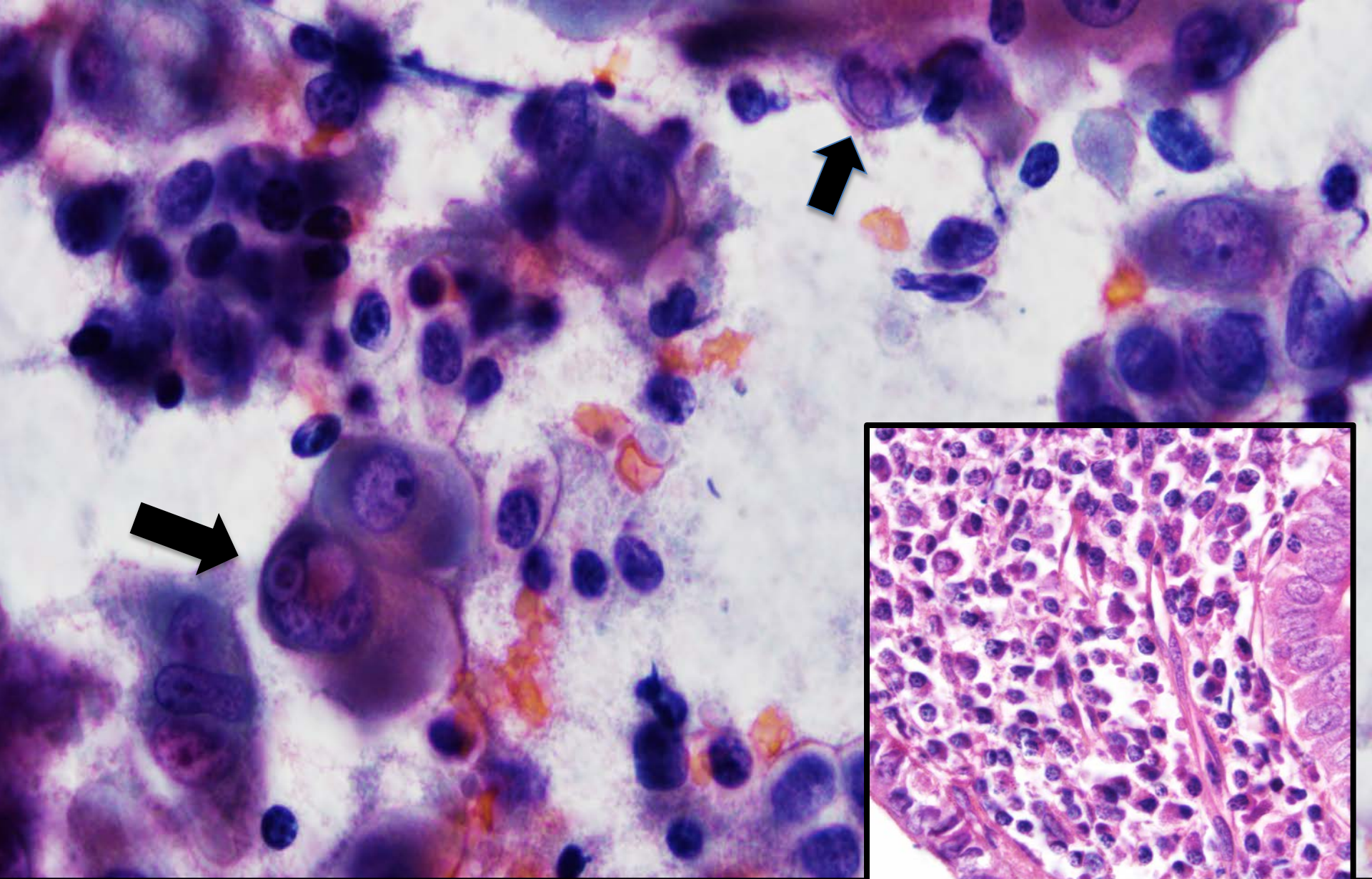
lenfoepitelyal kist” ile karisabilir.



25 Ulusal Patoloji Kongresi
6 Sitopatoloji Kongresi

14 - 17 Ekim 2015 / Merinos AKKM - BURSA





25. Ulusal Patoloji Kongresi

6. Sitopatoloji Kongresi

14 - 17 Ekim 2015 / Merinos AKKM - BURSA



Hobnail varyant PTK

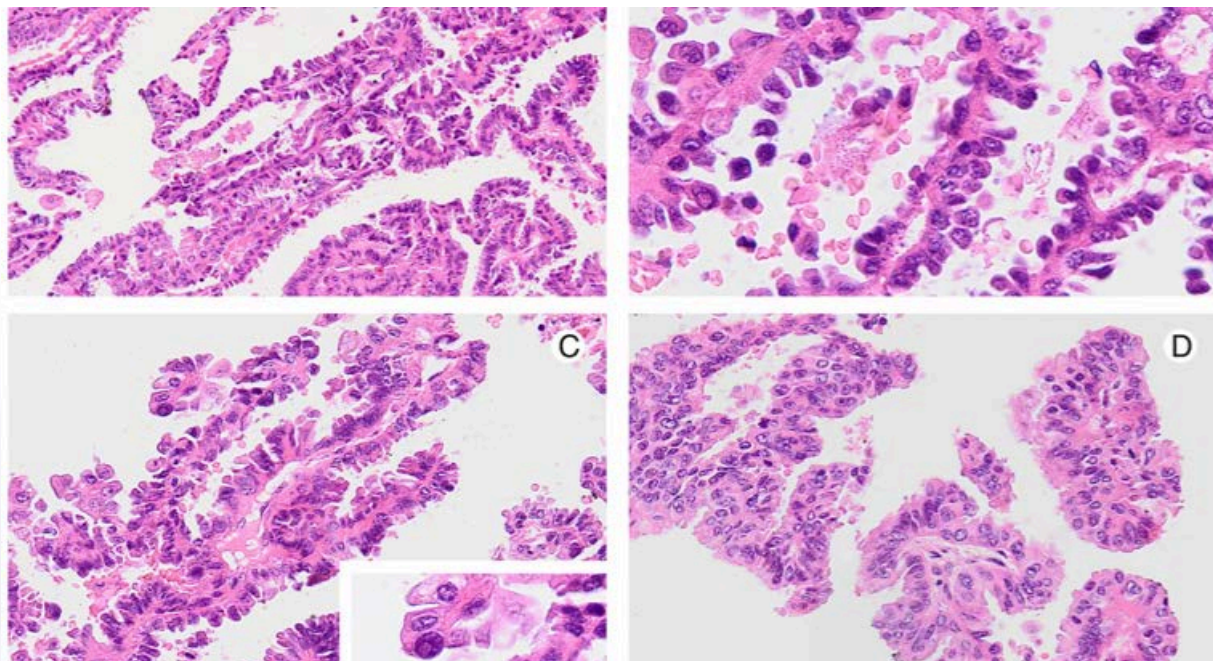
- Artmis N/S oran
- Keskin hucre sinirlari
- Elonge tumor hucreleri
- Kiremit benzeri siralanma; overlapping- kalabaliklasma yok
- Sabun kopugu benzeri intranukleer inkluzyon (TALL CELL ILE KARISIR)
- Nukleer groove ve intranukleer inkluzyonlar klasik tipe gore daha az
- Belirgin damar yapilari !!!
- Kuyruklu yildiz benzeri hucreler
- Cerebriform nuclei



Original contribution

Papillary thyroid carcinoma with hobnail features: histopathologic criteria to predict aggressive behavior☆☆☆

Sofia Asioli MD^{a,*}, Lori A. Erickson MD^b, Alberto Righi MD^a,
Ricardo V. Lloyd MD, PhD^c



25. Ulusal Patoloji Kongresi
6. Sitopatoloji Kongresi

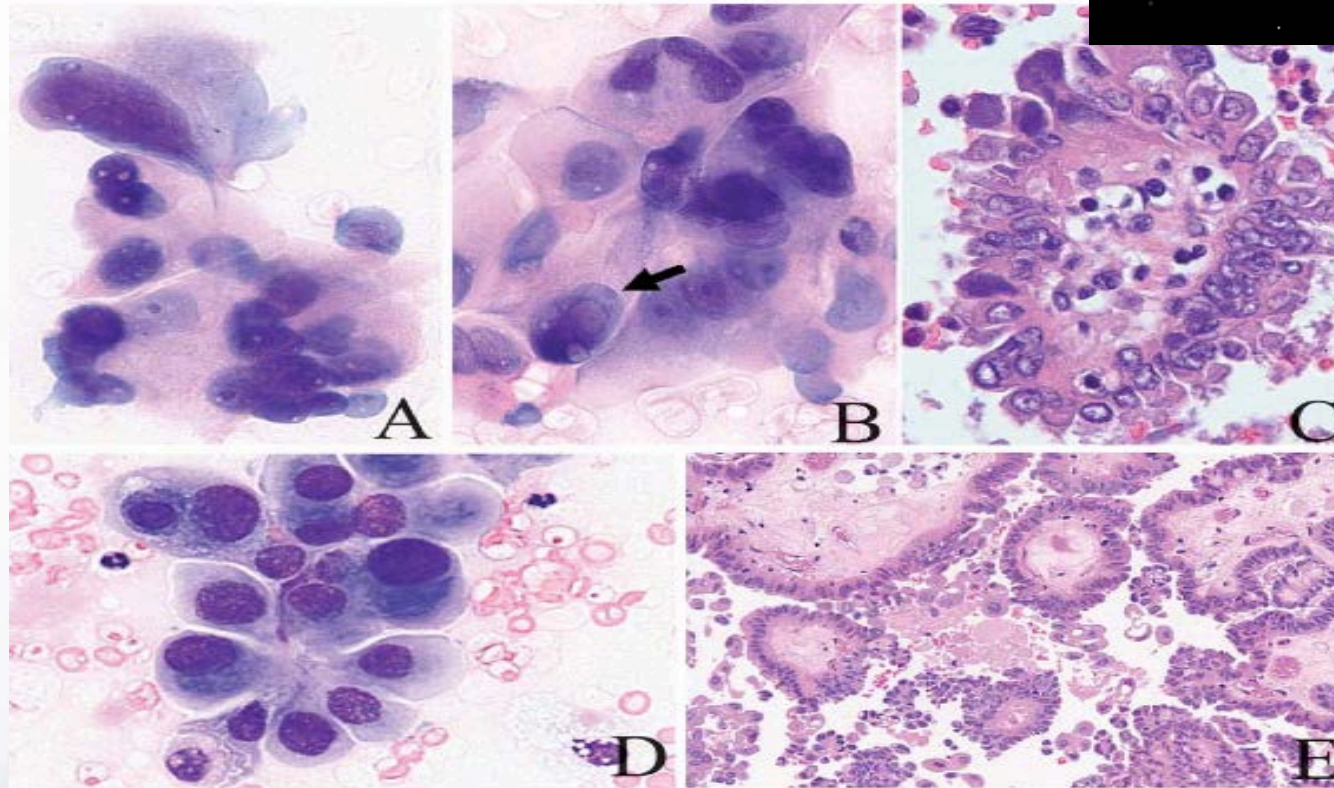

14 - 17 Ekim 2015 / Merinos AKKM - BURSA



Cytomorphologic and Molecular Features of Hobnail Variant of Papillary Thyroid Carcinoma:

Case Series and Literature Review

Sofia Asioli, M.D.,^{1*} Francesca Maletta, M.D.,¹ Fabio Pagni, M.D.,²
Donatella Pacchioni, M.D.,¹ Alice Vanzati, M.D.,² Sara Mariani, B.S.,¹
Nicola Palestini, M.D.,³ Ricardo V. Lloyd, M.D., Ph.D.,⁴ and
Anna Sapino, M.D.¹

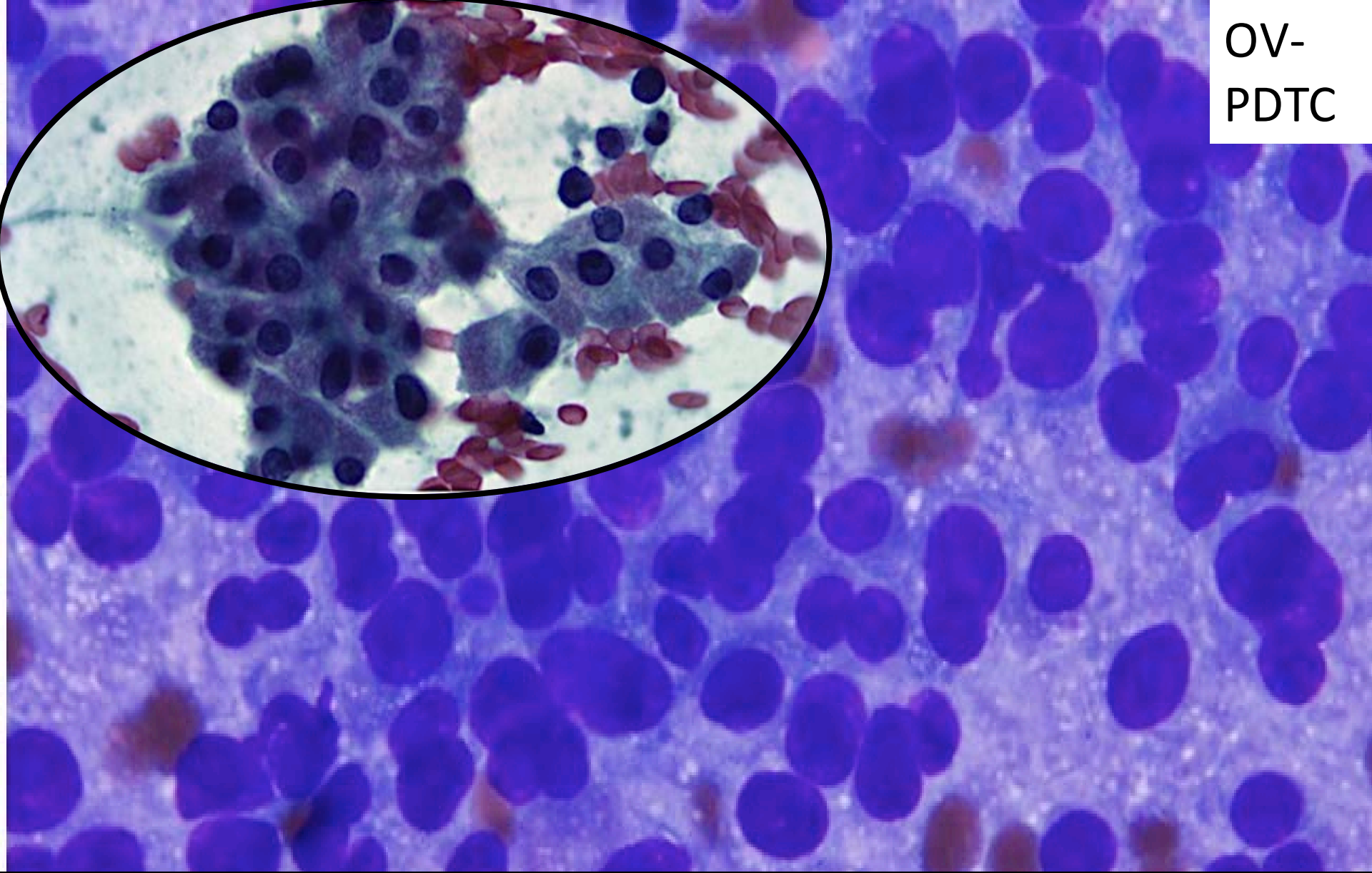


25 Ulusal Patoloji Kongresi
6 Sitopatoloji Kongresi

14 - 17 Ekim 2015 / Merinos AKKM - BURSA



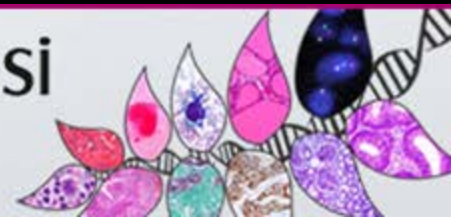OV-
PDTC



25. Ulusal Patoloji Kongresi

6. Sitopatoloji Kongresi

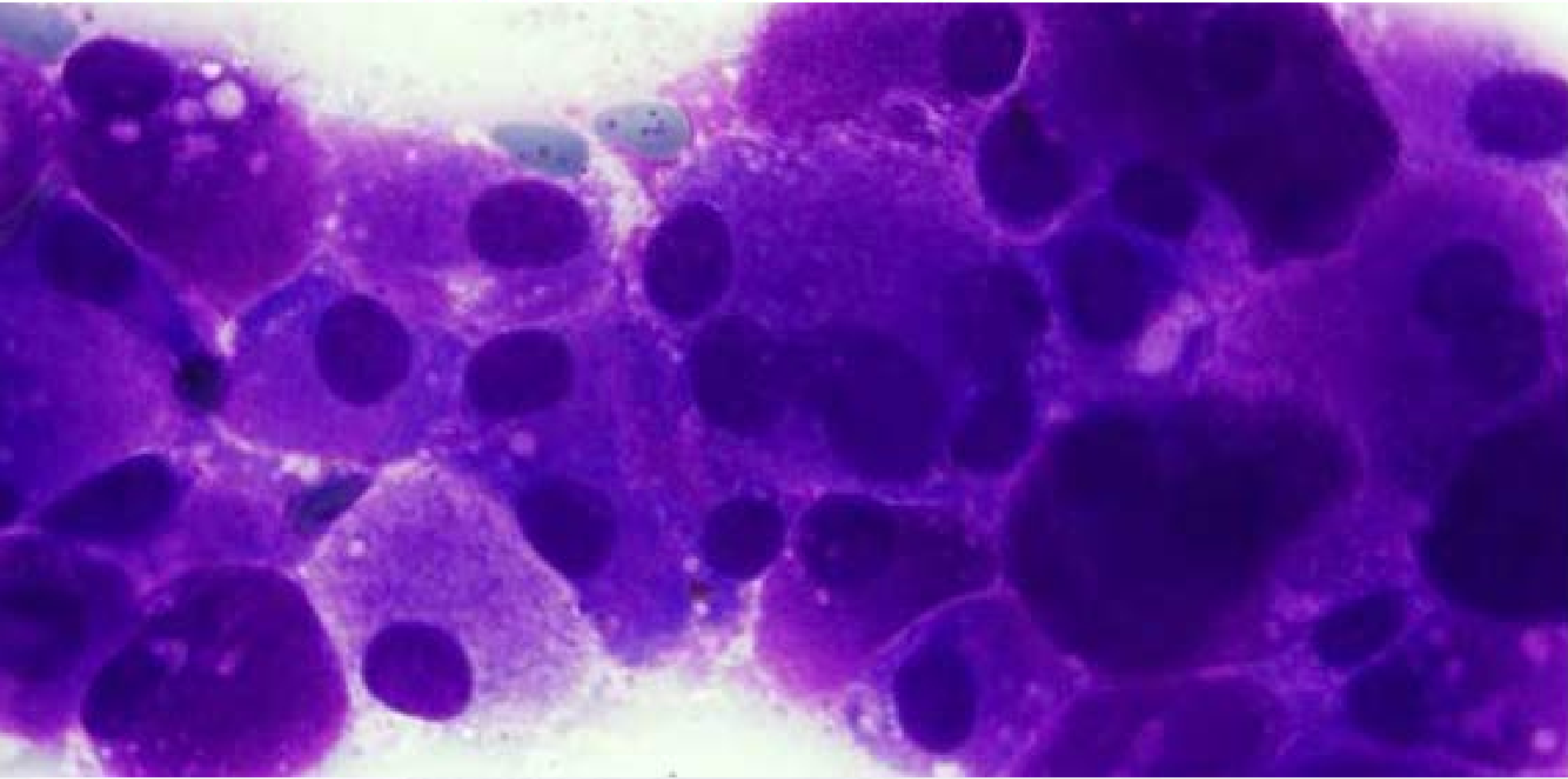
14 - 17 Ekim 2015 / Merinos AKKM - BURSA



Endocr Pathol. 2015 Aug 21. [Epub ahead of print]

Oncocytic Variant of Medullary Thyroid Carcinoma.

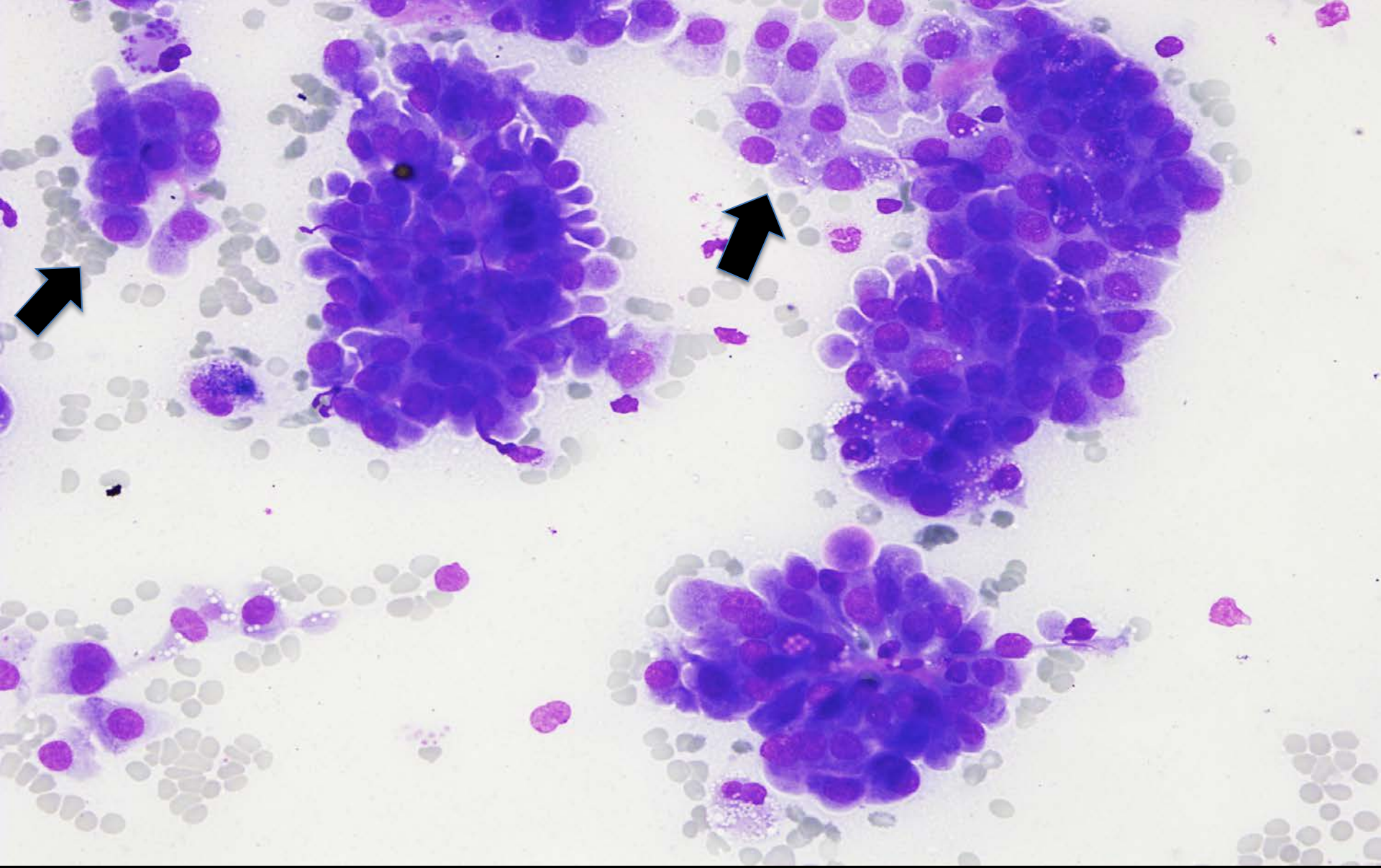
Canberk S¹, Onenerk M, Gunes P, Sayman E, Kilicoglu G.



25 Ulusal Patoloji Kongresi
6 Sitopatoloji Kongresi

14 - 17 Ekim 2015 / Merinos AKKM - BURSA



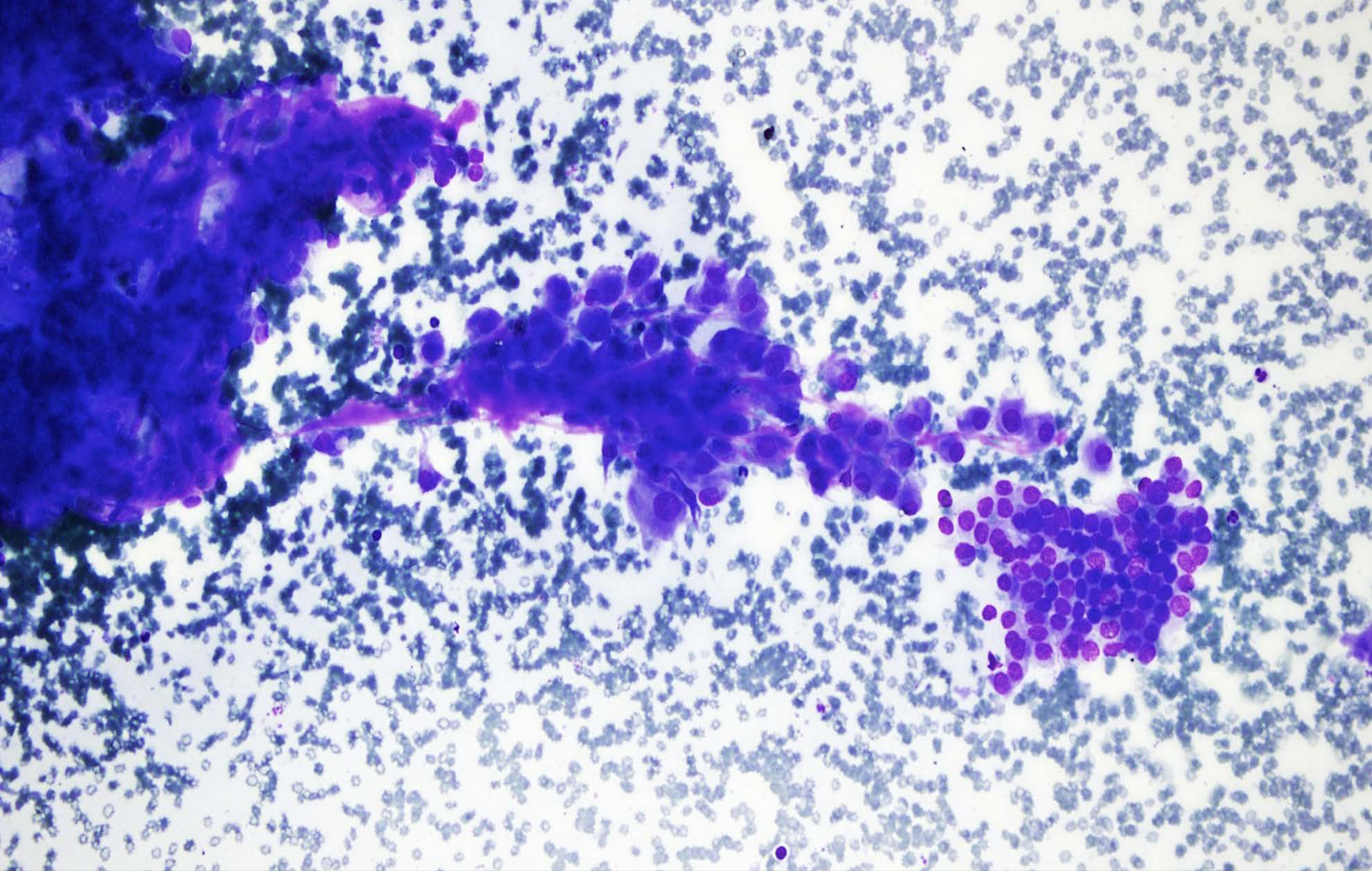


25. Ulusal Patoloji Kongresi

6. Sitopatoloji Kongresi

14 - 17 Ekim 2015 / Merinos AKKM - BURSA

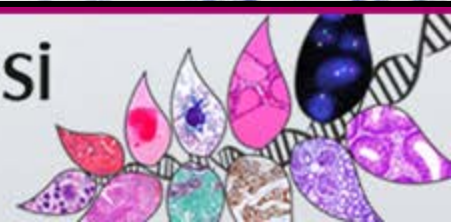

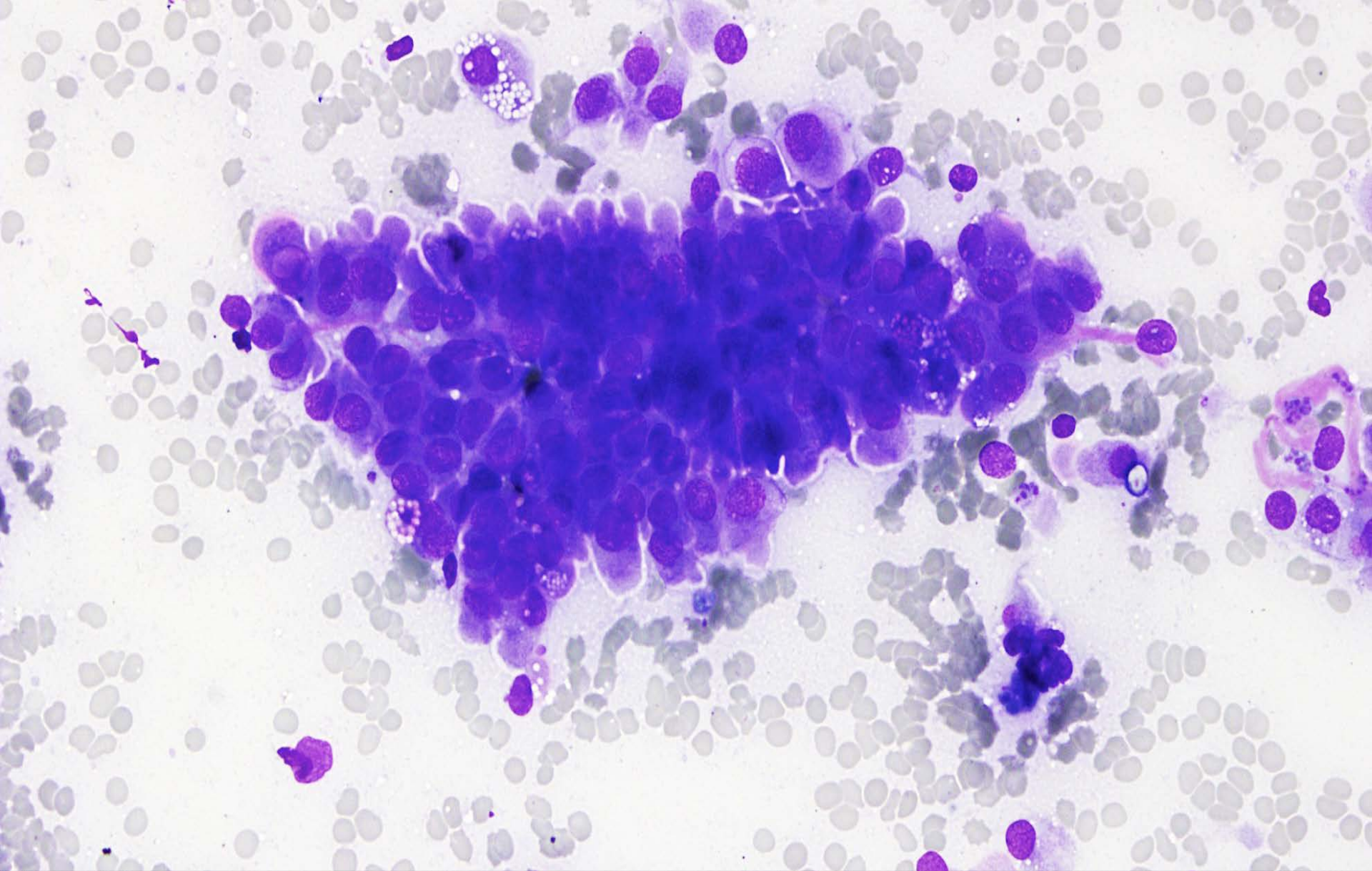


25. Ulusal Patoloji Kongresi

6. Sitopatoloji Kongresi

14 - 17 Ekim 2015 / Merinos AKKM - BURSA



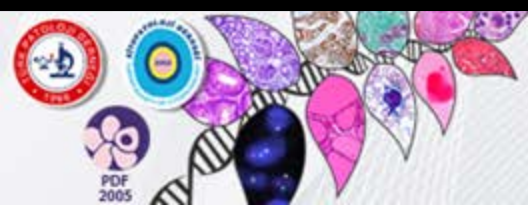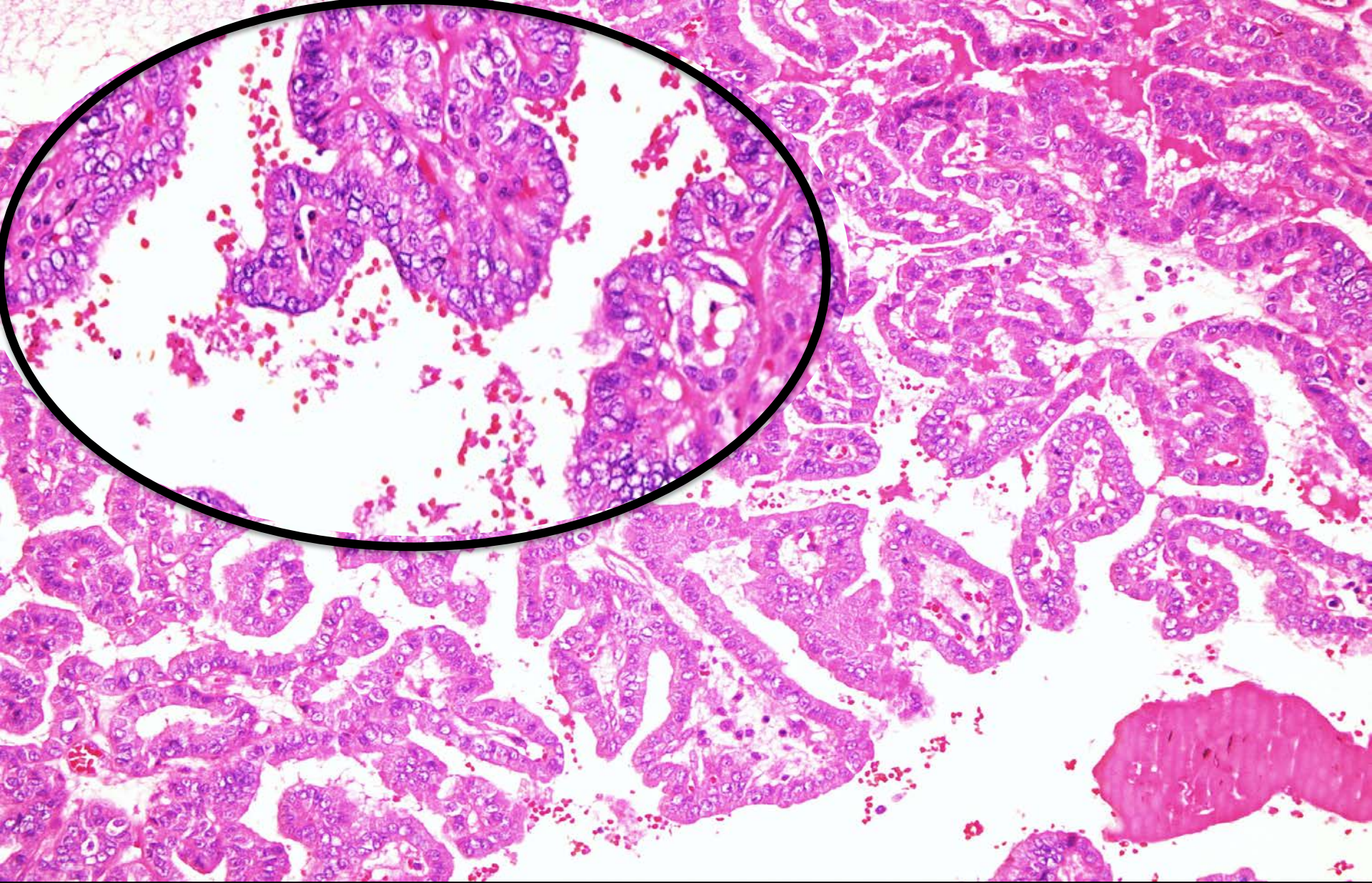


25. Ulusal Patoloji Kongresi

6. Sitopatoloji Kongresi

14 - 17 Ekim 2015 / Merinos AKKM - BURSA



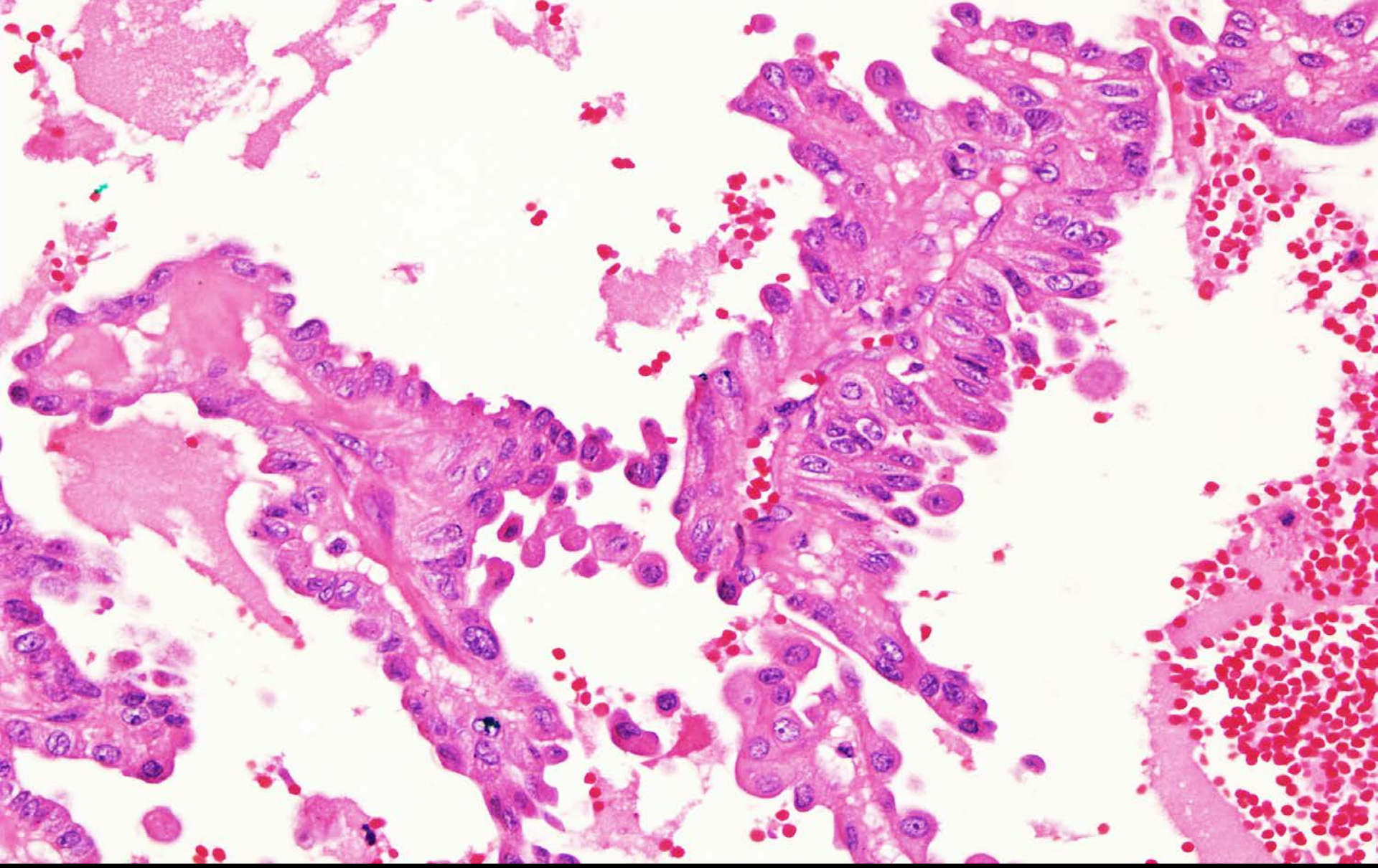


25. Ulusal Patoloji Kongresi

6. Sitopatoloji Kongresi

14 - 17 Ekim 2015 / Merinos AKKM - BURSA




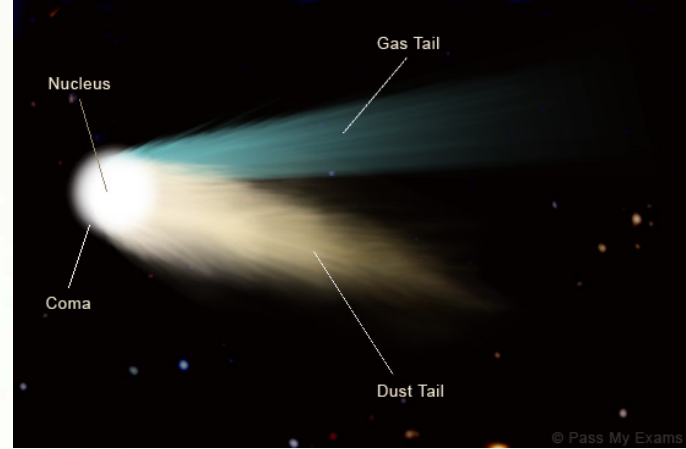
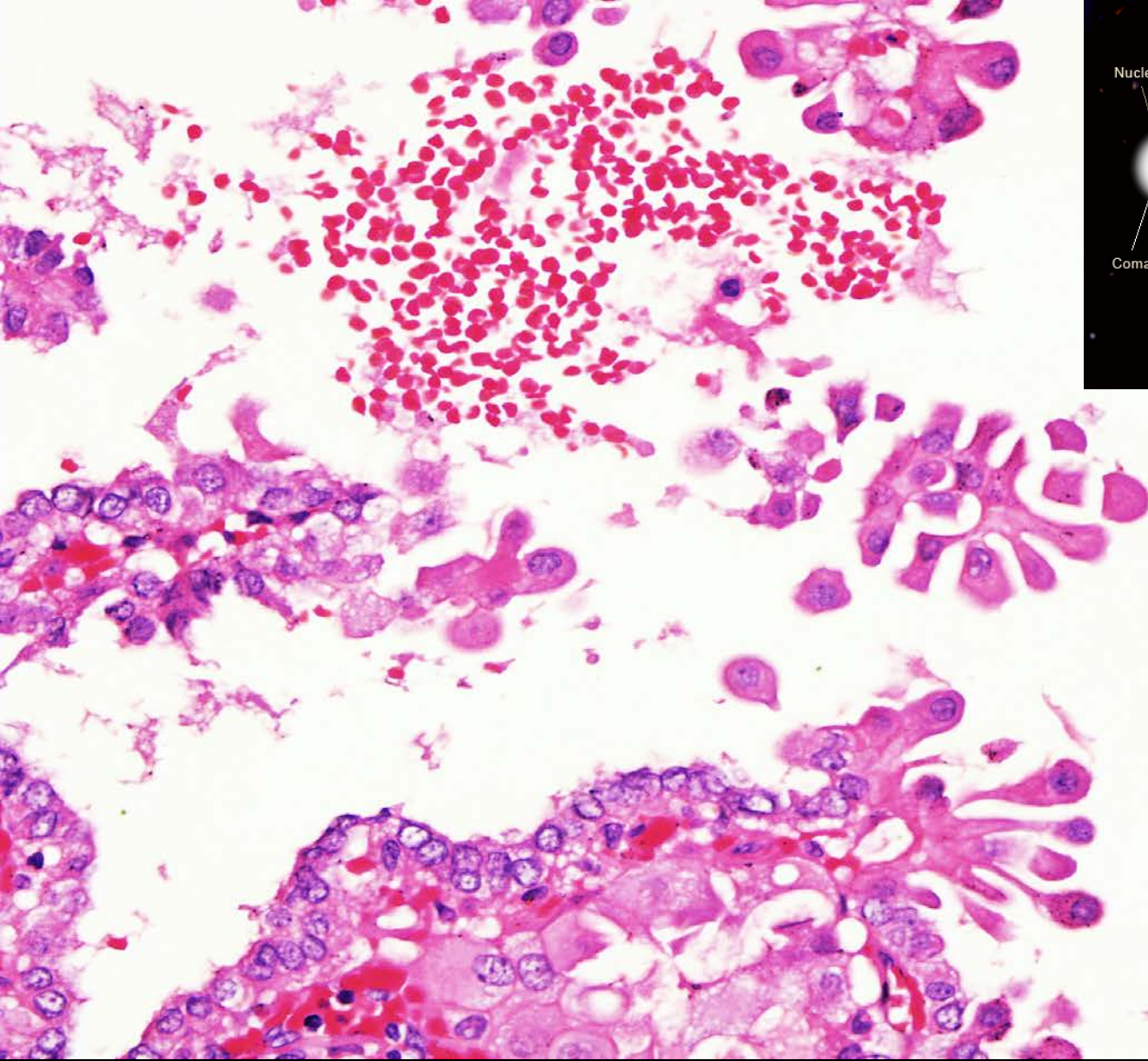


25. Ulusal Patoloji Kongresi

6. Sitopatoloji Kongresi

14 - 17 Ekim 2015 / Merinos AKKM - BURSA

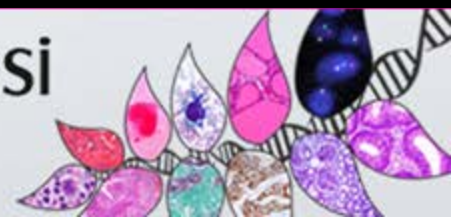



25. Ulusal Patoloji Kongresi

6. Sitopatoloji Kongresi

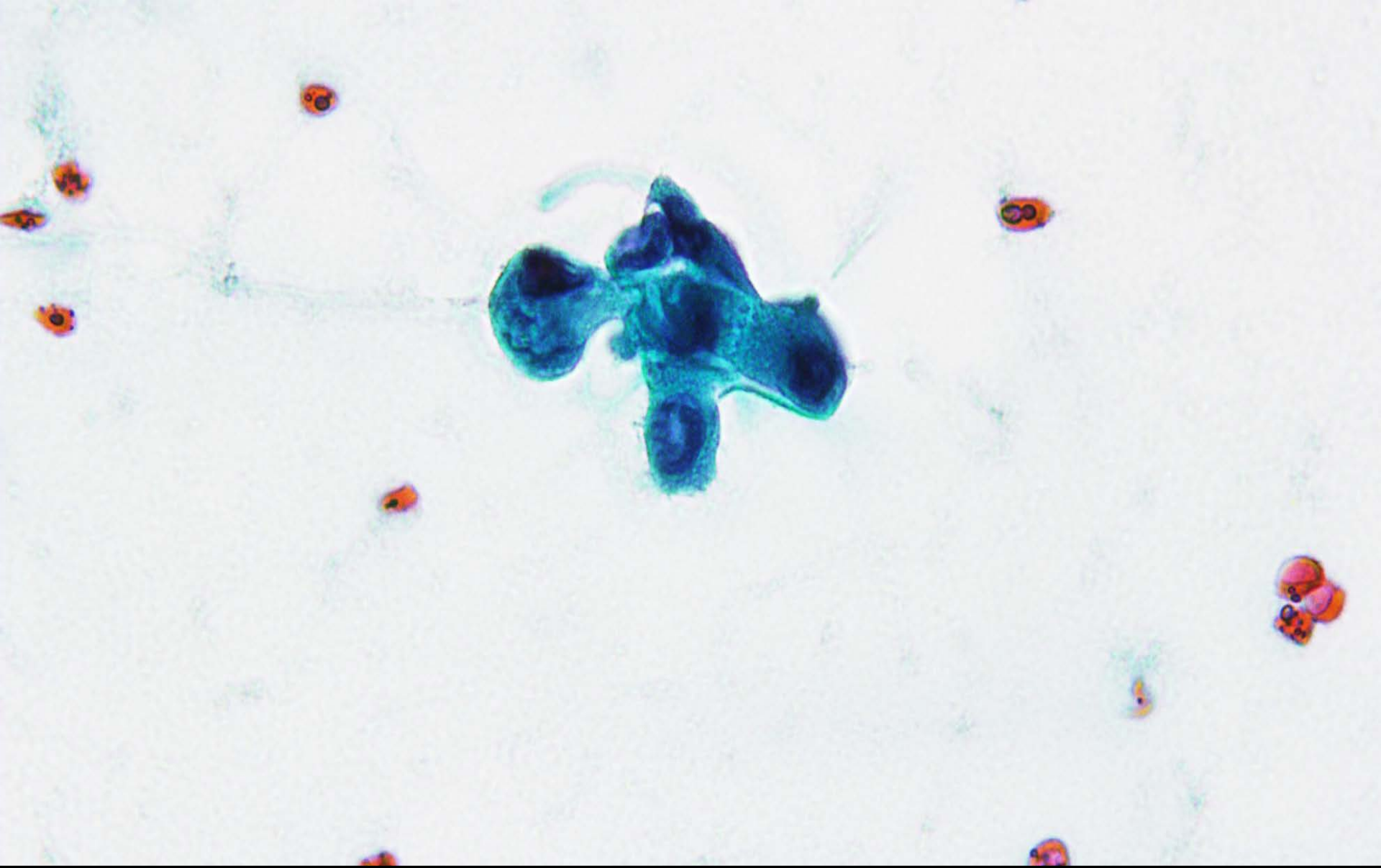
14 - 17 Ekim 2015 / Merinos AKKM - BURSA



Olgu 2

- ERKEK, 47 YAS
- BOYUN ORTA HAT, KISTIK OLUSUM, 2 CM



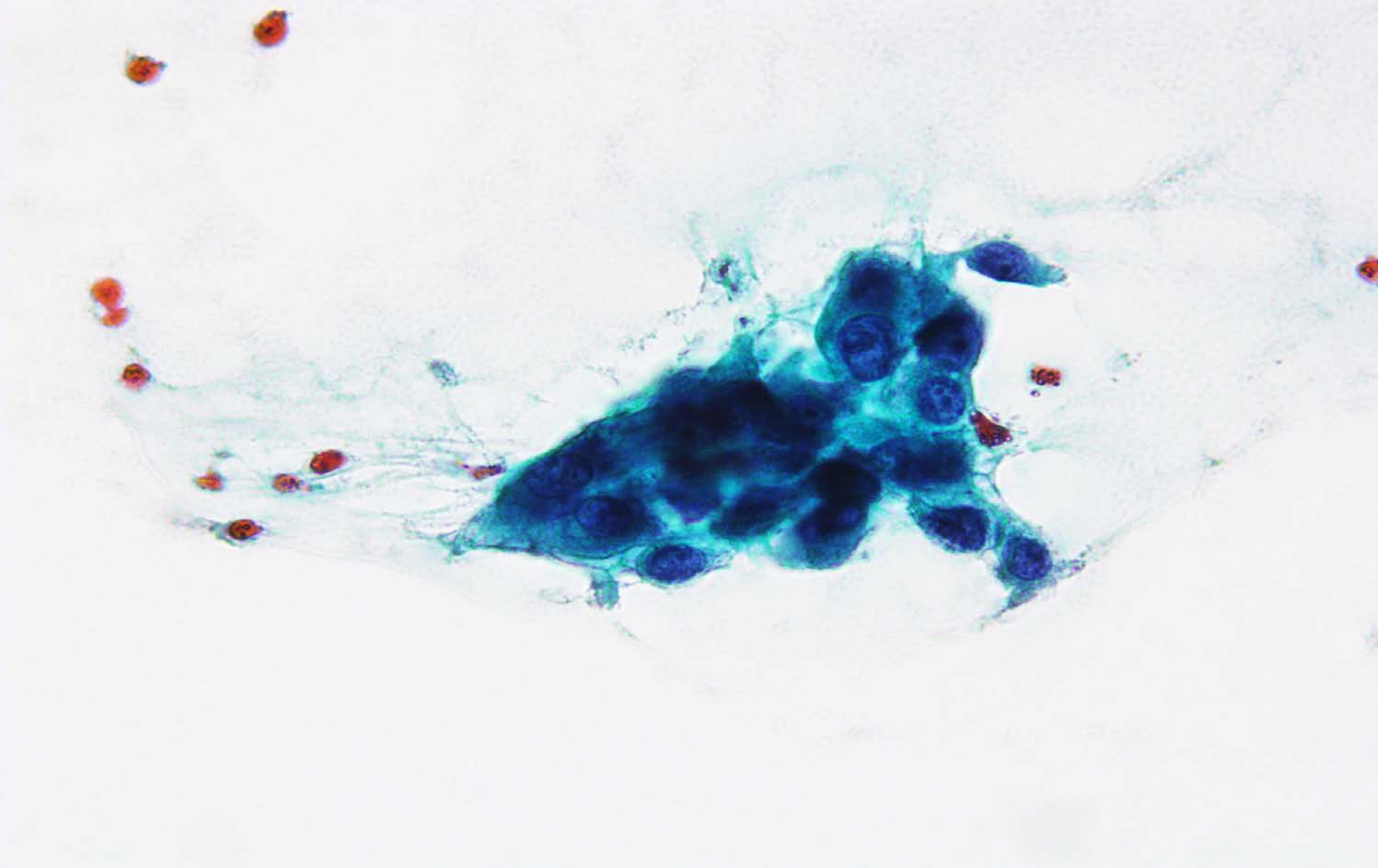


25. Ulusal Patoloji Kongresi

6. Sitopatoloji Kongresi

14 - 17 Ekim 2015 / Merinos AKKM - BURSA

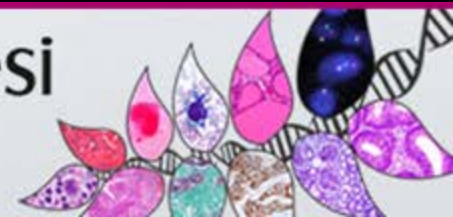

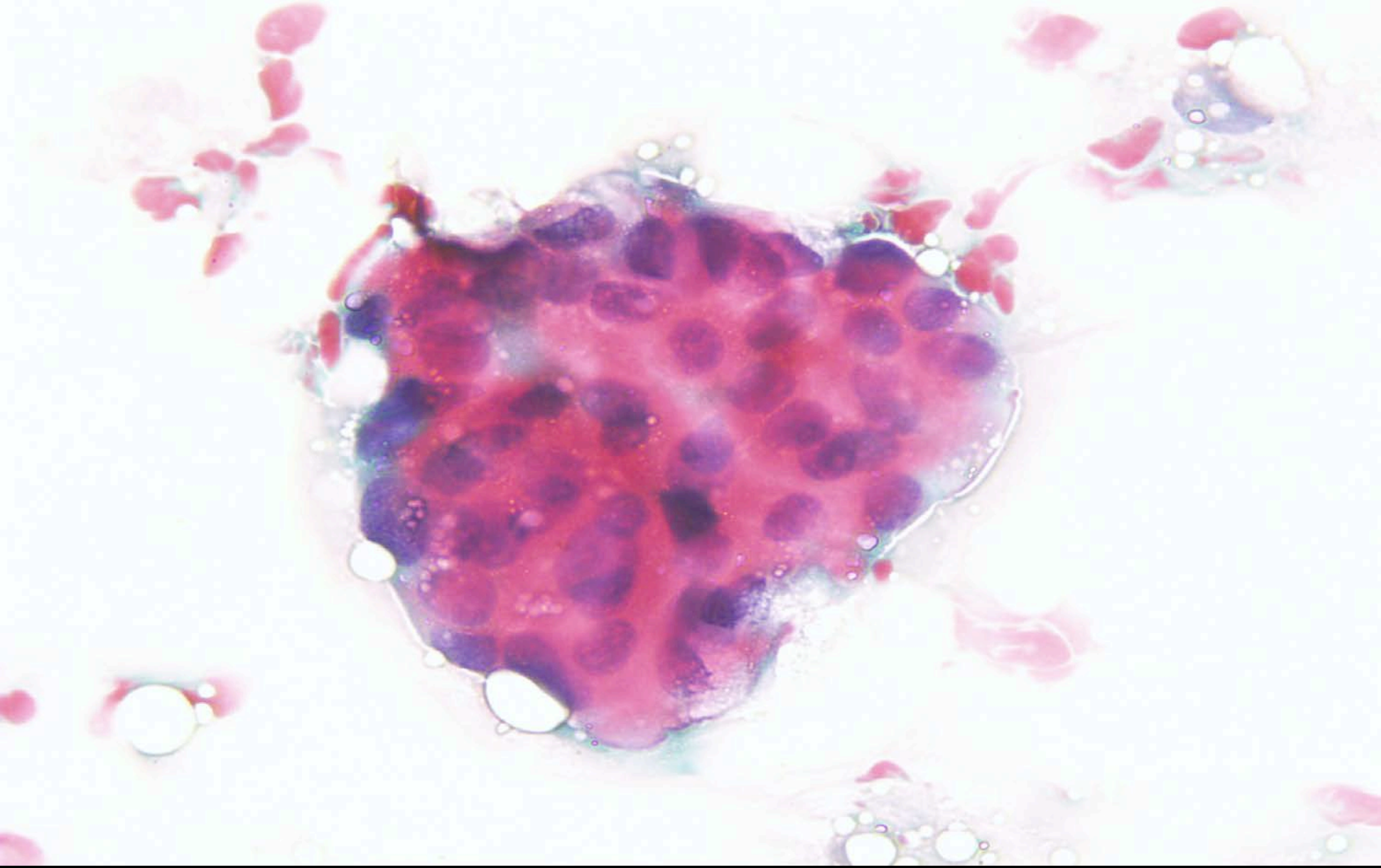


25. Ulusal Patoloji Kongresi

6. Sitopatoloji Kongresi

14 - 17 Ekim 2015 / Merinos AKKM - BURSA



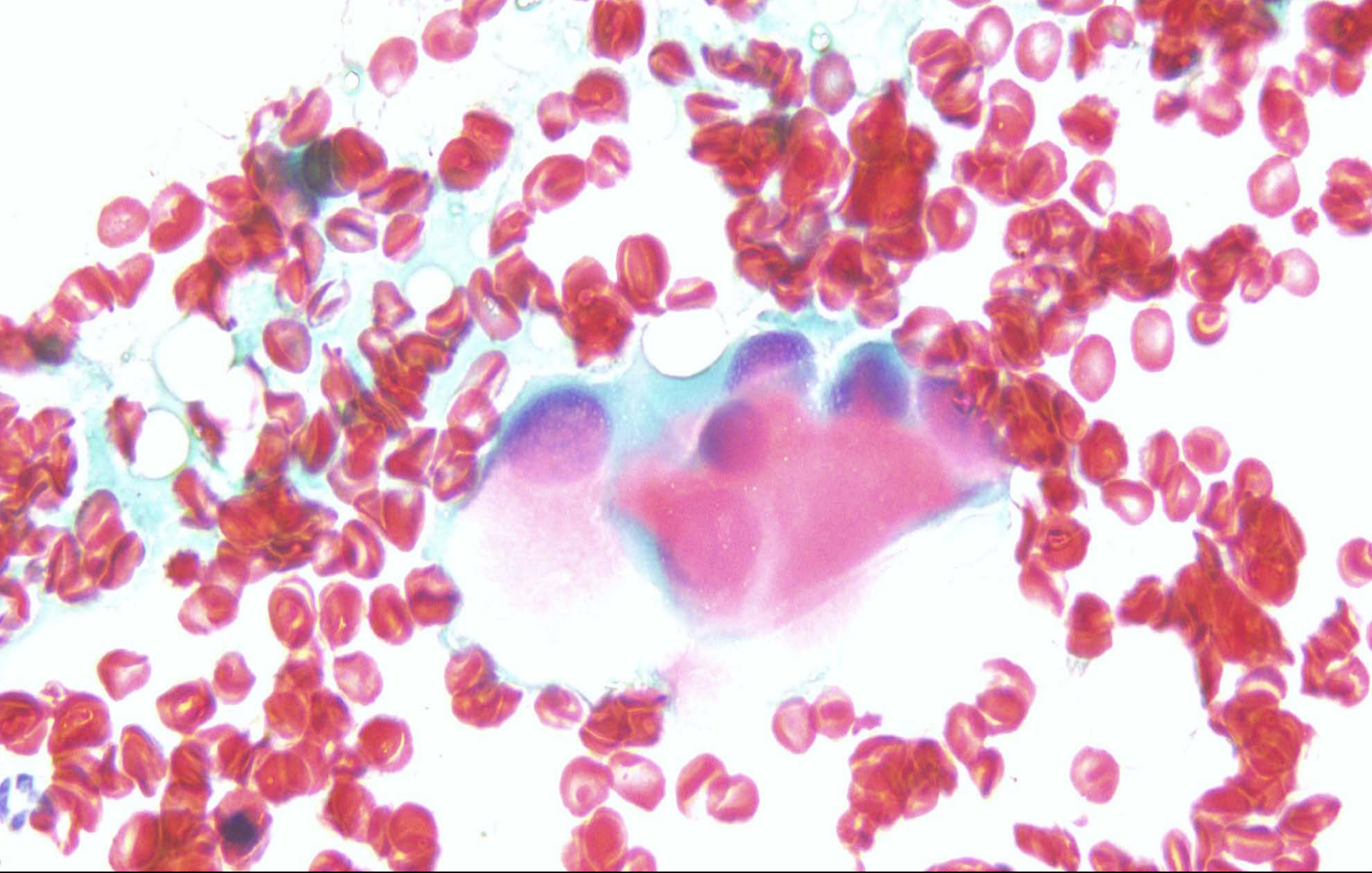


25. Ulusal Patoloji Kongresi

6. Sitopatoloji Kongresi

14 - 17 Ekim 2015 / Merinos AKKM - BURSA



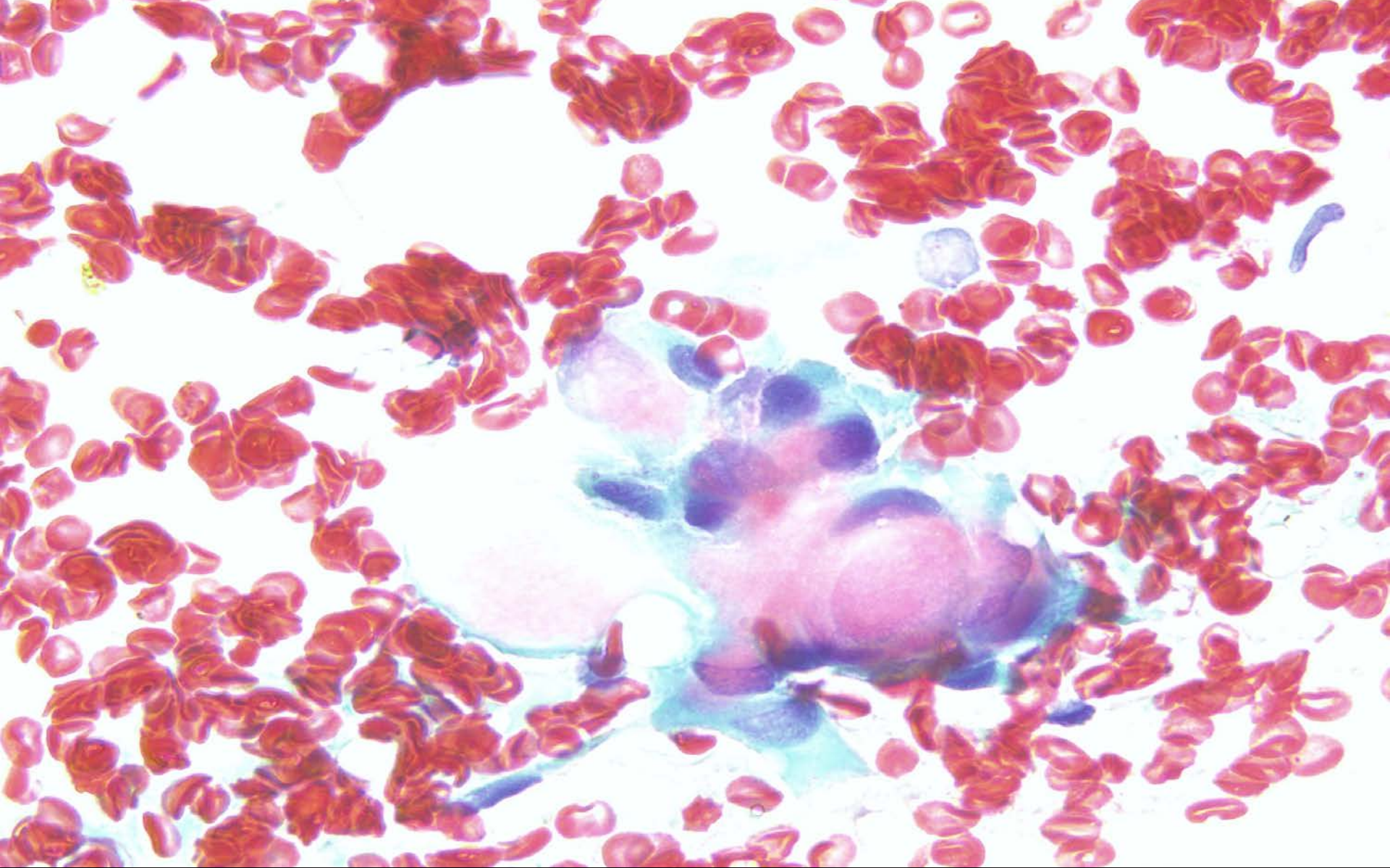


25. Ulusal Patoloji Kongresi

6. Sitopatoloji Kongresi

14 - 17 Ekim 2015 / Merinos AKKM - BURSA



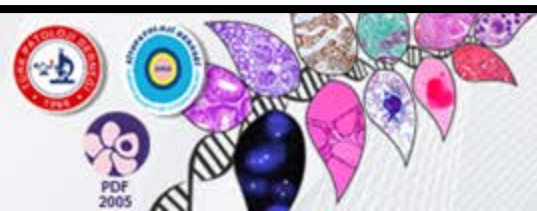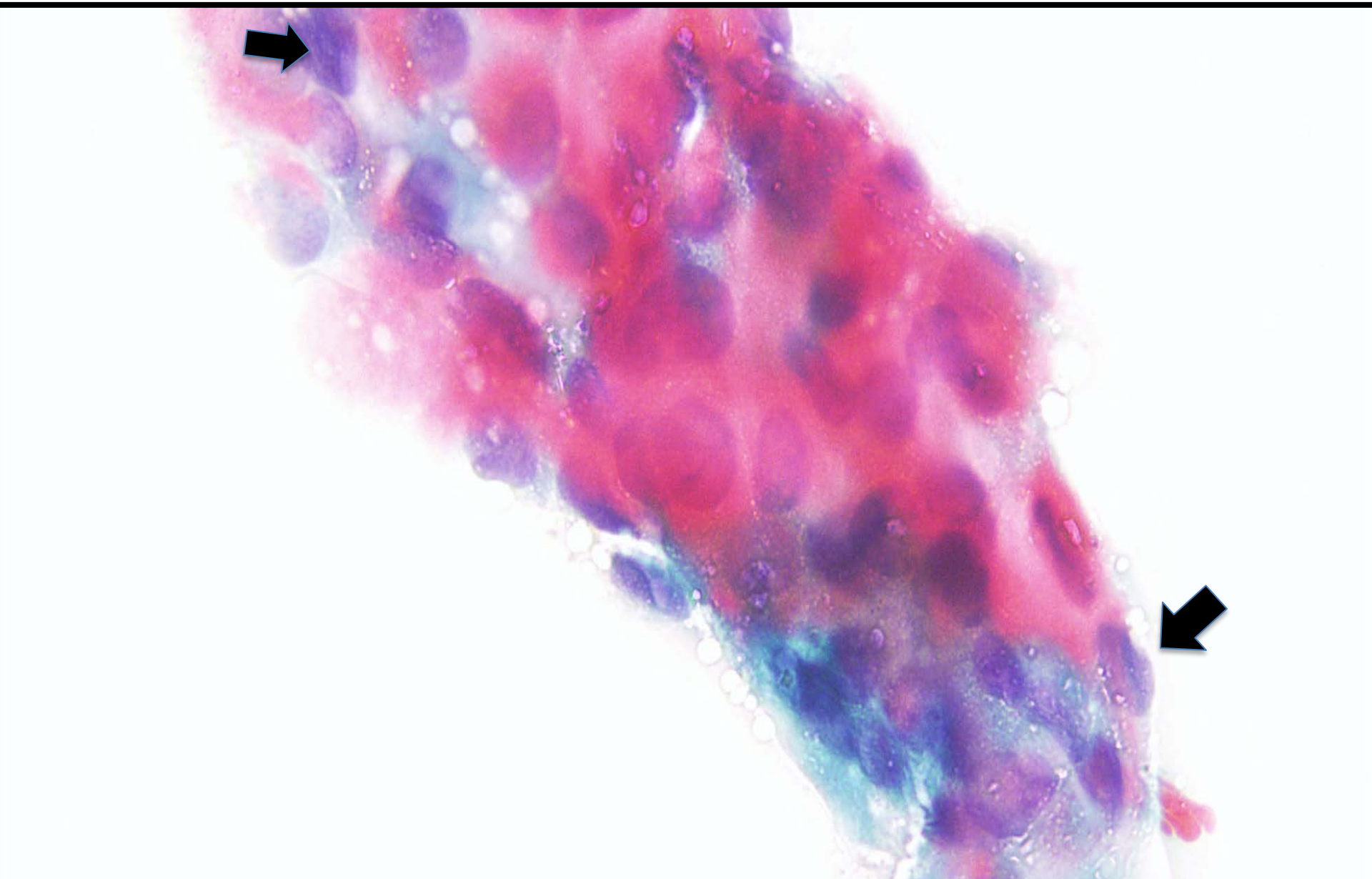


25. Ulusal Patoloji Kongresi

6. Sitopatoloji Kongresi

14 - 17 Ekim 2015 / Merinos AKKM - BURSA

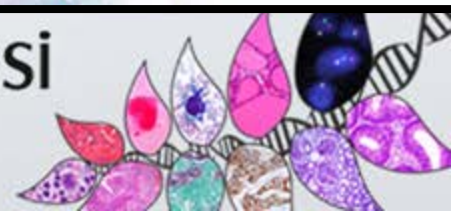

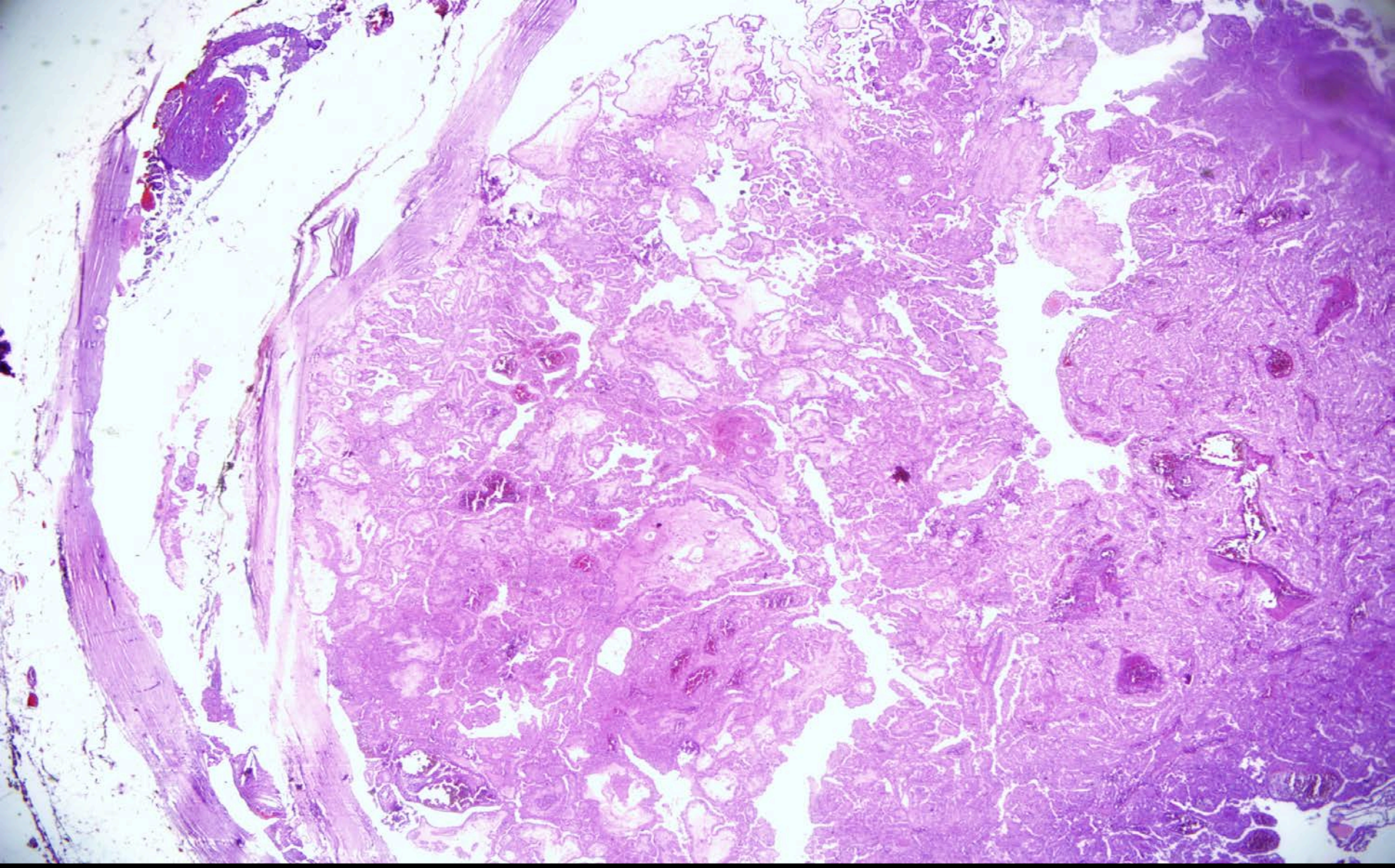


25. Ulusal Patoloji Kongresi

6. Sitopatoloji Kongresi

14 - 17 Ekim 2015 / Merinos AKKM - BURSA



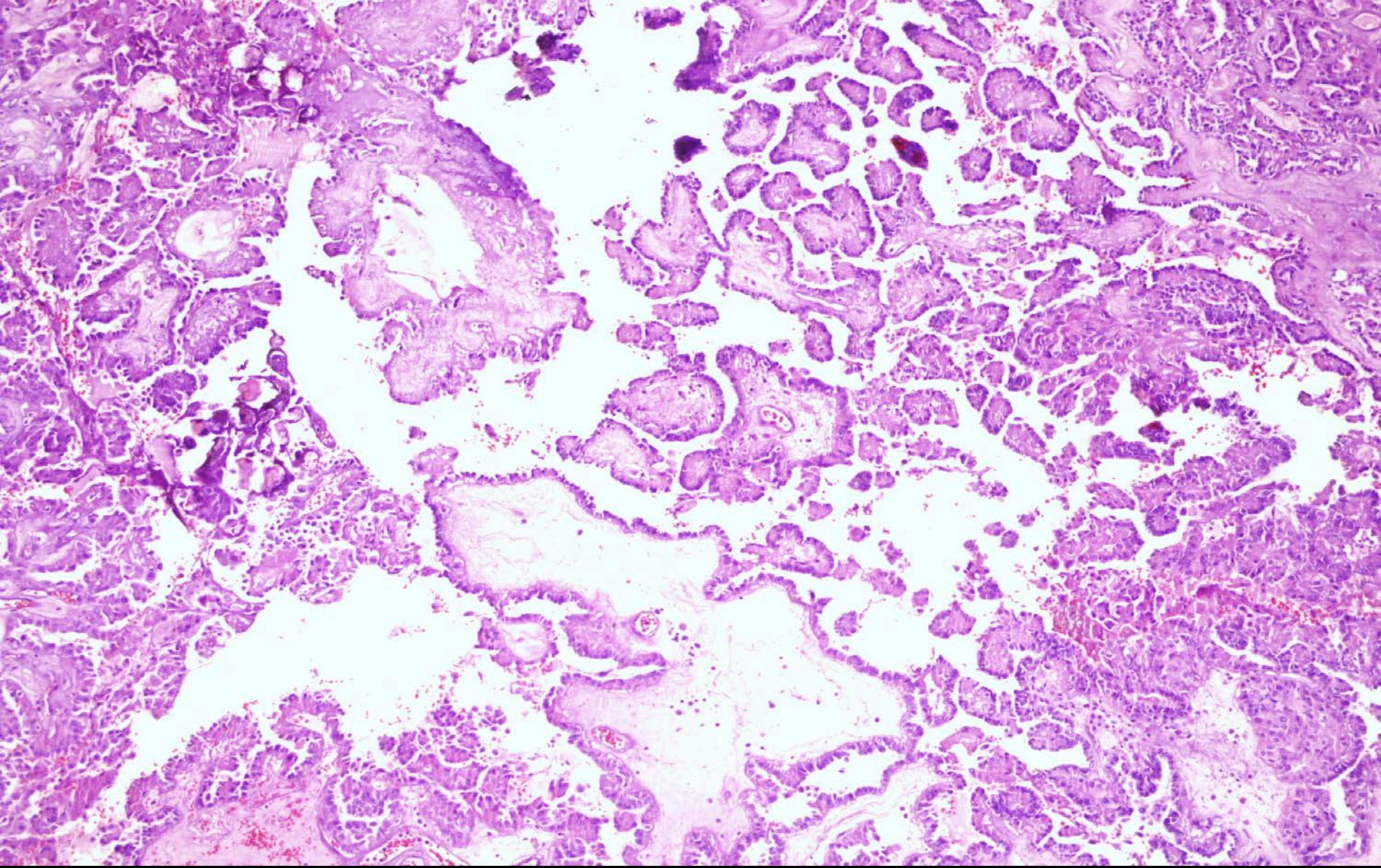


25. Ulusal Patoloji Kongresi

6. Sitopatoloji Kongresi

14 - 17 Ekim 2015 / Merinos AKKM - BURSA





25. Ulusal Patoloji Kongresi

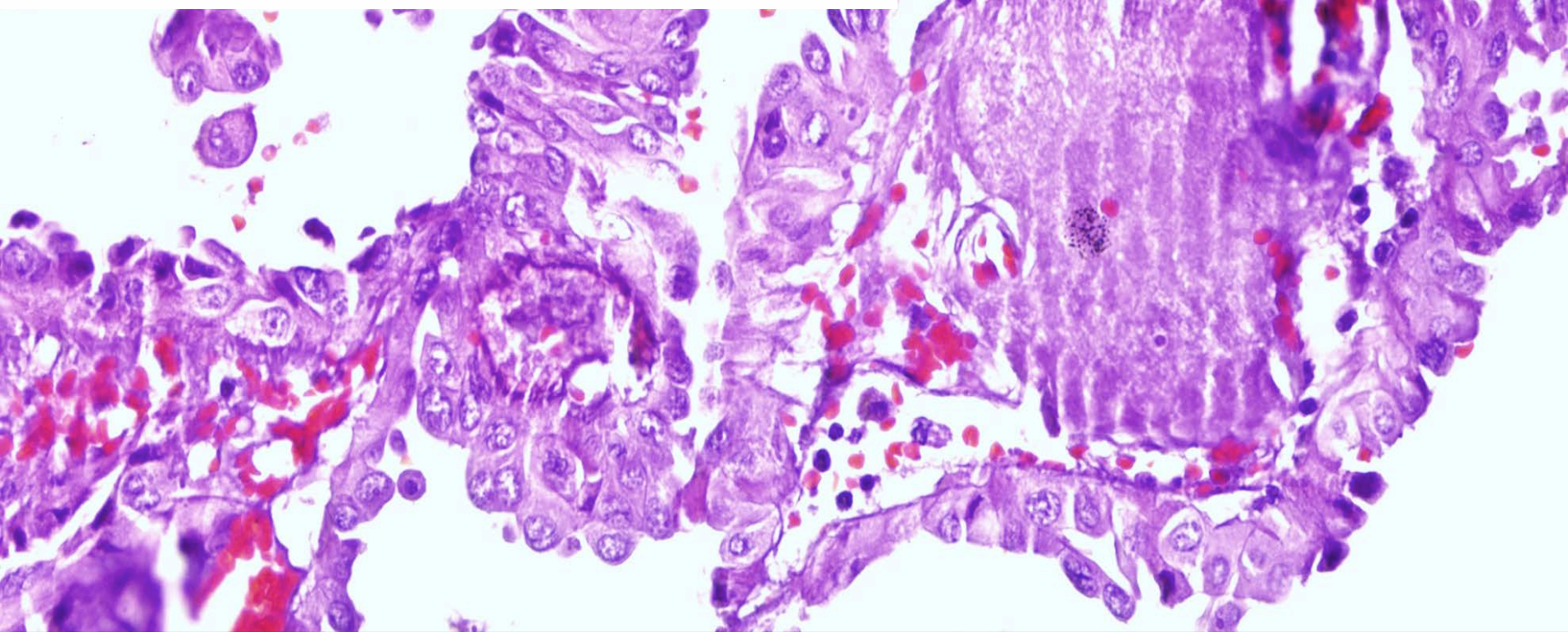
6. Sitopatoloji Kongresi

14 - 17 Ekim 2015 / Merinos AKKM - BURSA



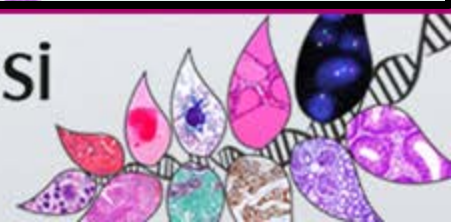Pathology of Thyroglossal Duct: an Institutional Experience

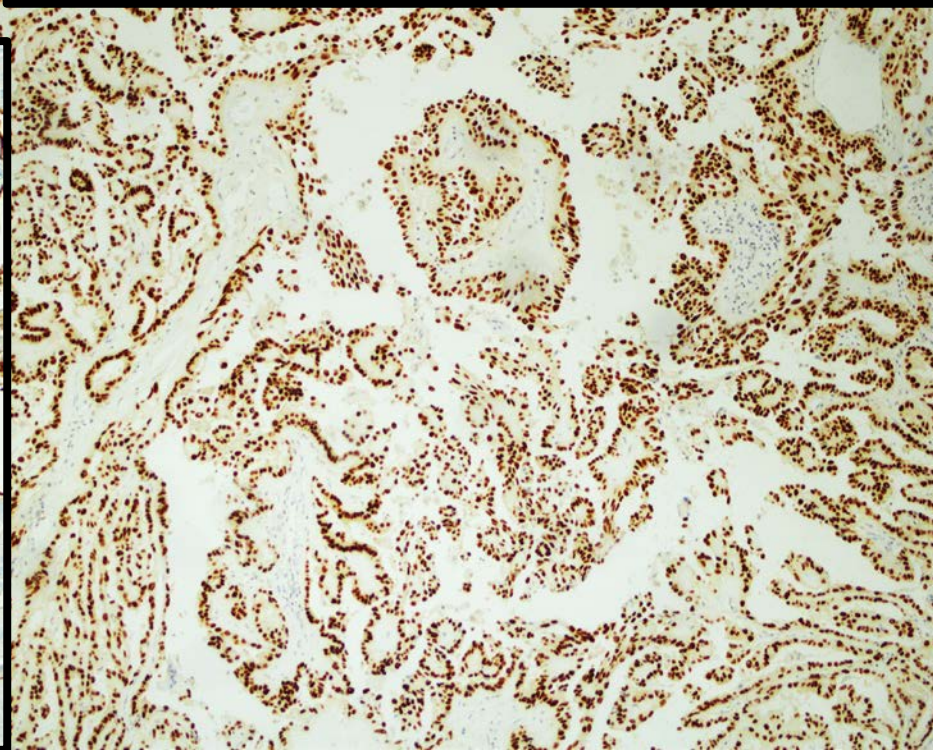
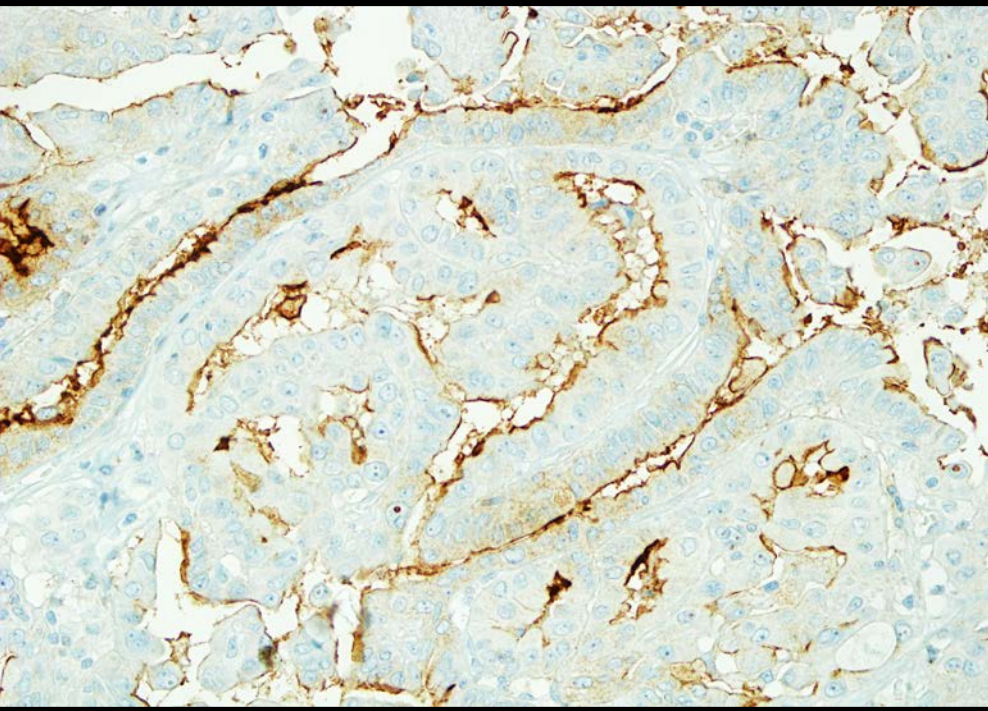
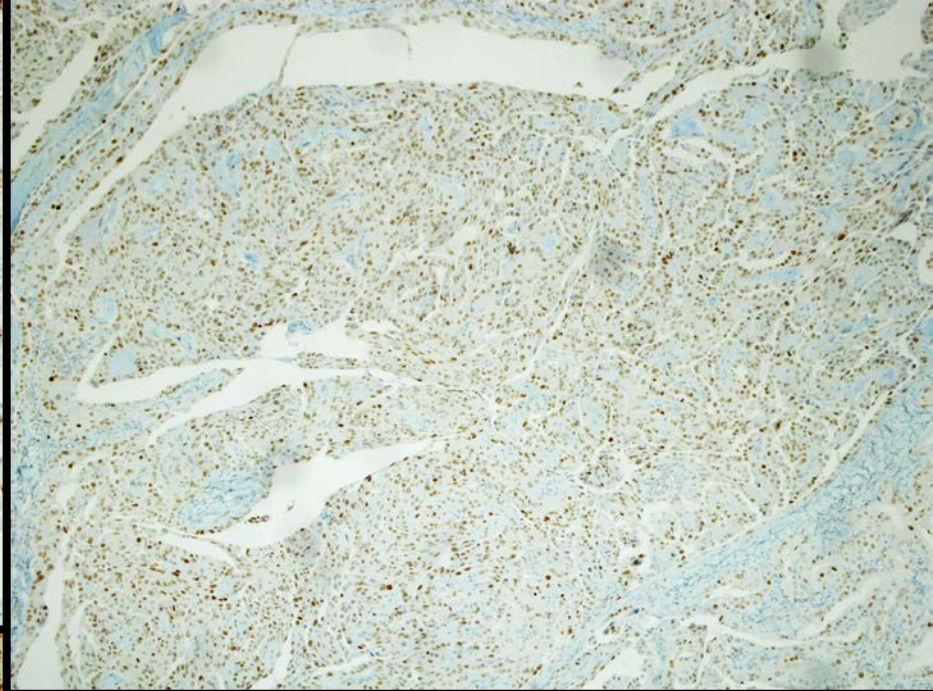
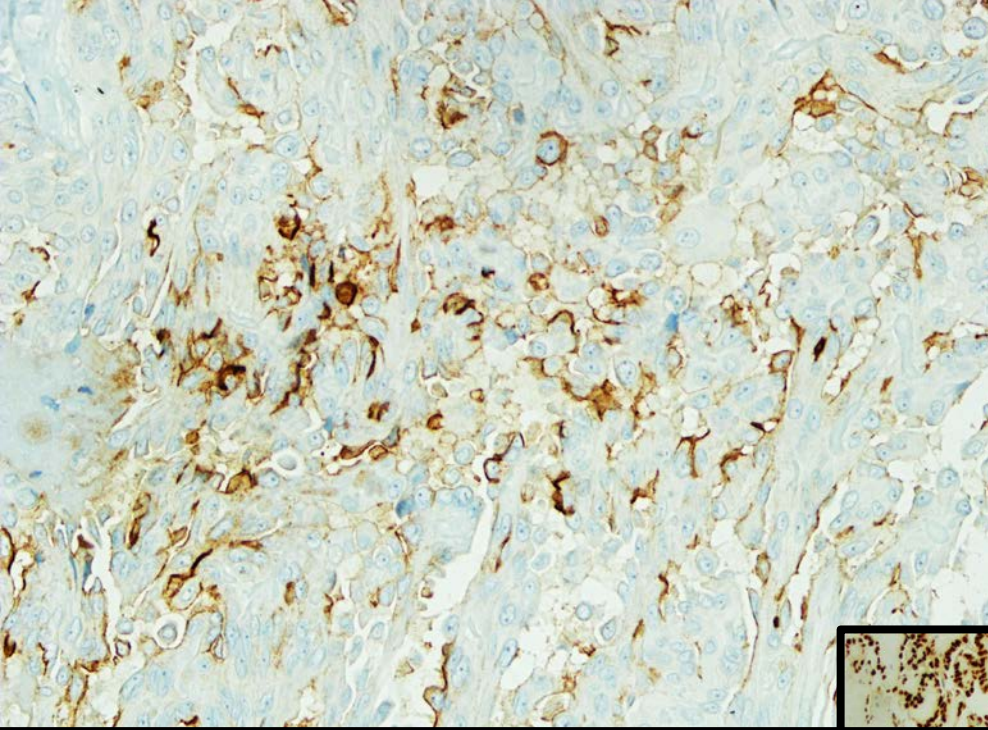
Shuanzeng Wei · Virginia A. LiVohi · Zubair W. Baloch



25 Ulusal Patoloji Kongresi
6 Sitopatoloji Kongresi

14 - 17 Ekim 2015 / Merinos AKKM - BURSA





Sunumumda emegi gecen;

- DR. PEMBEGUL GUNES
- DR. MURAT ERKAN
- DR. KEMAL BEHZATOGLU



25. Ulusal Patoloji Kongresi
6. Sitopatoloji Kongresi

14 - 17 Ekim 2015 / Merinos AKKM - BURSA



TESEKKUR EDERİM



25. Ulusal Patoloji Kongresi
6. Sitopatoloji Kongresi

14 - 17 Ekim 2015 / Merinos AKKM - BURSA

