



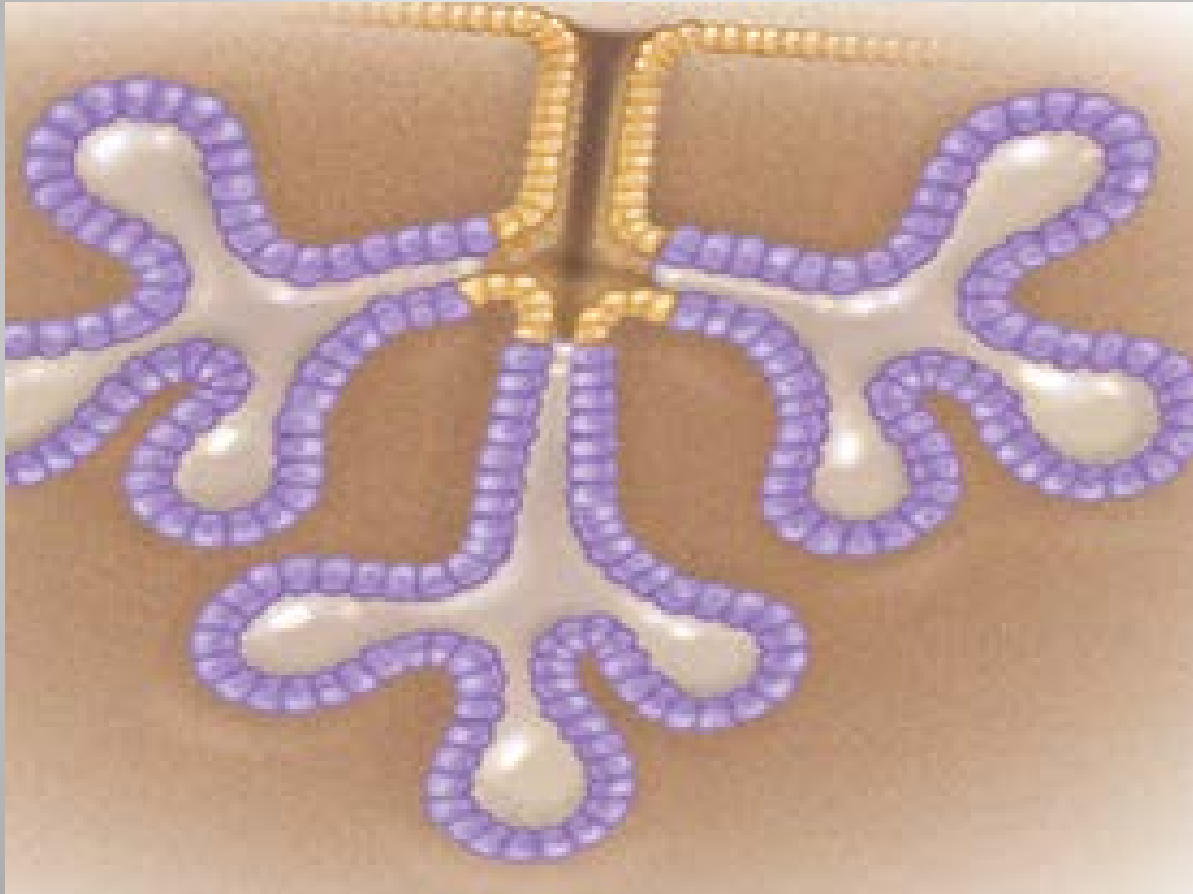
# Tkrk Bezi Tmrlerinde Muhtemel Prekrsr Lezyonlar

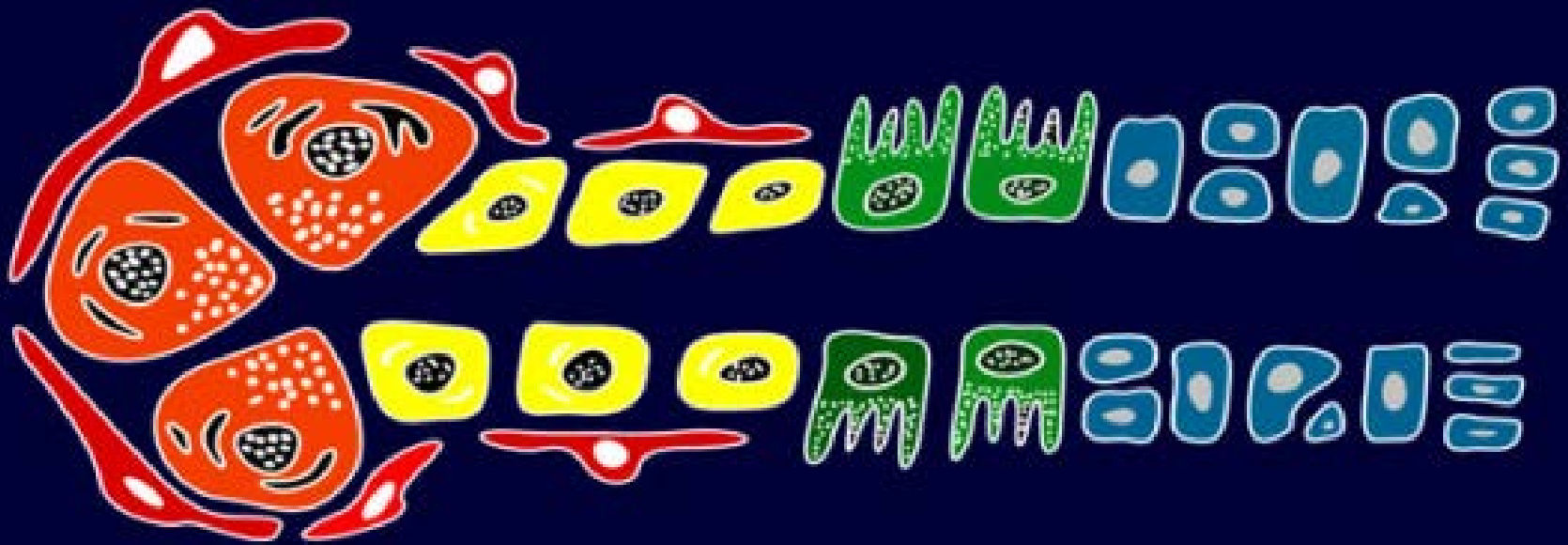
Dr. Melih KILIN, Dr. mer GNHAN,  
Dr. Serkan AKSOY, Dr. Ali Fuat IEK  
GATA TIBBİ PATOLOJİ AD

# Sunum Planı

- Giriş (Tükürük Bezi Tümörleri)
- Materyal ve Metod
- Sonuçlar
- Tartışma

# Pankreas ve Meme





Acinic cell Ca

Basaloid Tumors

Warthin's

Mucoepidermoid

Adenoid Cystic Ca

Oncocytic

Salivary Duct Ca

PLGA

Tumors

Adenocarcinoma

Myoepithelial Ca

Epi-myoepithelial Ca

Pleomorphic adenoma

# Tükürük Bezi Tümörleri 1/3

Rosai And Ackerman's Surgical Pathology 10th Edition

- **Stromal Metaplazi Gösterenler**  
(Pleomorfik Adenoma, Malign Mikst Tümör)
- **Oksifilik (Onkositik) Değişiklik Gösterenler**  
(Oksifilik adenoma [Onkositoma], oksifilik karsinoma, Whartin Tumor)
- **Monomorfik Adenoma**  
(Bazal Hücreli Adenoma ve Adenokarsinoma)

# Tükürük Bezi Tümörleri 2/3

Rosai And Ackerman's Surgical Pathology 10th Edition

- **Sebaseöz Diferansiasyon Gösterenler**

(Whartin Tümör, Pleomorfik Adenoma, Mukoepidermoid Karsinoma, Adenoid Kistik Karsinoma)

- **Miyoepitelyal Diferansiasyon Gösterenler**

Pleomorfik Adenoma, Adenoid Kistik Karsinoma, Terminal Duktus Karsinomu

# Tükürük Bezi Tümörleri 3/3

Rosai And Ackerman's Surgical Pathology 10th Edition

- **Şeffaf Hücreli Değişiklik Gösterenler**

(Miyoepitelyoma, Asinik Hücreli Karsinoma, Mukoepidermoid Karsinoma)

- **Duktus tümörleri**

(Duktal Papilloma ve Karsinoma)

- Papiller Adenokarsinoma, Skuamöz Hücreli Karsinoma, Küçük Hücreli Karsinoma, Lenfoepitelyoma Benzeri Karsinoma, Diğer Primer Karsinomalar

# Prekürsör???

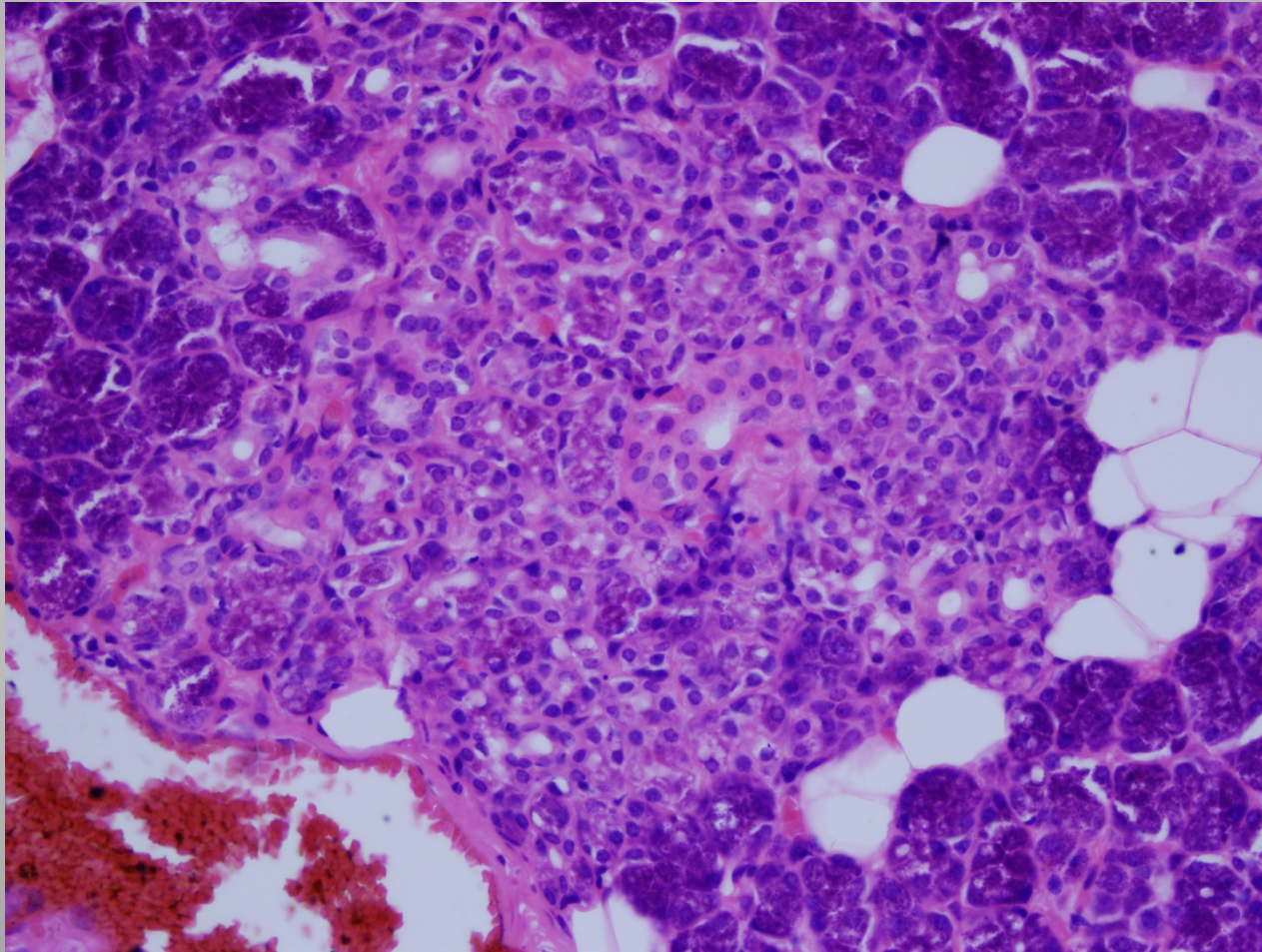
- Metaplaziler
- Hiperplaziler
- Kronik inflamatuvar süreçler
- Radyasyon
- .....
- Ne fayda sağlar?



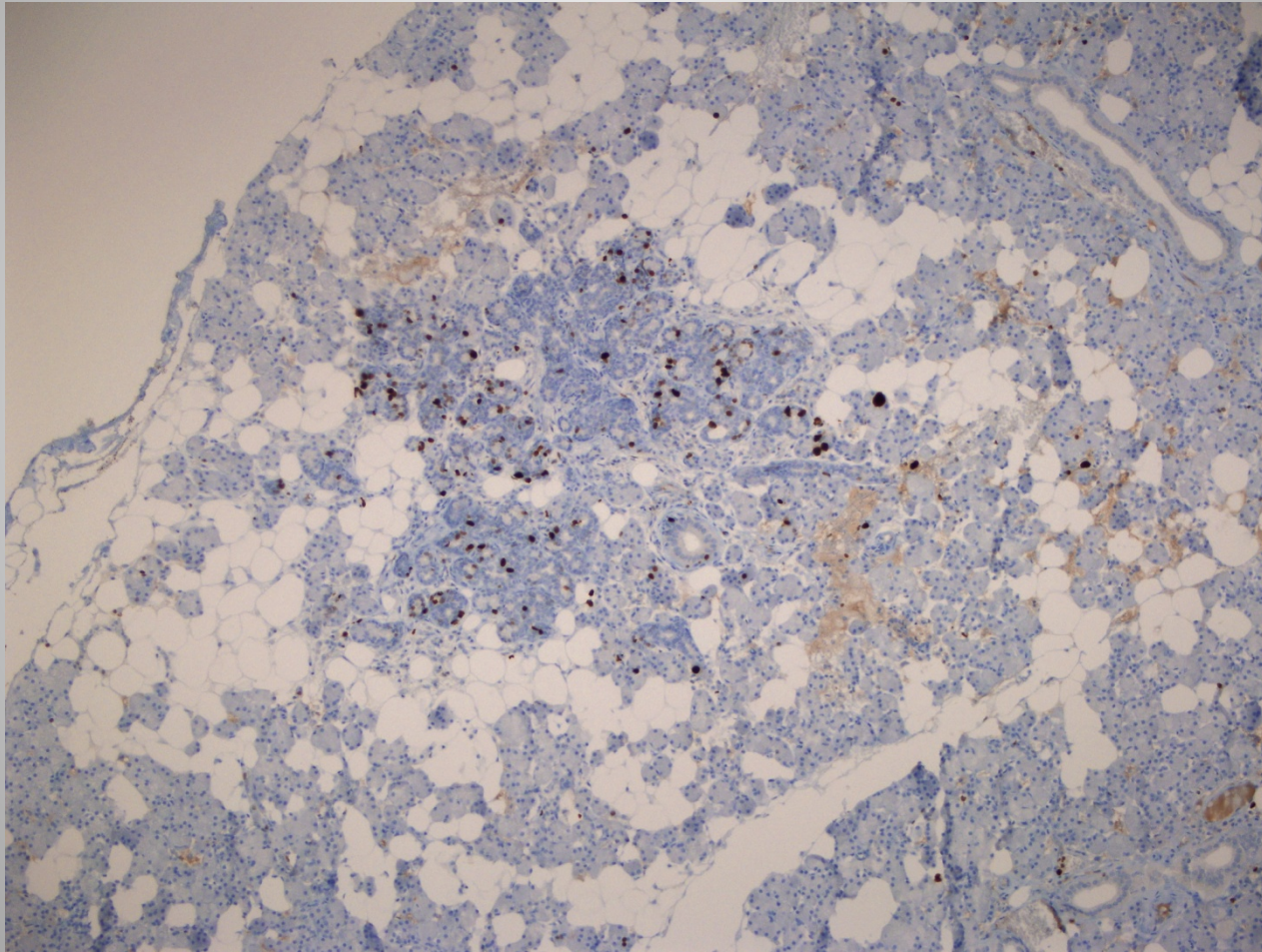
# Materyal ve Metod

- Gata Patoloji AD.
- Herhangi bir sebeple eksize edilmiş 166 tükürük bezi örneği geriye dönük tarandı.
- 18 tanesinde muhtemel bir prekürsör lezyon

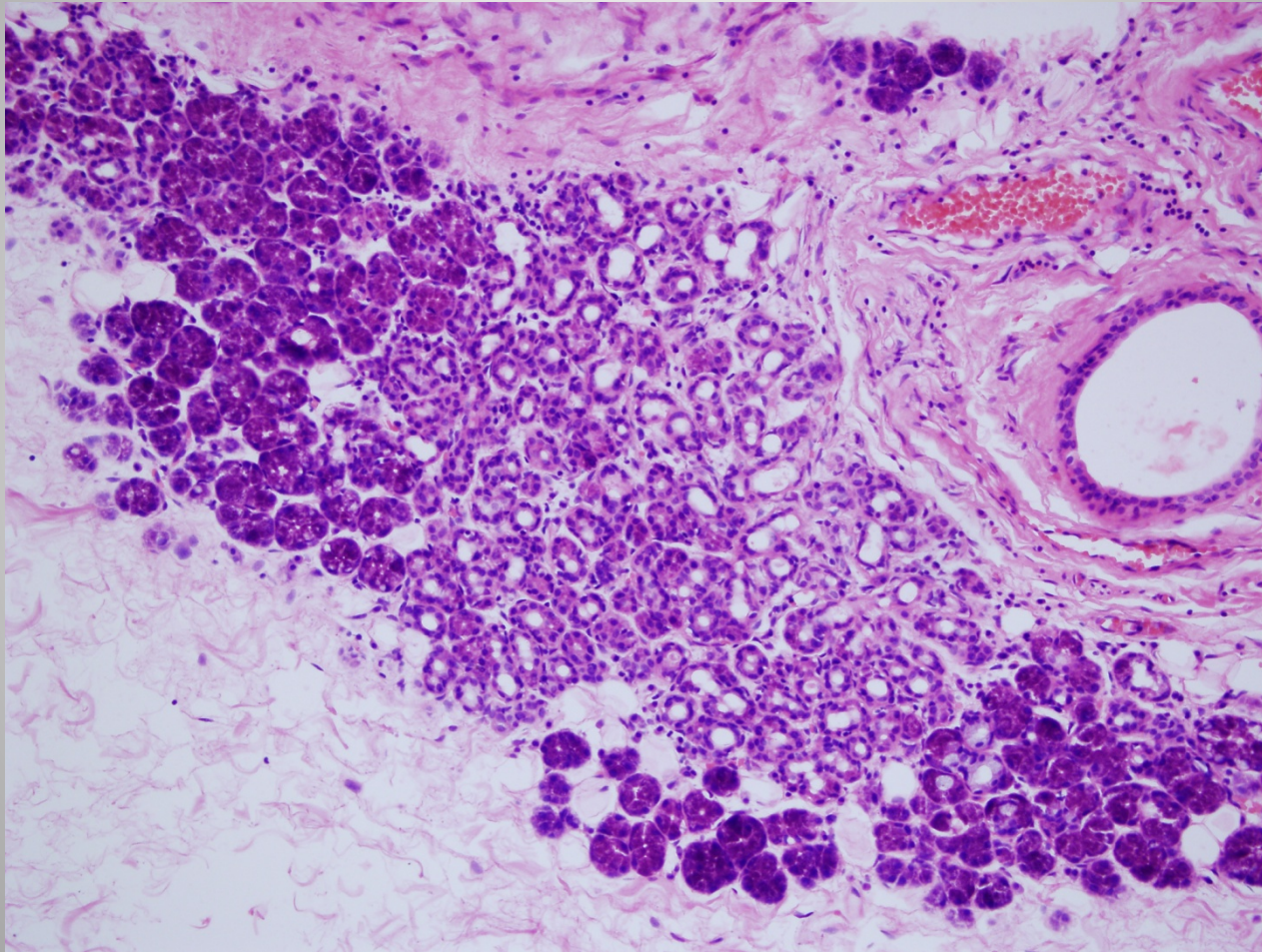
# Asiner Adenozis



# Ki-67

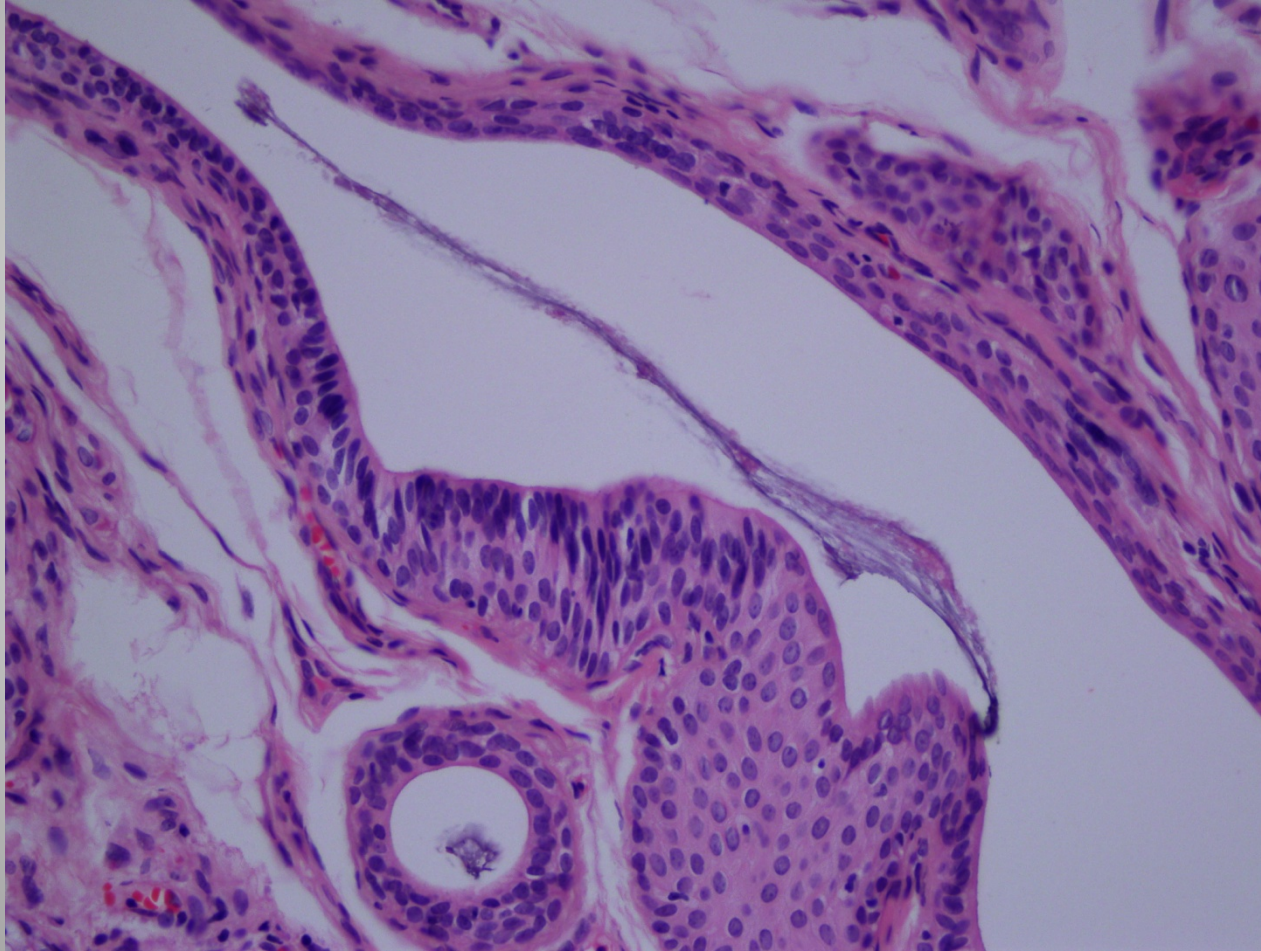


# “Intercalated” Duktus Adenozisi

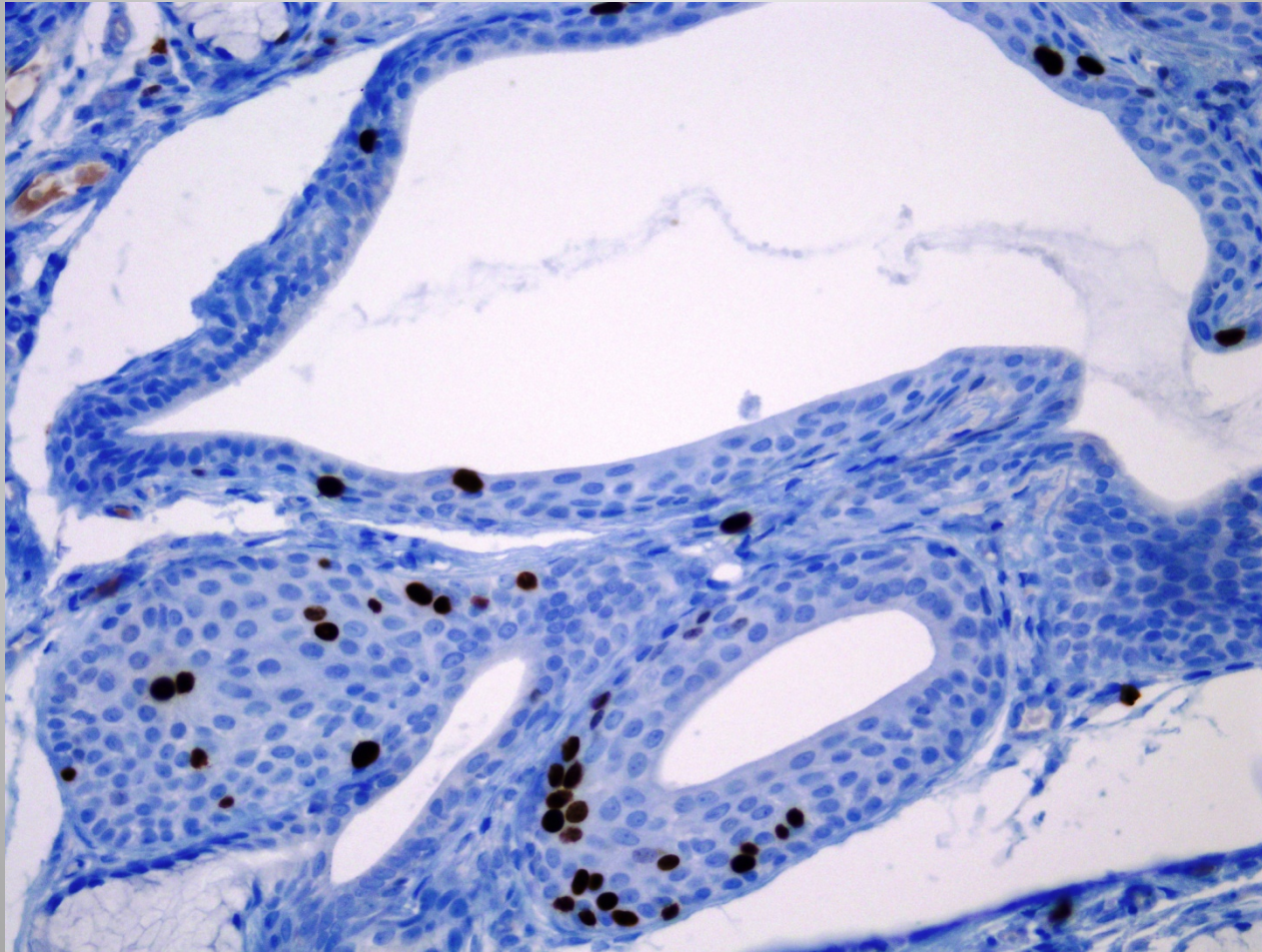


Intercalated Duct Lesions of Salivary Gland A Morphologic Spectrum From Hyperplasia to Adenoma: Am J Surg Pathol 2009;33:1322–1329 Ilan Weinreb, Raja R. Seethala, Jennifer L. Hunt, Runjan Chetty, Irving Dardick and Bayardo Perez-Ordóñez

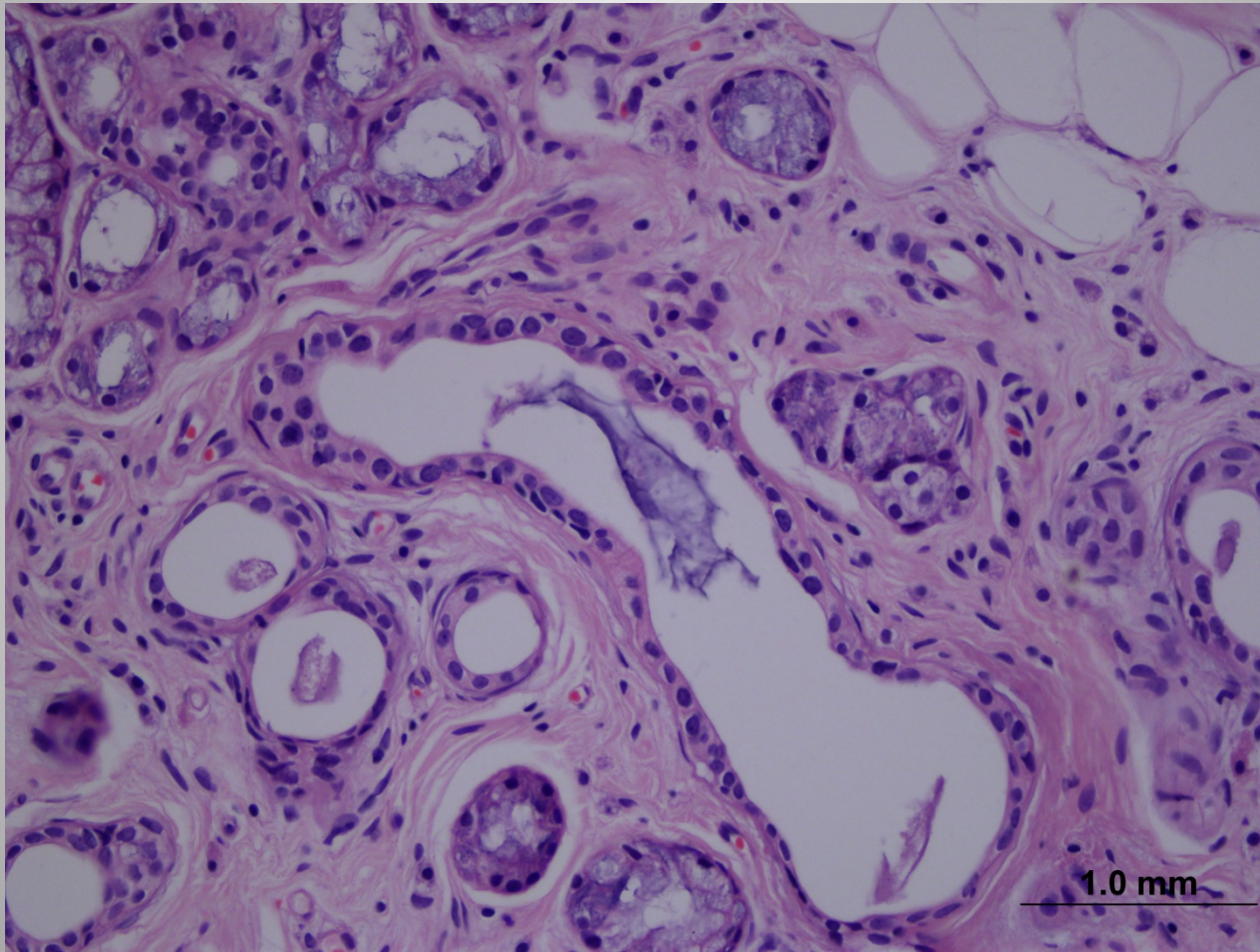
# Skvamöz Metaplazi ve Kolumnar Değişiklik



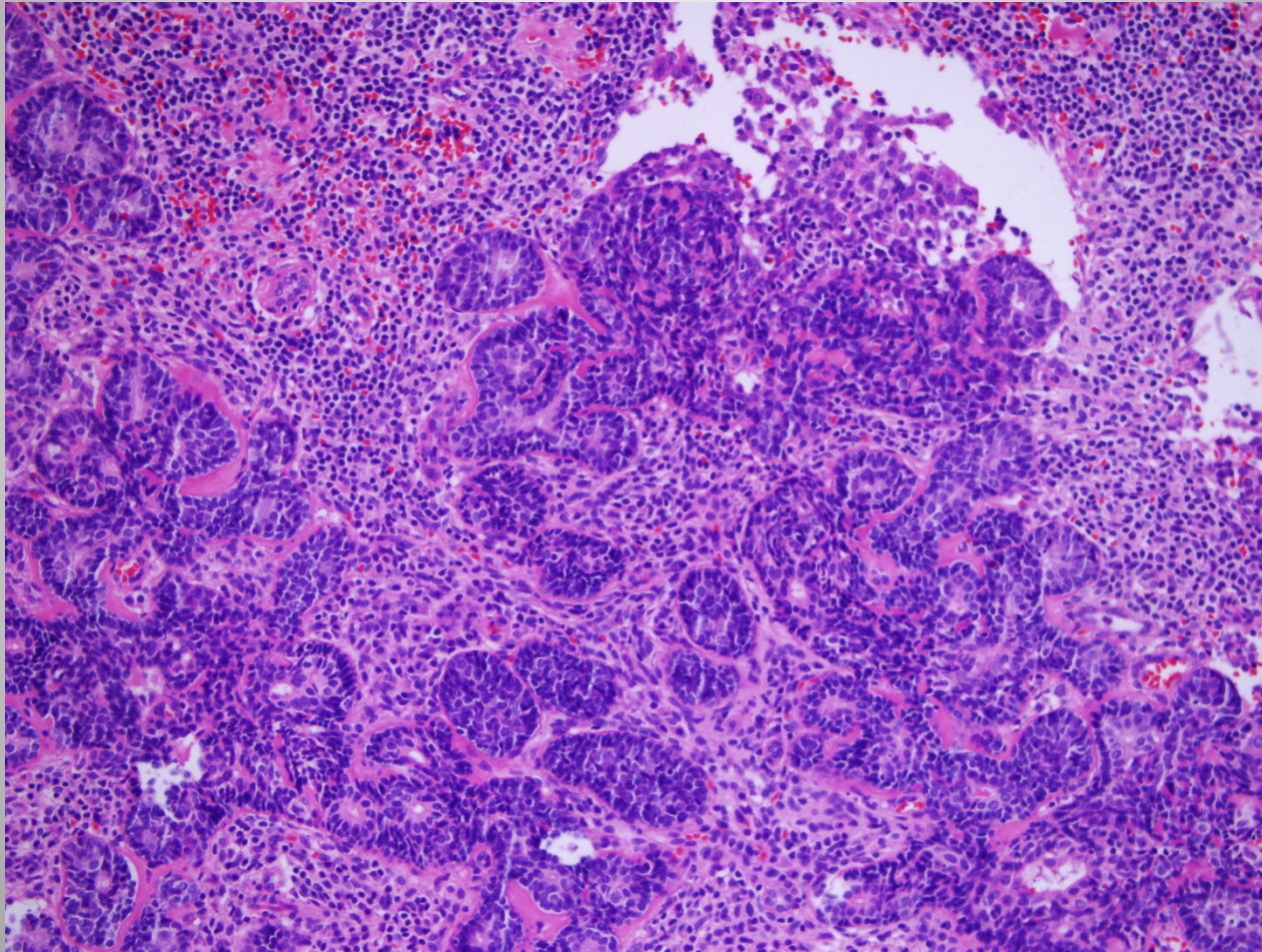
# Ki-67



# Sitolojik Atipiler

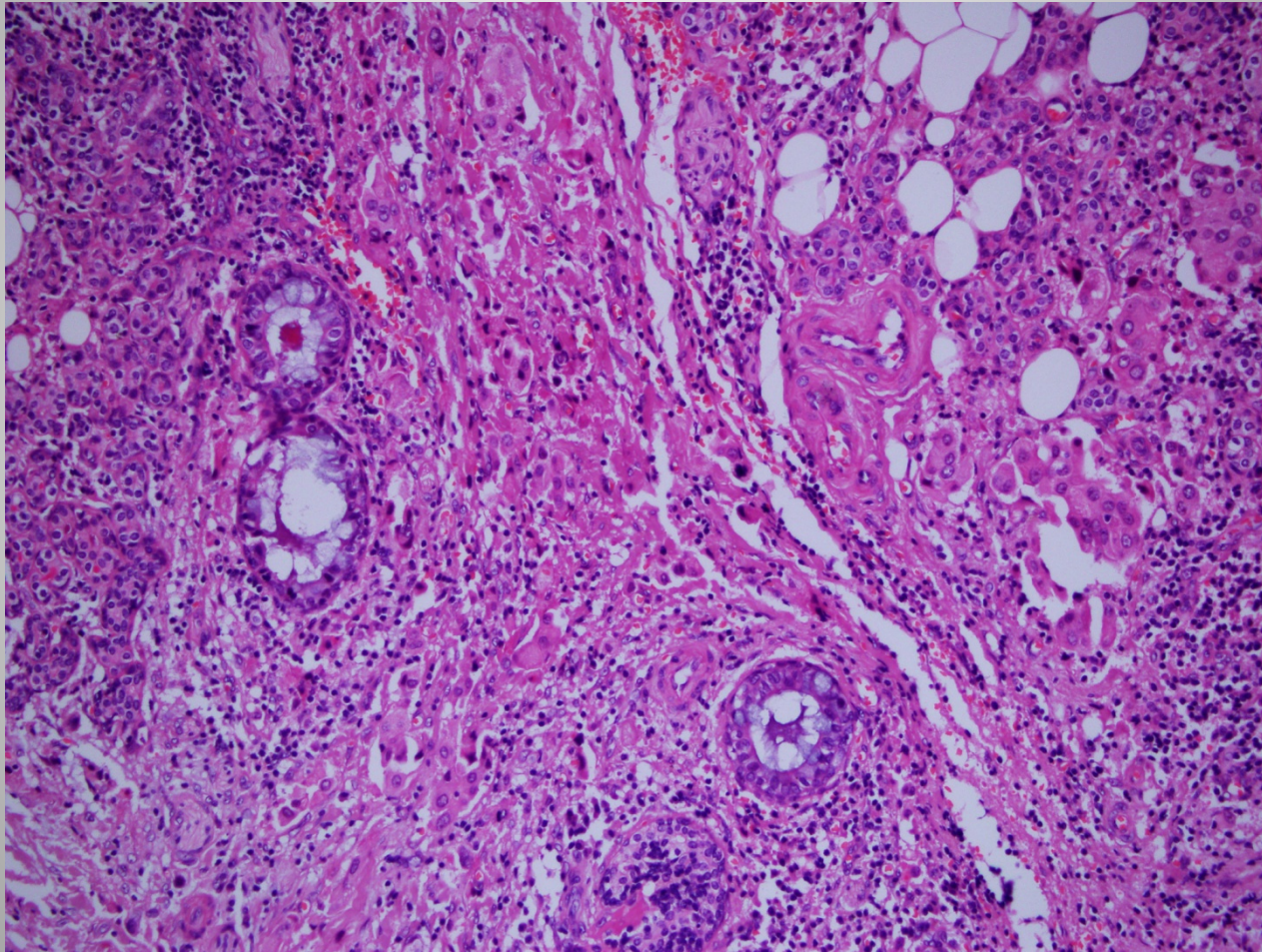


# Epimiyoepitelyal Proliferasyon

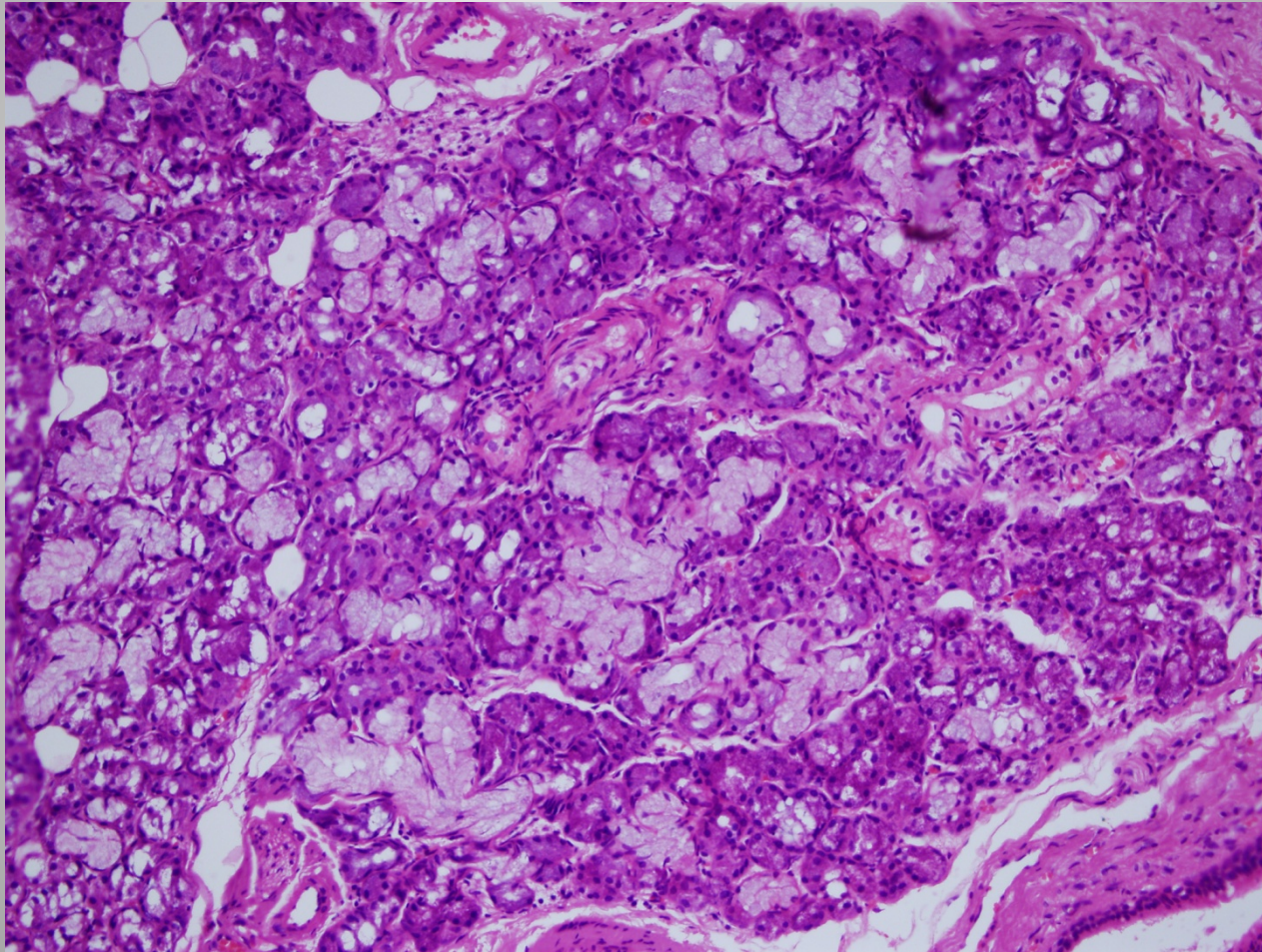




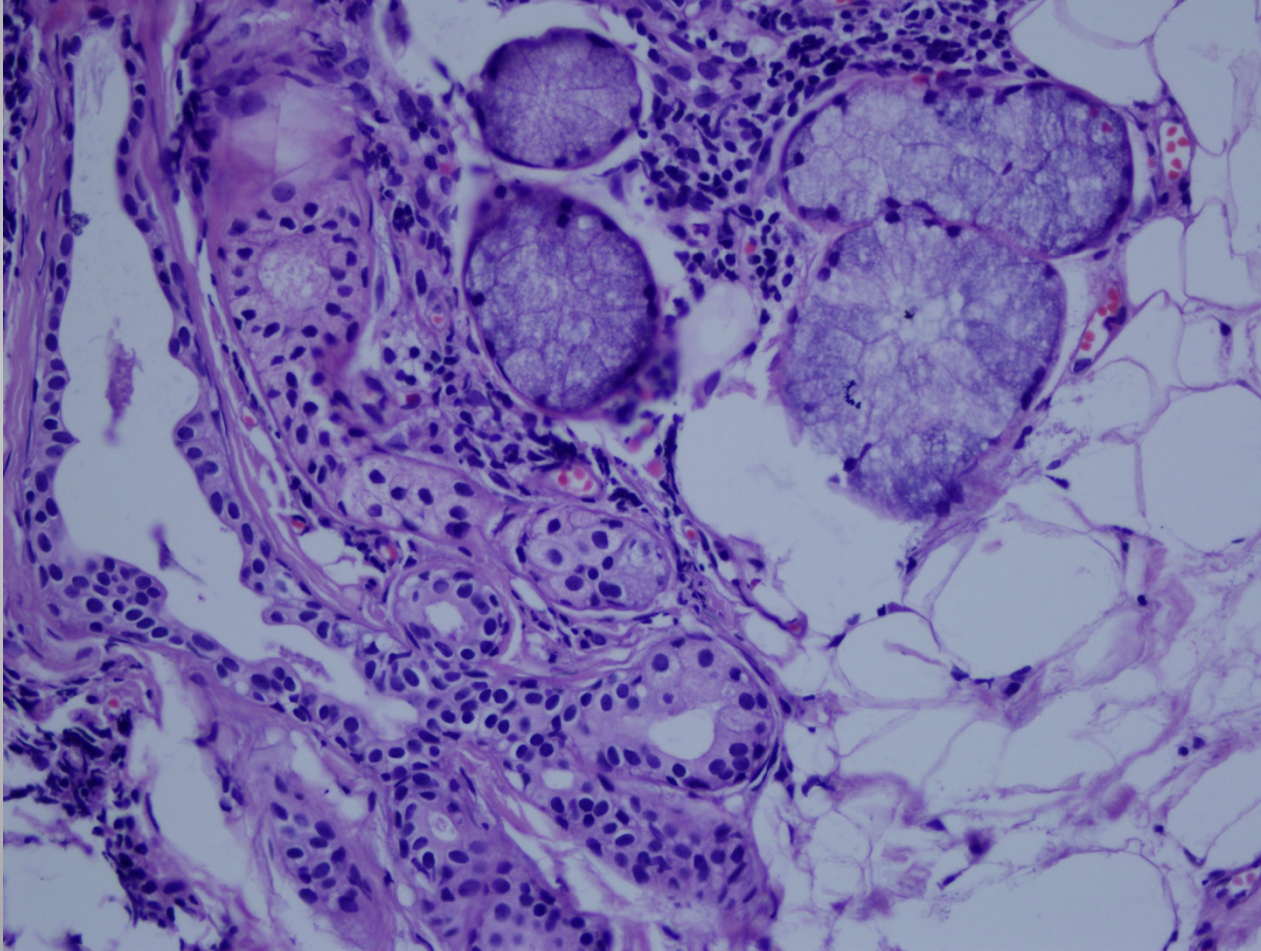
# Goblet Hücre Metaplazisi



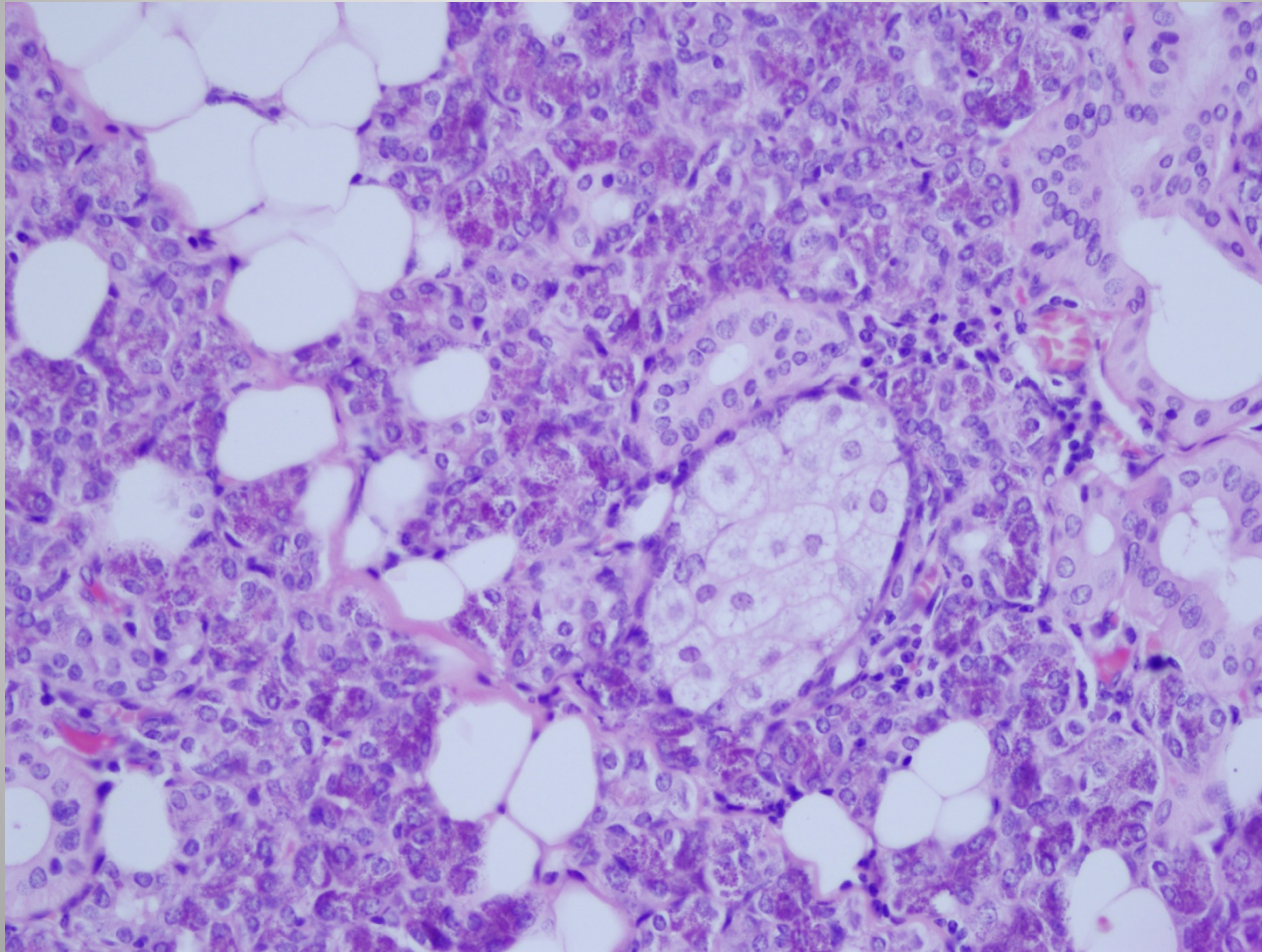
# Müsinöz Metaplazi



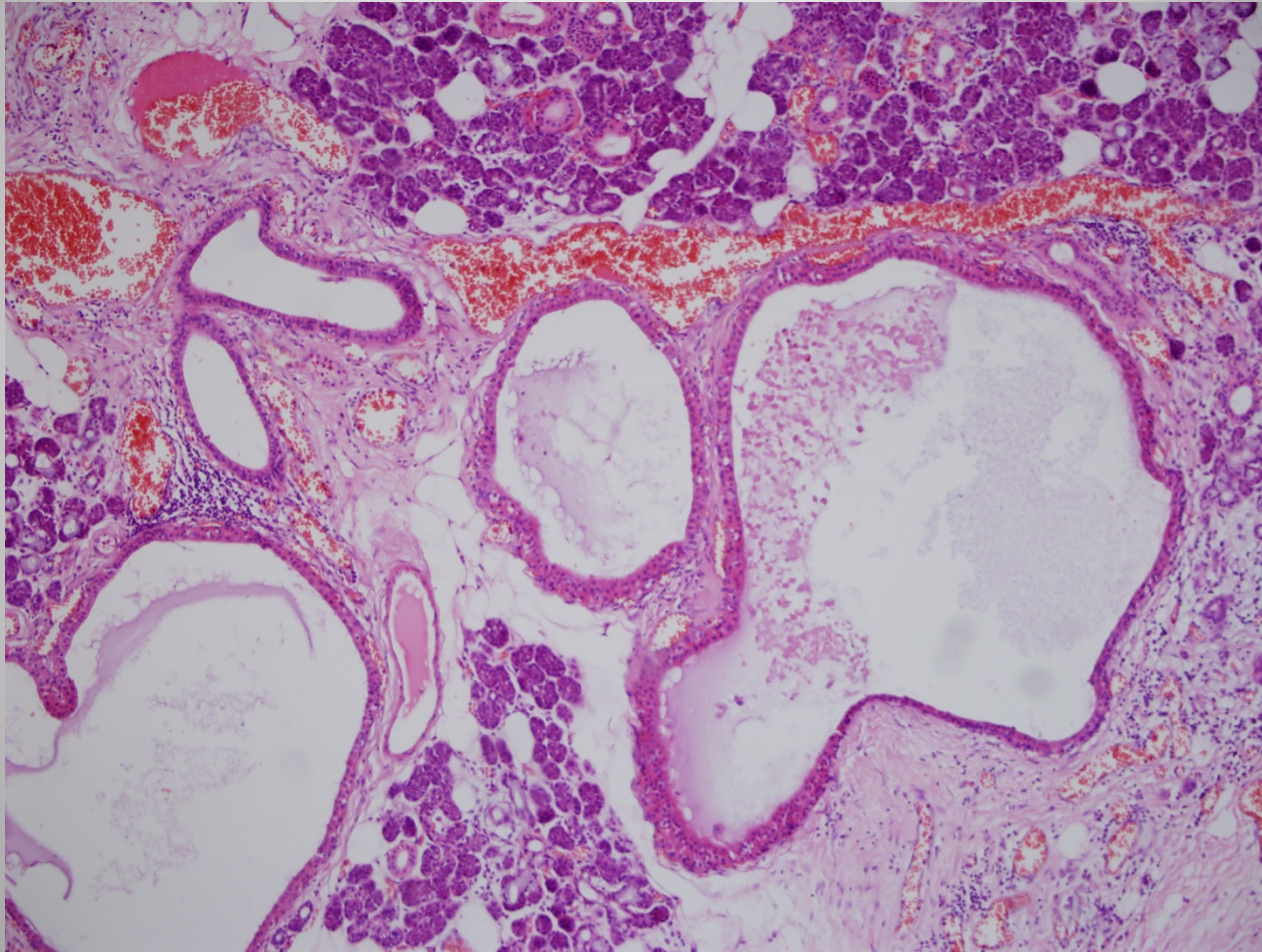
# Şeffaf Hücreli Değişiklikler



# Sebaseöz Metaplazi



# Onkositik Hiperplazi



# SONUÇLAR

LEZYON	YAŞ (ORTALAMASI)	CİNSİYET	LOKALİZASYON	EŞLİK EDEN MALİGN TÜRÖR	EŞLİK EDEN BENİGN TÜRÖR
7 AA	28	4E 3K	1MTB,1SMG, 5PG	-	6 PA
5 IDA	48	3E 2K	1SMG, 4PG	-	3 PA
1 SM	77	K	MTB	-	-
1 MM	21	K	SMG	-	-
1 OH	61	E	SMG	-	-
1 ŞHD	65	K	MTB	AKK	-
1 SeM	22	E	PG	-	PA
1 GHM	73	E	PG	DK	-

AA: Asiner Adenozis, E:Erkek, K:Kadın, MTB: Minör Tükürük Bezi, SMG: Submandibular Gland, PG: Parotis Gland, PA: Pleomorfik adenoma, IDA: "Intercalated" duktus adenozisi, SM: Skuamöz Metaplazi, MM: Müsinöz Metaplazi, OH: Onkositik hiperplazi, ŞHD: Şeffaf hücreli deęişiklik, SeM: Sebaceöz Metaplazi , GHM: Goblet Hücreli Metaplazi, DK: Duktus karsinomu

# Ne Yapılabilir?

- Muhtemel....
- IHK: p53 ve Ki-67
- Moleküler Patoloji, meme (1q, 16q, 13q, 17q12, 11q13 değişiklikleri, BRCA-1 )
- Moleküler Patoloji, pankreas (K-ras, p21, p53, BRCA-2 mutasyonları ile telomer kısalması, Her2/neu, “prostate stem cell antigen”)
- Moleküler Patoloji, tükürük bezi (TP53, Siklin yolağı, PTEN, ERBB2, HRAS, MDM2 gibi gen aberrasyonları)

# Kaynaklar

1. Precursors to Pancreatic Cancer: *Gastroenterology Clinics of North America*, Volume 36, Issue 4, Pages 831-849 Ralph H. Hruban, Anirban Maitra, Scott E. Kern, Michael Goggins.
2. Histopathological Study of the precursor Lesions of the Ductal Invasive Breast Carcinoma : Current Health Sciences Journal Vol. 35, No. 4, 2009 page 259-263 Georgiana Luminița Fota, Cristiana Simionescu, Claudia Valentina Georgescu , Nicoleta Pătrână , Mihaela Muntean , A. Stepan
3. Salivary Gland Hyperplasia: On: Adenomatous ductal proliferation of the salivary gland. Yu G-Y, Donath K, Mult D. Oral Surg Oral Med Oral Pathol Oral Radiol Endod 2001;91:215–221
4. Intercalated Duct Lesions of Salivary Gland A Morphologic Spectrum From Hyperplasia to Adenoma: Am J Surg Pathol 2009;33:1322–1329 Ilan Weinreb, Raja R. Seethala, Jennifer L. Hunt, Runjan Chetty, Irving Dardick and Bayardo Perez-Ordóñez
5. The Molecular Pathology of Breast Cancer Progression J Pathol. 2011 January ; 223(2): 307–317. doi:10.1002/path.2808. Alessandro Bombonati and Dennis C. Sgroi
6. Precursor Lesions In Pancreatic Cancer: Morphologic and Molecular Pathology Pathology (2011), 43(3), April Christopher J. Scarlett, Elizabeth I. Salisbury, Andrew V. Biankin and James Kench.
7. A review of the proliferative capacity of major salivary glands and the relationship to current concepts of neoplasia in salivary glands ORAL SURCORAL MED ORAL PATHOL 1990;69:53-67) Irving Dardick, MD, Roger W. Byard, MBBS and Jacqueline A. Carnegie, PhD
8. Genomic landscape of salivary gland tumors, Oncotarget Advance Publications 2015 Shumei Kato, Sheryl K. Elkin, Maria Schwaederle, Brett N. Tomson, Teresa Helsten, Jennifer L. Carter, Razelle Kurzrock
9. Disease of the salivary glands pathology-diagnosis-treatment-facial nerve surgery. Seifert G, Mielke A, Haubrich J, Chilla R. Stuttgart, Germany: Georg Thieme Verlag; 1986
10. Intraoral, mucinous, minor salivary gland lesions presenting clinically as tumors. Giansanti JS, Baker GO, Waldron CA. Oral Surg Oral Med Oral Pathol 1971;52:51–55.
11. Adenomatous ductal proliferation of the salivary glands. Yu GY, Donath K. Oral Surg Oral Med Oral Pathol Oral Radiol Endod 2001;91:215–221
12. Rosai And Ackerman's Surgical Pathology 10th Edition



# Dikkatiniz İin Teřekkür Ederim

