

Endometrial Cancer:

Common Problems in Histologic Subtyping That are Clinically Relevant

Joseph Rabban MD MPH
Professor
UCSF Pathology Department



University of California
San Francisco



Treatment Decisions for Uterine Carcinoma

1. Primary Surgery or Trial of Hormonal Therapy

2. Extent of Staging Surgery

3. Type of Adjuvant Therapy

4. Type of Lynch syndrome evaluation

Treatment Decisions for Uterine Carcinoma

Surgeon's View of Uterine Cancer

```
graph TD; A[Surgeon's View of Uterine Cancer] --> B[Low Risk Behavior]; A --> C[High Risk Behavior];
```

Low Risk Behavior

- Low stage at presentation
- Low likelihood to:
 - recur
 - metastasize
 - cause death

High Risk Behavior

- Advanced stage at presentation
- Chemo-resistance
- Local recurrence
- Distant metastasis
- Death

Treatment Decisions for Uterine Carcinoma

Surgeon's View of Uterine Cancer

Low Risk Behavior

**Endometrioid
Mucinous**

Grade: 1

LVI: No

Stage: I

High Risk Behavior

**High Grade Serous
Clear Cell
Carcinosarcoma
Undifferentiated**

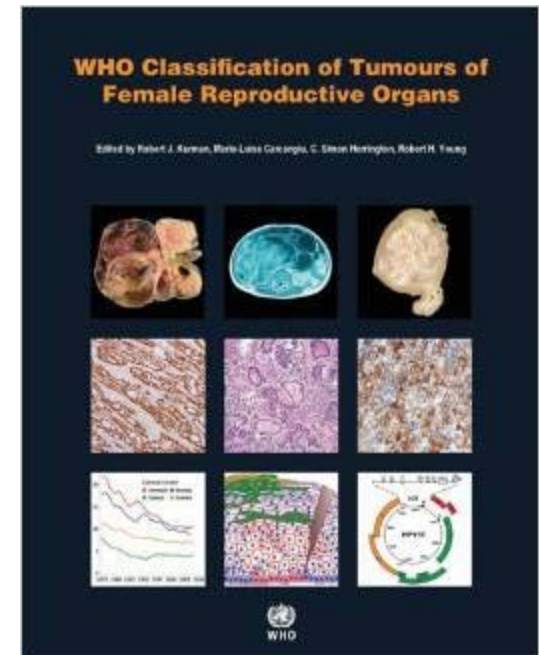
Grade: 3

LVI: Yes

Stage: >I

2014 WHO Classification of Uterine Carcinoma

- Endometrioid adenocarcinoma
 - Serous carcinoma
 - Clear cell carcinoma
 - Mucinous carcinoma
 - Neuroendocrine tumors
 - Undifferentiated / Dedifferentiated carcinoma
 - Mixed type carcinoma
-
- Carcinosarcoma



Integrated genomic characterization of endometrial carcinoma

The Cancer Genome Atlas Research Network*

2 MAY 2013 | VOL 497 | NATURE | 73

The Cancer Genome Atlas



*Understanding genomics
to improve cancer care*

NATIONAL
CANCER
INSTITUTE



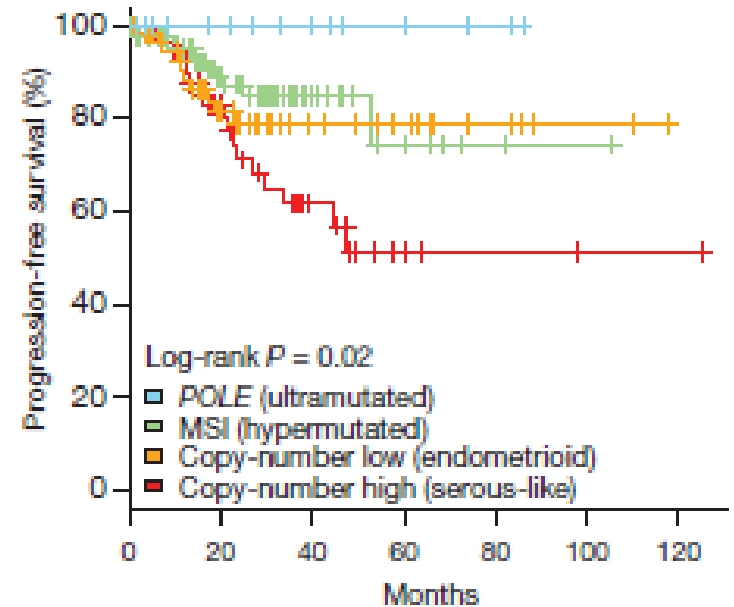
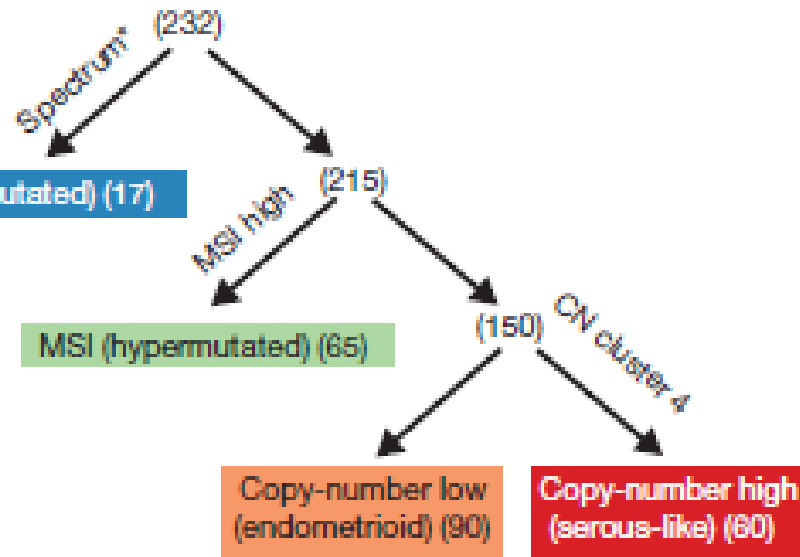
genome.gov

National Human Genome Research Institute

National Institutes of Health

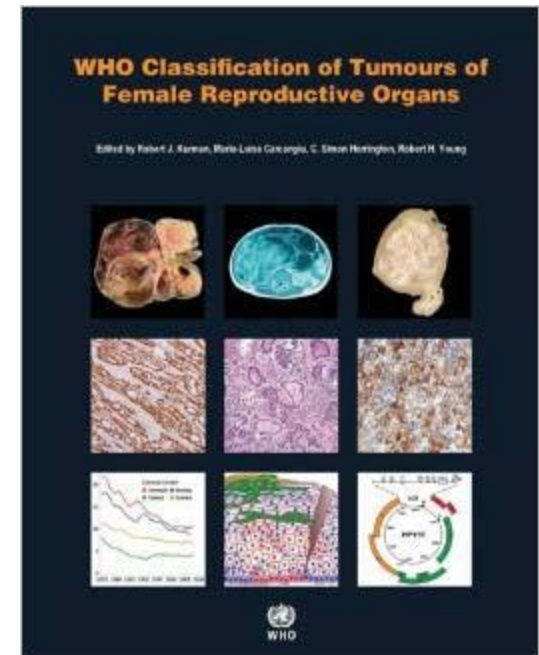
The Cancer Genome Atlas Classification of Uterine Cancer

2 MAY 2013 | VOL 497 | NATURE | 67



2014 WHO Classification of Uterine Carcinoma

- Endometrioid adenocarcinoma
 - Serous carcinoma
 - Clear cell carcinoma
 - Mucinous carcinoma
 - Neuroendocrine tumors
 - Undifferentiated / Dedifferentiated carcinoma
 - Mixed type carcinoma
-
- Carcinosarcoma



Treatment Decisions for Uterine Carcinoma

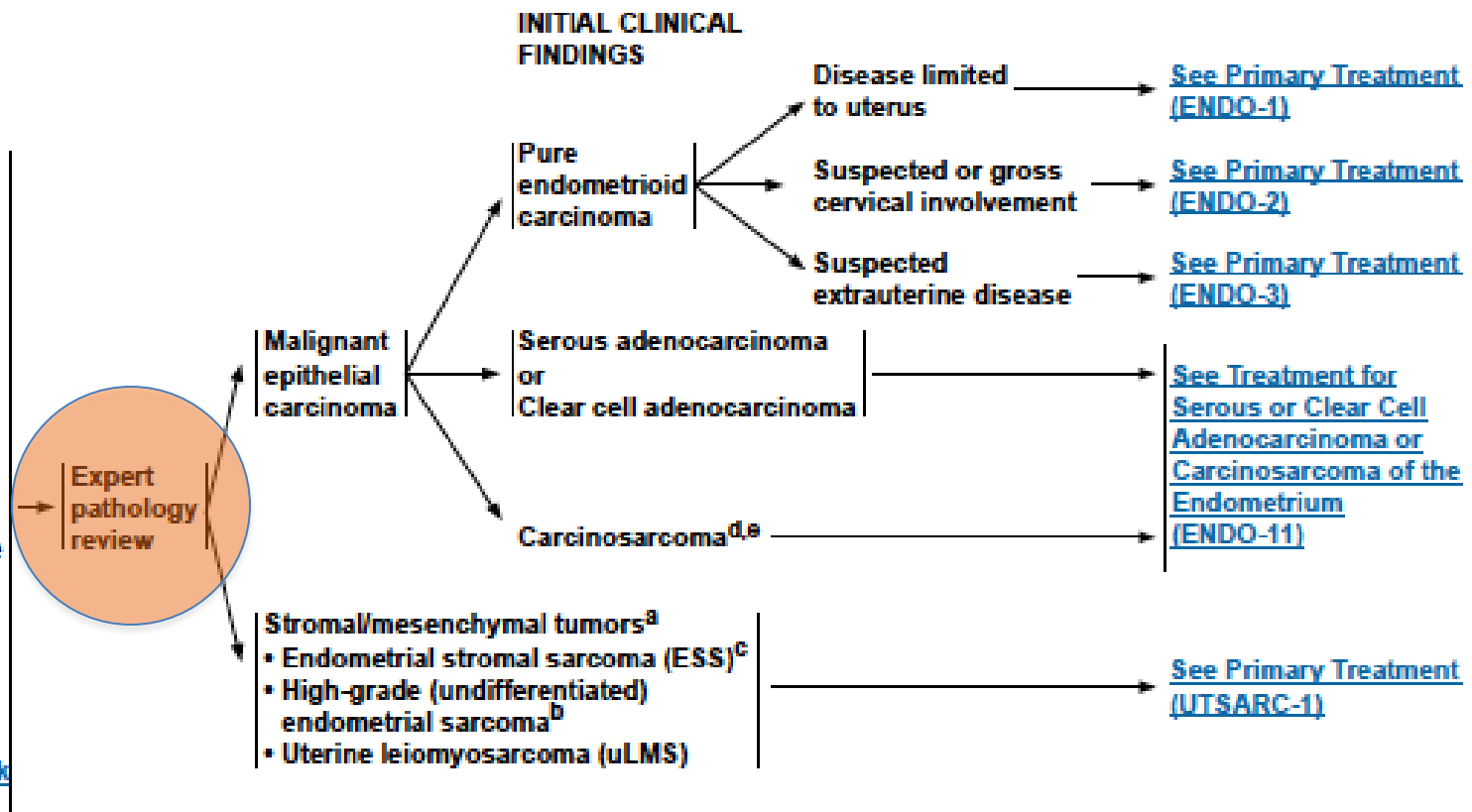
All staging in guideline is based on updated 2010 FIGO staging. (See [ST-1](#) and [ST-2](#))

INITIAL EVALUATION

- H&P
- CBC (including platelets)
- Endometrial biopsy^a
- Chest imaging

Optional:

- Liver function test (LFT)/renal function tests/chemistry profile
- Consider genetic counseling/testing for patients (<50 y) and those with a significant family history of endometrial and/or colorectal cancer^b ([See Lynch syndrome/ HNPCC in the NCCN Guidelines for Genetic/Familial High-Risk Assessment: Colorectal](#))



Treatment Decisions for Uterine Carcinoma

	Pathologic Data	Source of Data
1. Primary Surgery or Hormonal Therapy	Tumor type Grade	Biopsy
2. Extent of Surgery	Tumor type Grade LVI Stage	Biopsy Intraoperative evaluation
3. Type of Adjuvant Therapy	Tumor type Grade LVI Stage	Hysterectomy
4. Type of Lynch syndrome evaluation	Morphology	Hysterectomy

Decision 1. Primary Surgery or Trial of Hormonal Therapy

Surgery is the default unless:

- **G1 endometrioid adenocarcinoma**
- **Clinically low stage**

AND

- **Fertility preservation desired**



**Trial of
Hormone
Therapy**

Treatment Decisions for Uterine Carcinoma

Decision 2. Extent of Surgery

Biopsy / Frozen Section

Hysterectomy

g1 Endometrioid, no Myoinvasion/LVI

Plus pelvic lymph nodes

g1 Endometrioid, + LVI or Myoinvasion

Plus para-aortic lymph nodes:

g2 Endometrioid, + LVI or >stage IA
g3 Endometrioid
Clear cell carcinoma

Plus omentectomy:

Serous carcinoma
Carcinosarcoma

Treatment Decisions for Uterine Carcinoma

Decision 3. Type of Adjuvant Treatment

None	grade 1 endometrioid, no LVI, stage I
Chemotherapy considered	grade 2 or 3 endometrioid / age / LVI / MM invasion serous, clear cell, carcinosarcoma
Radiation considered	clear cell, serous, carcinosarcoma higher stage endometrioid
Ifosfamide considered	carcinosarcoma with rhabomyosarcoma elements
Etoposide considered	neuroendocrine carcinoma

Treatment Decisions for Uterine Carcinoma

Practical Approach to Uterine Cancer Diagnosis

```
graph TD; A[Practical Approach to Uterine Cancer Diagnosis] --> B[Low Risk Tumor Behavior]; A --> C[High Risk Tumor Behavior]; B --> D[Grade 1 Endometrioid Adenocarcinoma]; C --> E[Grade 3 endometrioid cancer, Serous carcinoma, Clear cell carcinoma, Carcinosarcoma, Undifferentiated carcinoma];
```

Low Risk Tumor Behavior

**Grade 1 Endometrioid
Adenocarcinoma**

High Risk Tumor Behavior

- **Grade 3 endometrioid cancer**
- **Serous carcinoma**
- **Clear cell carcinoma**
- **Carcinosarcoma**
- **Undifferentiated carcinoma**

Treatment Decisions for Uterine Carcinoma

Practical Approach to Uterine Cancer Diagnosis

Low Risk Tumor Behavior

**Grade 1 Endometrioid
Adenocarcinoma**

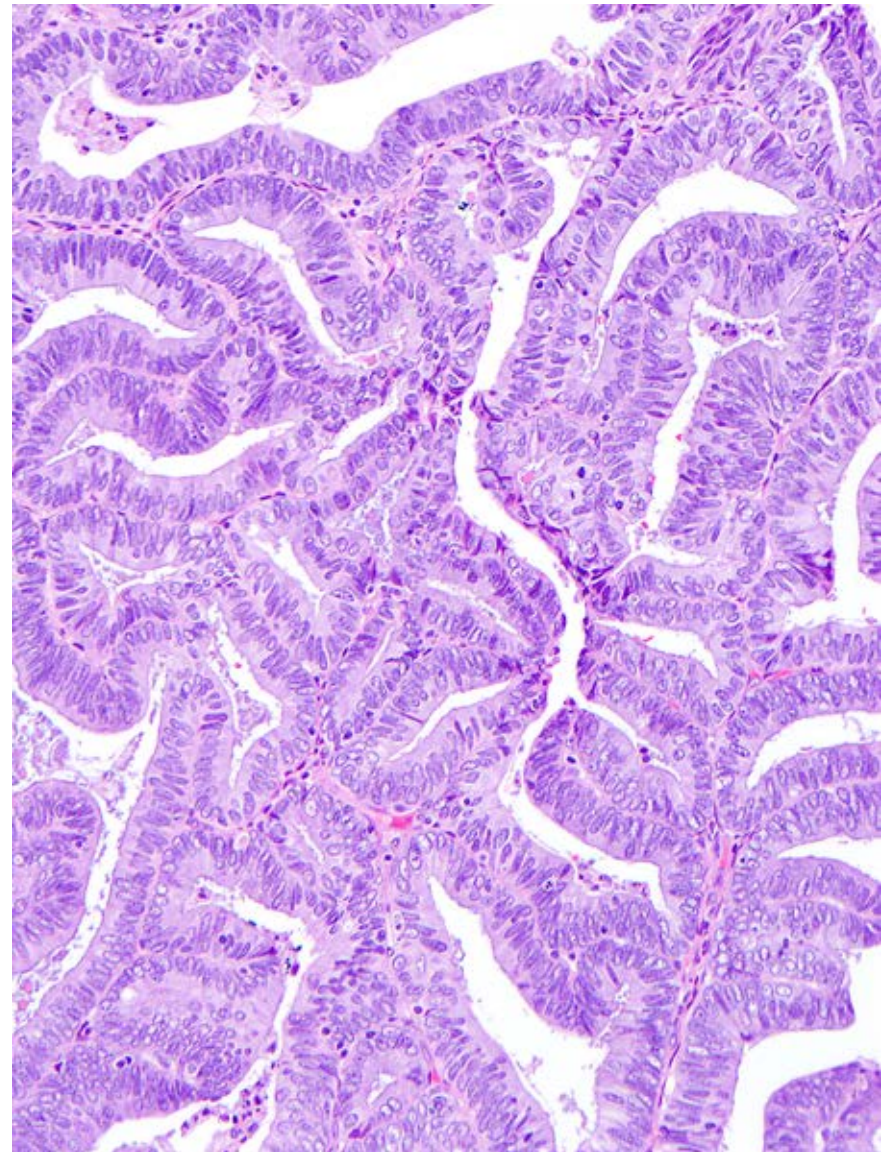
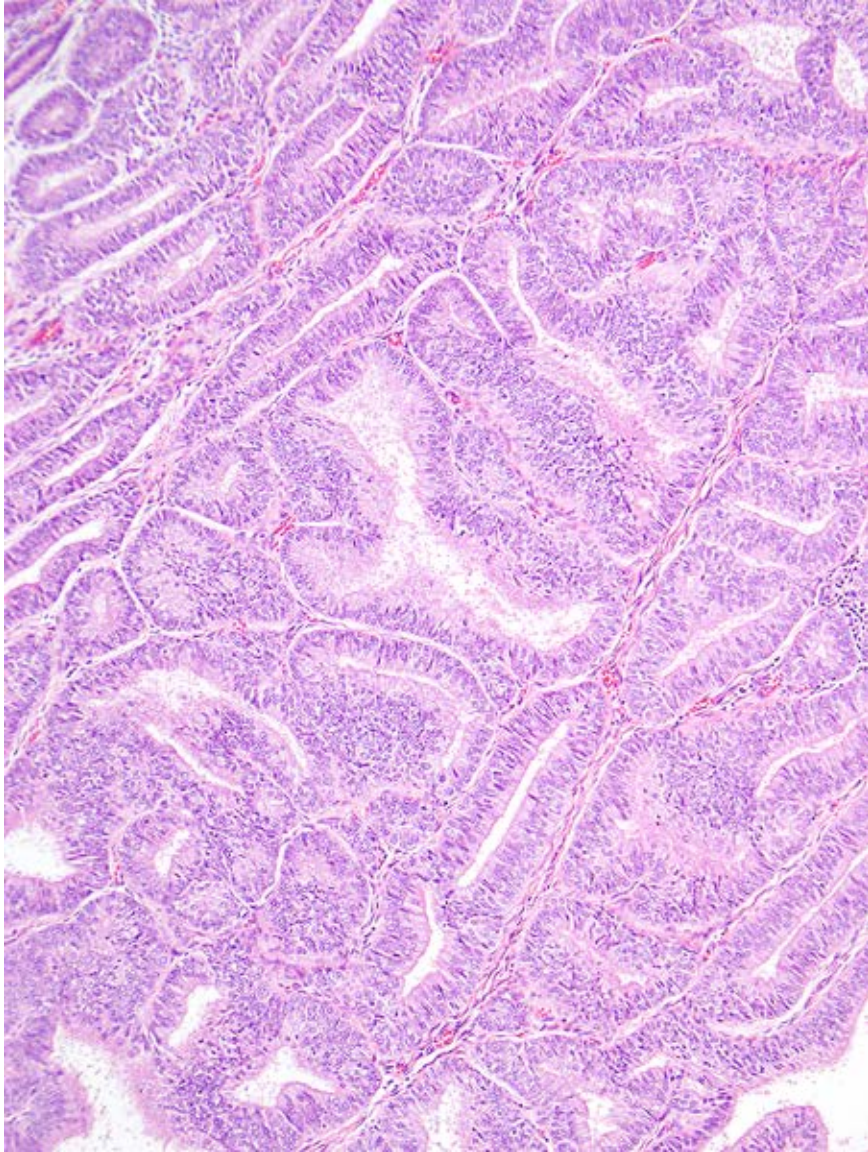
**Classic
Morphology**

High Risk Tumor Behavior

- **Grade 3 endometrioid cancer**
- **Serous carcinoma**
- **Clear cell carcinoma**
- **Carcinosarcoma**
- **Undifferentiated carcinoma**

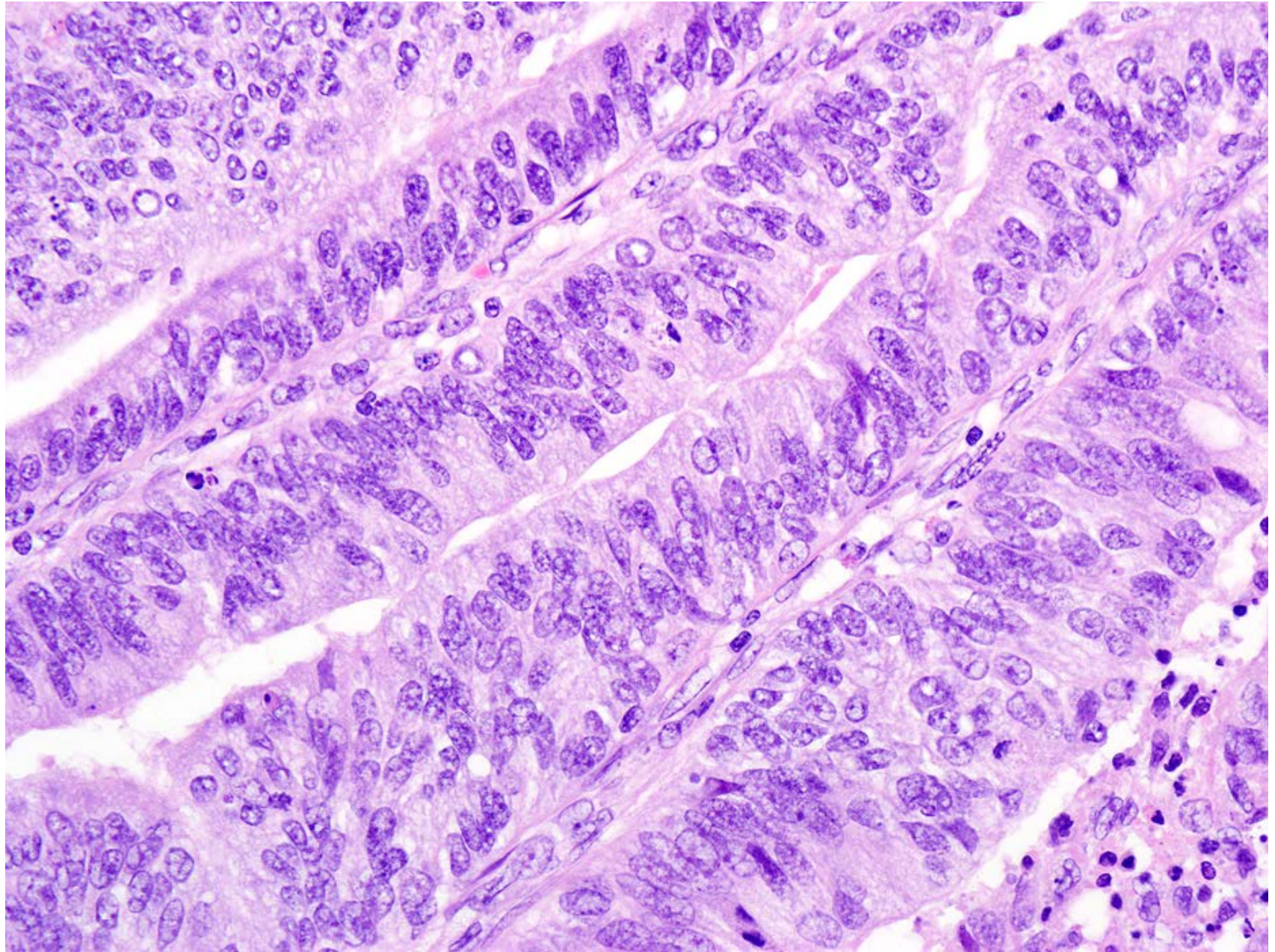
Endometrioid Adenocarcinoma

Classical Morphology



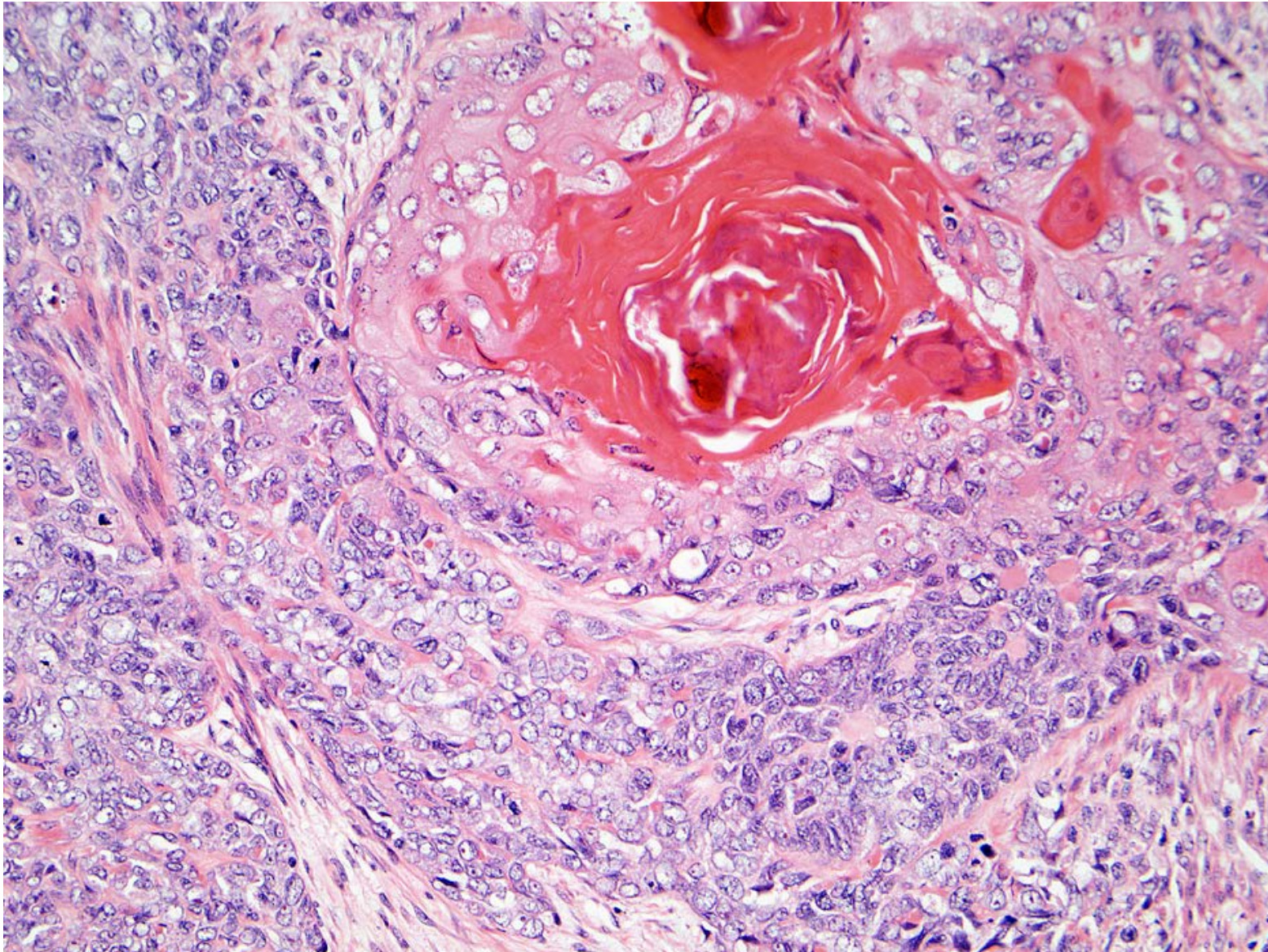
Endometrioid Adenocarcinoma

Classical Morphology



Endometrioid Adenocarcinoma

Classical Morphology



Treatment Decisions for Uterine Carcinoma

Practical Approach to Uterine Cancer Diagnosis

Low Risk Tumor Behavior

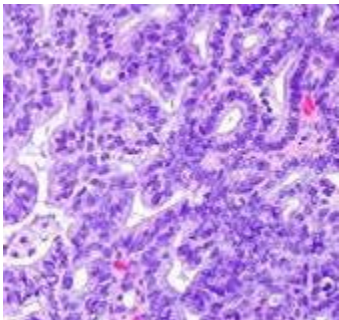
High Risk Tumor Behavior

**Grade 1 Endometrioid
Adenocarcinoma**

**Classic
Morphology**

**Variant
Morphology**

- Grade 3 endometrioid cancer
- Serous carcinoma
- Clear cell carcinoma
- Carcinosarcoma
- Undifferentiated carcinoma



Tumors with a Protean Phenotype

*Robert H. Young

Advances in Anatomic Pathology, Vol. 7, No. 5, September, 2000

Proteus: the “shape shifter”



Variants of Endometrioid Adenocarcinoma

TABLE 1. *Endometrioid carcinomas of the uterine corpus*

Typical
Secretory
With papillae
Villoglandular
Small nonvillous papillae
Microglandular
Sertoliform
With metaplastic changes
Squamous differentiation
Clear cell change, not otherwise specified
Surface changes resembling syncytial metaplasia or microglandular hyperplasia
Ciliated cells
Oxyphilic (or oncocytic) cells
With spindled epithelial cells (sarcomatoid)
With a poorly differentiated carcinomatous component
With other patterns
Diffuse growth with low-grade cytology
Extensive hyalinization
Pinched off glands that may be cystic or pseudovascular
With other rare findings
Psammoma bodies
Stromal metaplasia (e.g., osteoid)
With <10% component of one or more other cell types of endometrial carcinoma (e.g., serous, mucinous)



Problematic Patterns of Uterine Cancer

- Glandular
- Papillary
- Spindled
- Clear cell-rich
- Necrosis in “low grade” tumor
- MELF-myoinvasion in low grade tumor
- Mucin-rich
- Solid pattern with high grade atypia



Outline of Talk

Practical problems in sub-typing uterine carcinoma:

- Variants of **g1 endometrioid adenocarcinoma** that mimic high risk tumors
- MELF-pattern myoinvasion in **g1 endometrioid adenocarcinoma**
- New to 2014 WHO: undifferentiated / dedifferentiated carcinoma

Practical Approach to Classifying Uterine Carcinoma

Evaluate in order :

- ***Clinical context:*** **Menopausal status / age**
- ***Low magnification:*** **Architecture**
- ***High magnification:*** **Cytology**
- ***Adjacent tissue:*** **Precursor lesion**
- ***If needed:*** **Immunohistochemistry**

Problematic Patterns of Uterine Cancer

- **Glandular**
- **Papillary**
- **Spindled**
- **Clear cell-rich**
- **Necrosis in “low grade” tumor**
- **MELF-myoinvasion in low grade tumor**
- **Mucin-rich**
- **Solid pattern with high grade atypia**



Low risk and high risk types may mimic each other



Potential to under-diagnose adverse features

Glandular Pattern

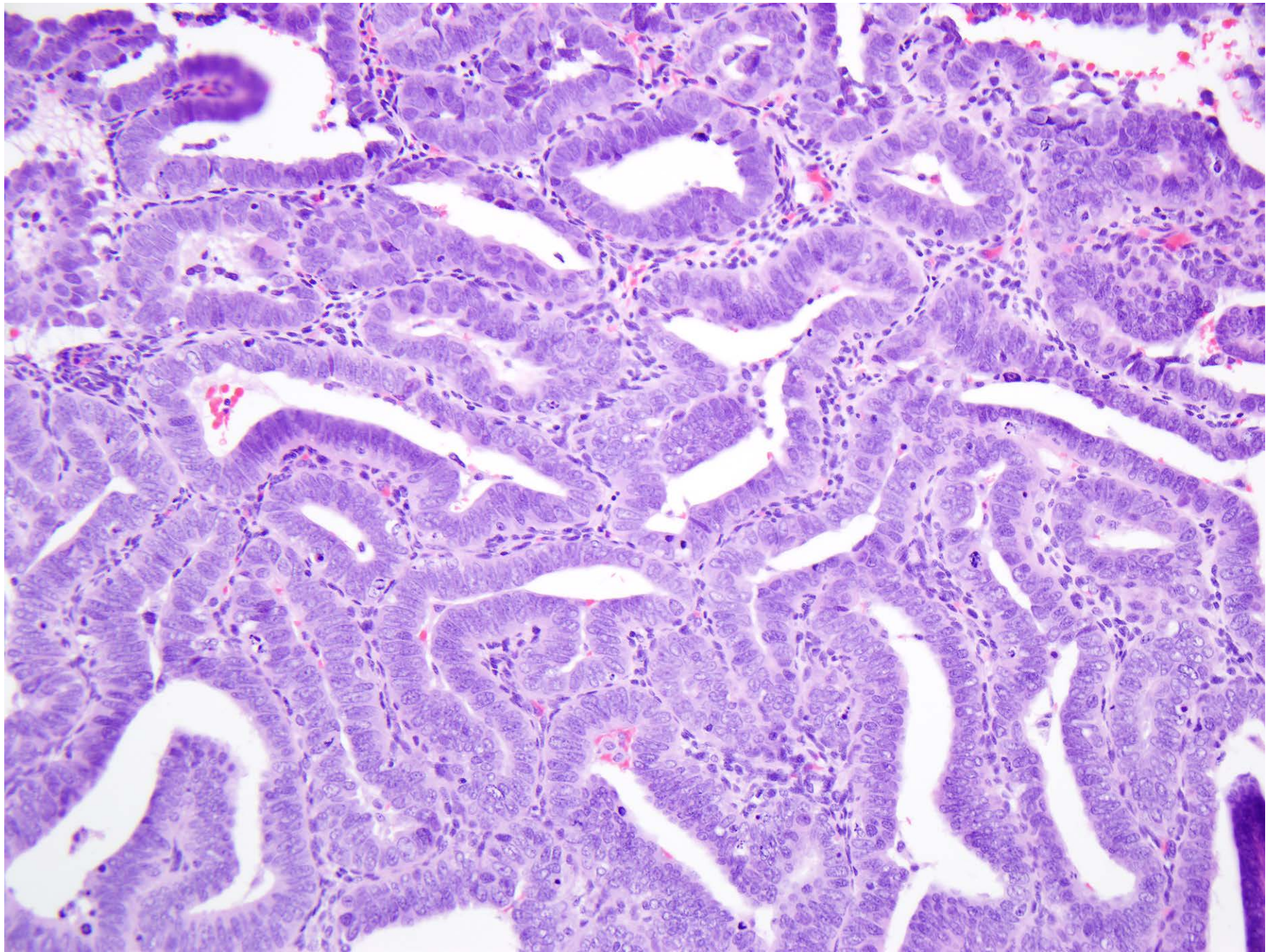
Low Risk Behavior

- Atypical hyperplasia
- G1 endometrioid adenocarcinoma

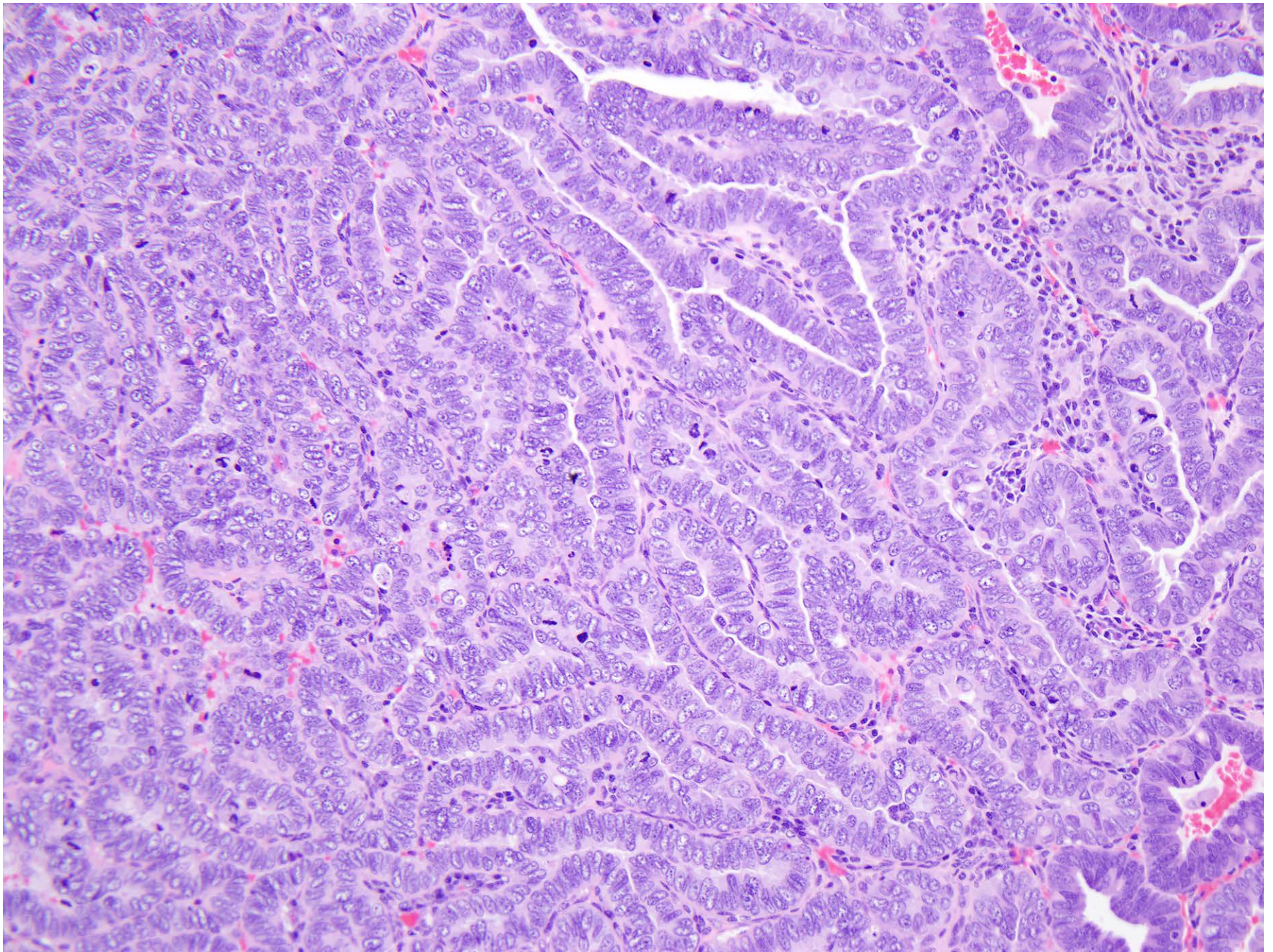
High Risk Behavior

- Pseudo-glandular pattern serous carcinoma

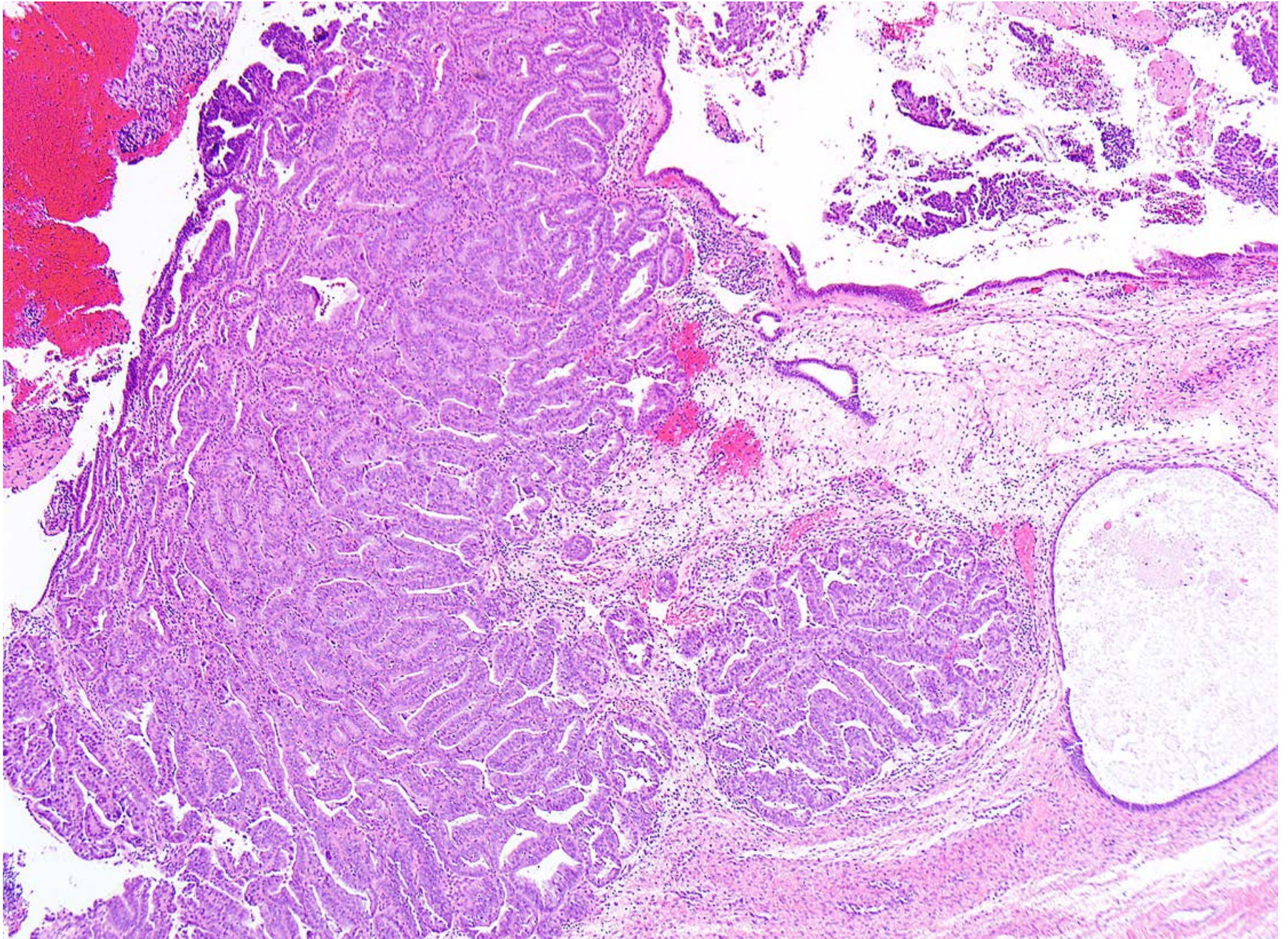
Glandular Pattern



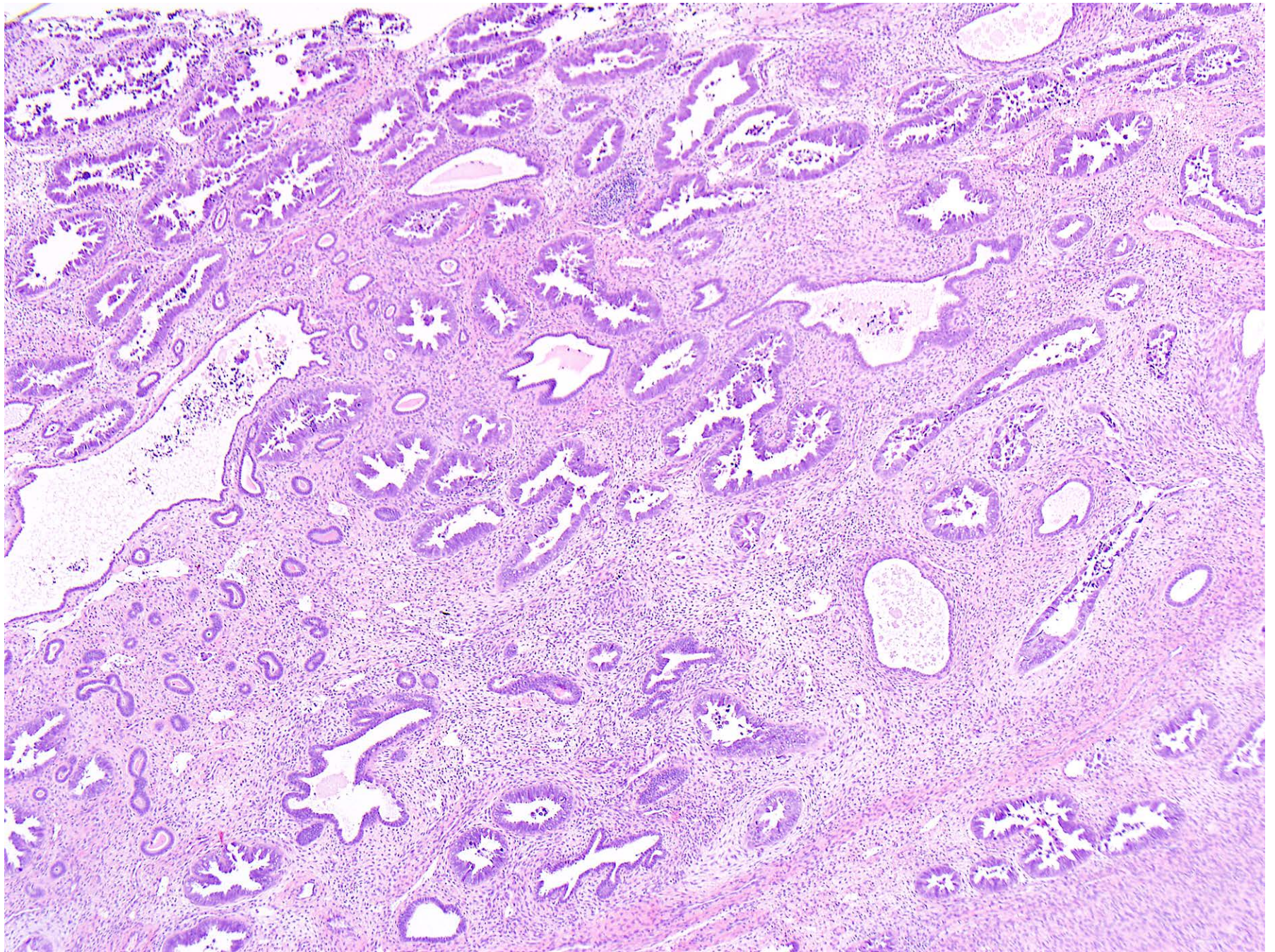
Glandular Pattern



Glandular Pattern in a Polyp



Glandular Pattern in a Polyp

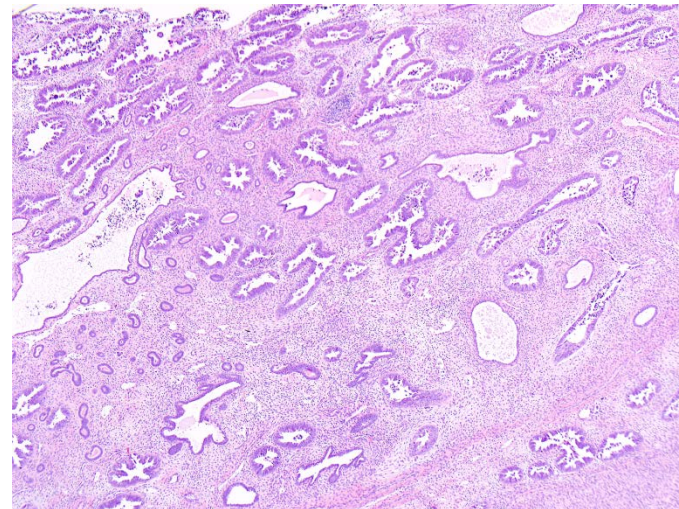
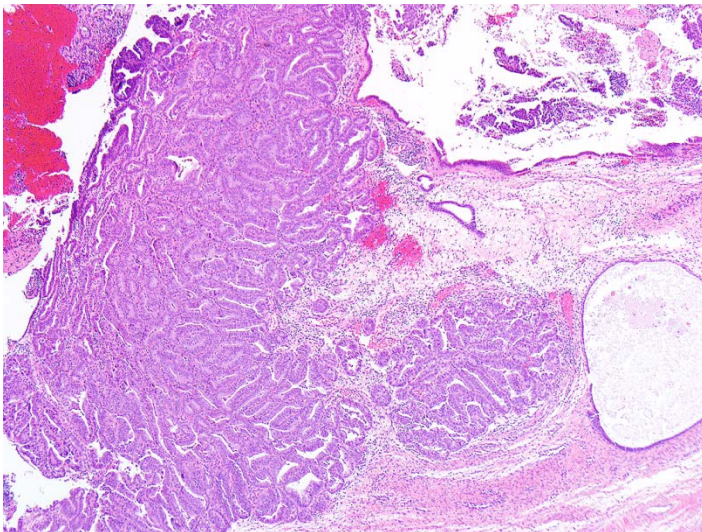
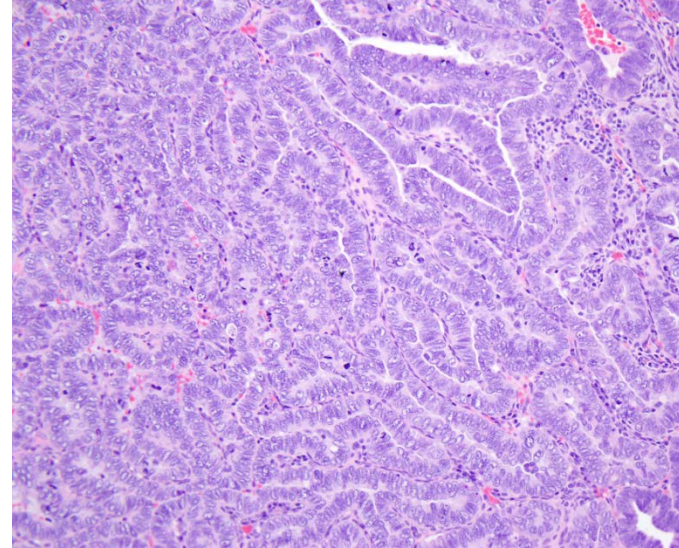
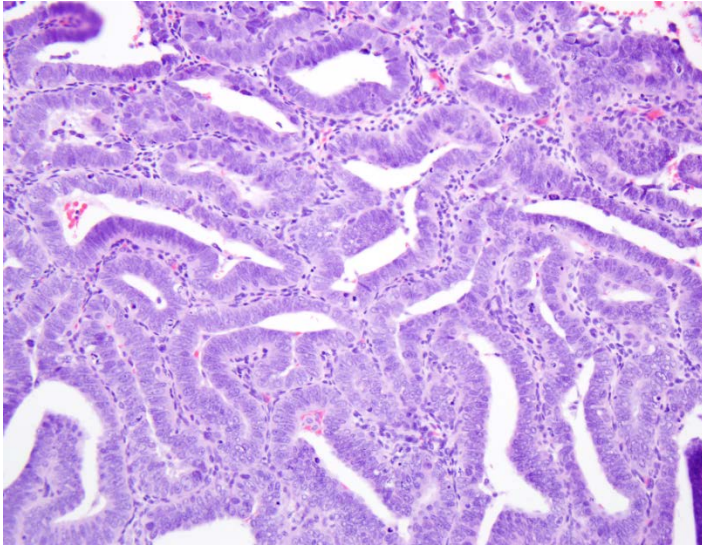


Pseudo-glandular Serous Carcinoma

All are grade 3.

All require full surgical staging.

All are potential high risk behavior.



Glandular Pattern Uterine Cancer

**Grade 1
Endometrioid**

**Pseudoglandular
Serous**

**Architectural
Grade**

Low

Low

**Nuclear
Grade**

Low

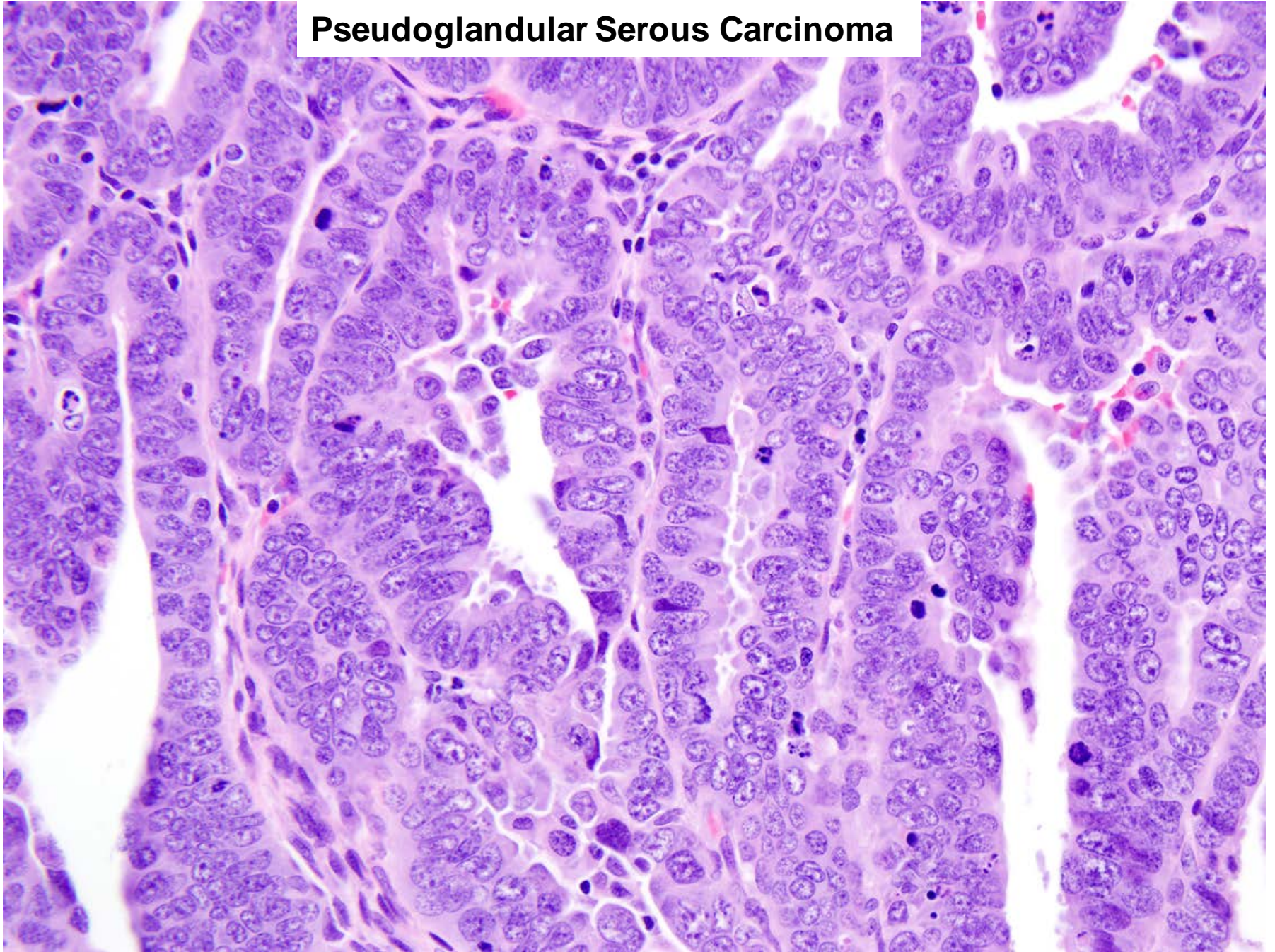
High

**Discordant architecture
versus nuclear grade**

- **Pleomorphic nuclei**
- **Cherry-red macronucleoli**
- **Smudge cells**
- **Atypical mitoses**

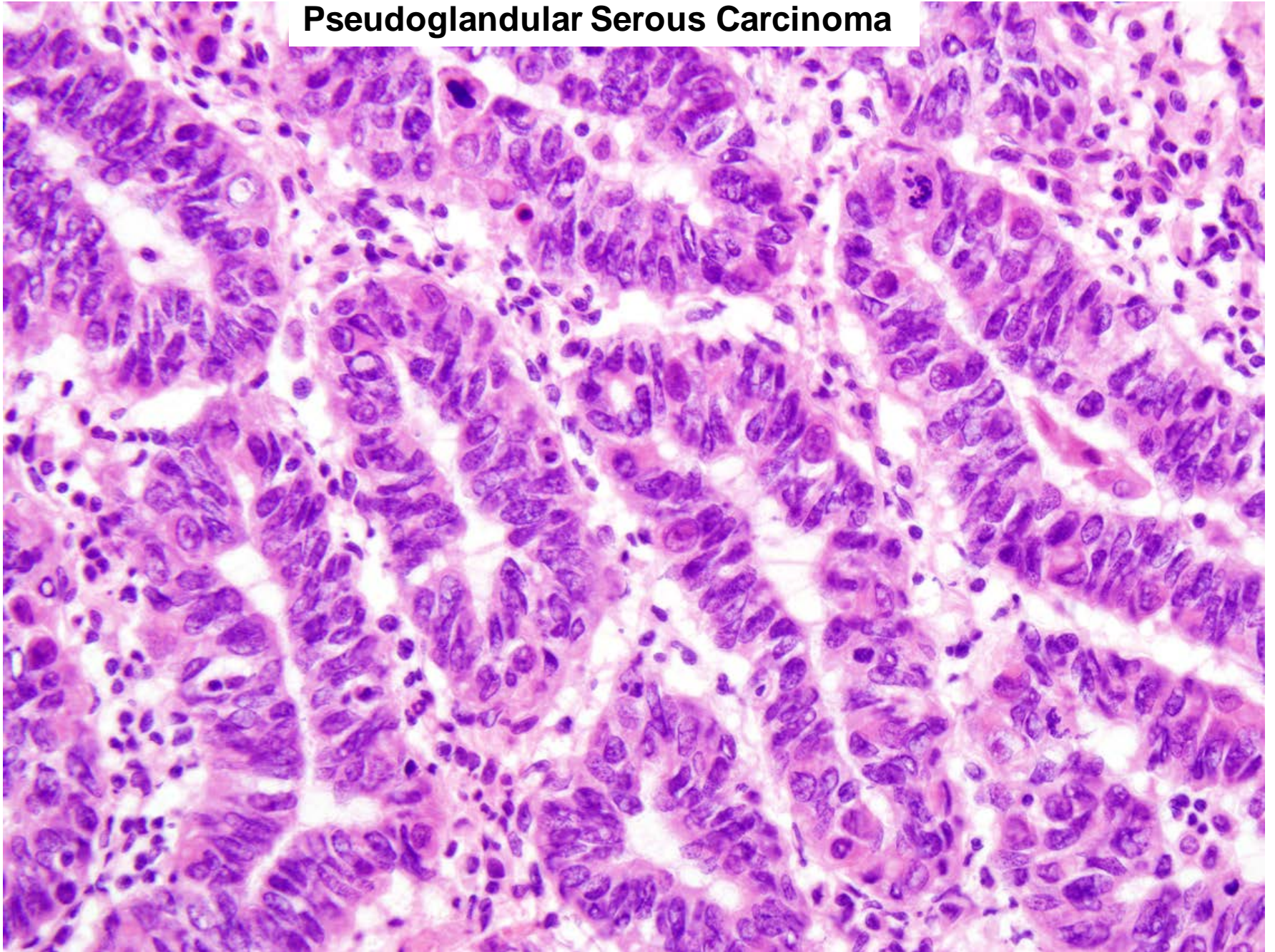
High N/C Ratio

Pseudoglandular Serous Carcinoma



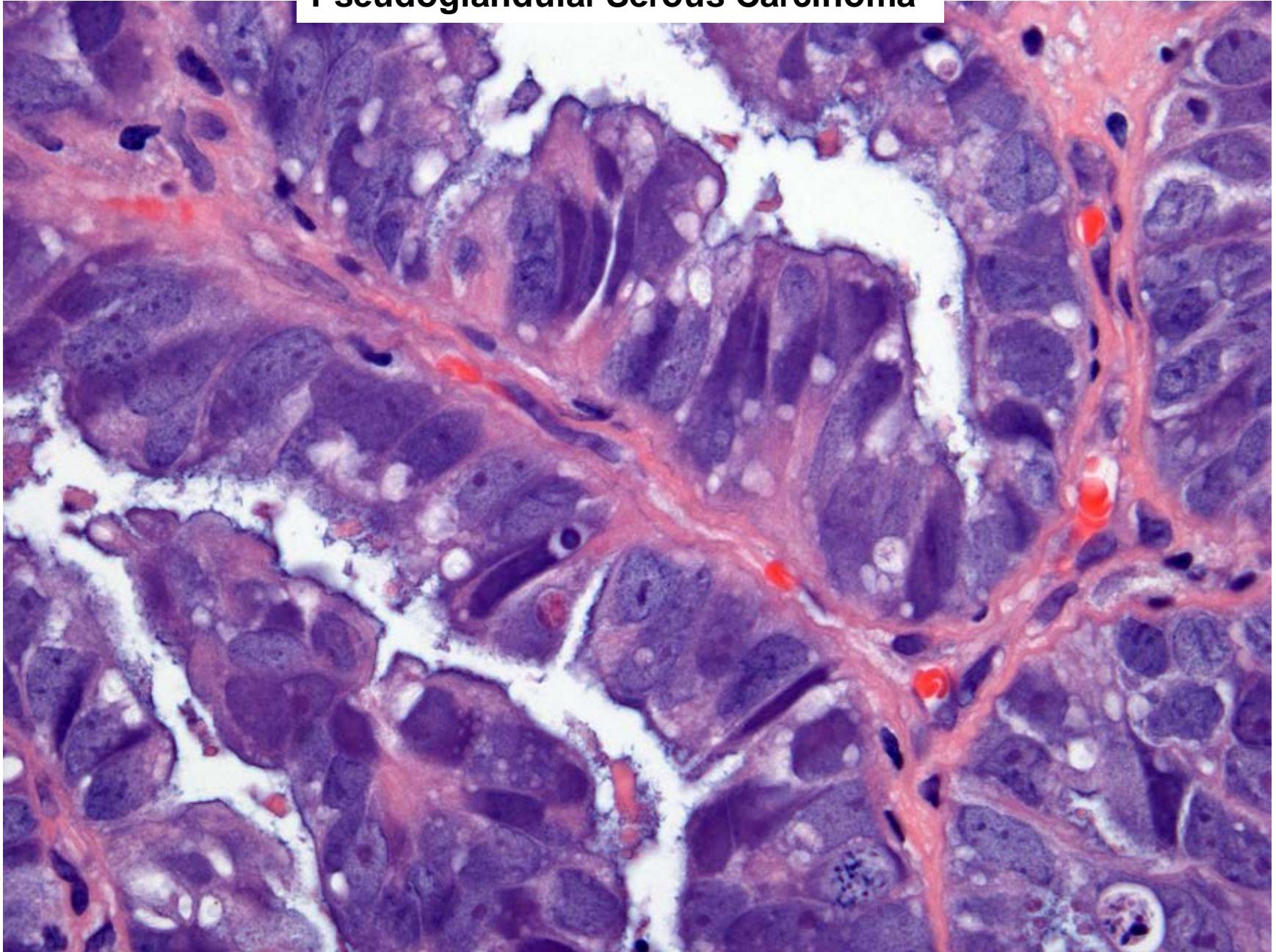
High N/C Ratio

Pseudoglandular Serous Carcinoma



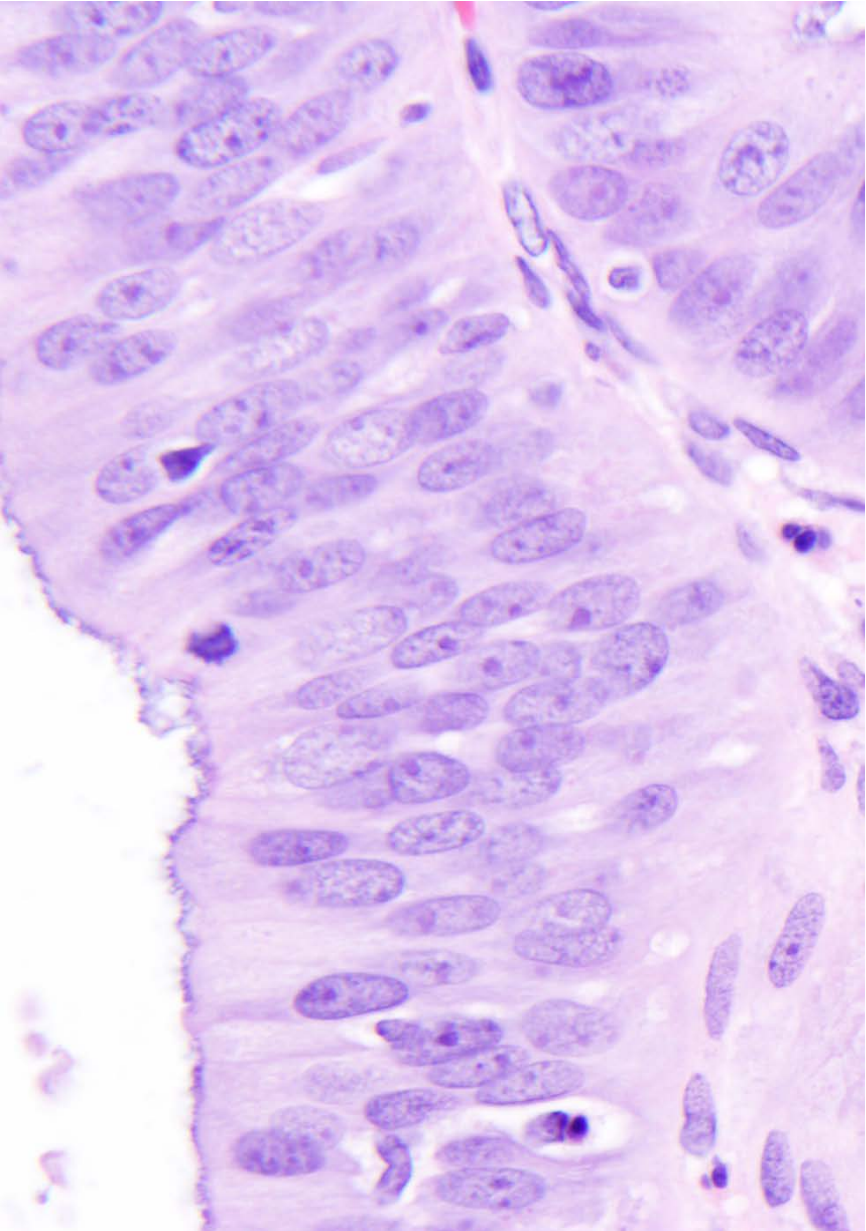
Severe Atypia

Pseudoglandular Serous Carcinoma

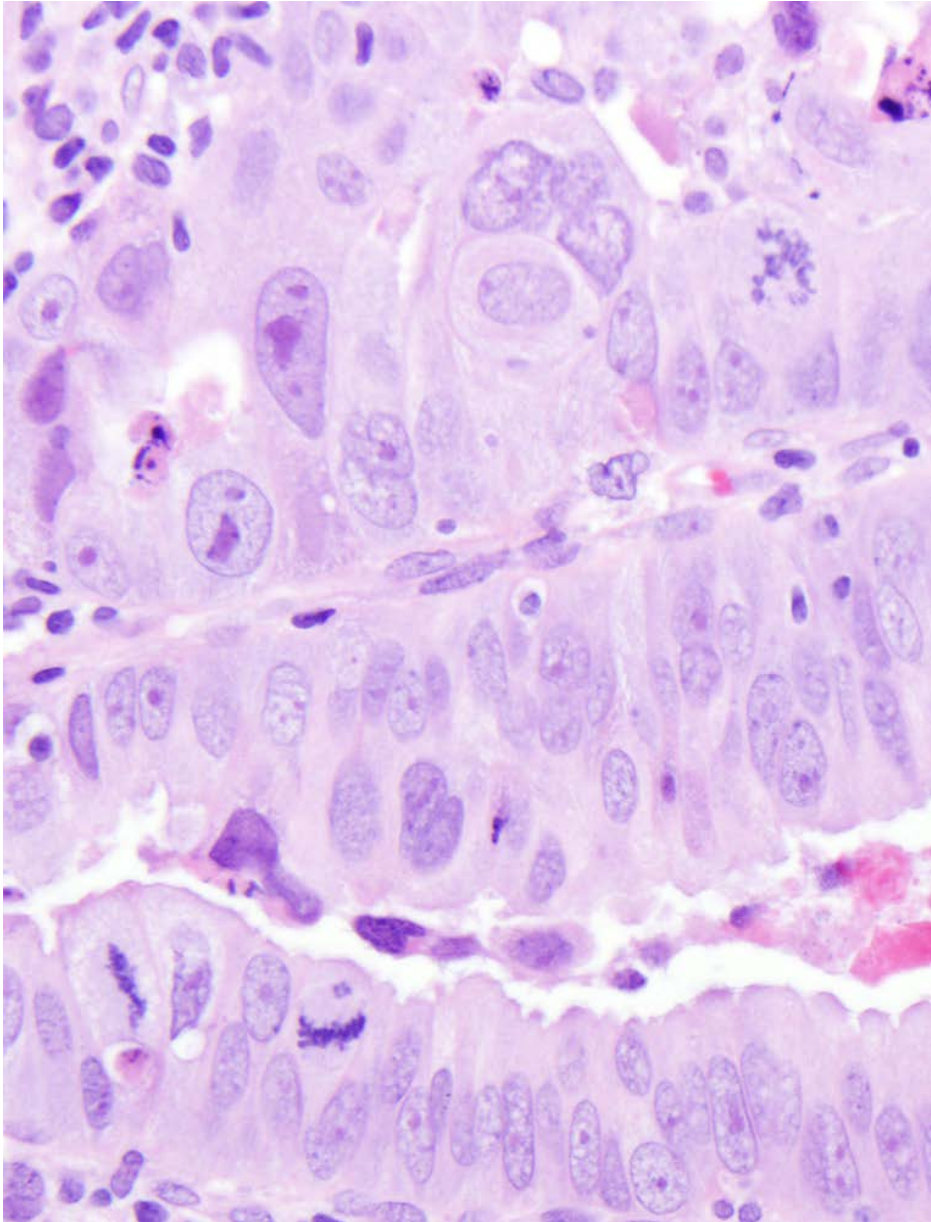


Nucleoli

Endometrioid carcinoma
(upper end of size)

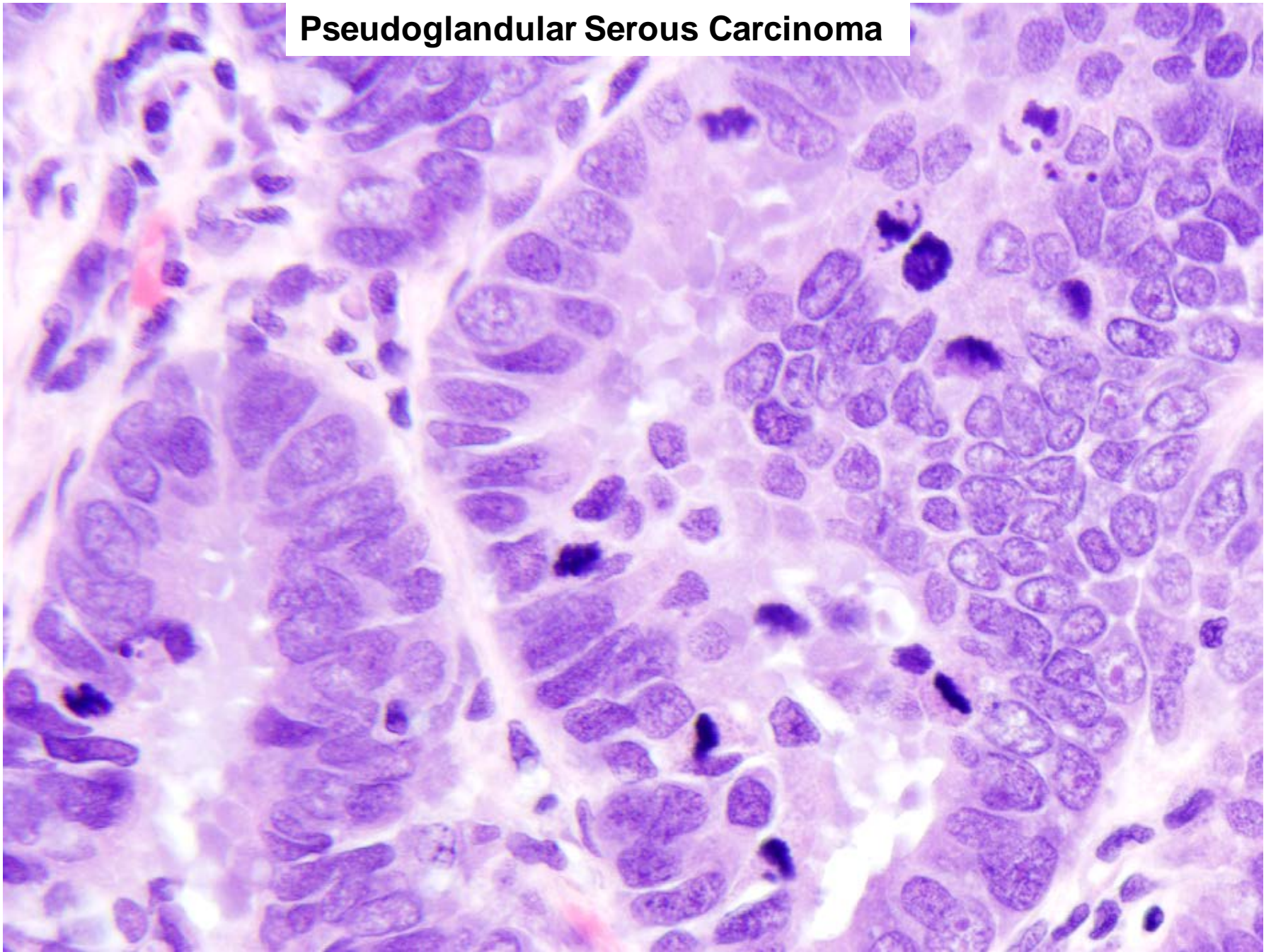


Serous carcinoma
irregular, large, cherry-red



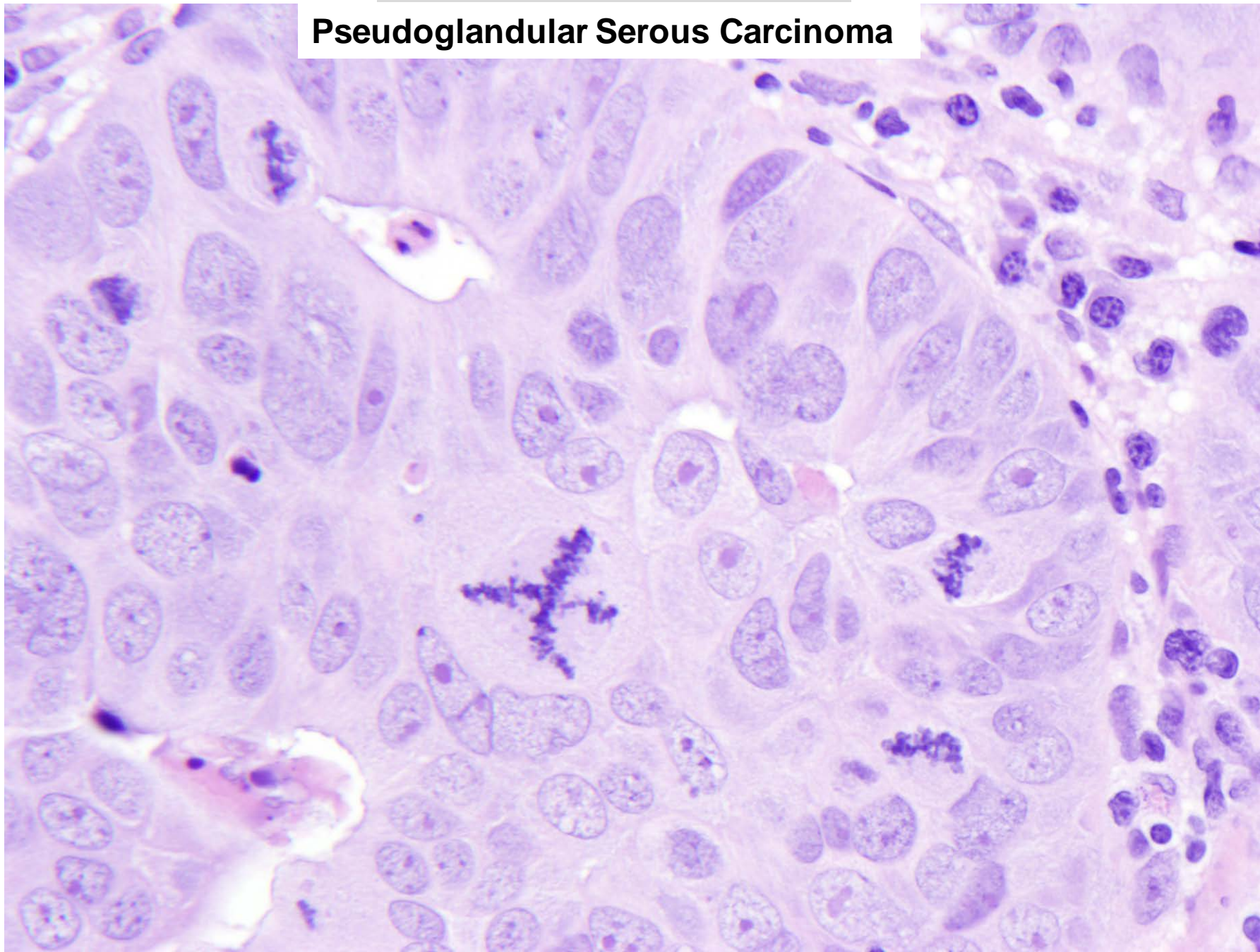
Brisk mitoses

Pseudoglandular Serous Carcinoma



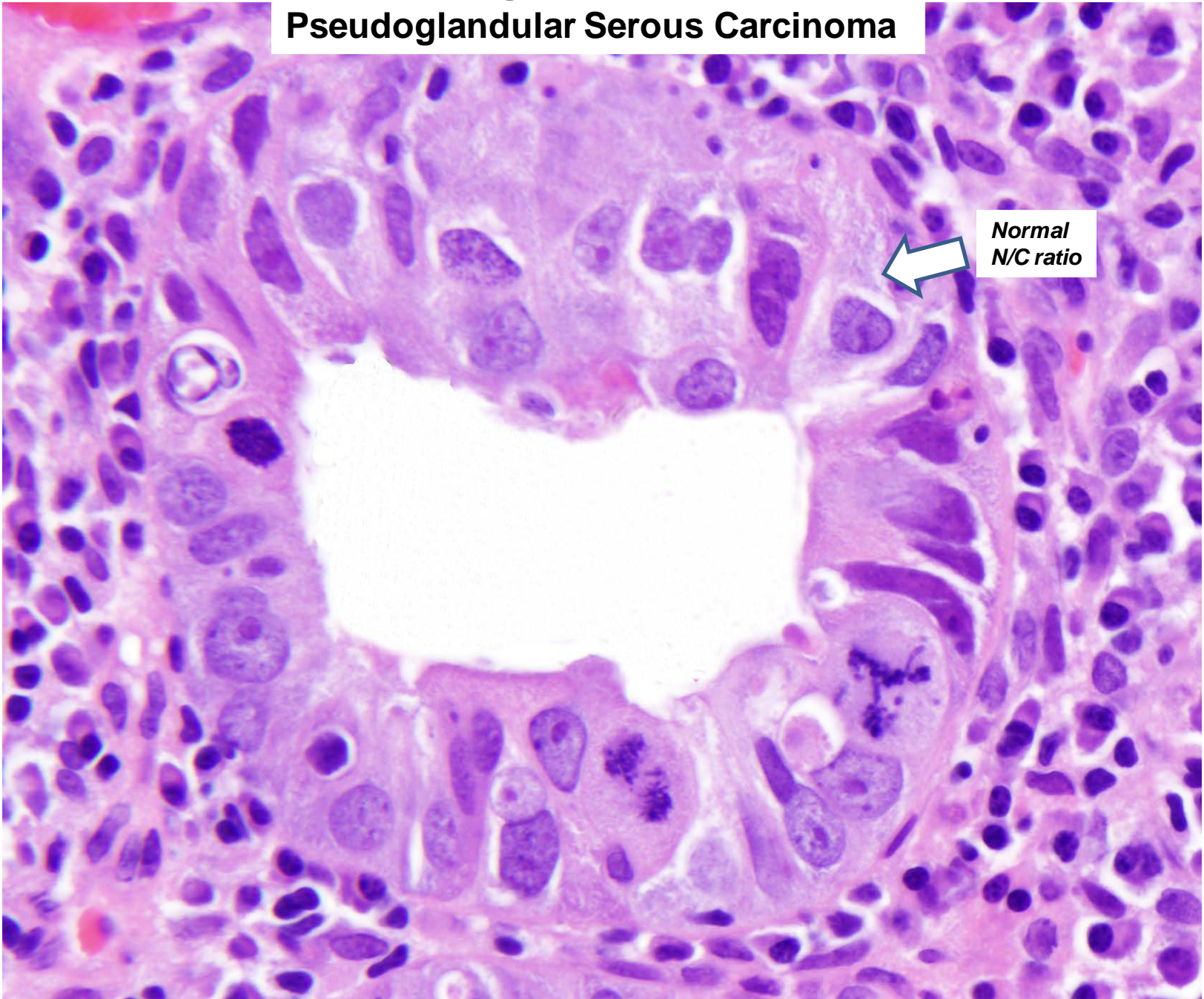
Atypical mitoses

Pseudoglandular Serous Carcinoma



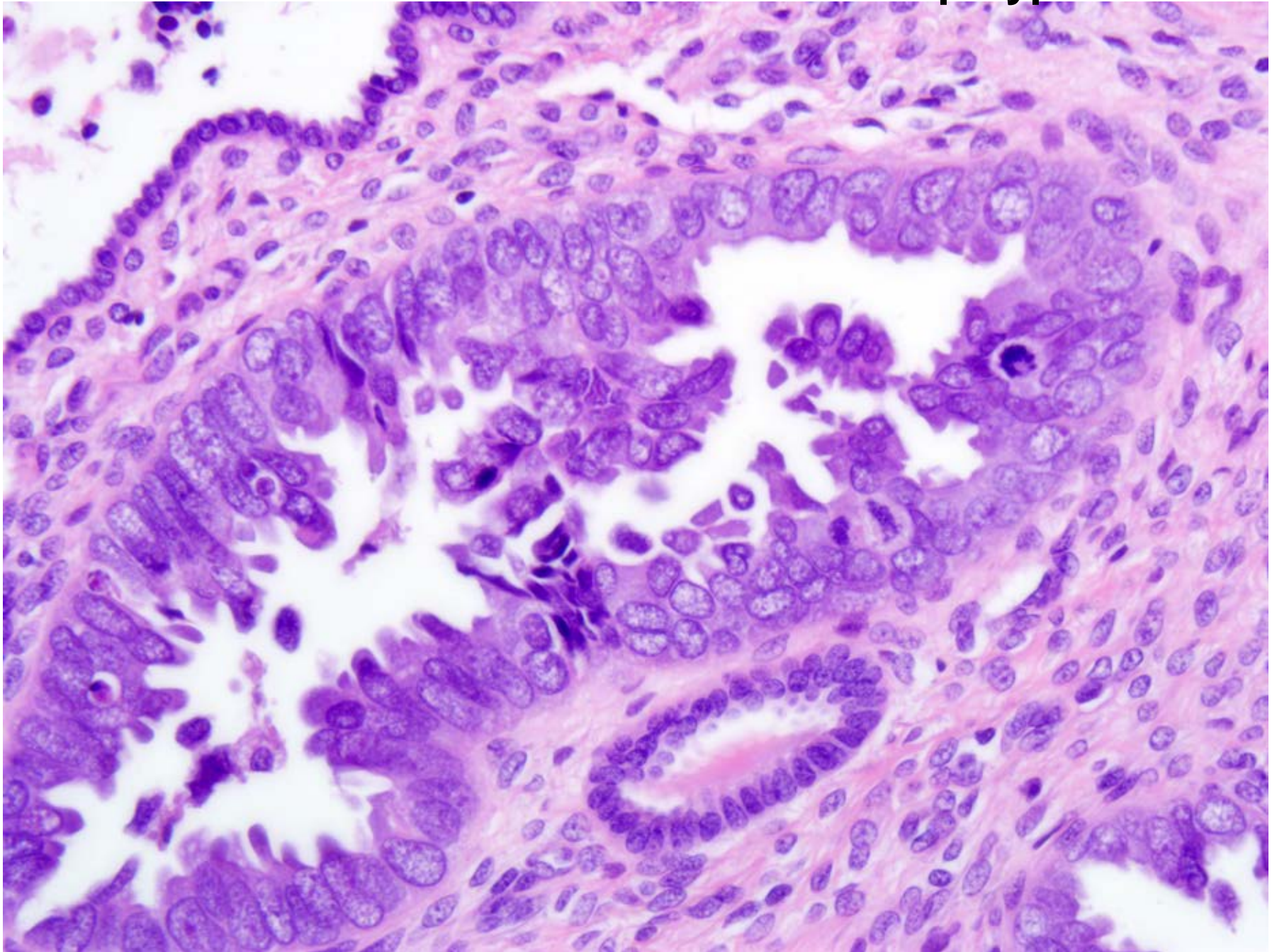
Smudged Chromatin

Pseudoglandular Serous Carcinoma



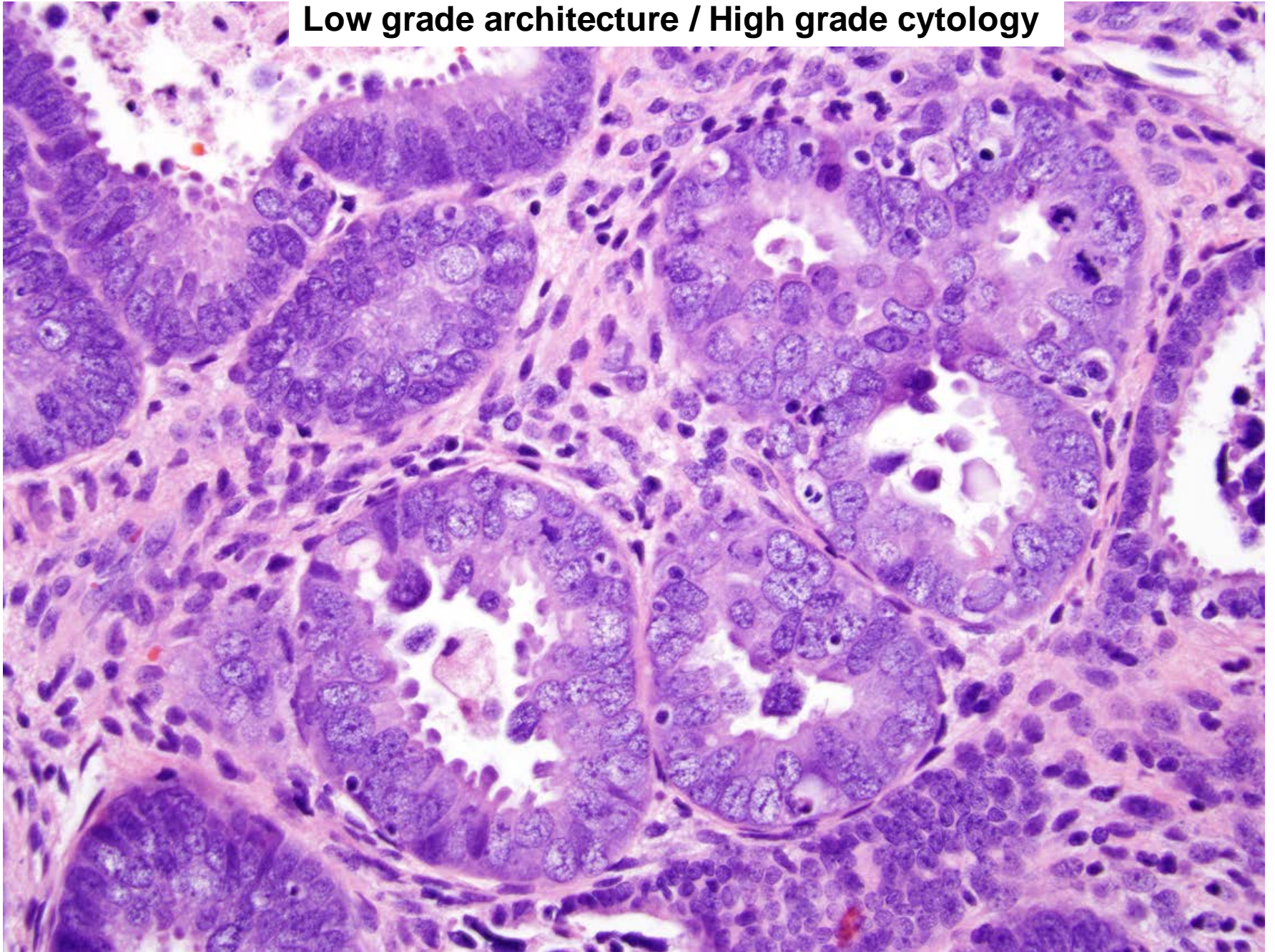
Normal
N/C ratio

Minimal serous carcinoma in a polyp



Minimal serous carcinoma in a polyp

Low grade architecture / High grade cytology

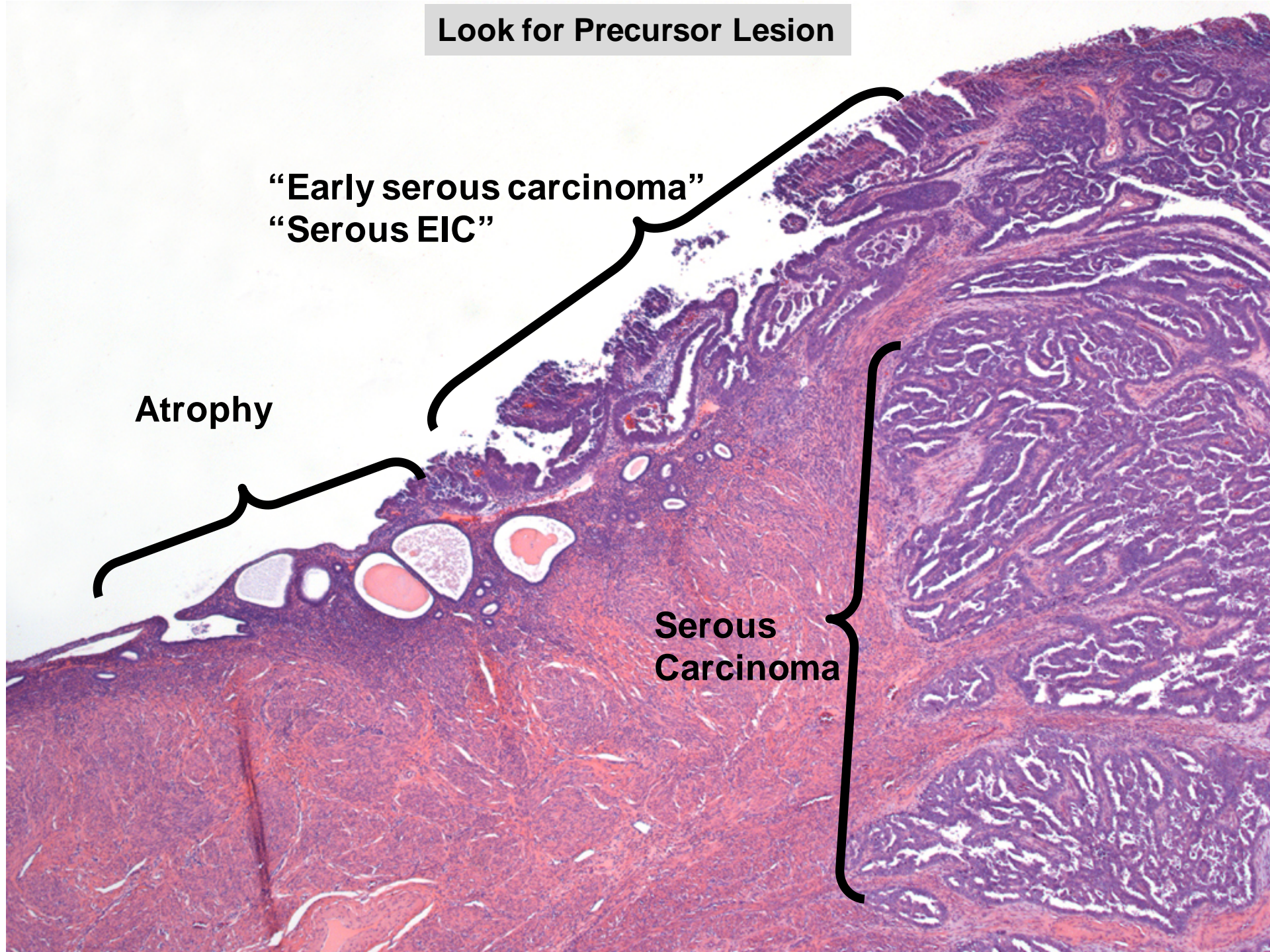


Look for Precursor Lesion

“Early serous carcinoma”
“Serous EIC”

Atrophy

Serous
Carcinoma



Glandular Pattern Uterine Cancer

Adenomyosis

**Myoinvasion by
Pseudoglandular
Serous cancer**

**Architectural
Grade**

Low

Low

**Nuclear
Grade**

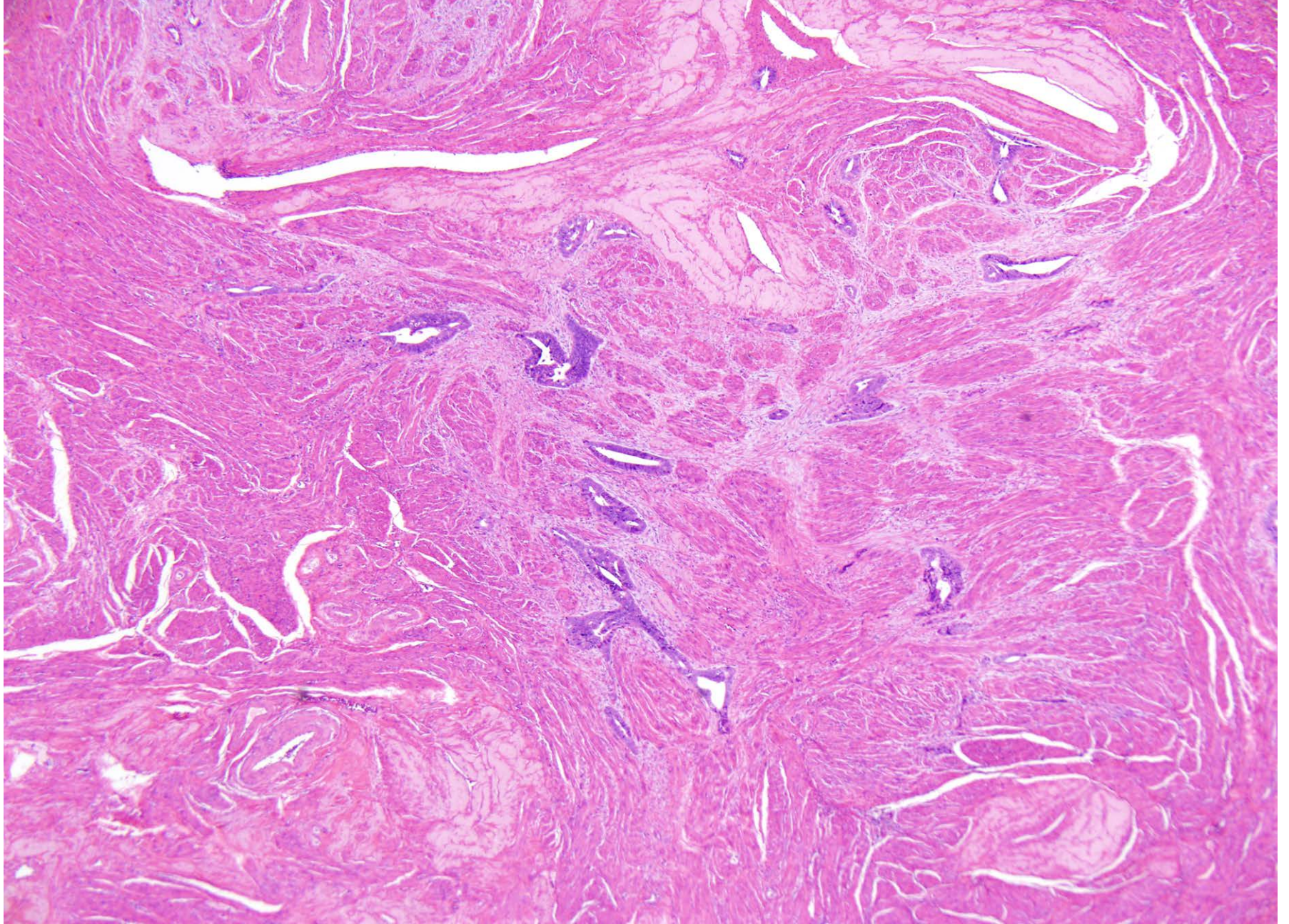
Low

High

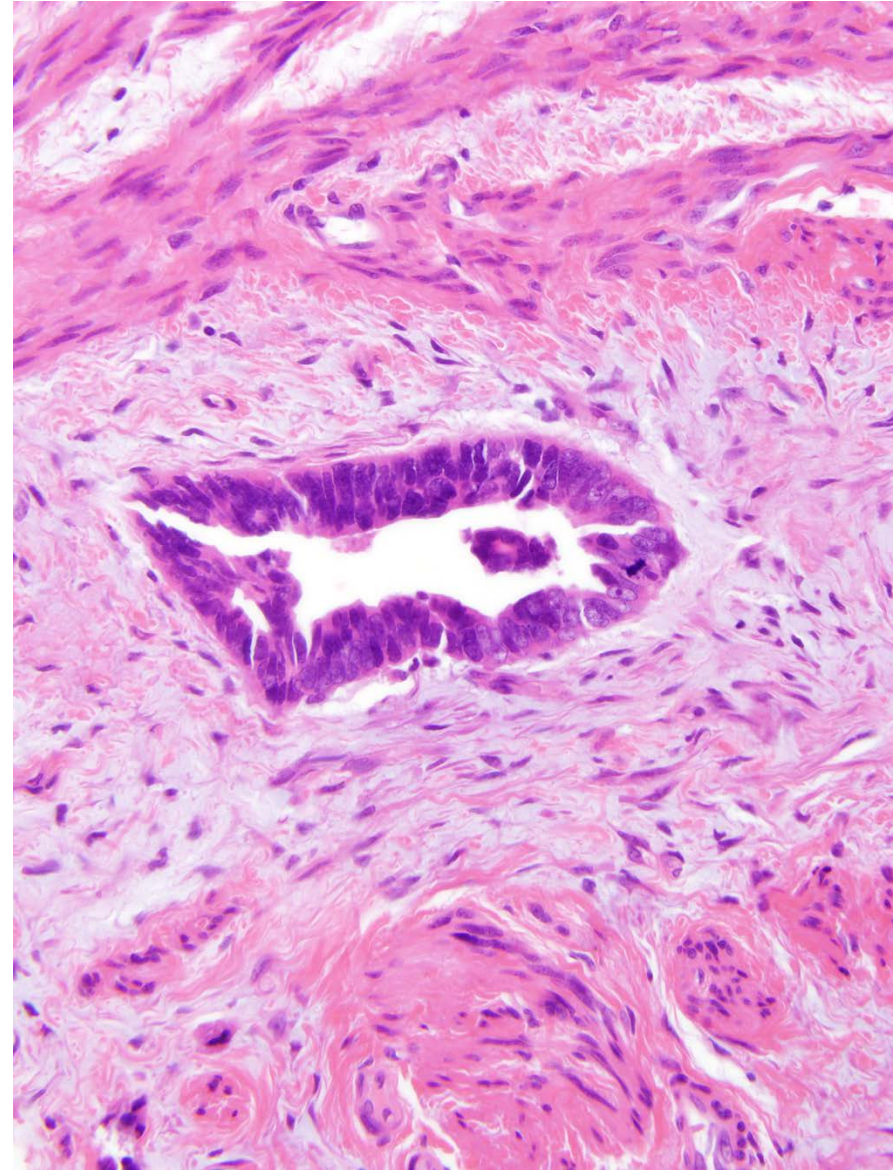
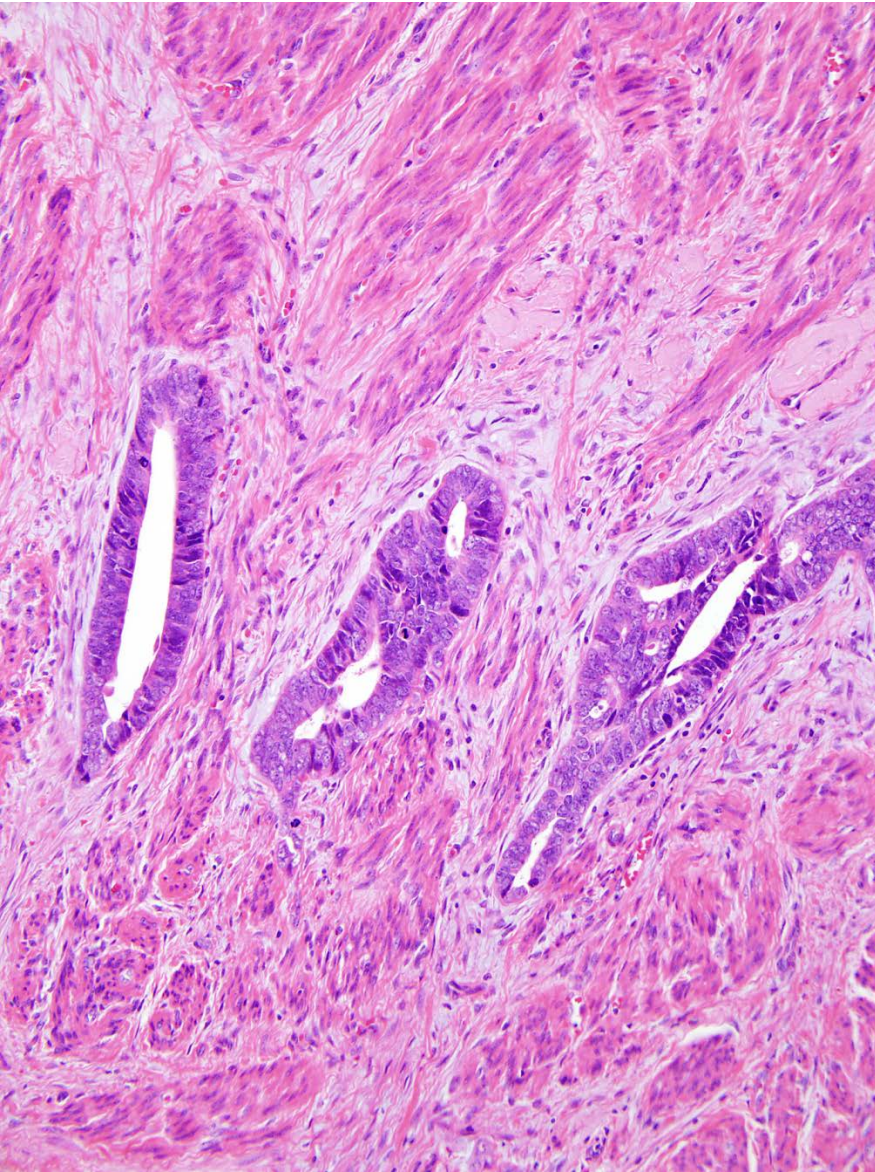
**Discordant architecture
versus nuclear grade**

- **Pleomorphic nuclei**
- **Cherry-red macronucleoli**
- **Smudge cells**
- **Atypical mitoses**

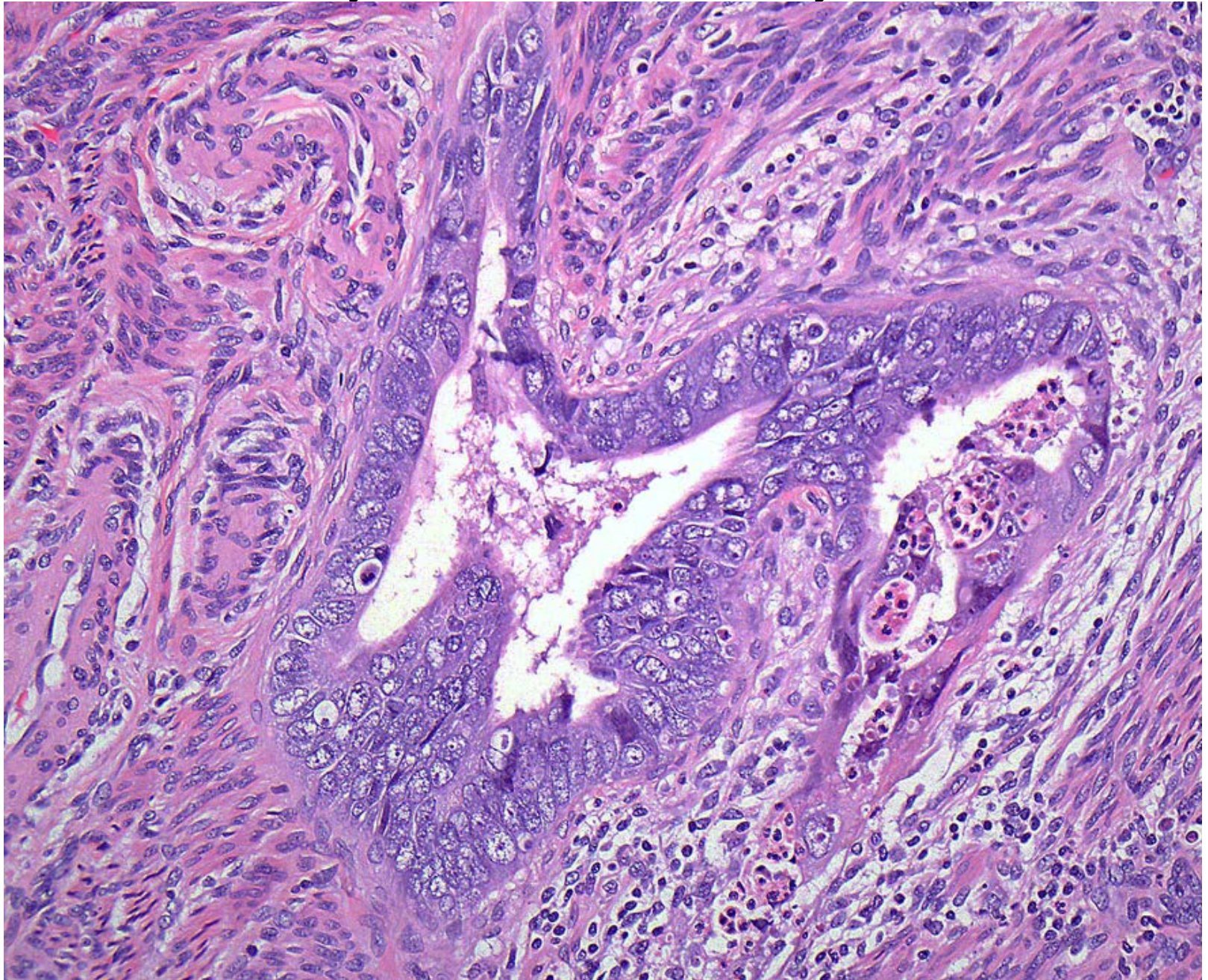
**Pseudoglandular Serous Carcinoma
Myoinvasion mimics adenomyosis**



Pseudoglandular Serous Carcinoma Myoinvasion mimics adenomyosis



**Pseudoglandular Serous Carcinoma
Myoinvasion mimics adenomyosis**



Glandular Pattern of Uterine Cancer

Grade 1 Endometrioid

Pseudoglandular Serous

Architectural
Grade

Low

Low

Nuclear
Grade

Low

High

p16, p53

Wild type

Aberrant

ER

Diffuse, strong

Variable

p53 IHC Interpretation in GYN Serous Carcinoma

Pattern of p53 IHC stain

p53 gene mutation

Strong/diffuse (>60% cells)



90 %

Completely negative



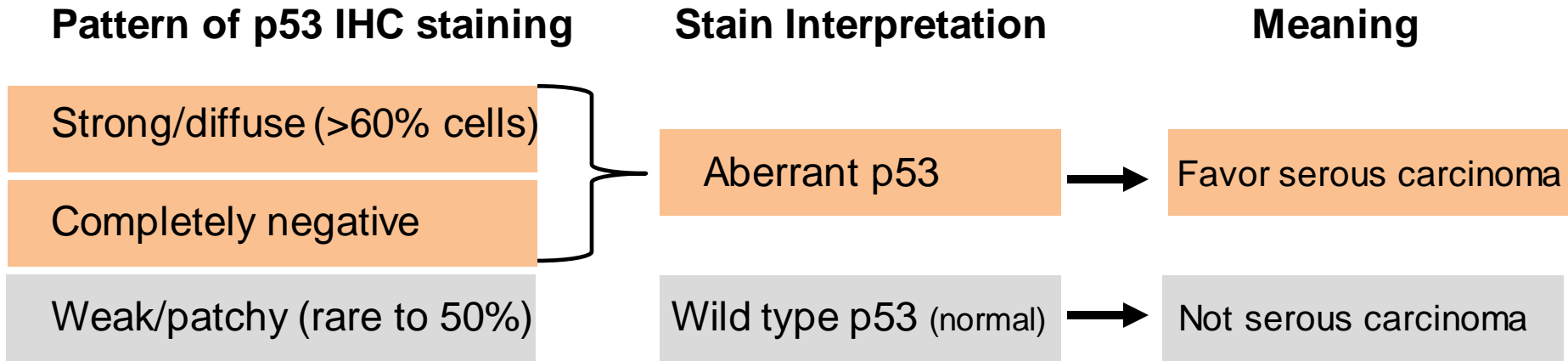
88 %

Weak/patchy (rare to 50%)



20 %

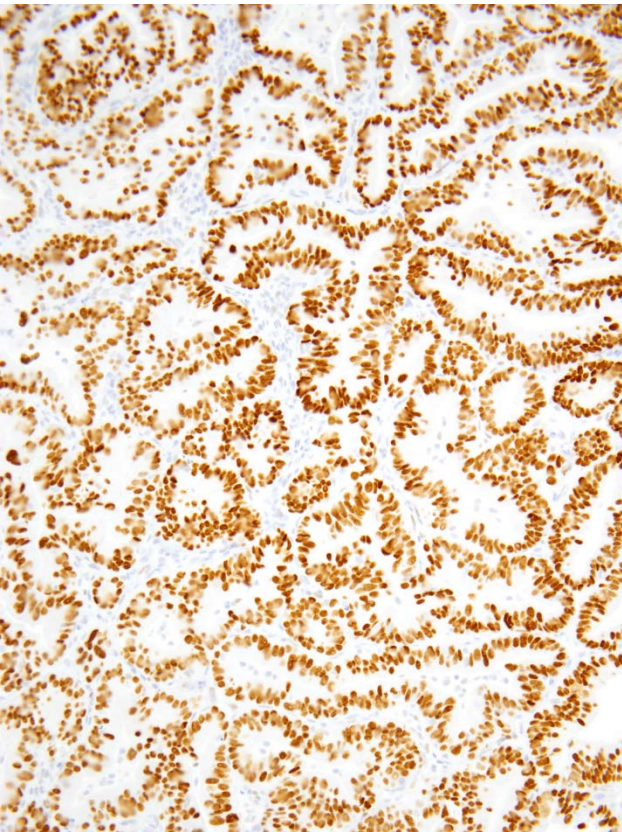
p53 IHC Interpretation in GYN Serous Carcinoma



p53 interpretation in GYN Serous Carcinoma

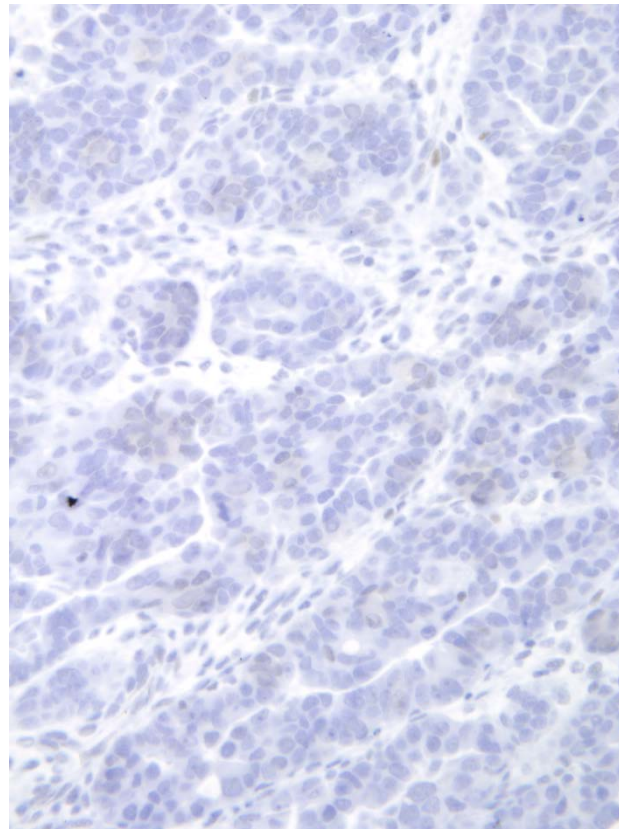
Aberrant p53

Favor serous carcinoma



Aberrant p53

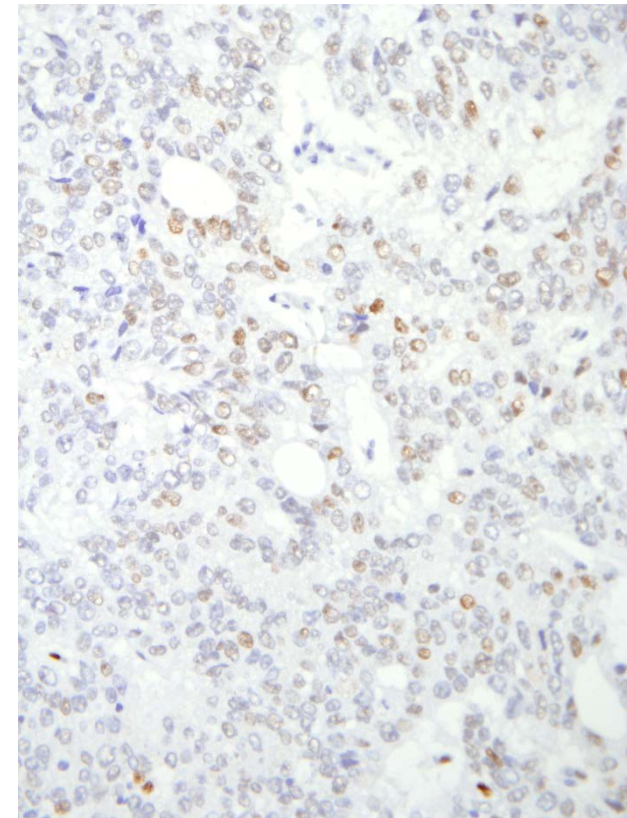
Favor serous carcinoma



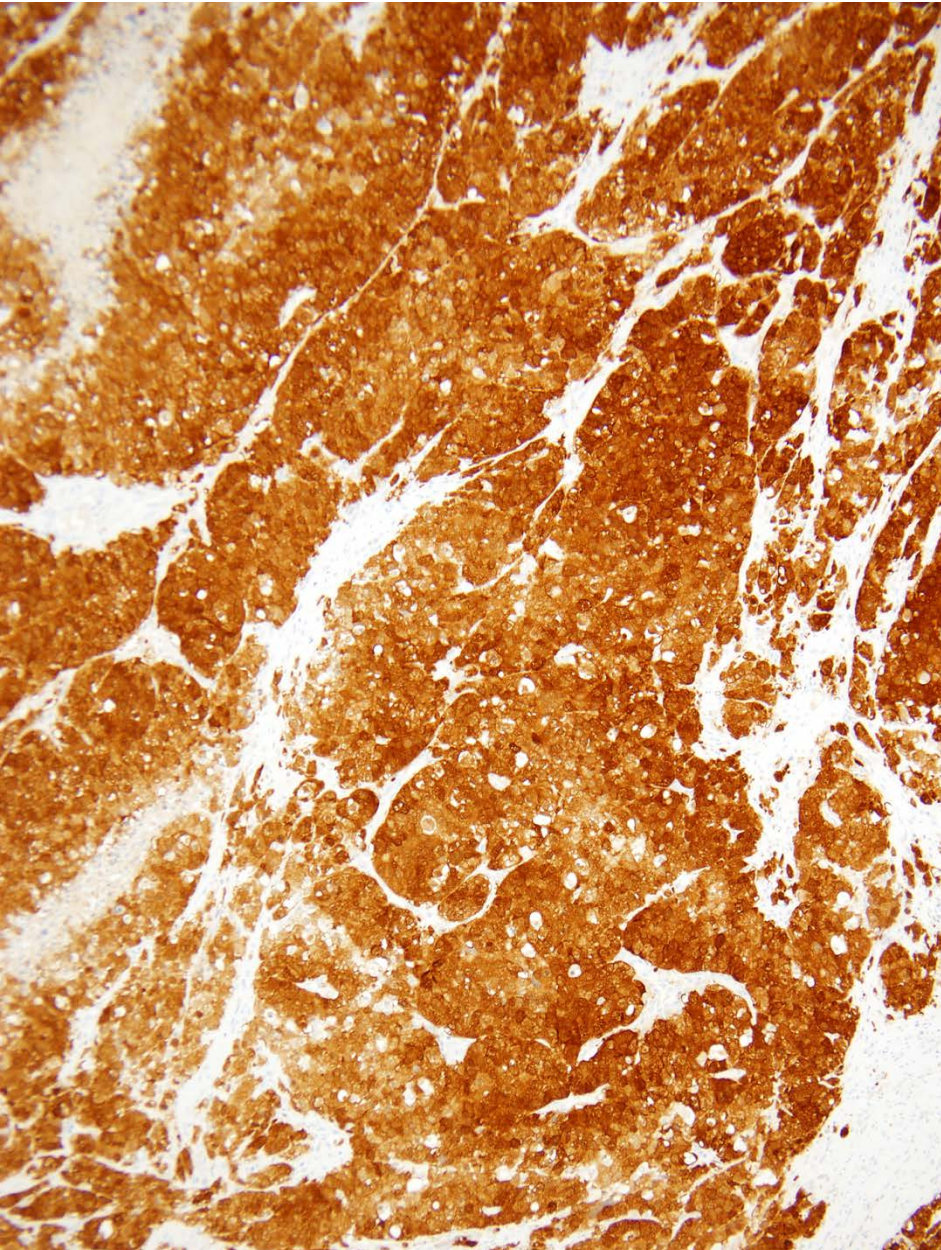
Check for internal control

Wild type p53

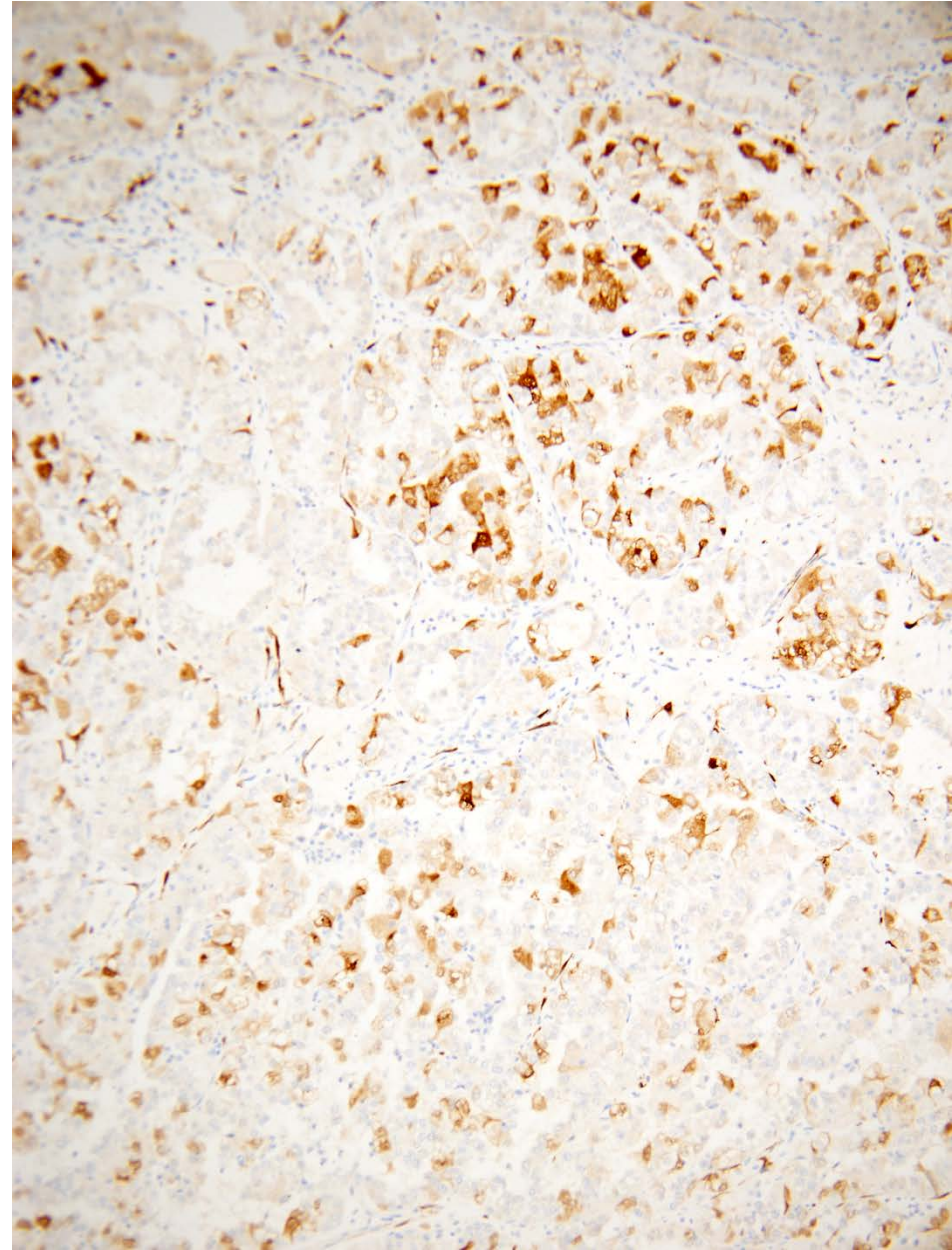
Not serous carcinoma



Diffuse / strong p16
Favor serous carcinoma

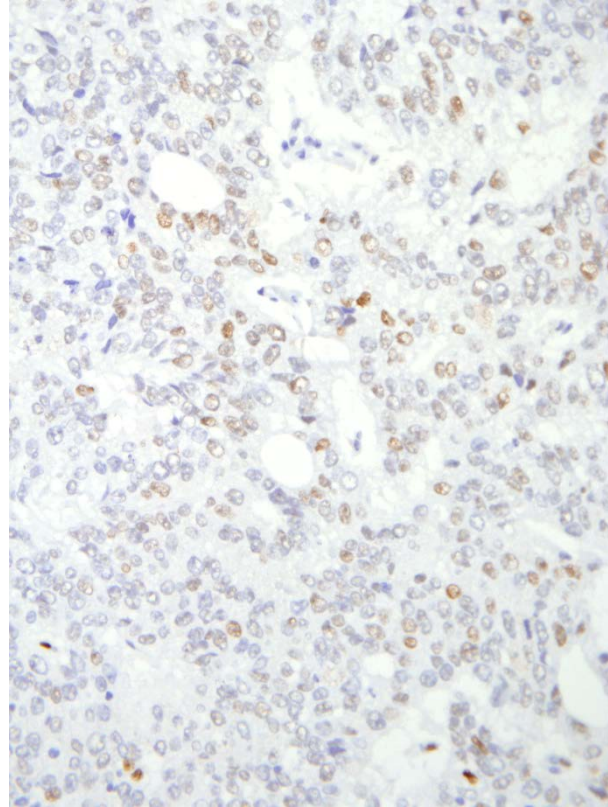
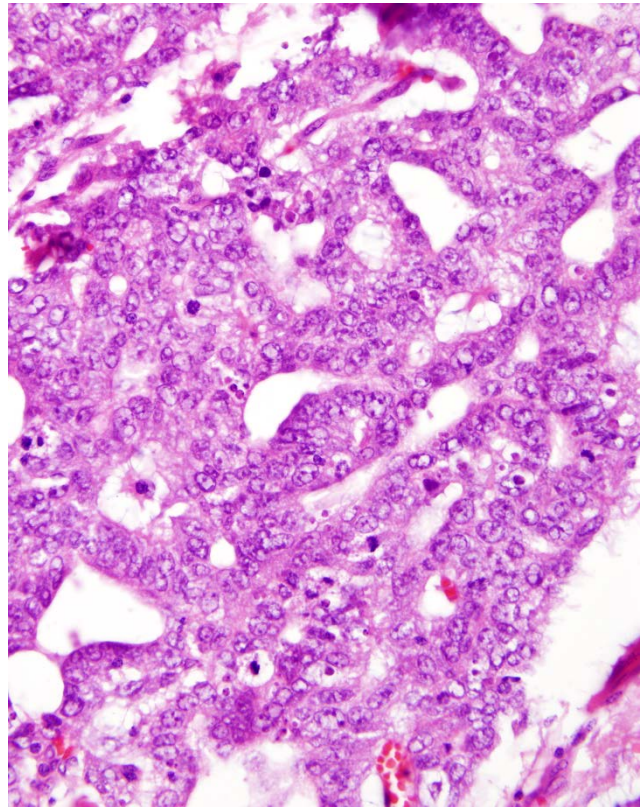


Patchy p16
Not in favor of serous carcinoma

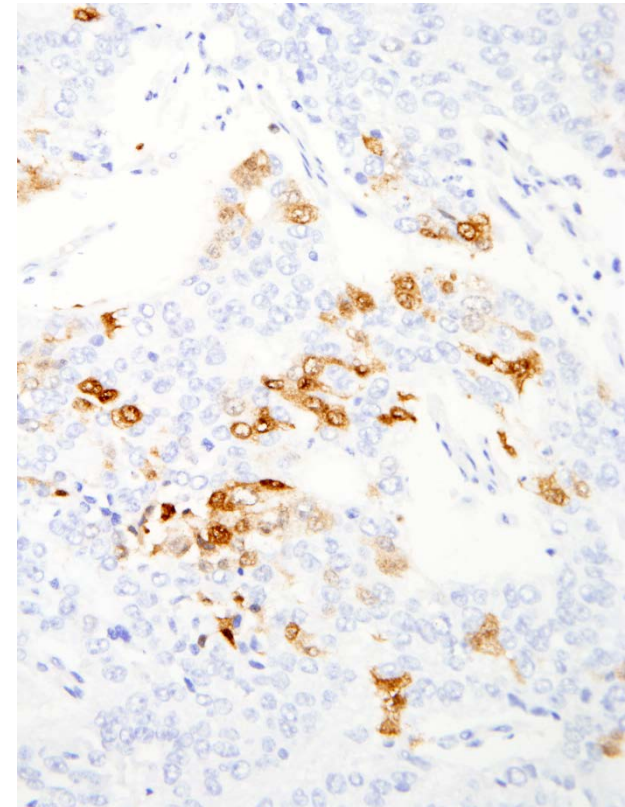


Endometrioid Adenocarcinoma, grades 1 & 2

p53
Wild type

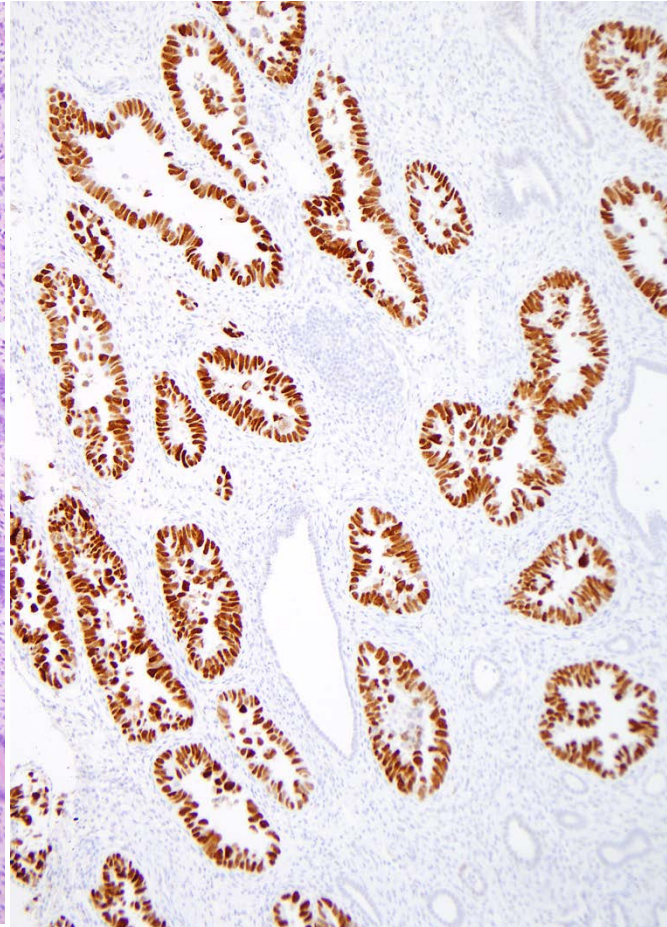
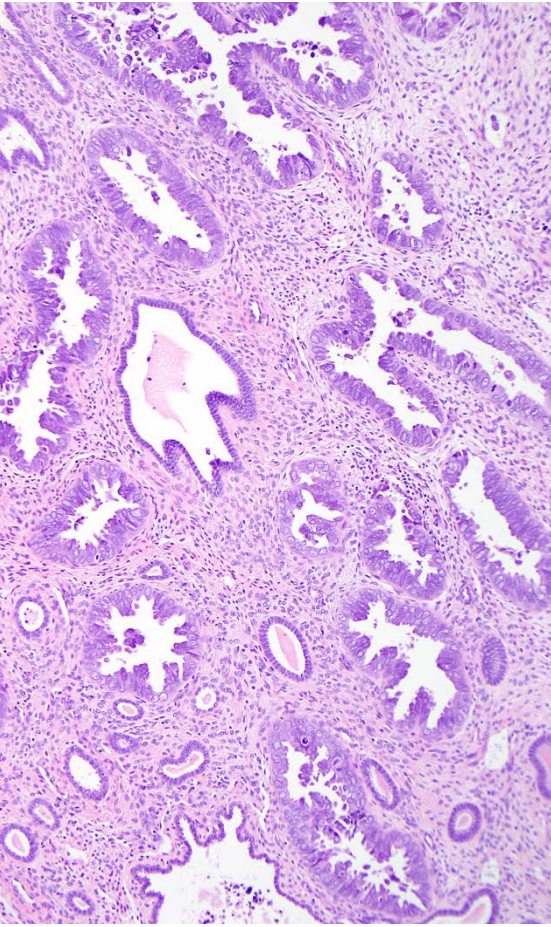


p16
Wild type

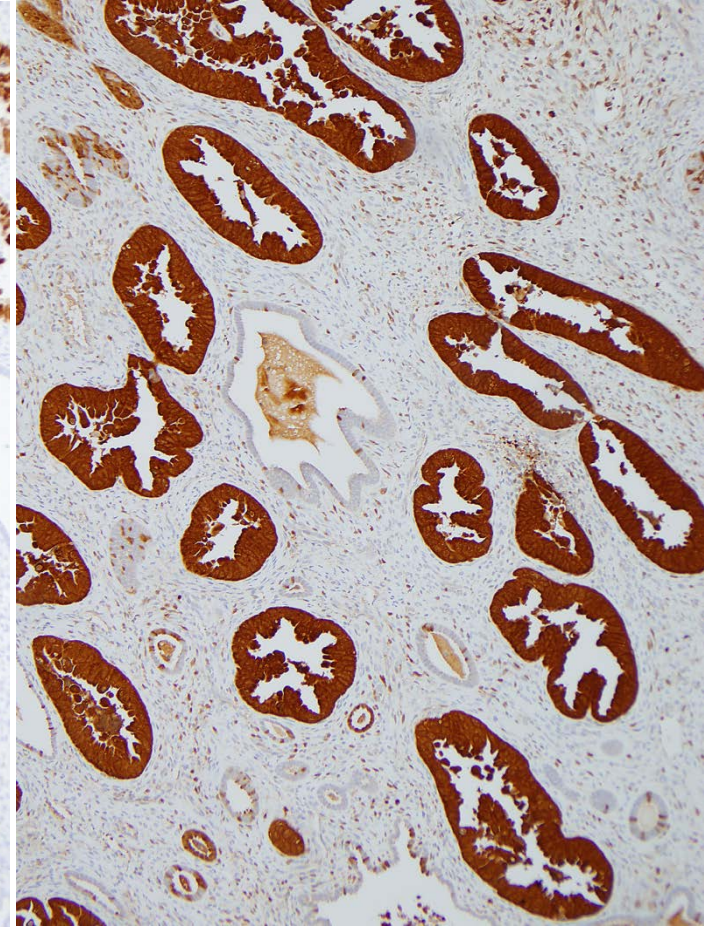


Pseudoglandular serous carcinoma

p53
Diffuse, strong



p16
Diffuse, strong



Pseudo-glandular Serous Carcinoma

Potential Mimics

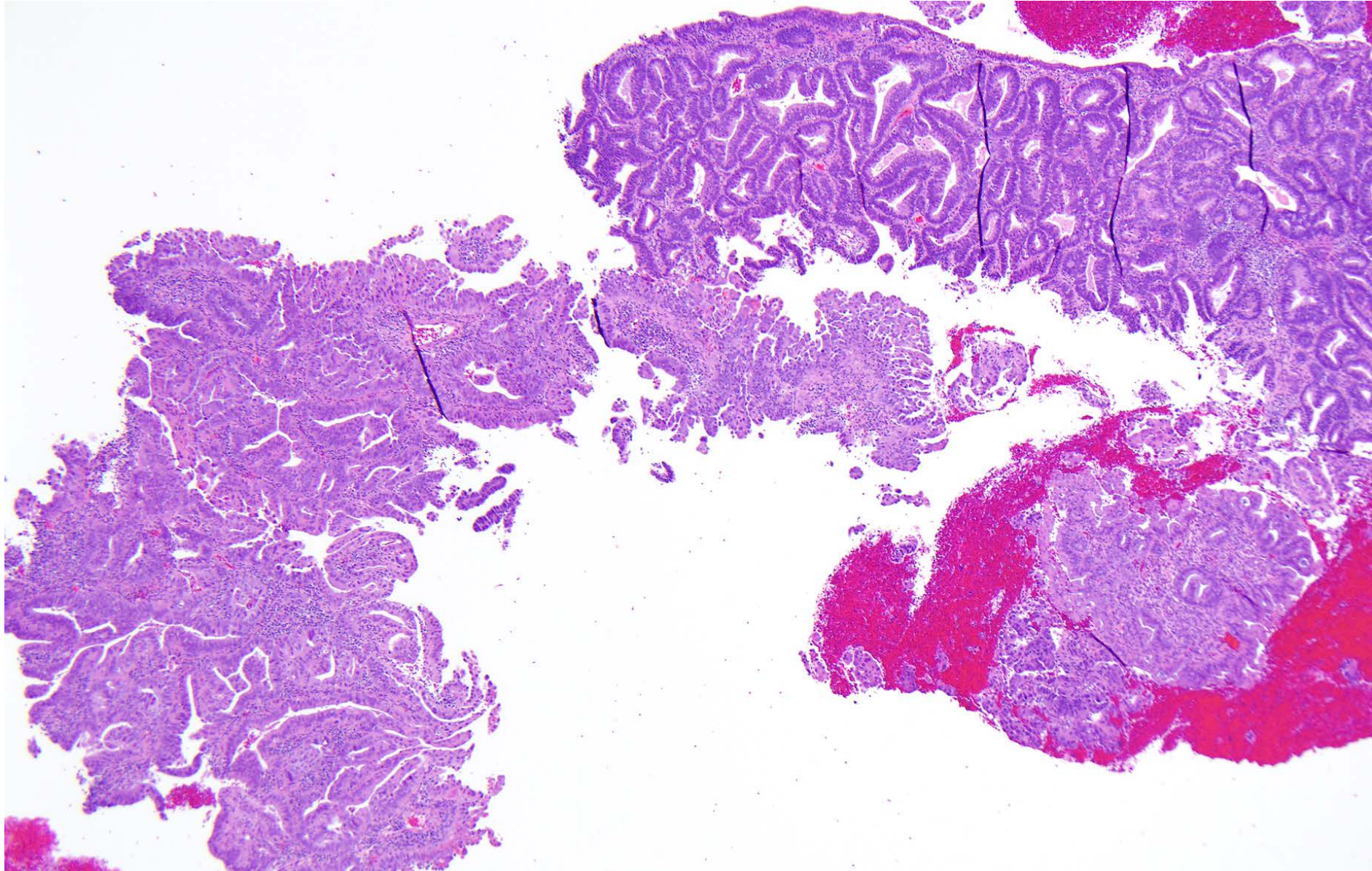
- **G1 or G2 endometrioid adenocarcinoma**
 - **Pure**
 - **Mixed**

- **Adenomyosis**

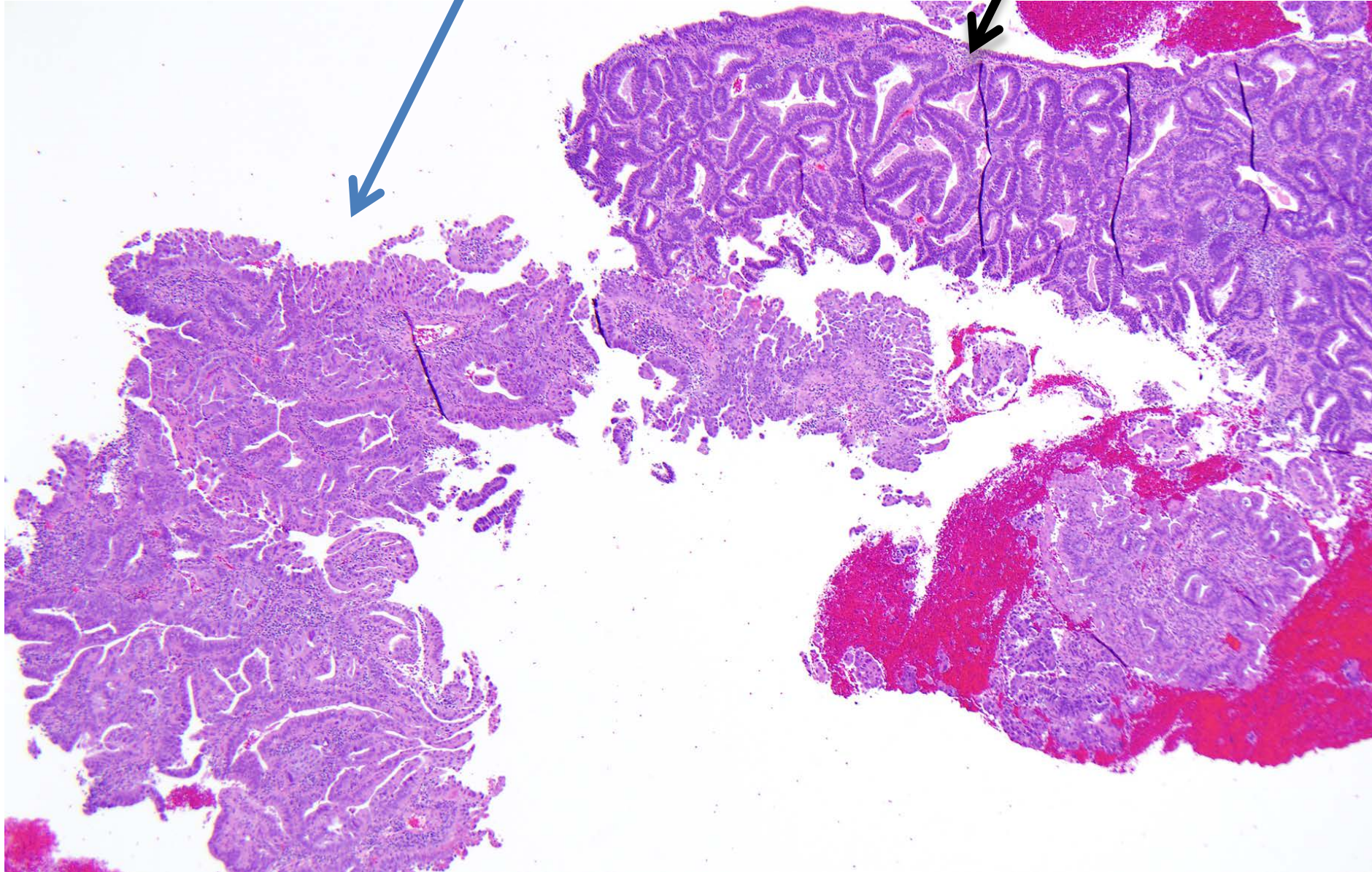
- **Atypical hyperplasia**

- **Polyp with hyperplasia**

Biopsy: Glandular pattern tumor

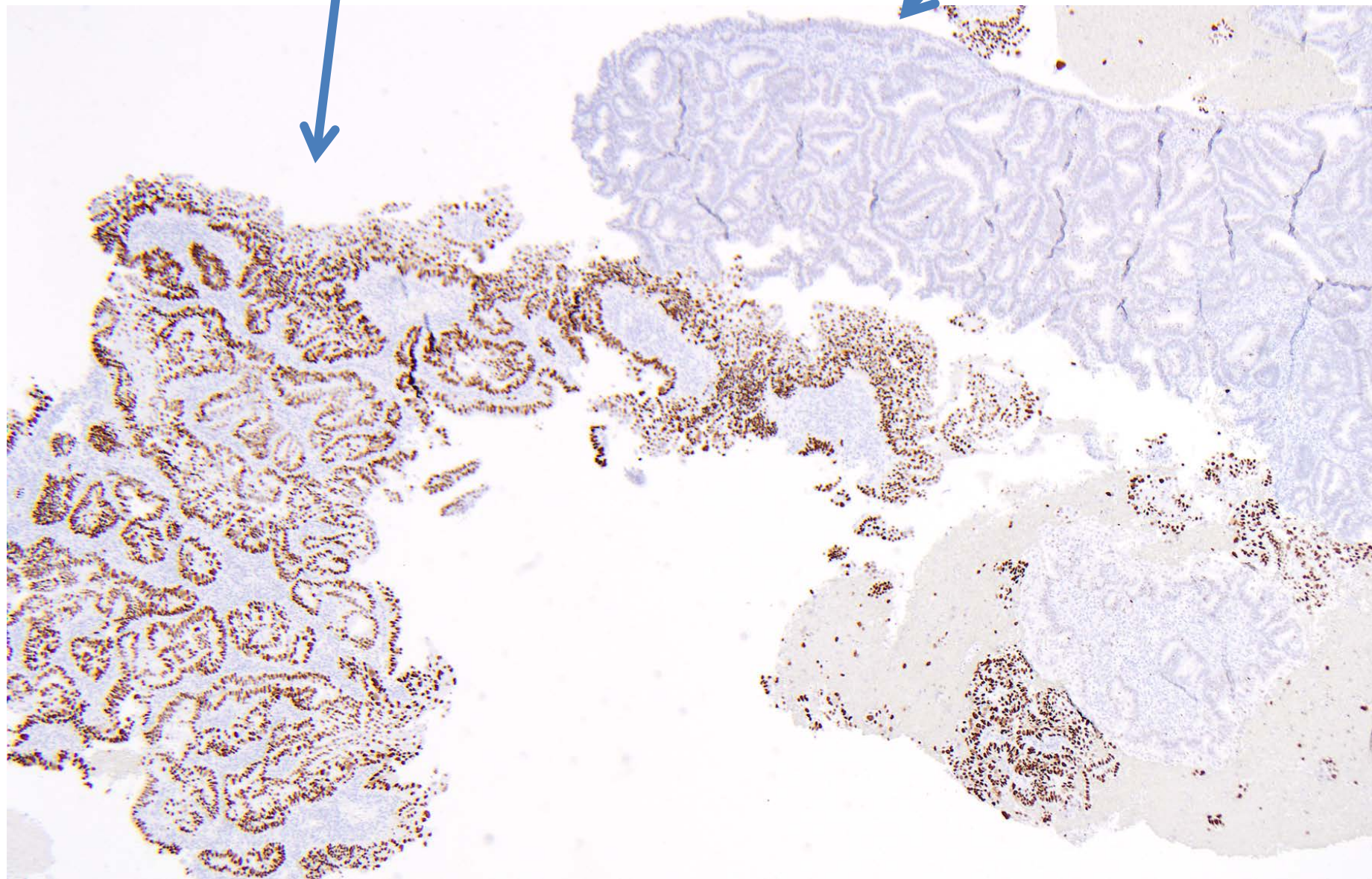


Mixed pseudoglandular serous carcinoma plus grade 1 endometrioid cancer



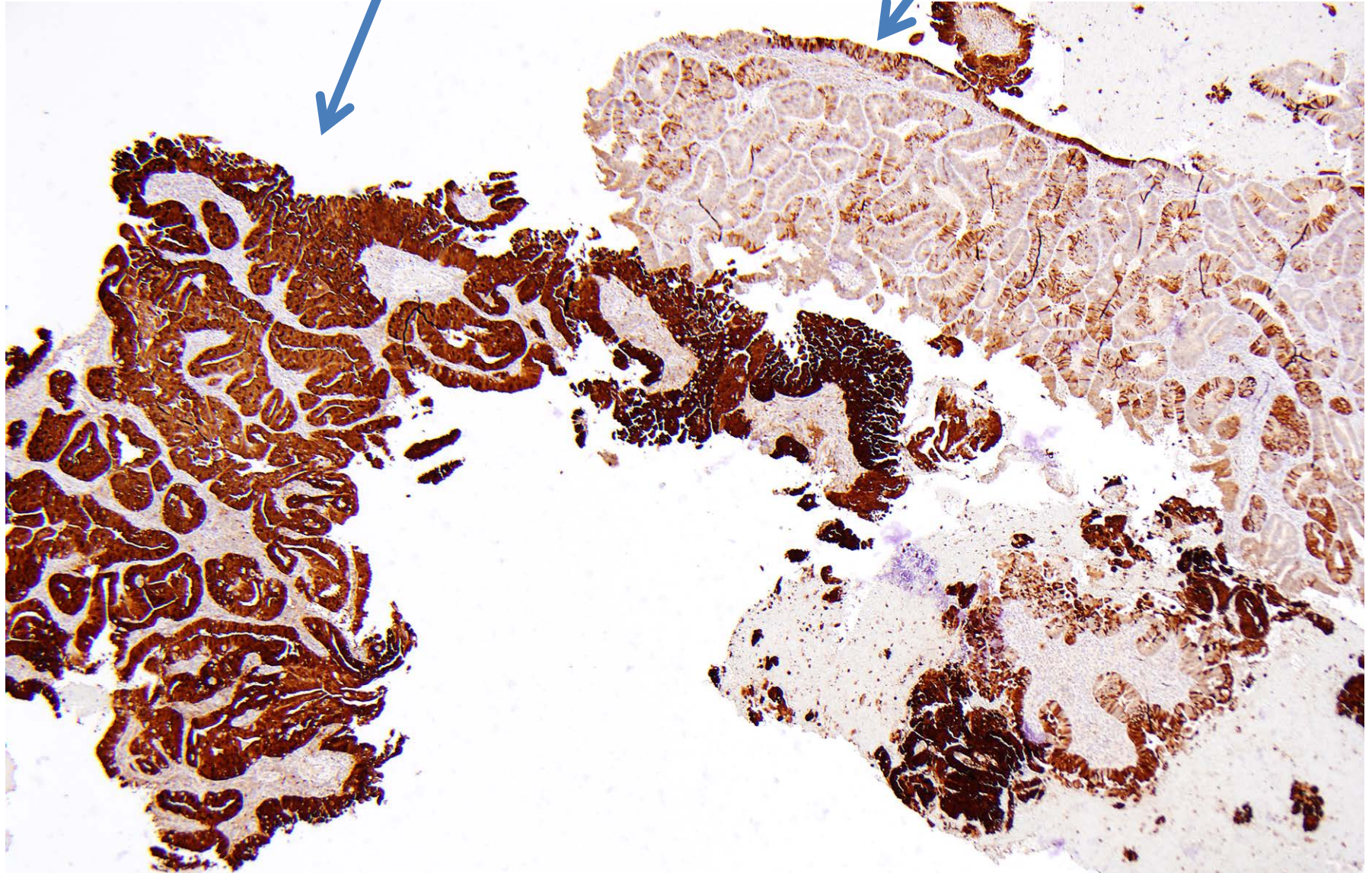
Mixed pseudoglandular serous carcinoma plus grade 1 endometrioid cancer

p53



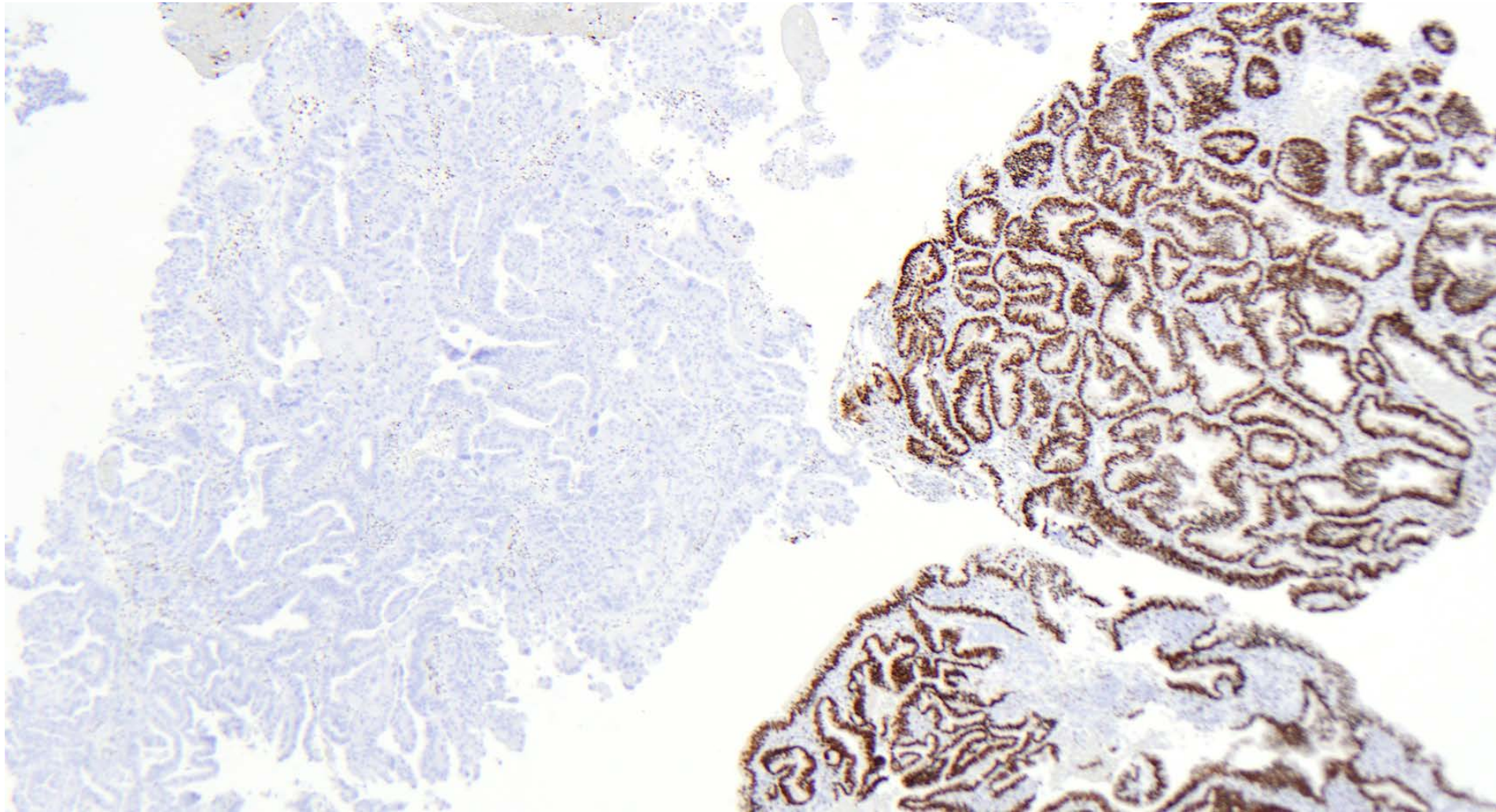
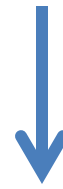Mixed pseudoglandular serous carcinoma plus grade 1 endometrioid cancer

p16



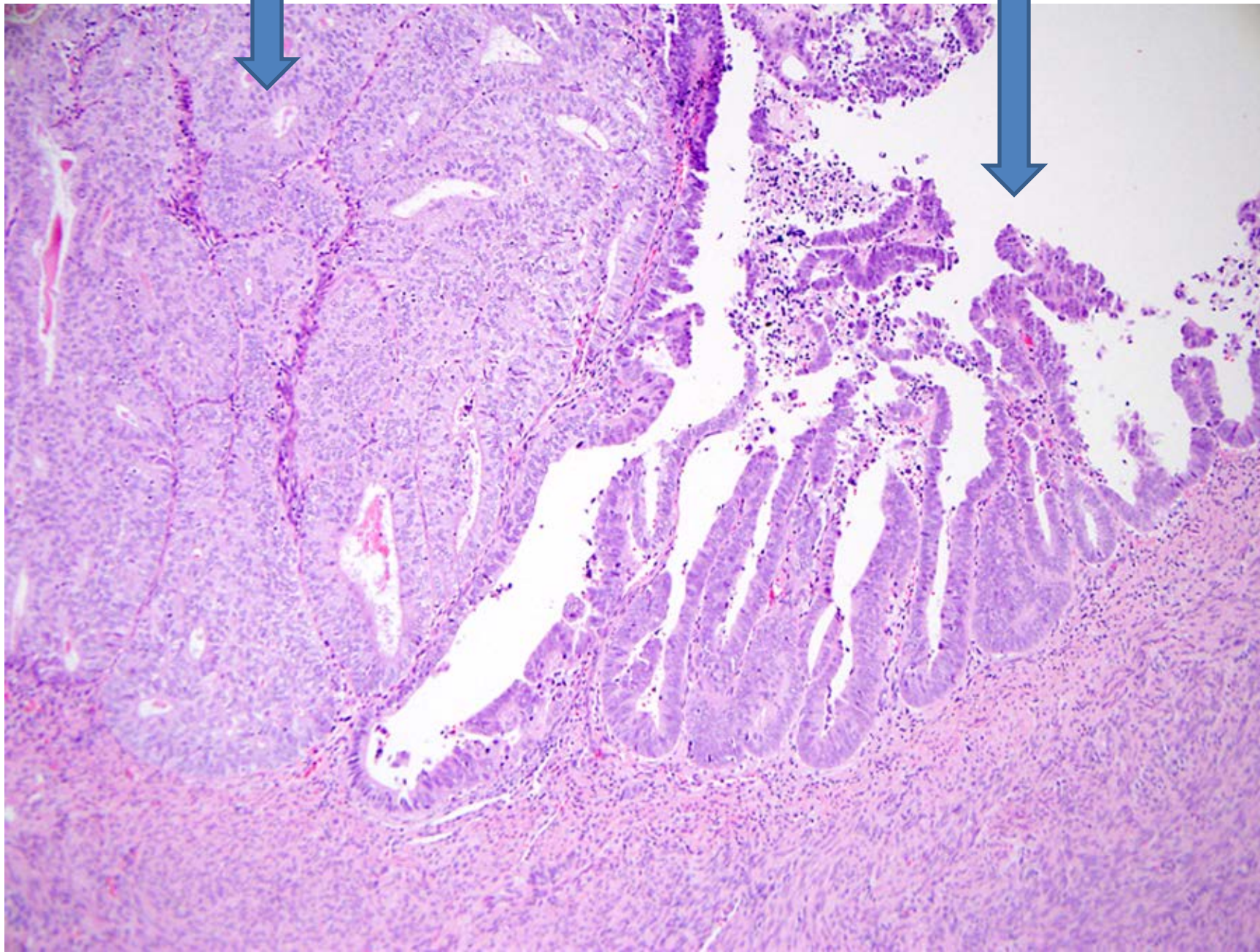
Mixed pseudoglandular serous carcinoma plus grade 1 endometrioid cancer

Estrogen Receptor

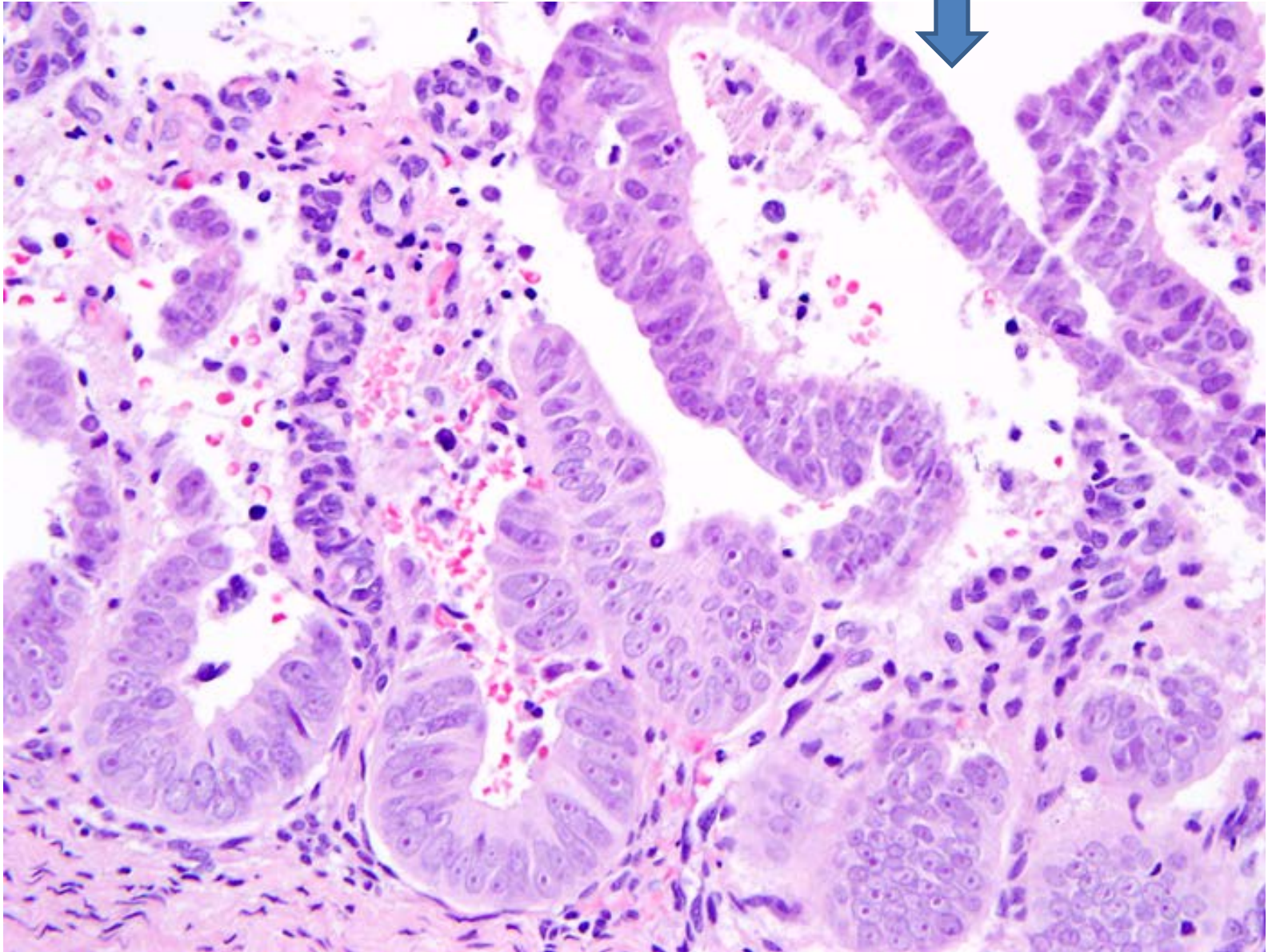


Grade 2 Endometrioid cancer

? Grade 1 Endometrioid cancer



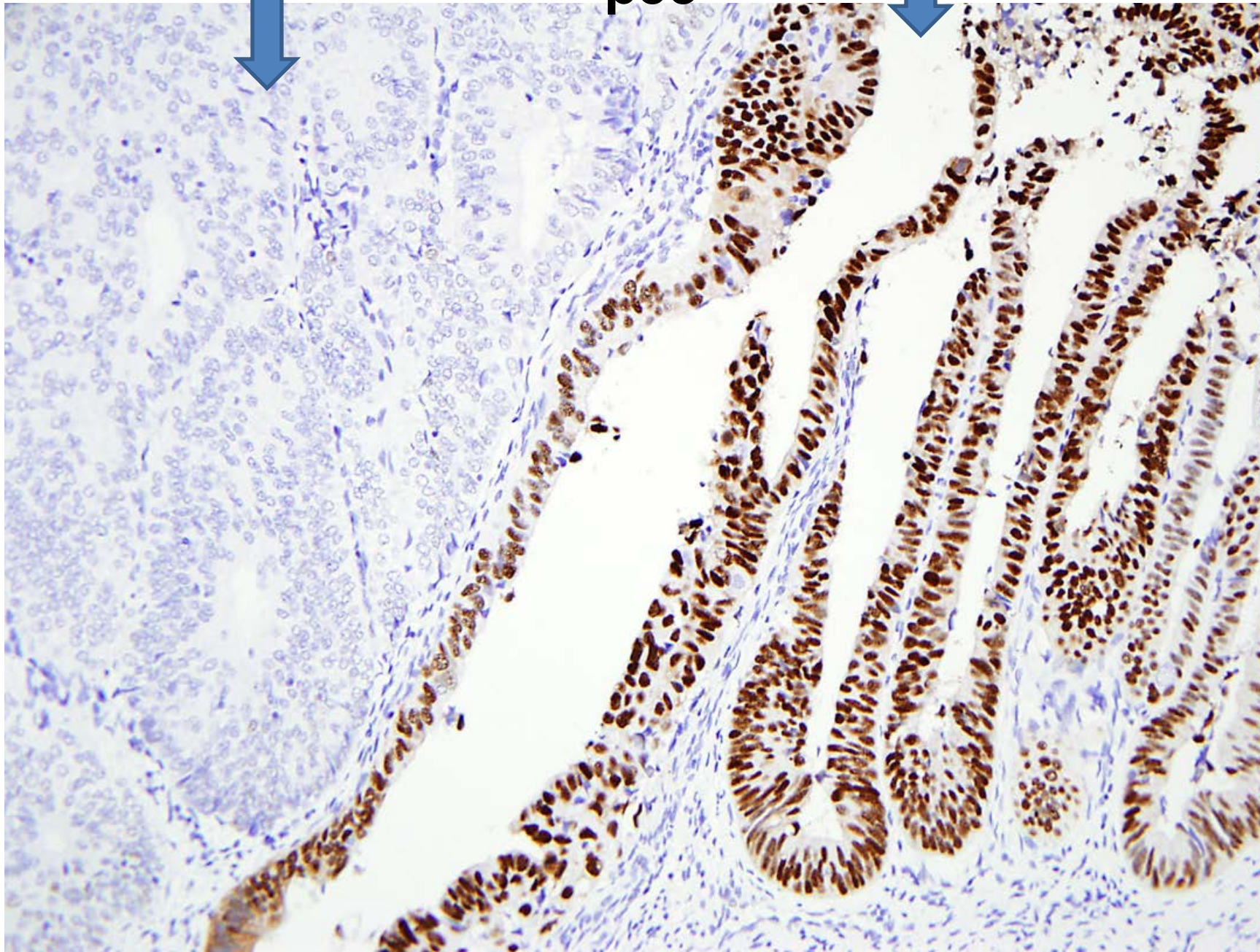
? Grade 1 Endometrioid cancer



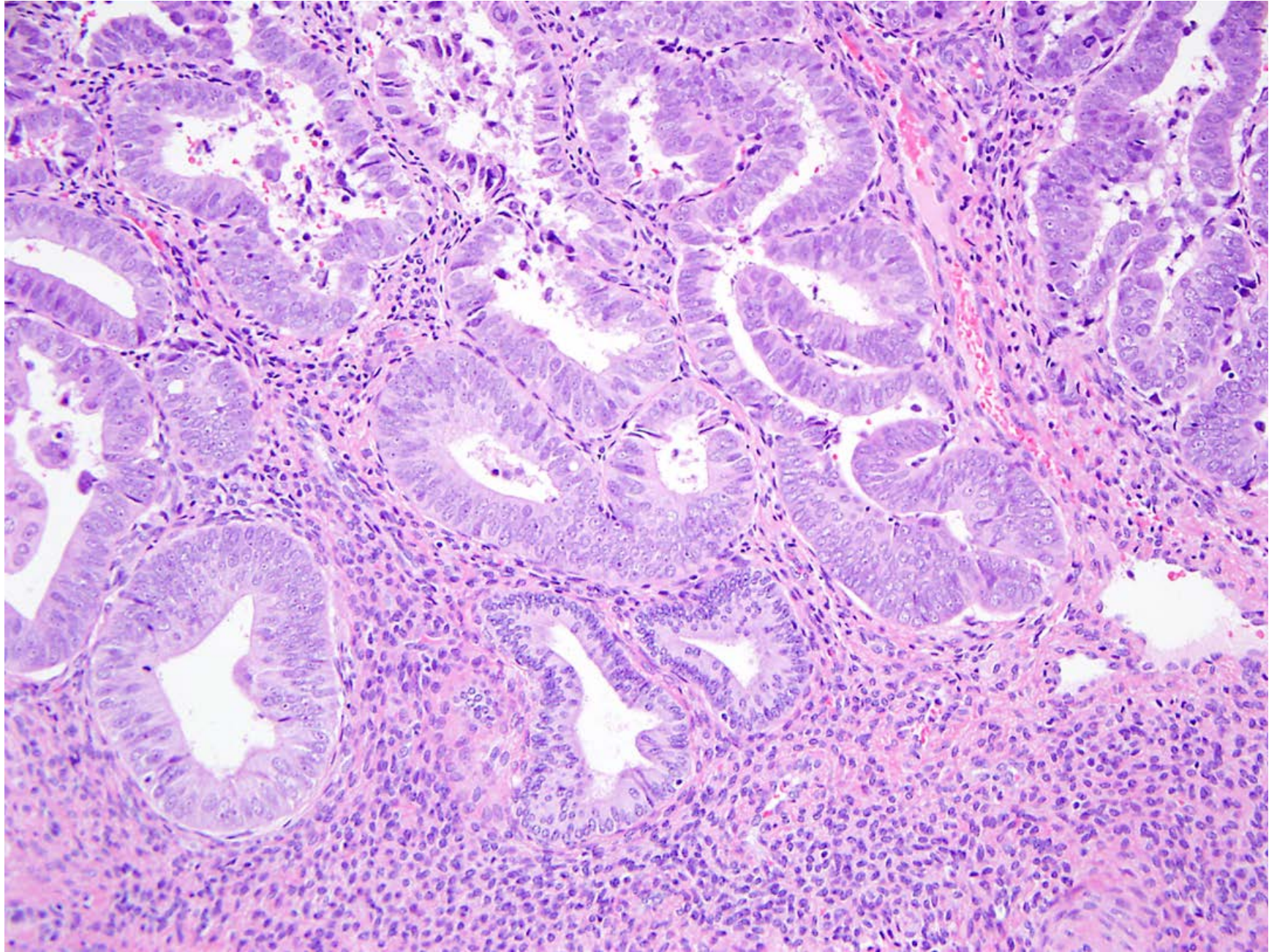
Grade 2 Endometrioid cancer

Serous carcinoma, grade 3

p53

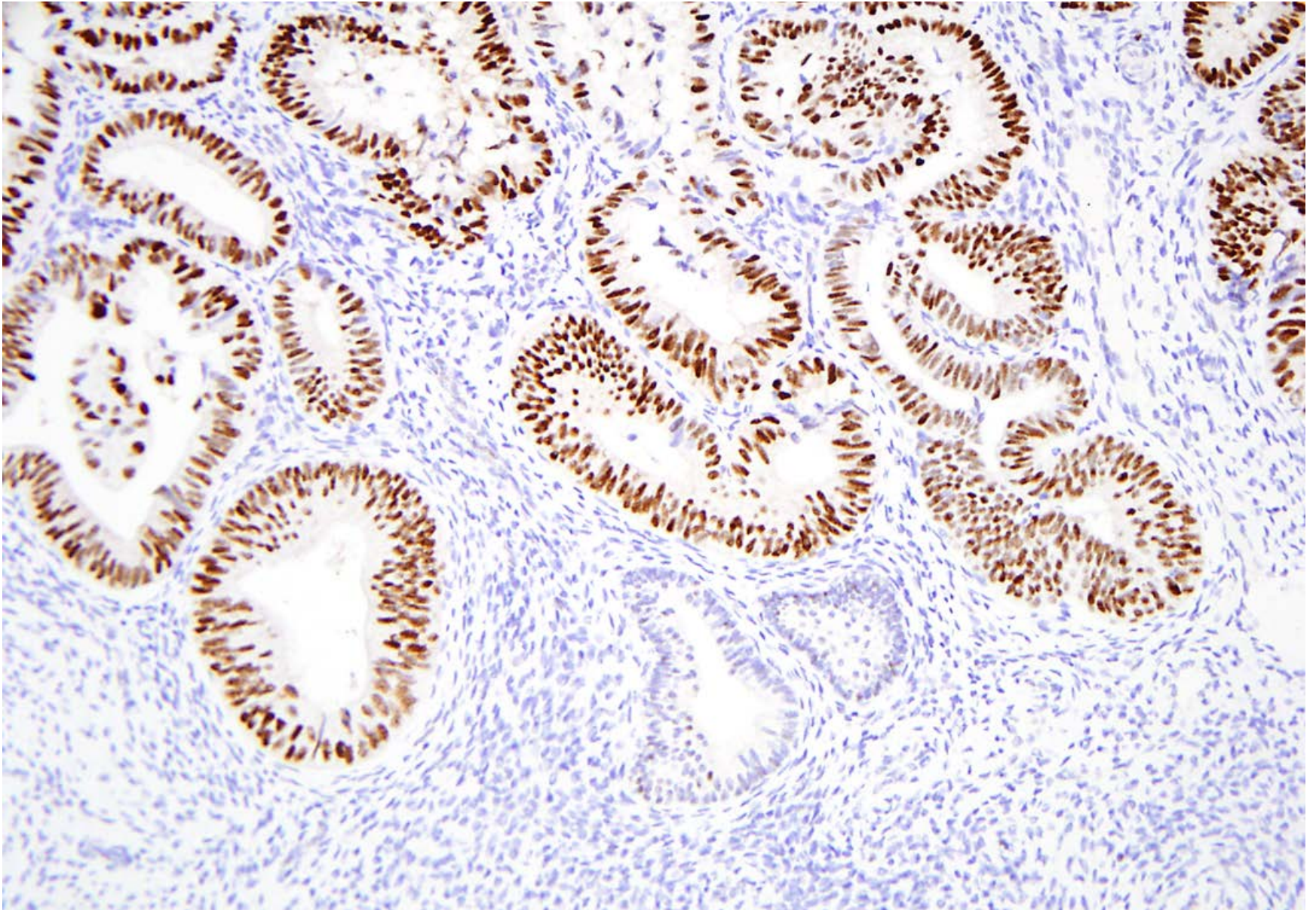


Atypical Hyperplasia ?

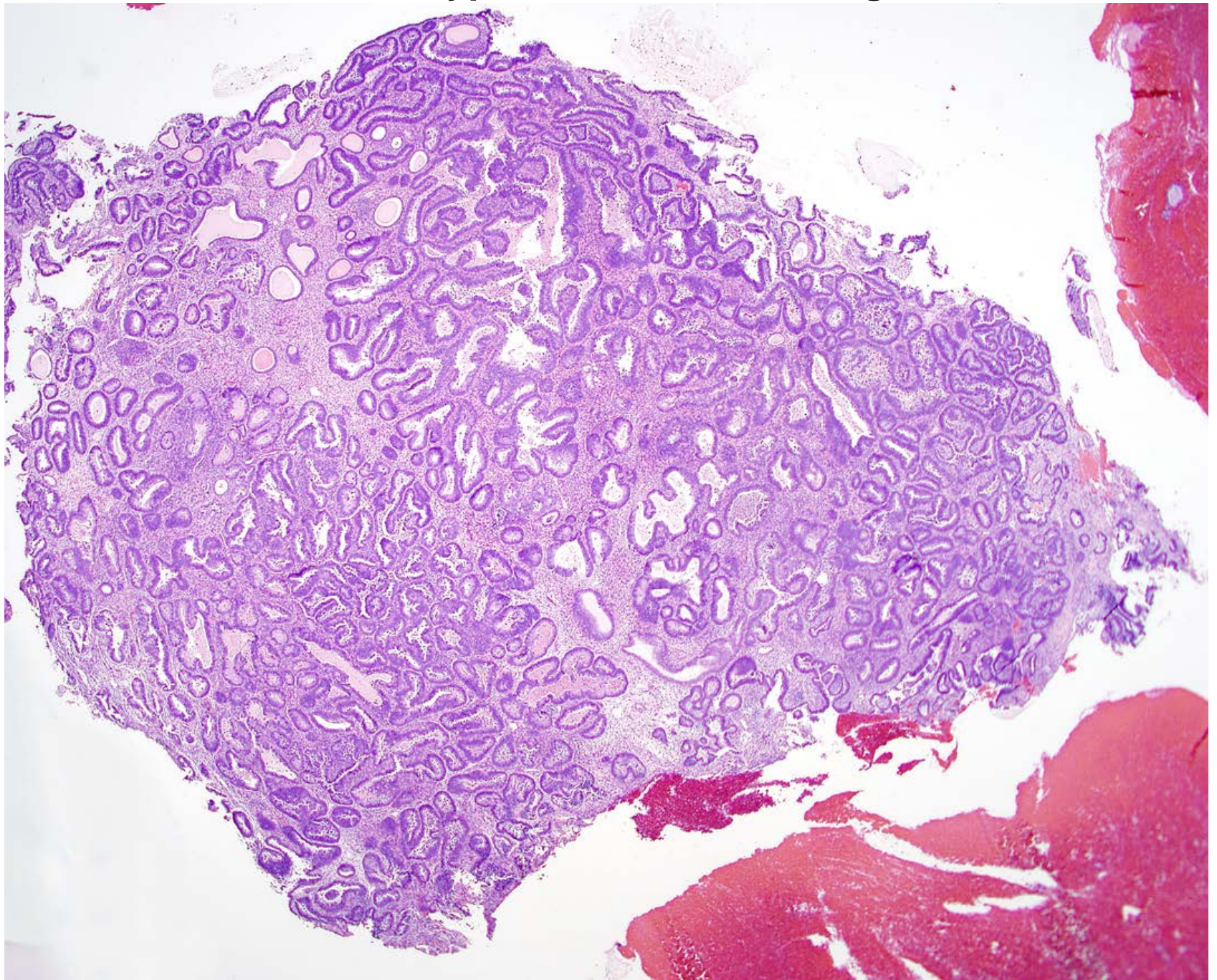


Pseudoglandular Serous Carcinoma

p53

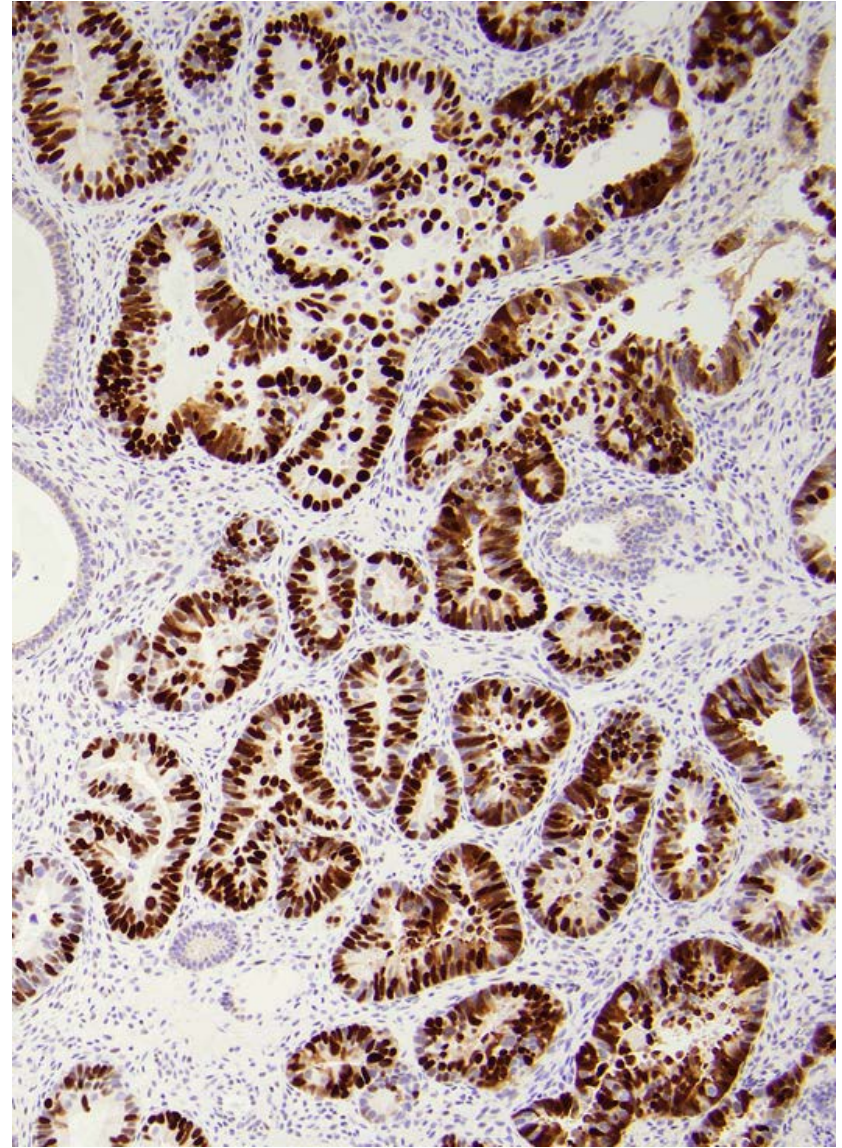
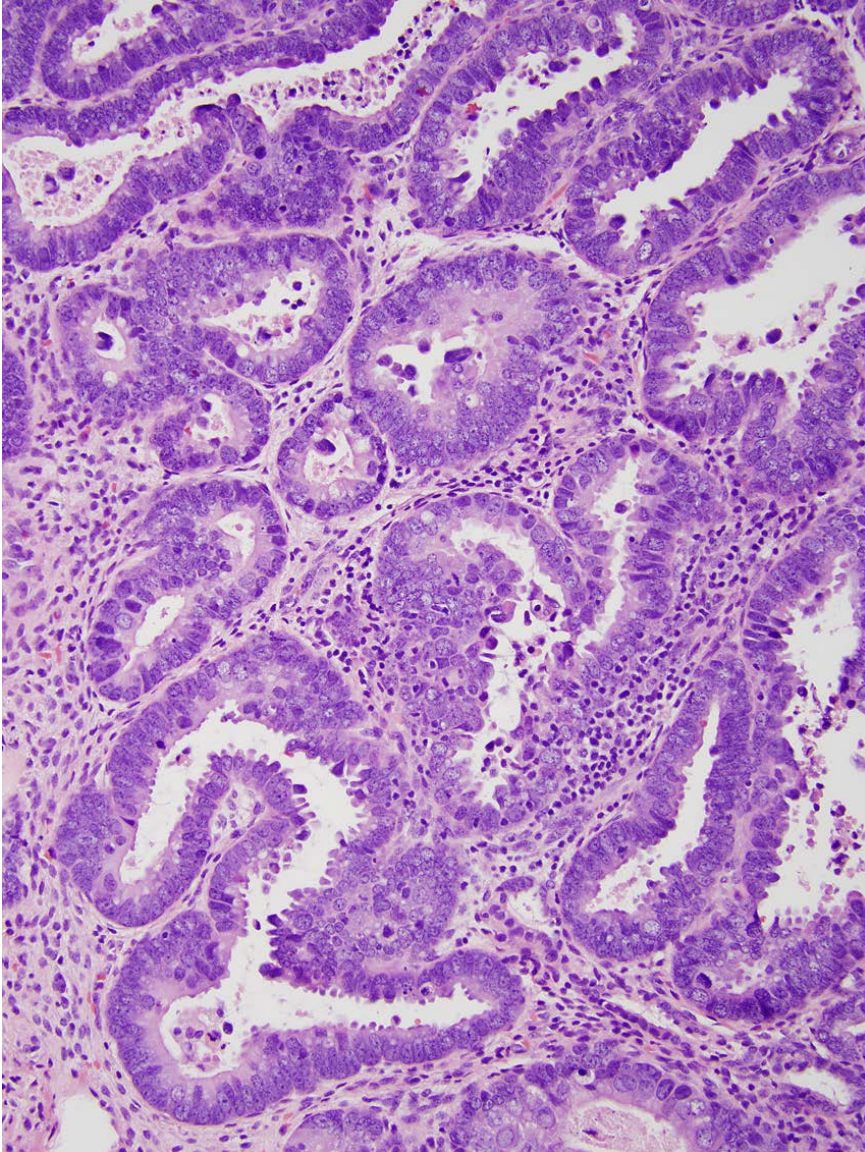


Polyp with Gland Crowding



Polyp with Serous Carcinoma

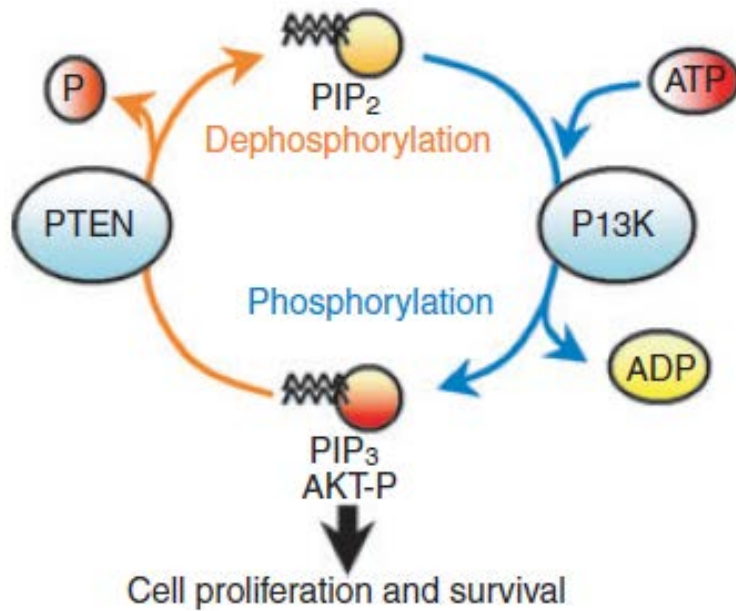
p53



PTEN Mutation

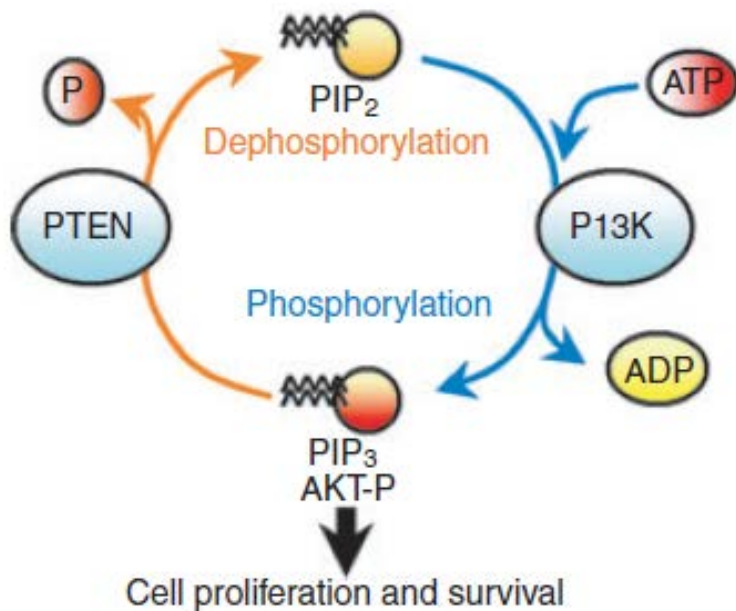
Common in endometrioid carcinoma

Uncommon in non-endometrioid carcinoma



PTEN Mutation

Common in endometrioid carcinoma
Uncommon in non-endometrioid carcinoma



Matias-Guiu & Prat 2013 Histopathology

PTEN Loss by IHC


Normal endometrium	Rare
Hyperplasia	~30%
Atypical hyperplasia	~75%
Endometrioid cancer	~60-75%
Non-endometrioid cancer	~25-35%

Djordjevic 2013 Mod Pathol
Darvishian 2004 AJSP
Mutter 2000 JNCI

Pseudoglandular serous carcinoma

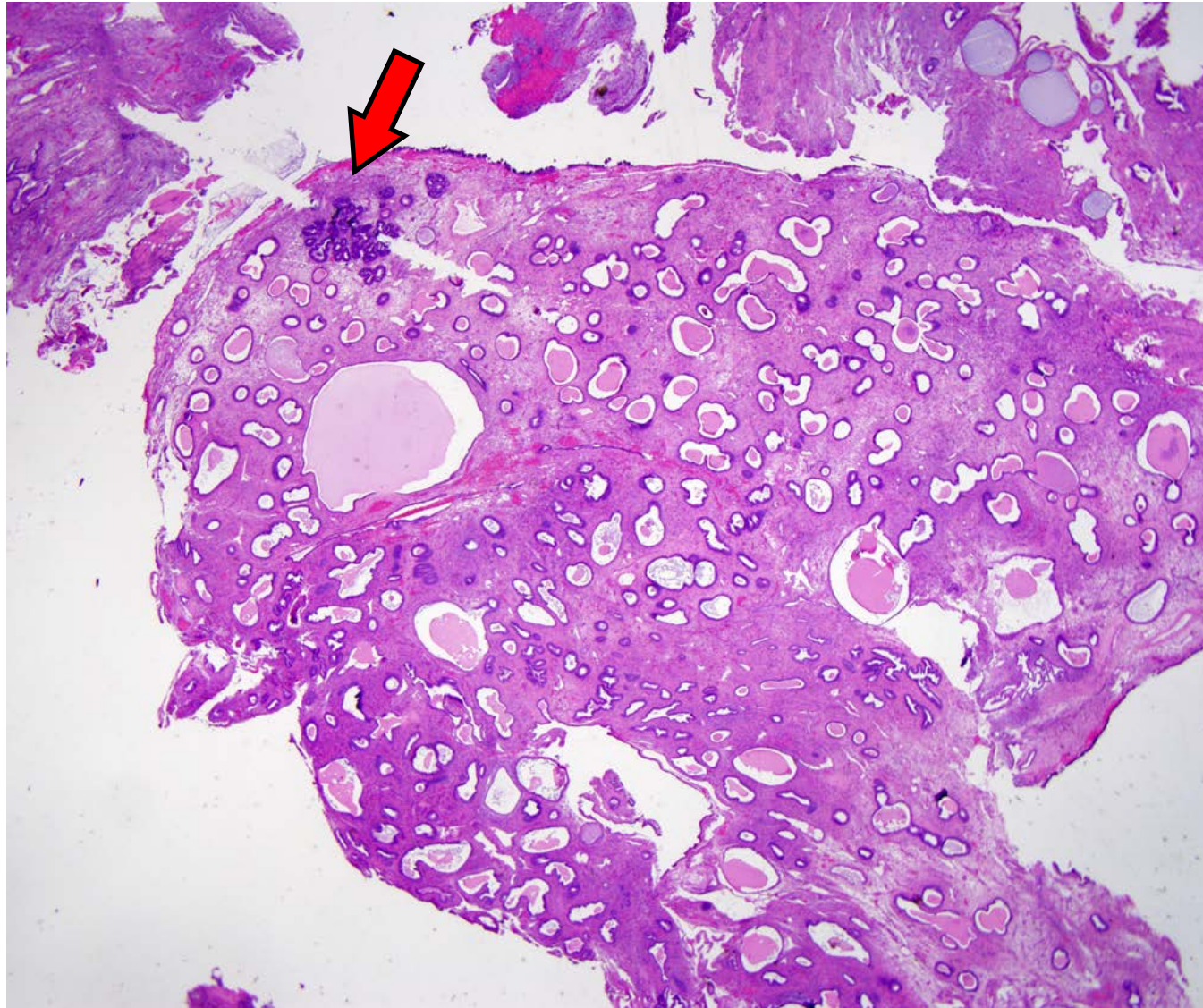
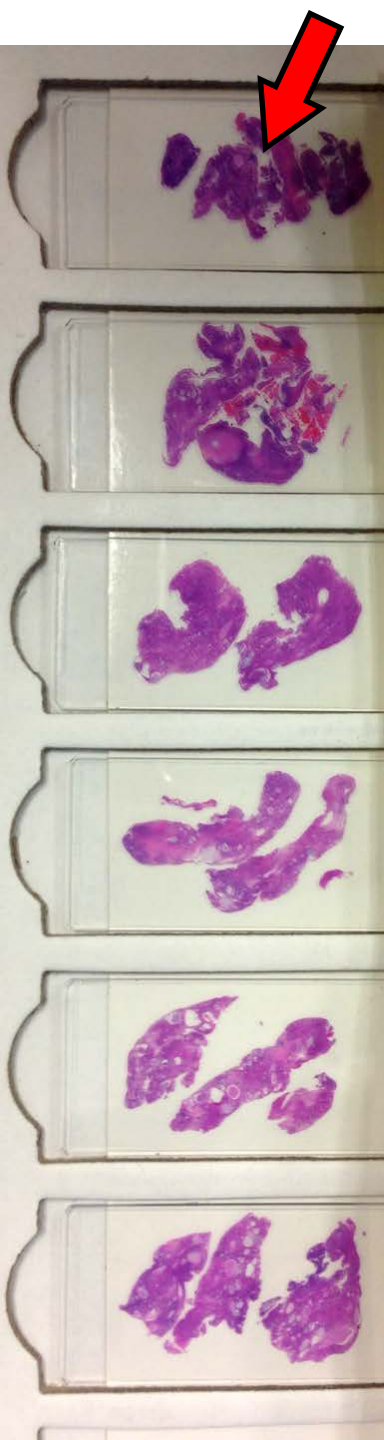How to avoid under-recognition

- Before diagnosing atypical hyperplasia or grade 1 endometrioid carcinoma



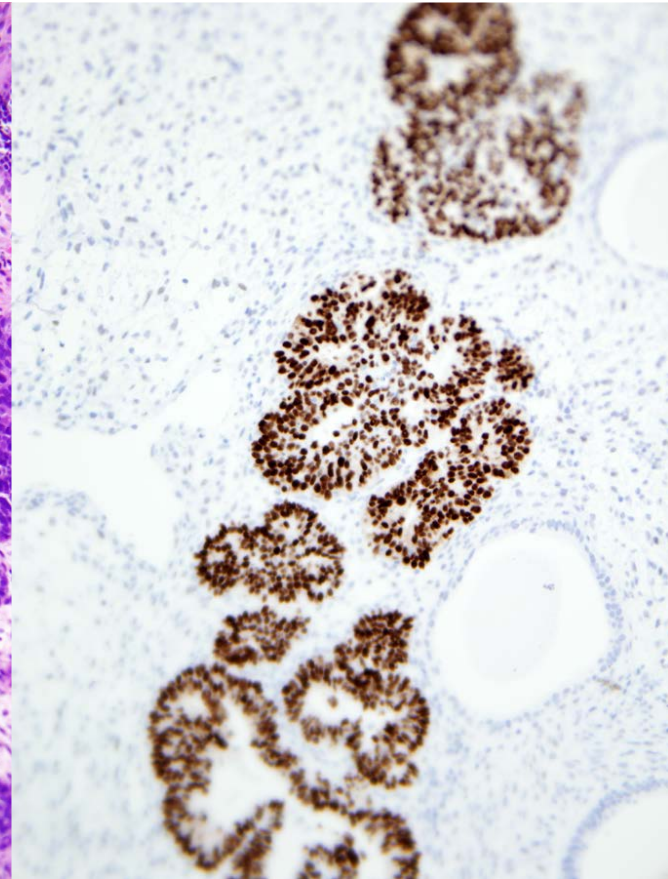
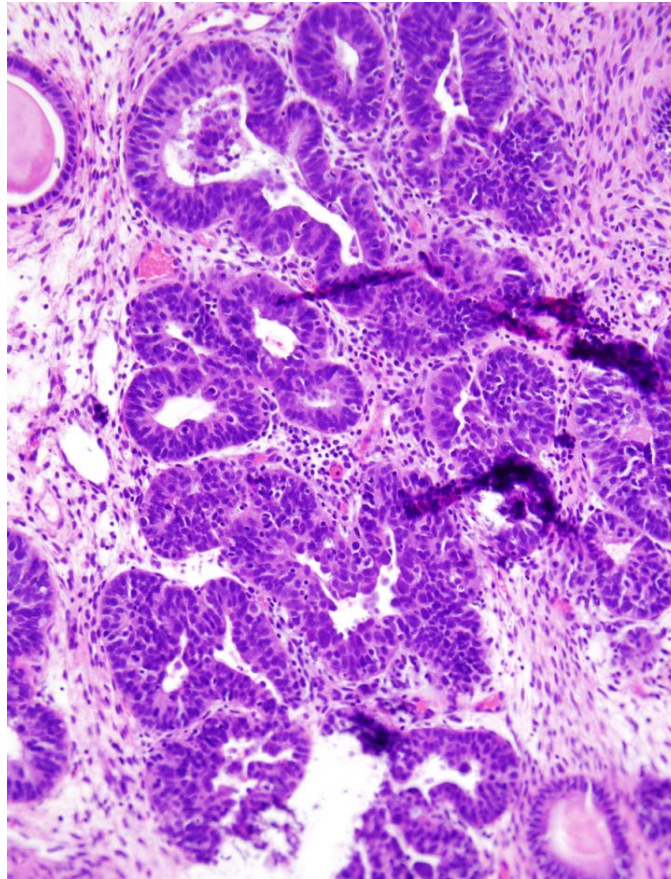
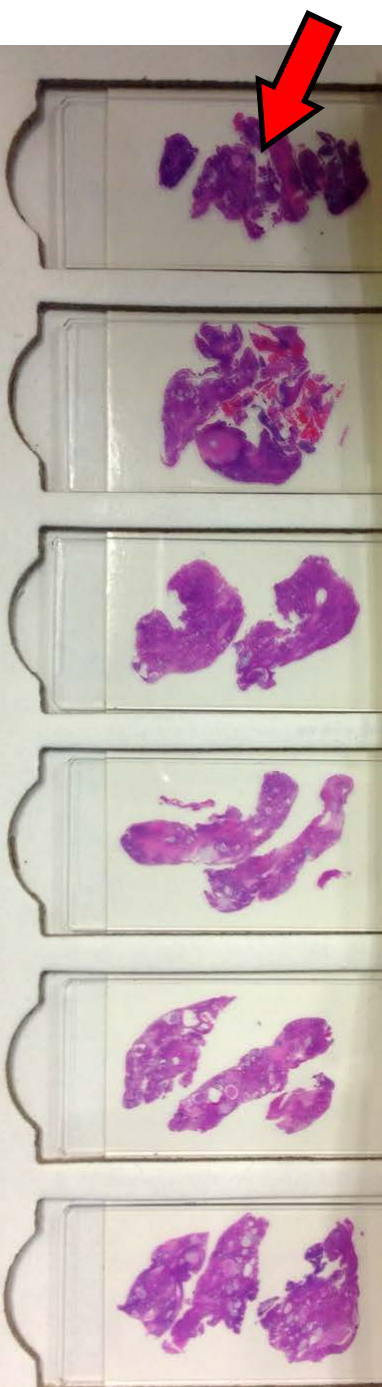Polyp in Post-Menopausal Women:

Risk for Occult Serous Carcinoma



Polyp in Post-Menopausal Women: Risk for Occult Serous Carcinoma

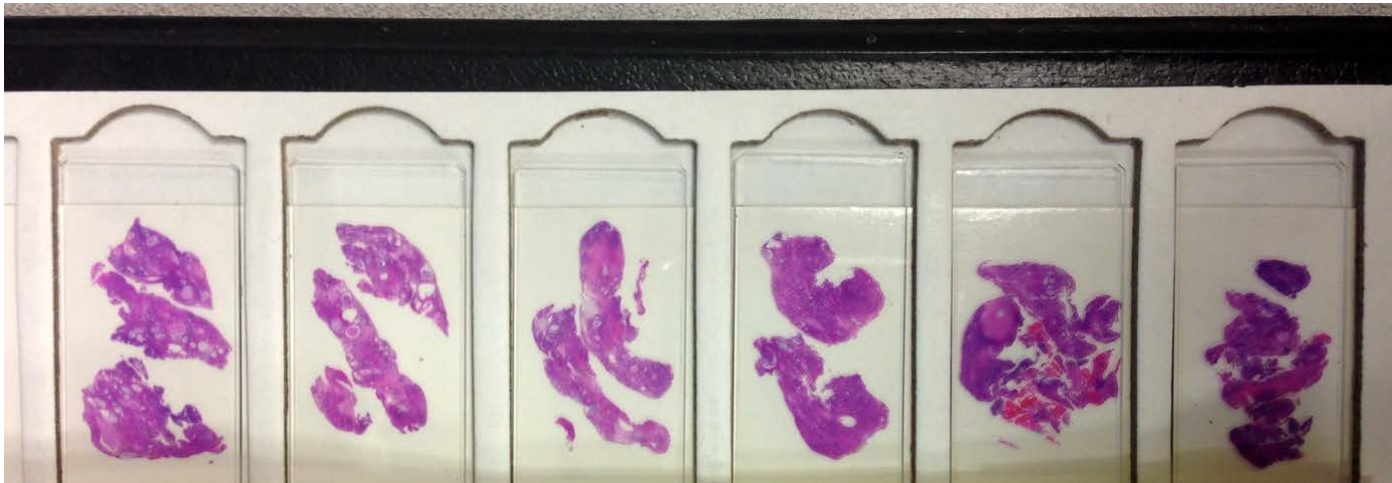p53



Pseudoglandular serous carcinoma

How to avoid under-recognition

- Examine entire polyp (not just part of it) if patient is post-menopausal



Problematic Patterns of Uterine Cancer

- Glandular



- **Papillary**

- Spindled

- Clear cell-rich

- Necrosis in “low grade” tumor

- MELF-myoinvasion in low grade tumor

- Mucin-rich

- Solid pattern with high grade atypia

Papillary Pattern

Low Risk Behavior

- Villoglandular endometrioid adenocarcinoma
- Endometrioid adenocarcinoma with small, non-villous papillae
- Endometrioid adenocarcinoma with sloughing artifact

- Villoglandular endocervical adenocarcinoma

High Risk Behavior

- Serous carcinoma
- Clear cell carcinoma

Papillary Pattern Uterine Cancer

	Papillary variant Endometrioid Carcinoma	Papillary Serous Carcinoma
Architectural Grade	Low	Low
Nuclear Grade	Low	High

**Discordant architecture
versus nuclear grade**

- Pleomorphic nuclei
- Cherry-red macronucleoli
- Smudge cells
- Atypical mitoses

Papillary Pattern Uterine Cancer

Papillary variant Endometrioid Carcinoma

Papillary Serous Carcinoma

Architectural
Grade

Low

Low

Nuclear
Grade

Low

High

p53, p16

wild type

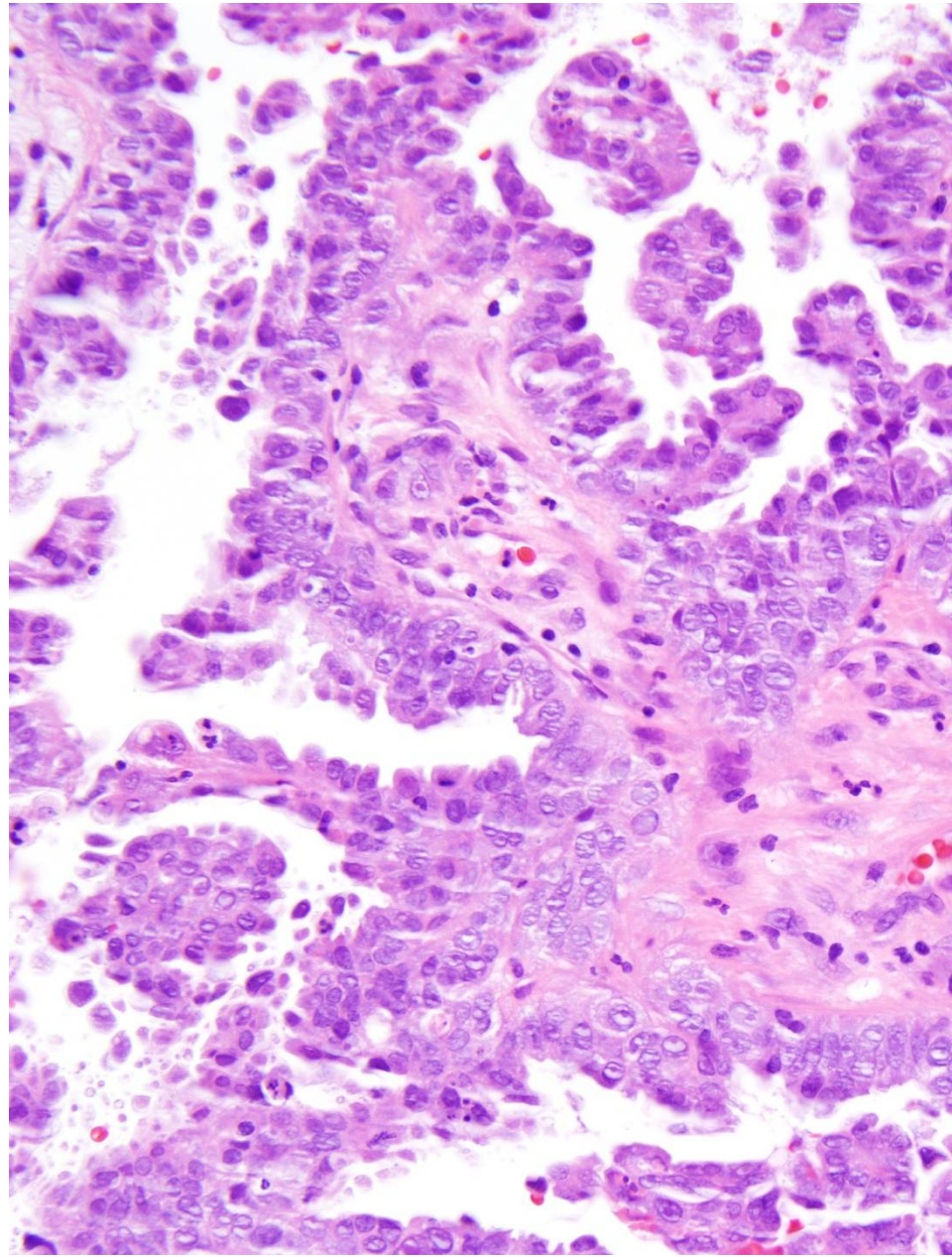
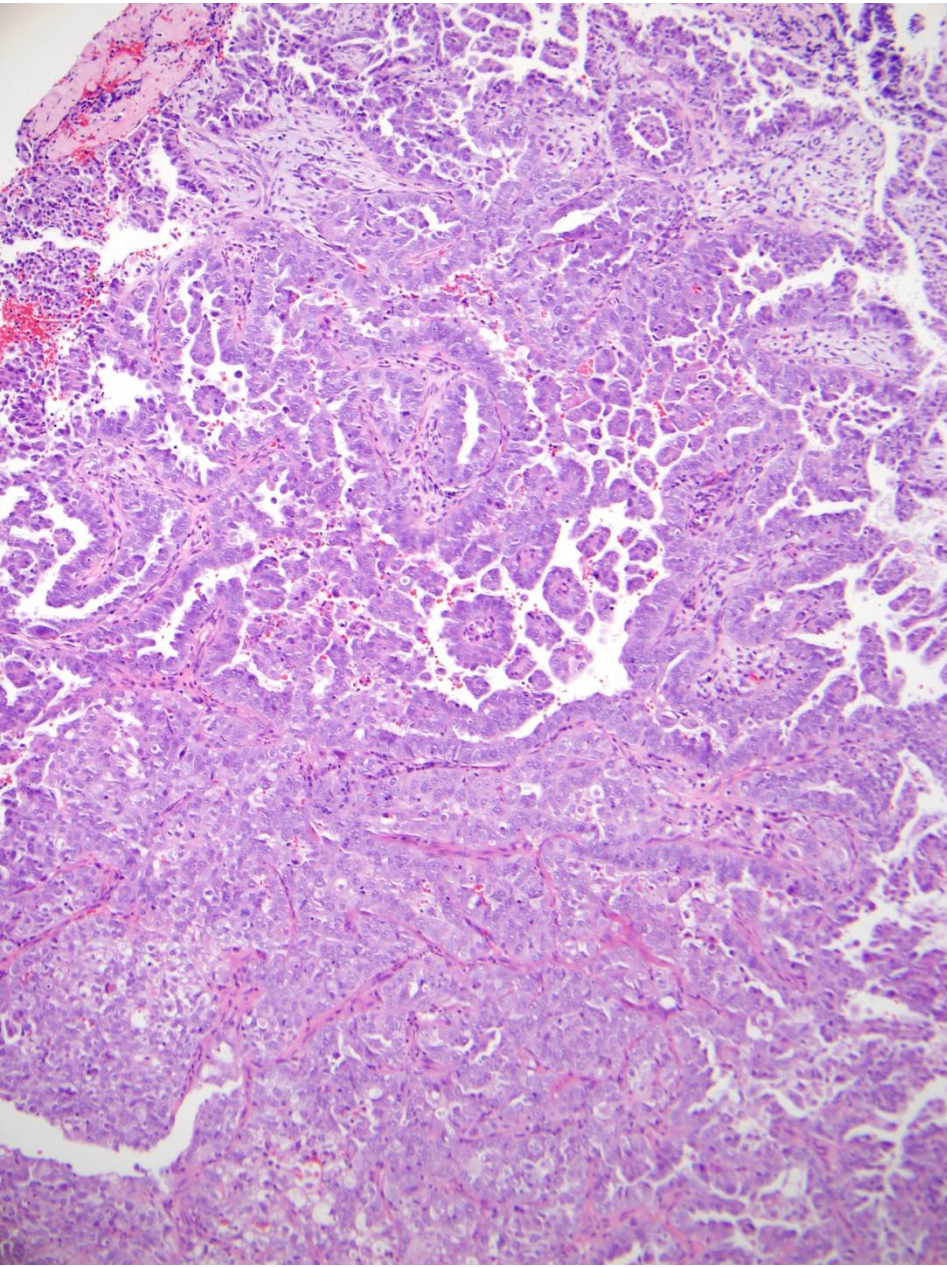
aberrant

ER

diffuse, strong

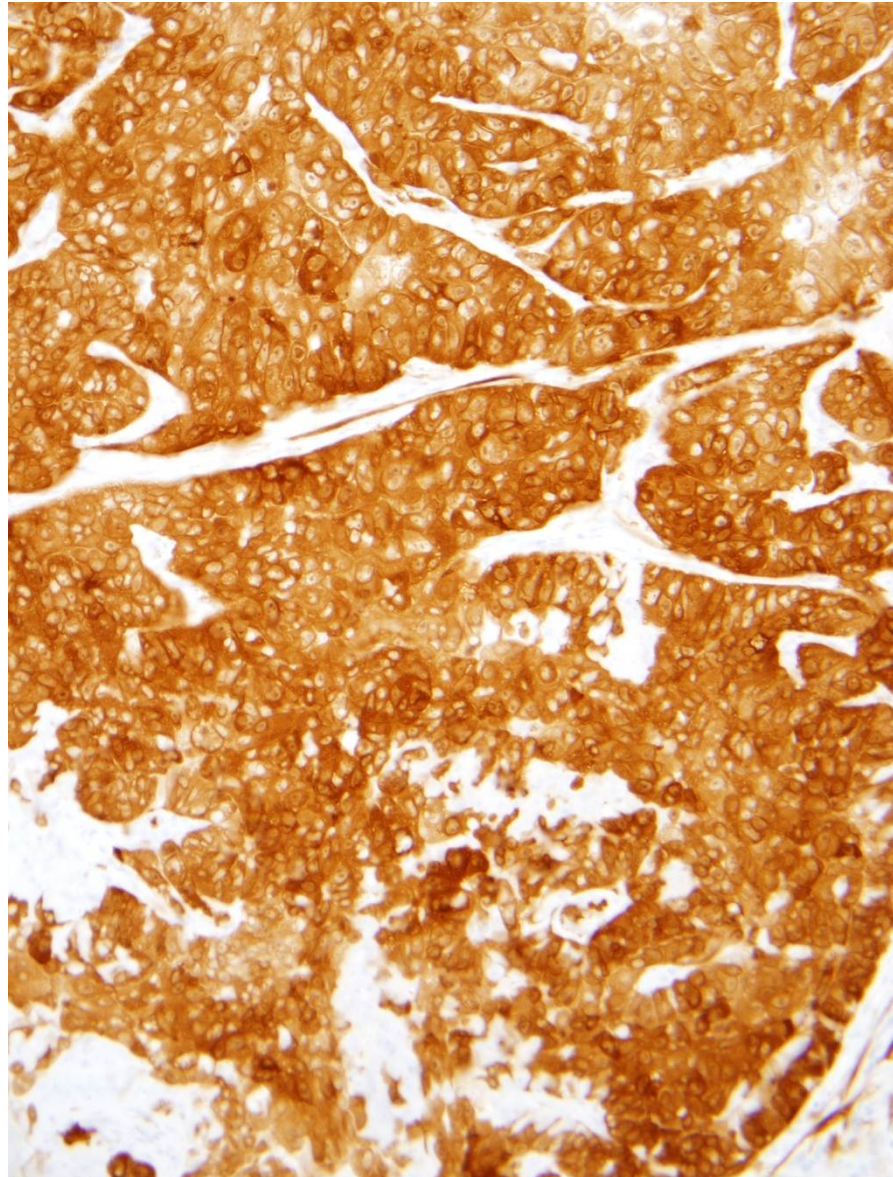
variable

Papillary Serous Carcinoma

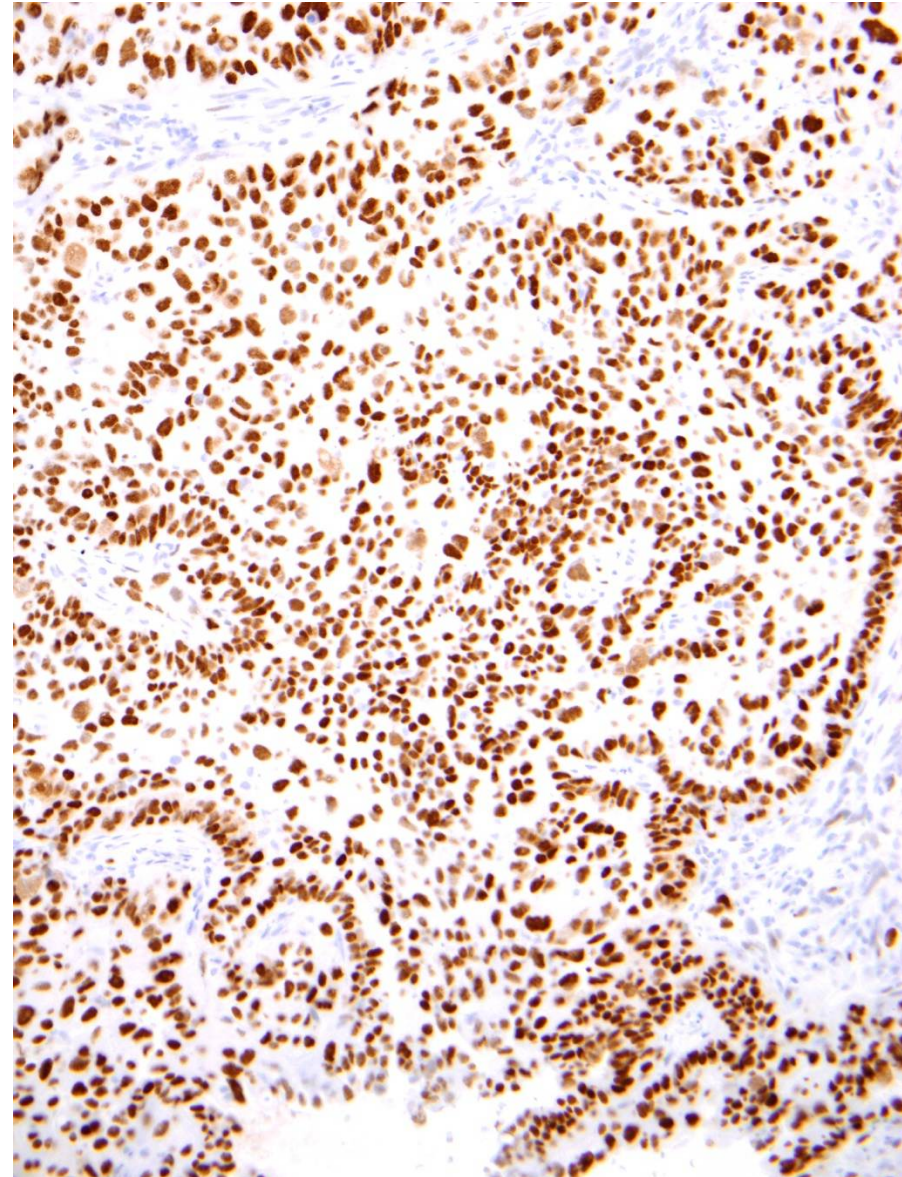


Papillary Serous Carcinoma

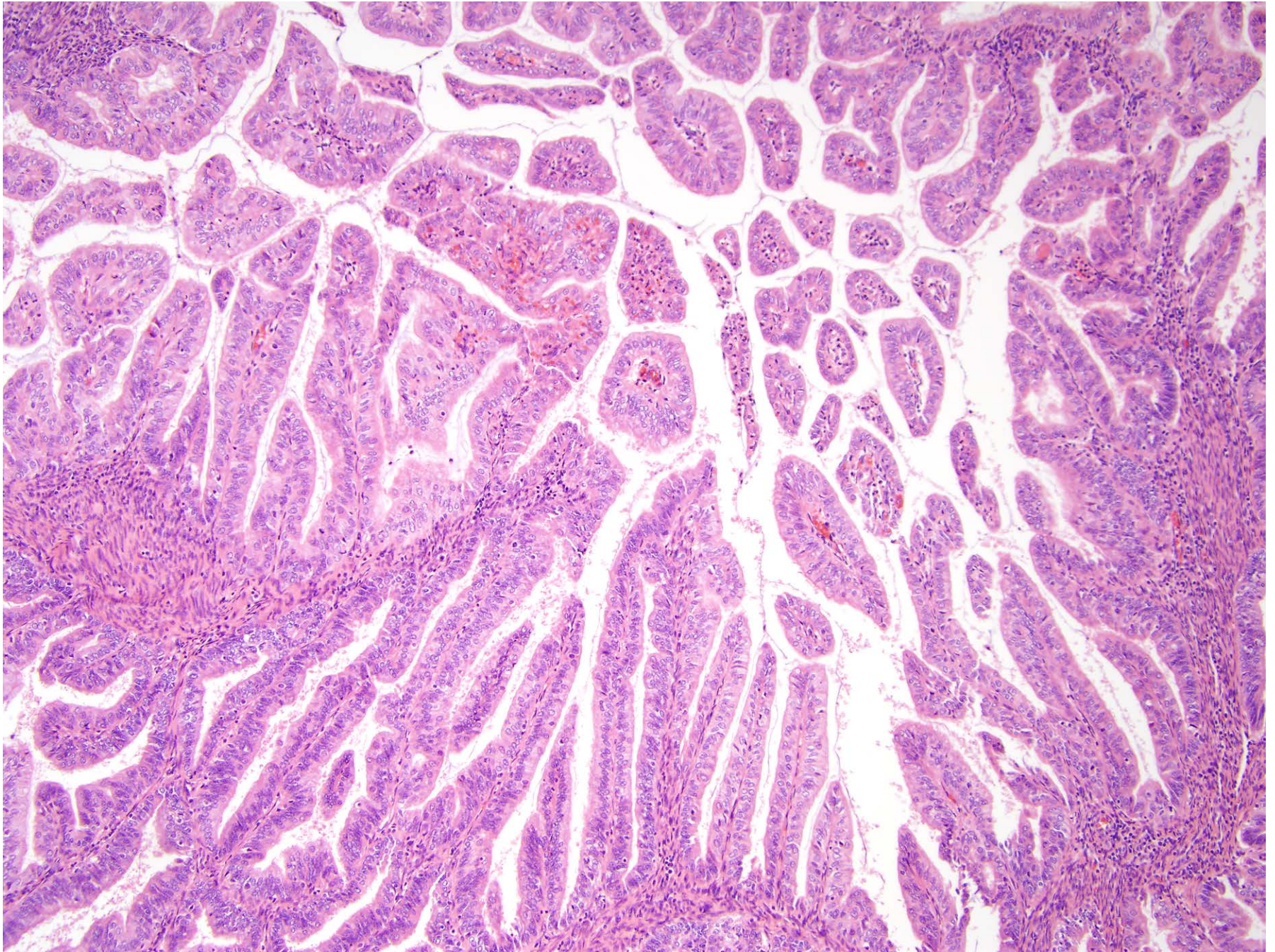
p16: diffuse / strong



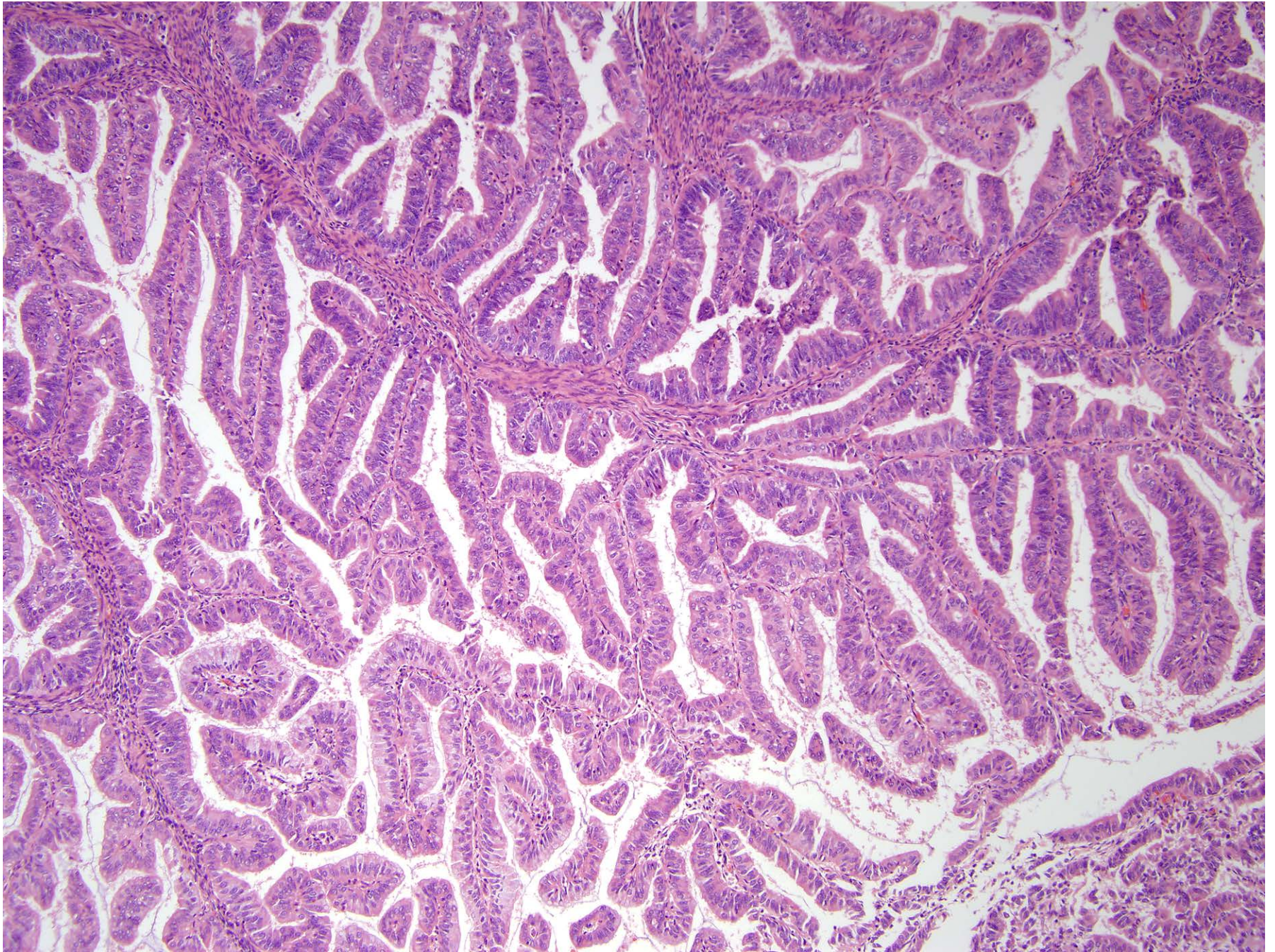
p53: diffuse / strong



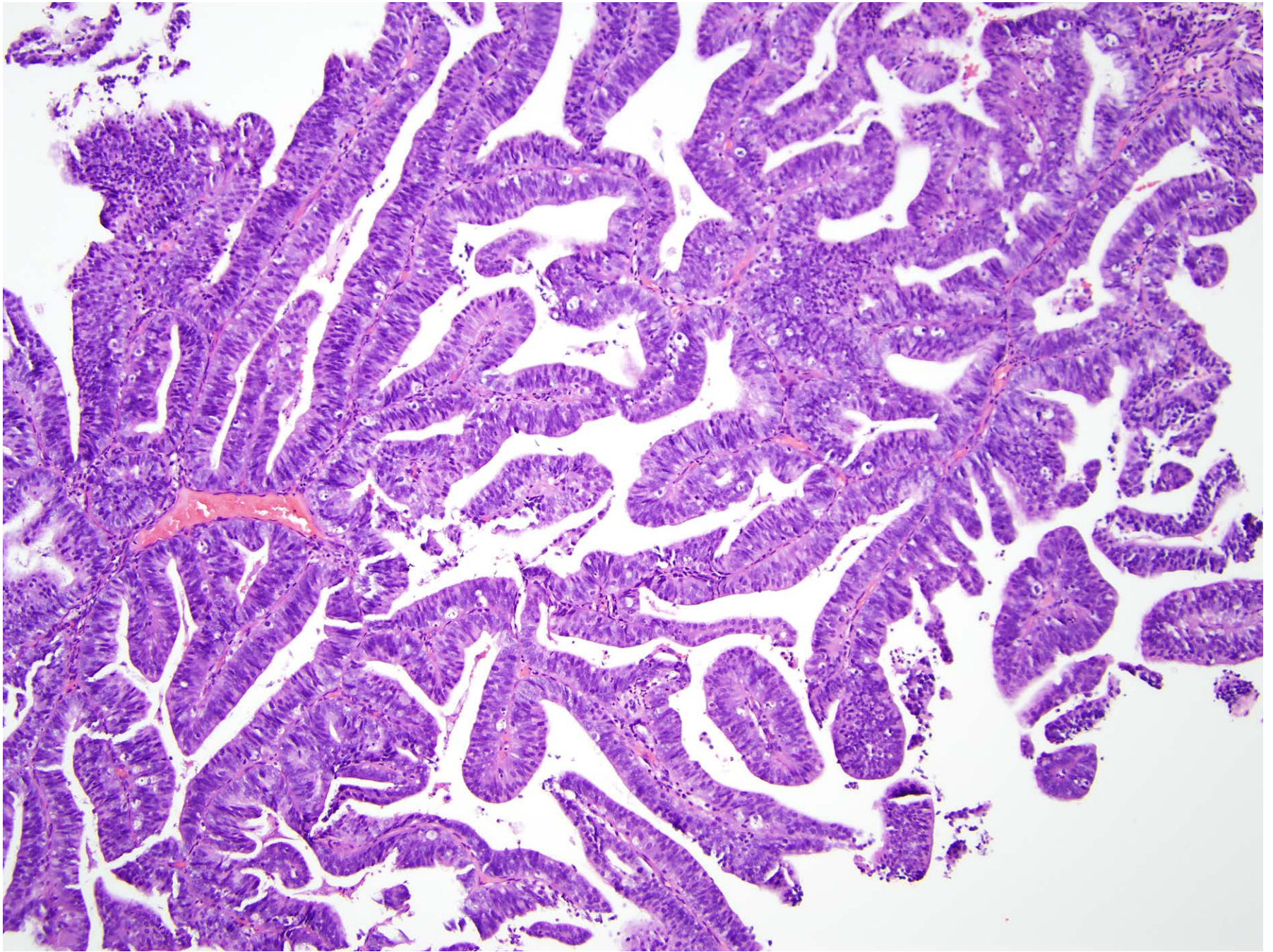
Villoglandular endometrioid adenocarcinoma



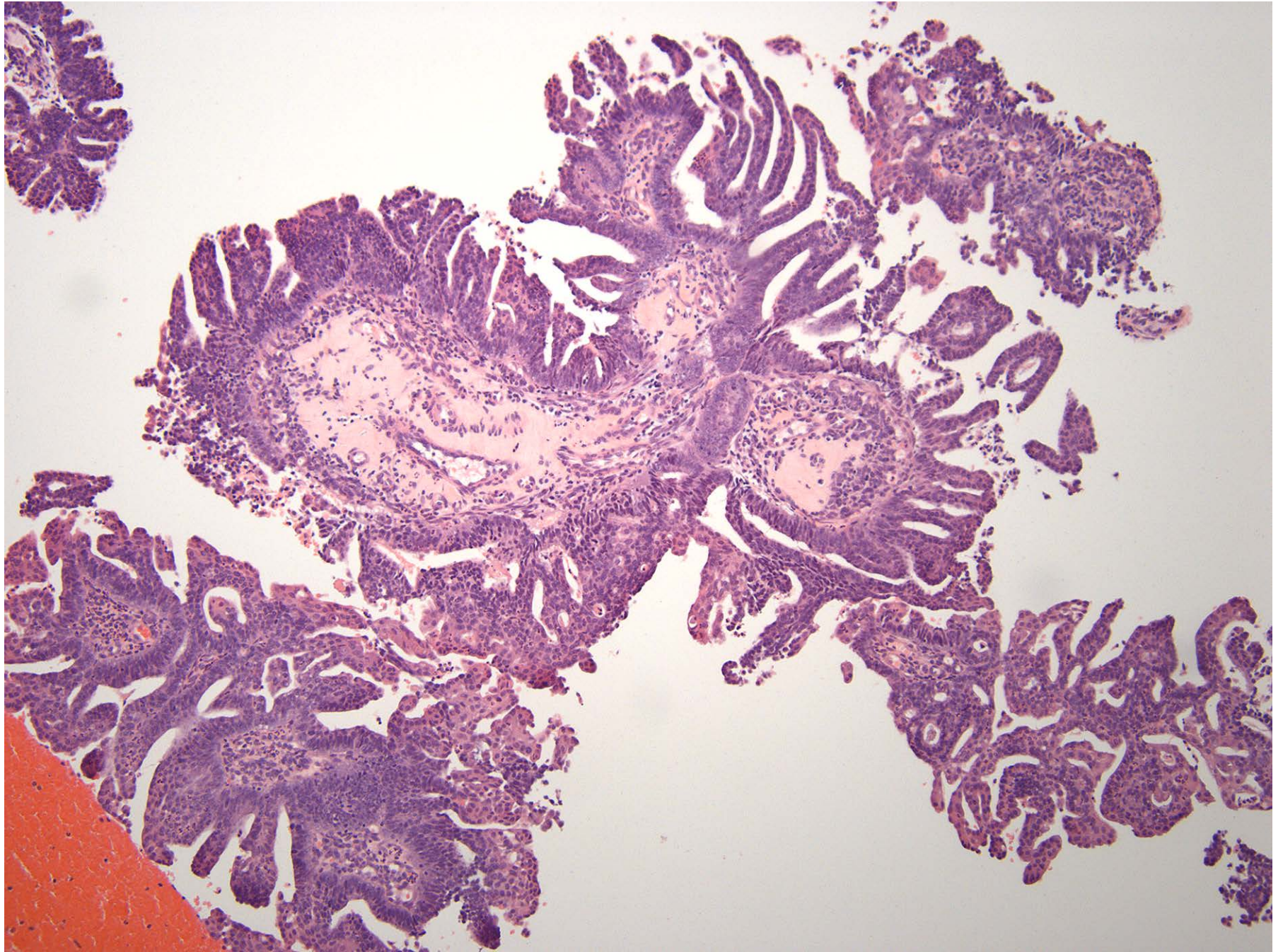
Villoglandular endometrioid adenocarcinoma



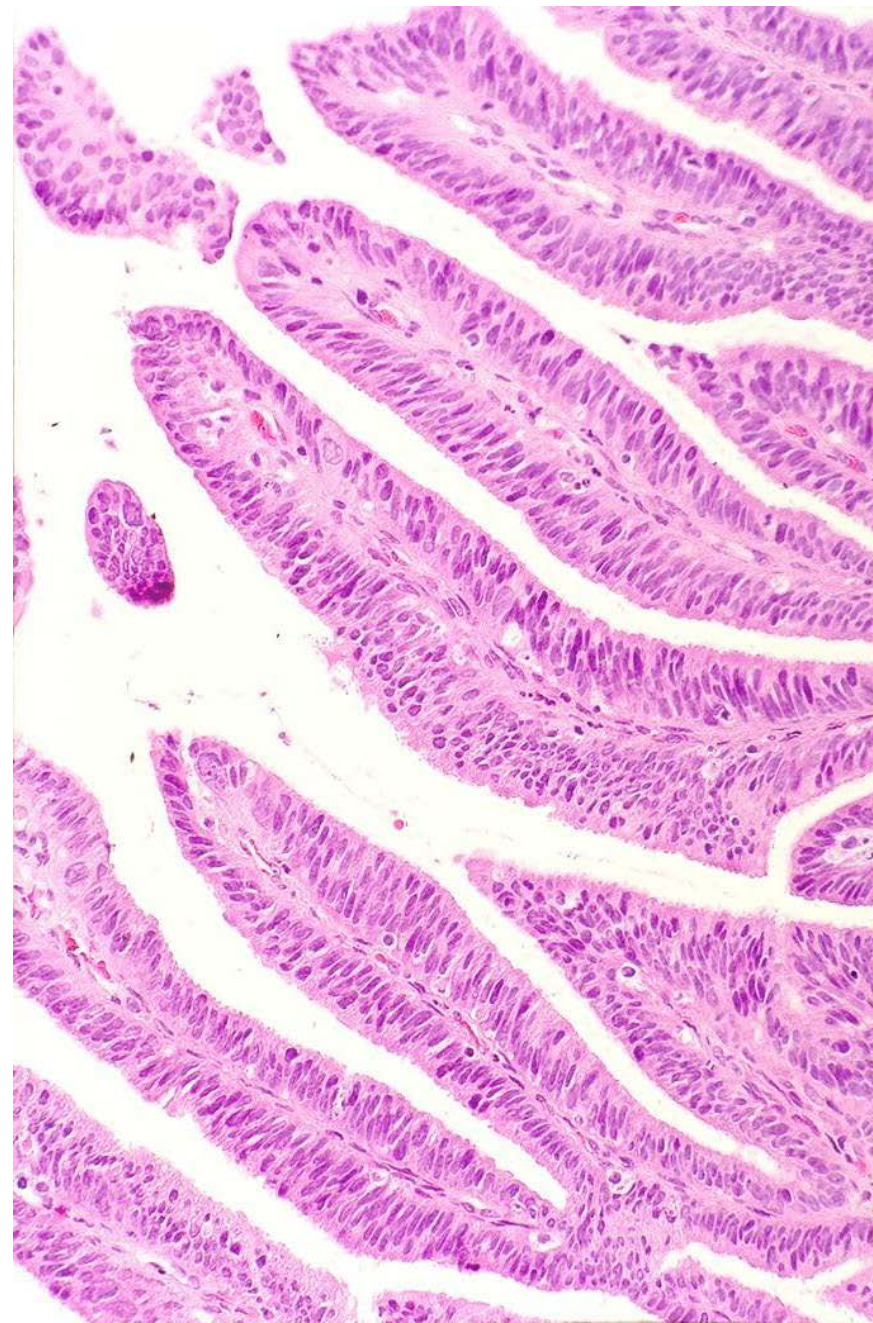
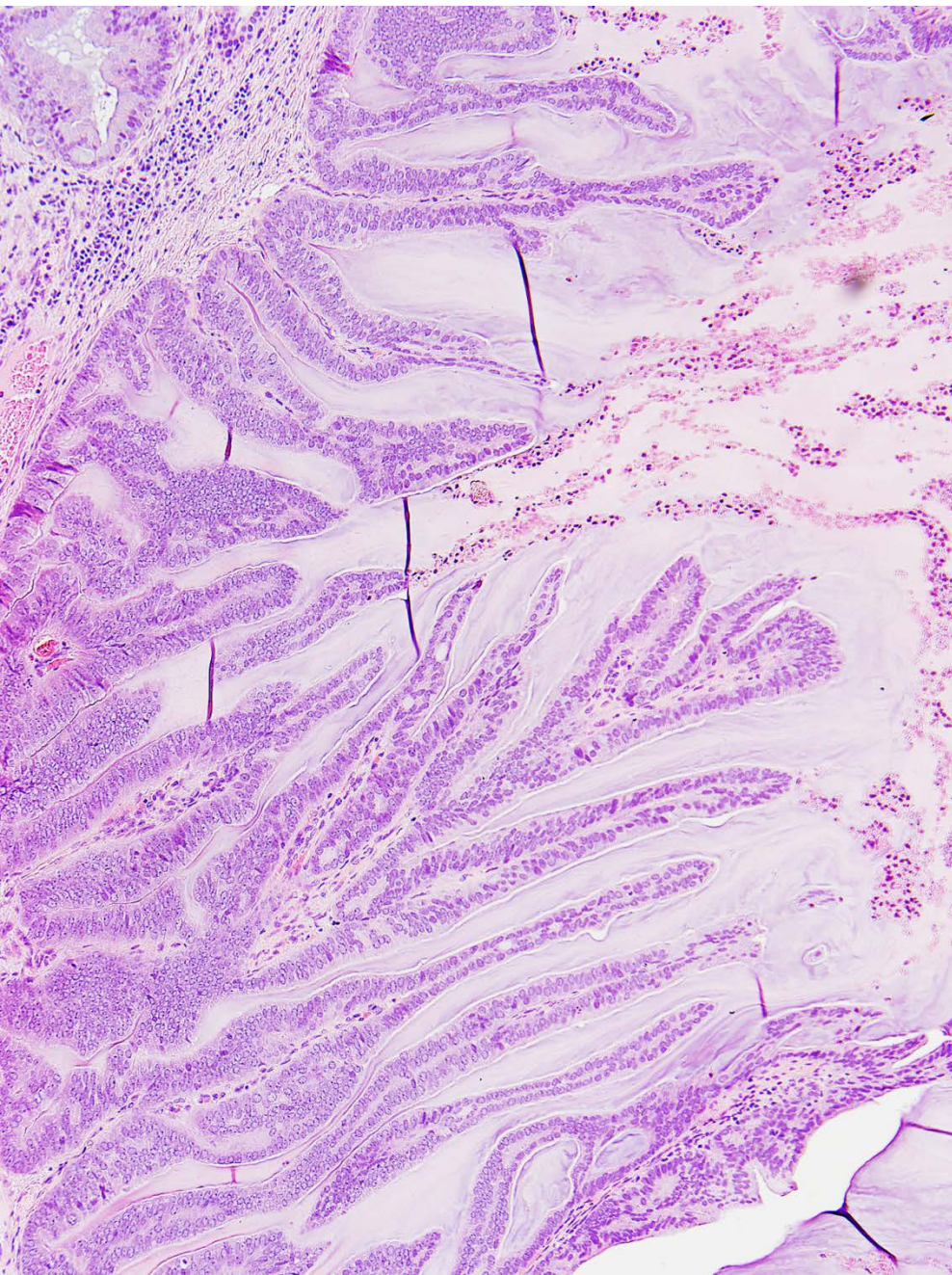
Villoglandular endometrioid adenocarcinoma



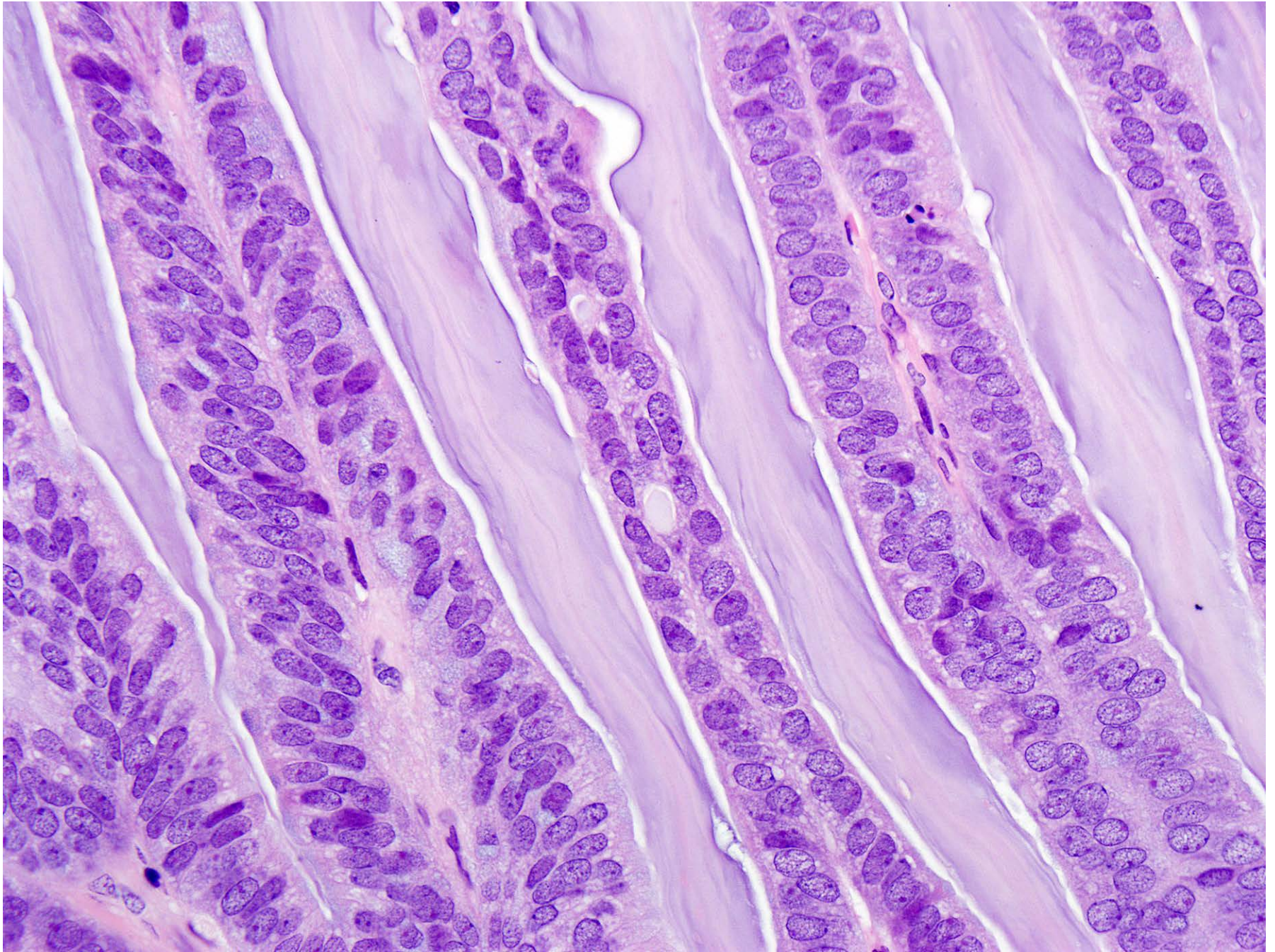
Villoglandular endometrioid adenocarcinoma



Villoglandular endometrioid adenocarcinoma

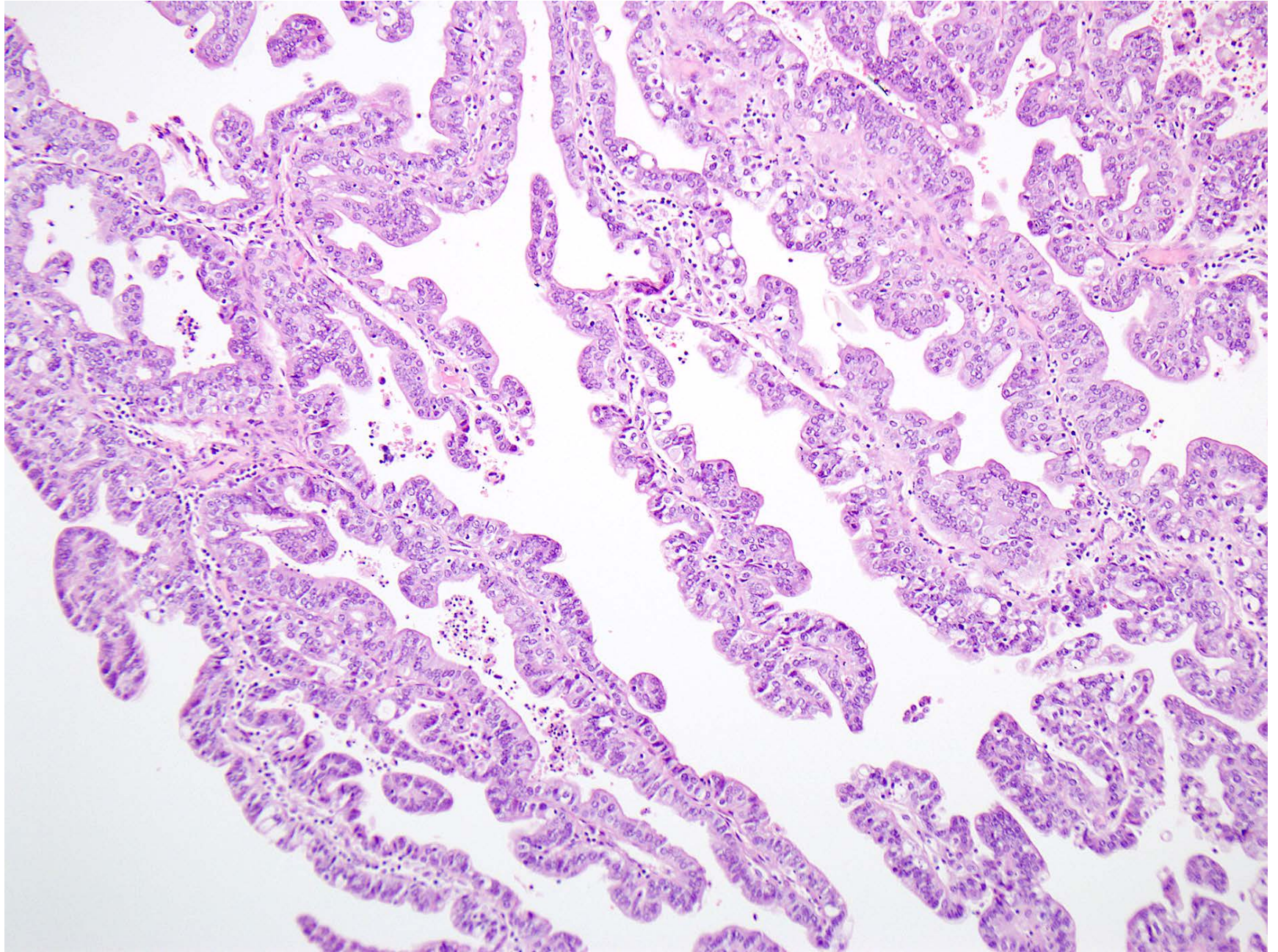


Villoglandular endometrioid adenocarcinoma

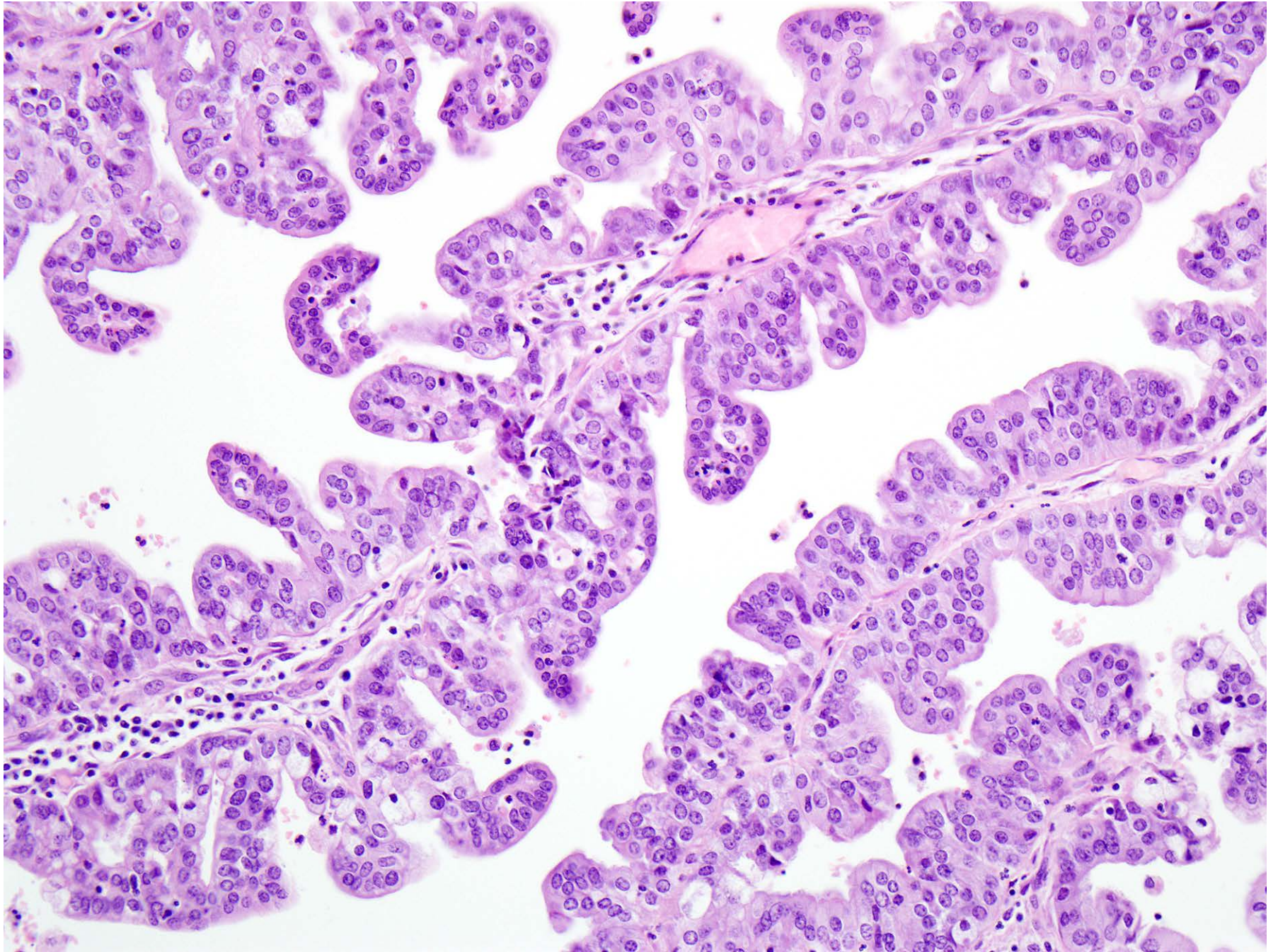


Endometrioid adenocarcinoma with small non-villous papillae

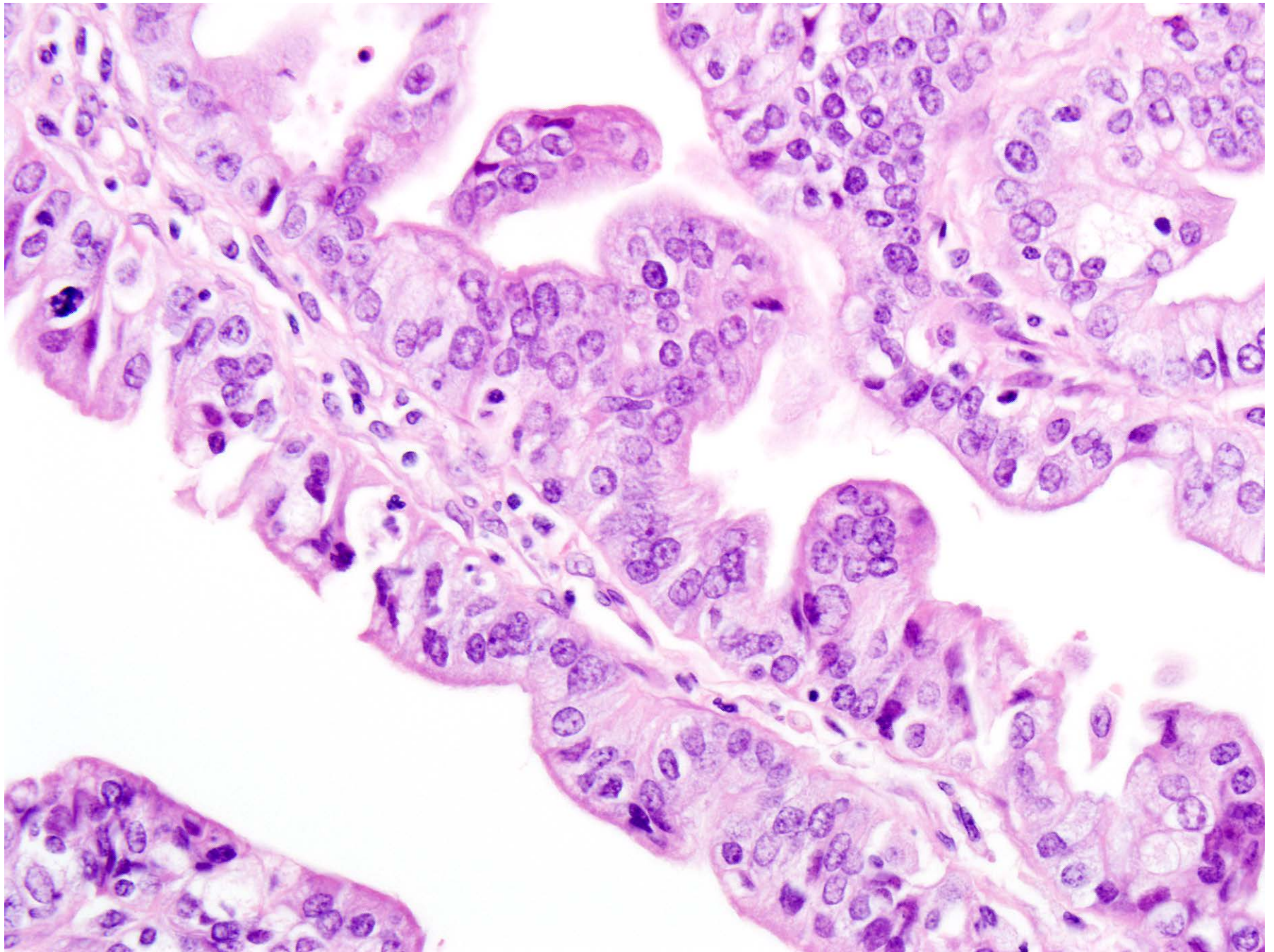
Mimics Serous Carcinoma



Endometrioid adenocarcinoma with small non-villous papillae

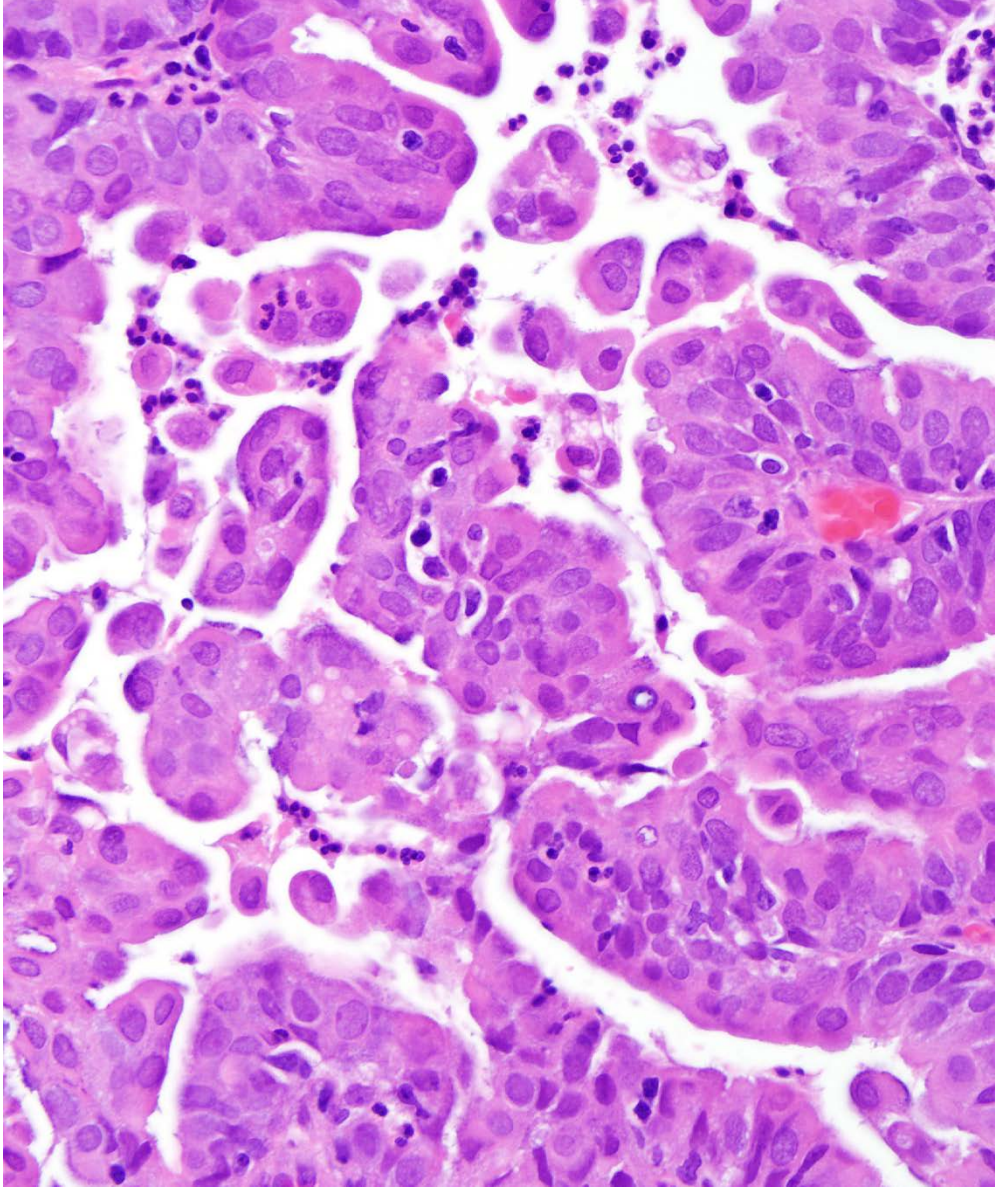
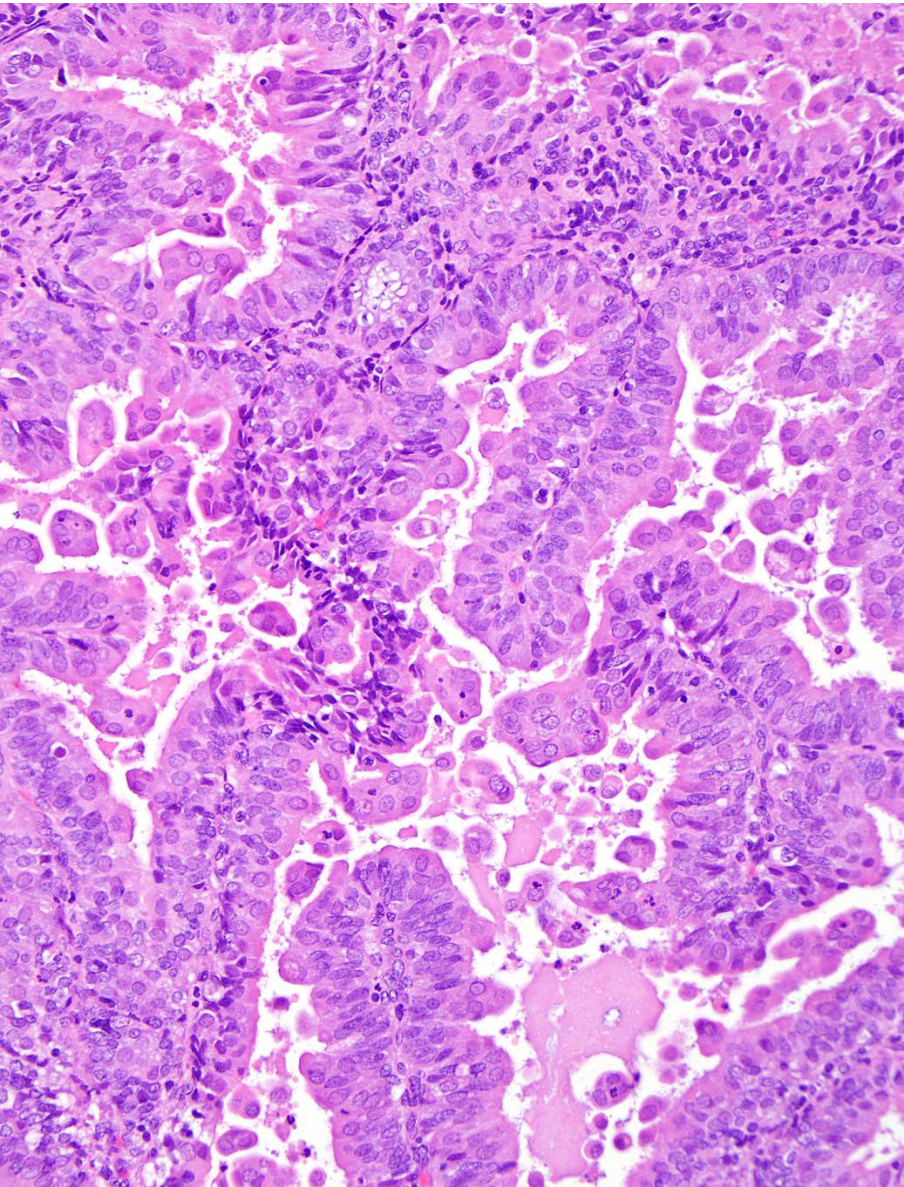


Endometrioid adenocarcinoma with small non-villous papillae



Endometrioid adenocarcinoma with sloughing papillary “buds”

Mimics Serous Carcinoma

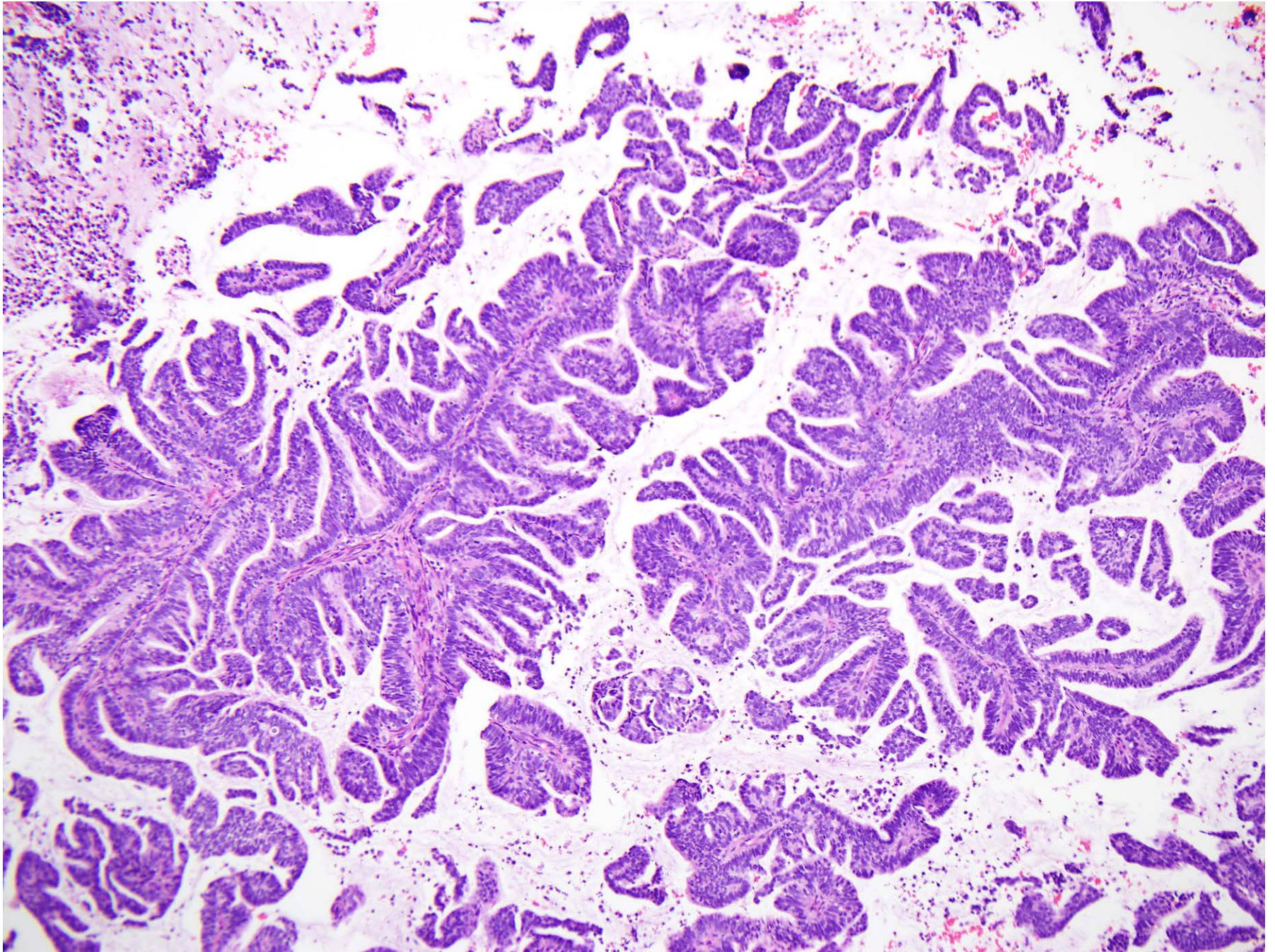


Villoglandular endocervical adenocarcinoma in “EMB”

Clues to raise concern:

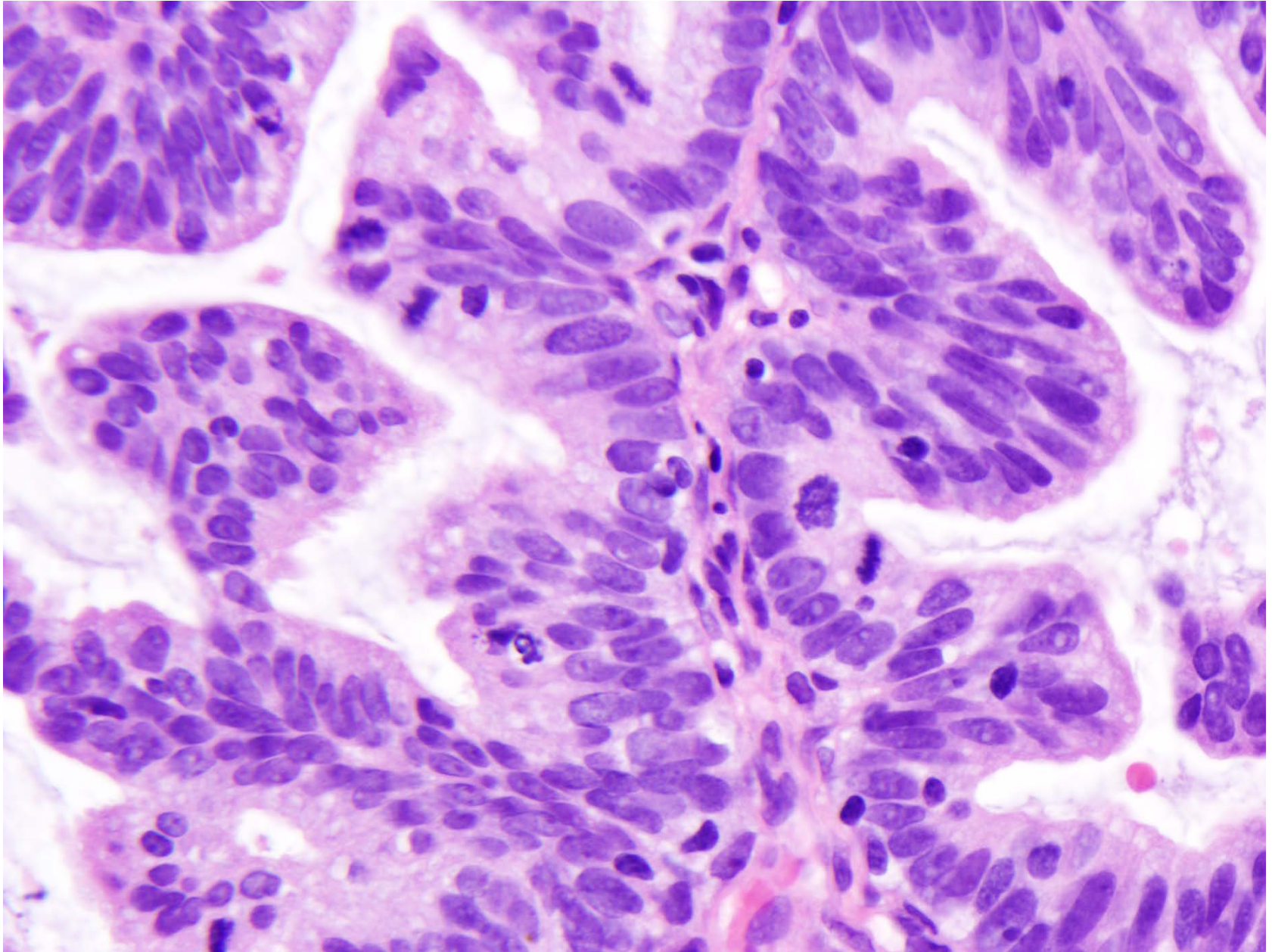
- Young age (35-45)
 - Clinical lesion in endocervix
-
- Apical: “Floating” mitoses
 - Basal: Apoptotic debris
-
- Negative: ER, Vimentin, p53
 - Positive: p16, mCEA
-

Villoglandular endocervical adenocarcinoma in “EMB”



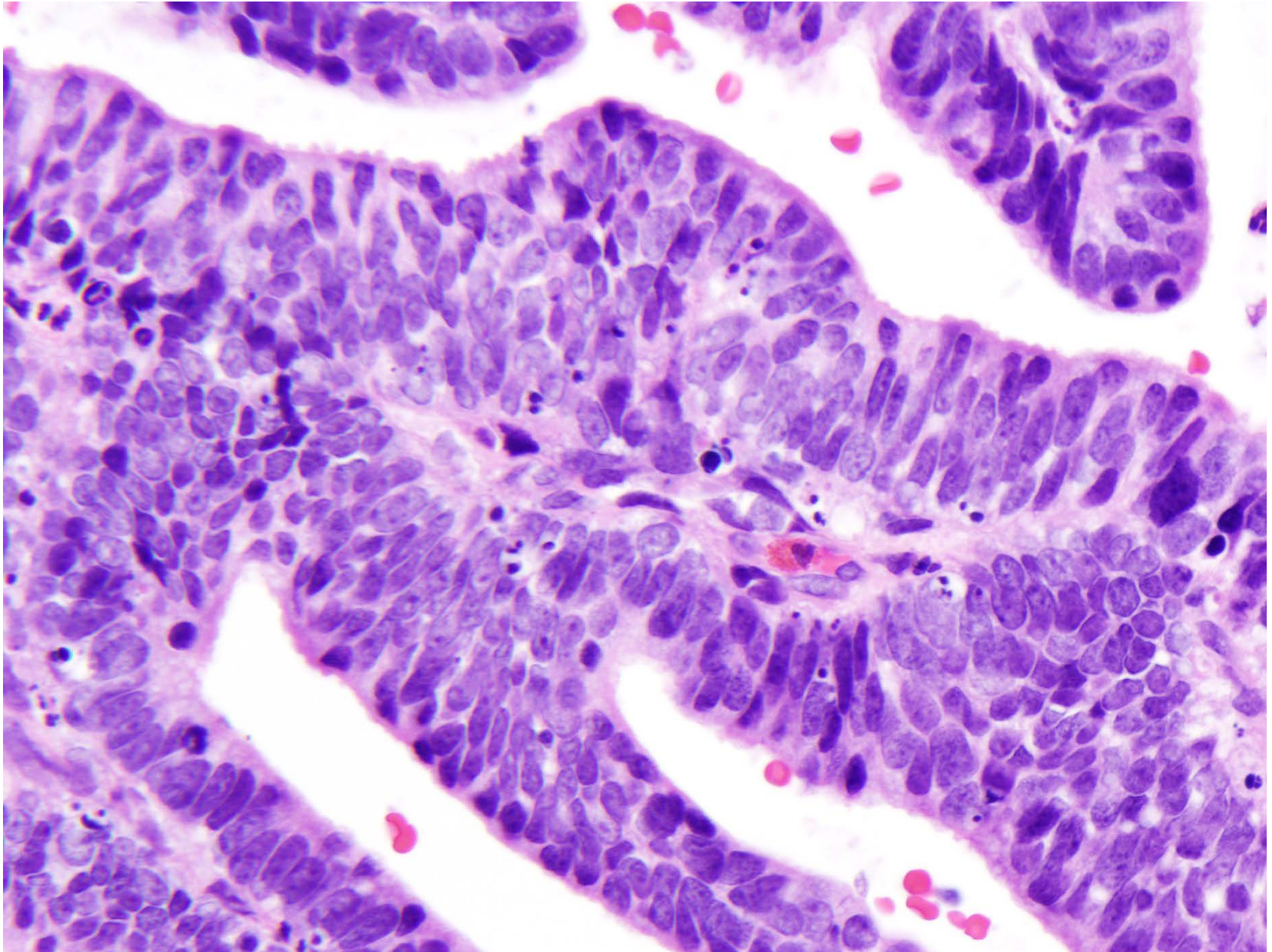
Villoglandular endocervical adenocarcinoma in “EMB”

Floating mitoses in apical cytoplasm



Villoglandular endocervical adenocarcinoma in “EMB”

Apoptotic debris



Problematic Patterns of Uterine Cancer

- Glandular
- Papillary
- **Spindled**
- Clear cell-rich
- Necrosis in “low grade” tumor
- MELF-myoinvasion in low grade tumor
- Mucin-rich
- Solid pattern with high grade atypia

Spindled Pattern

Low Risk Behavior

- Endometrioid adenocarcinoma with spindle cells
- Endometrioid adenocarcinoma, corded and hyalinized type
- Endometrioid adenocarcinoma, with progestin treatment effect
- Atypical polypoid adenomyoma

High Risk Behavior

- Carcinosarcoma

Uterine Cancers with Spindle Cells

Spindled type Endometrioid Carcinoma

Carcinosarcoma

Epithelium and spindle cells **Merged**

Separate

Epithelial atypia **Low grade**

High grade

Spindle cell atypia **None**

High grade

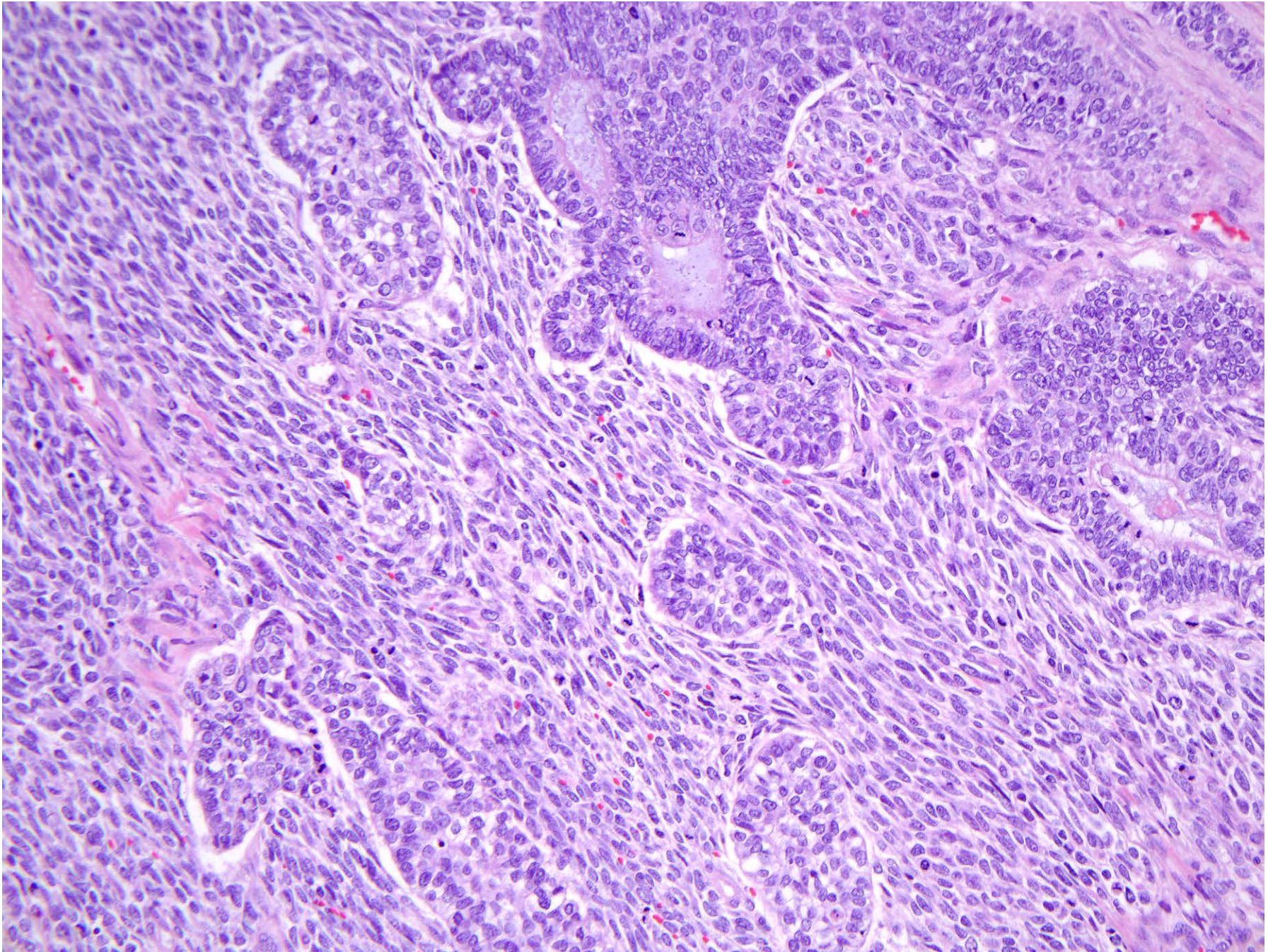
Heterologous elements **No**

Common

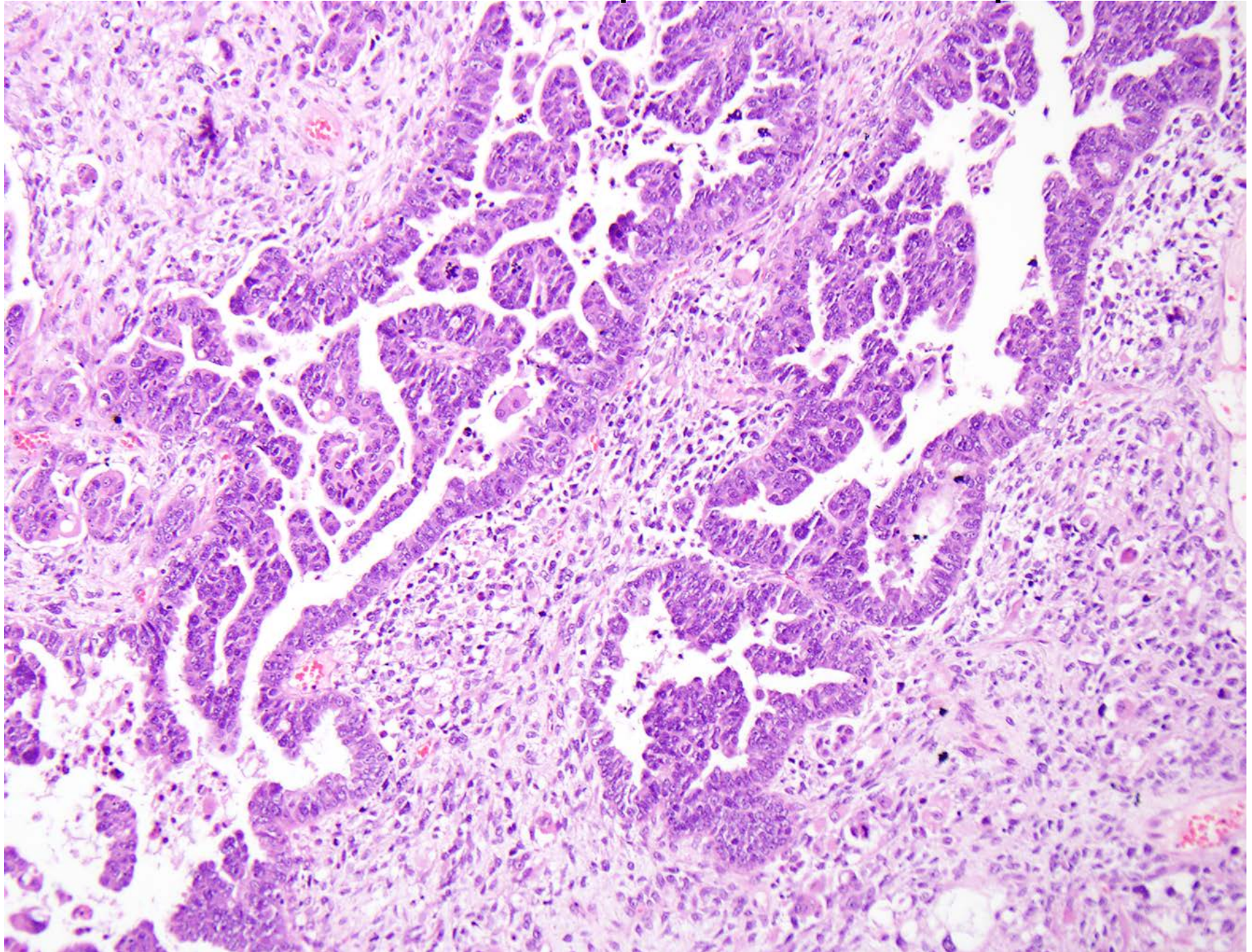
Aberrant p16, p53 **No**

Yes

Carcinosarcoma: sharp demarcation of 2 components

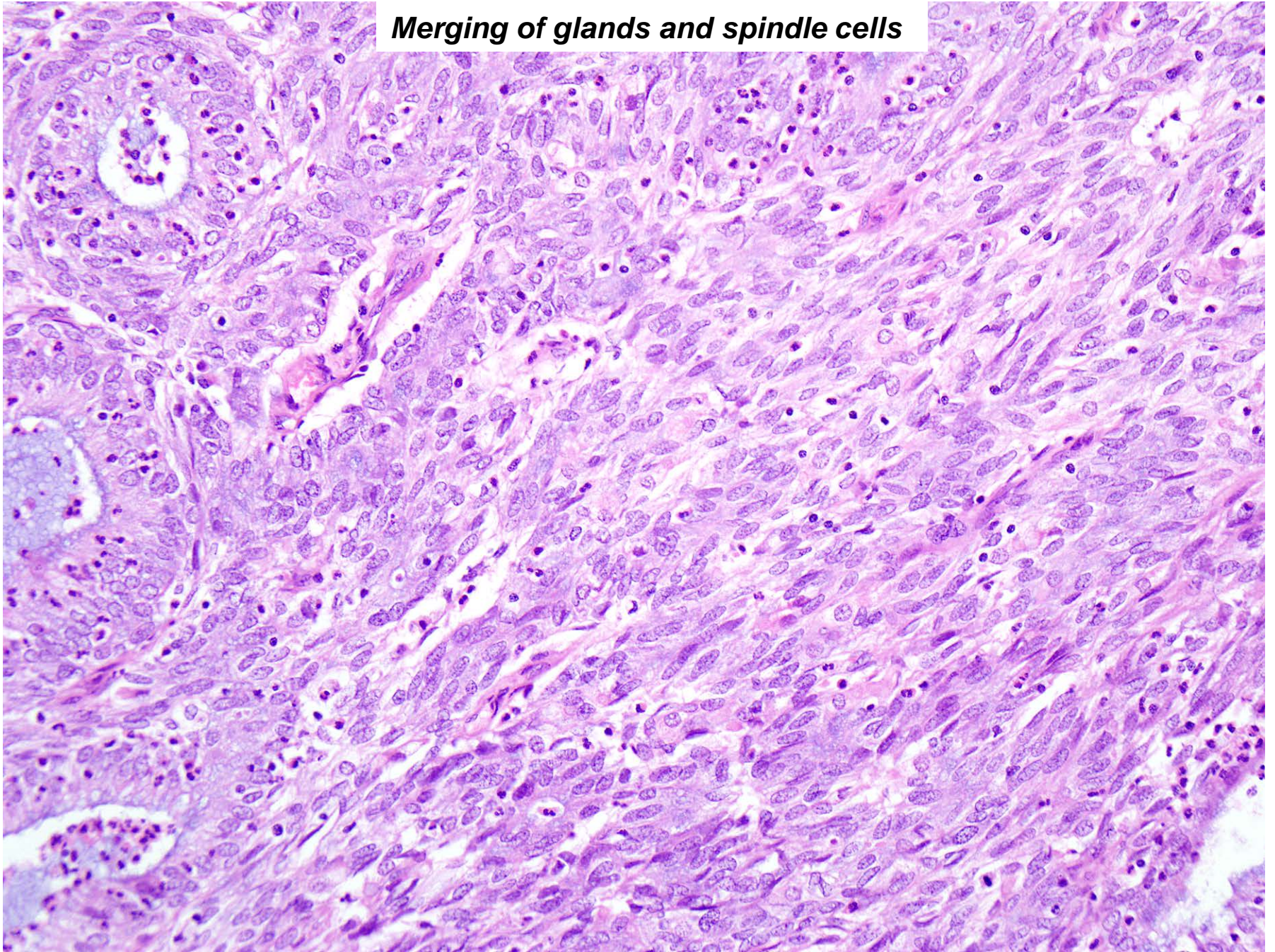


Carcinosarcoma: sharp demarcation of 2 components



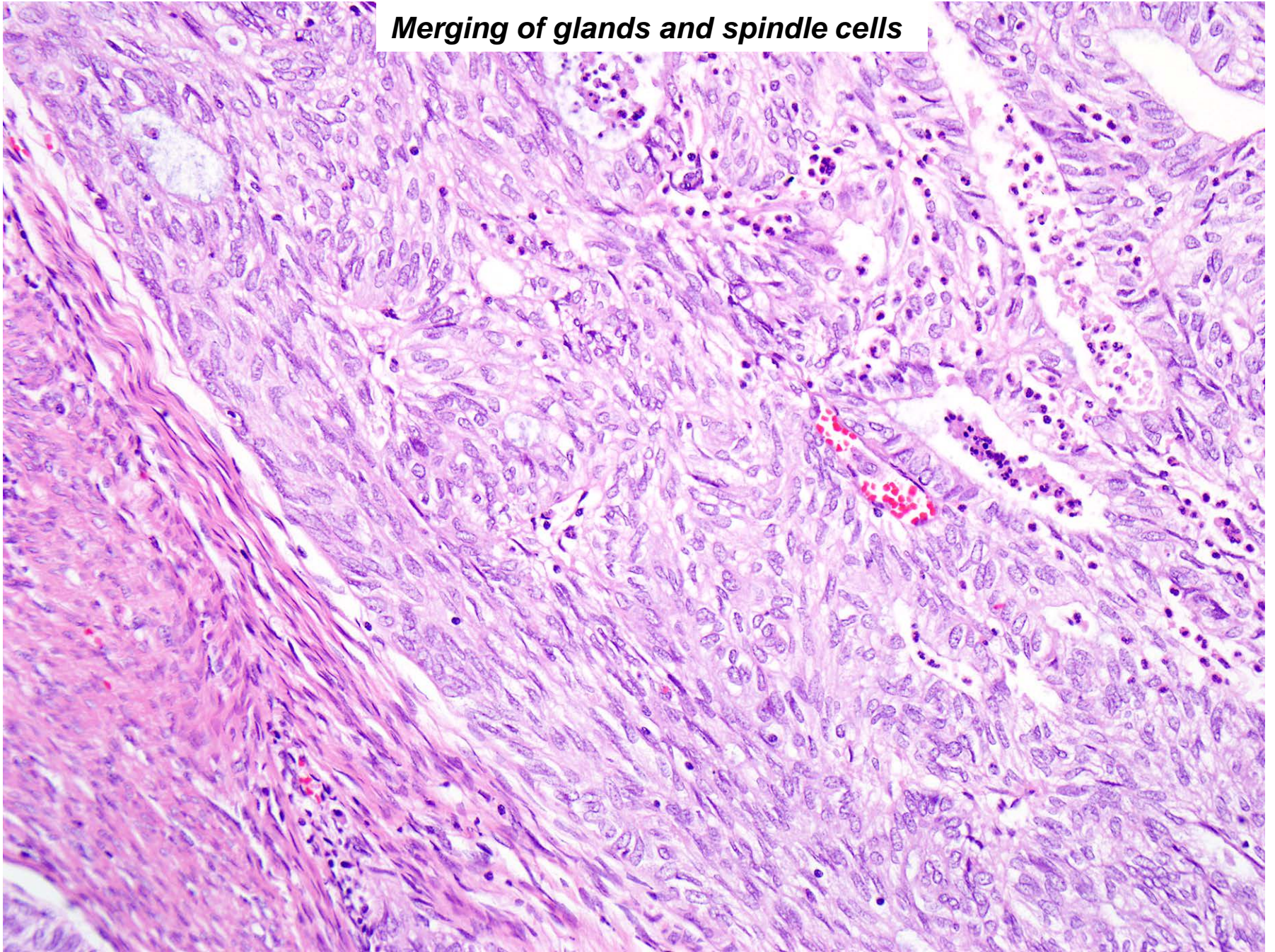
Endometrioid carcinoma with spindle cells

Merging of glands and spindle cells



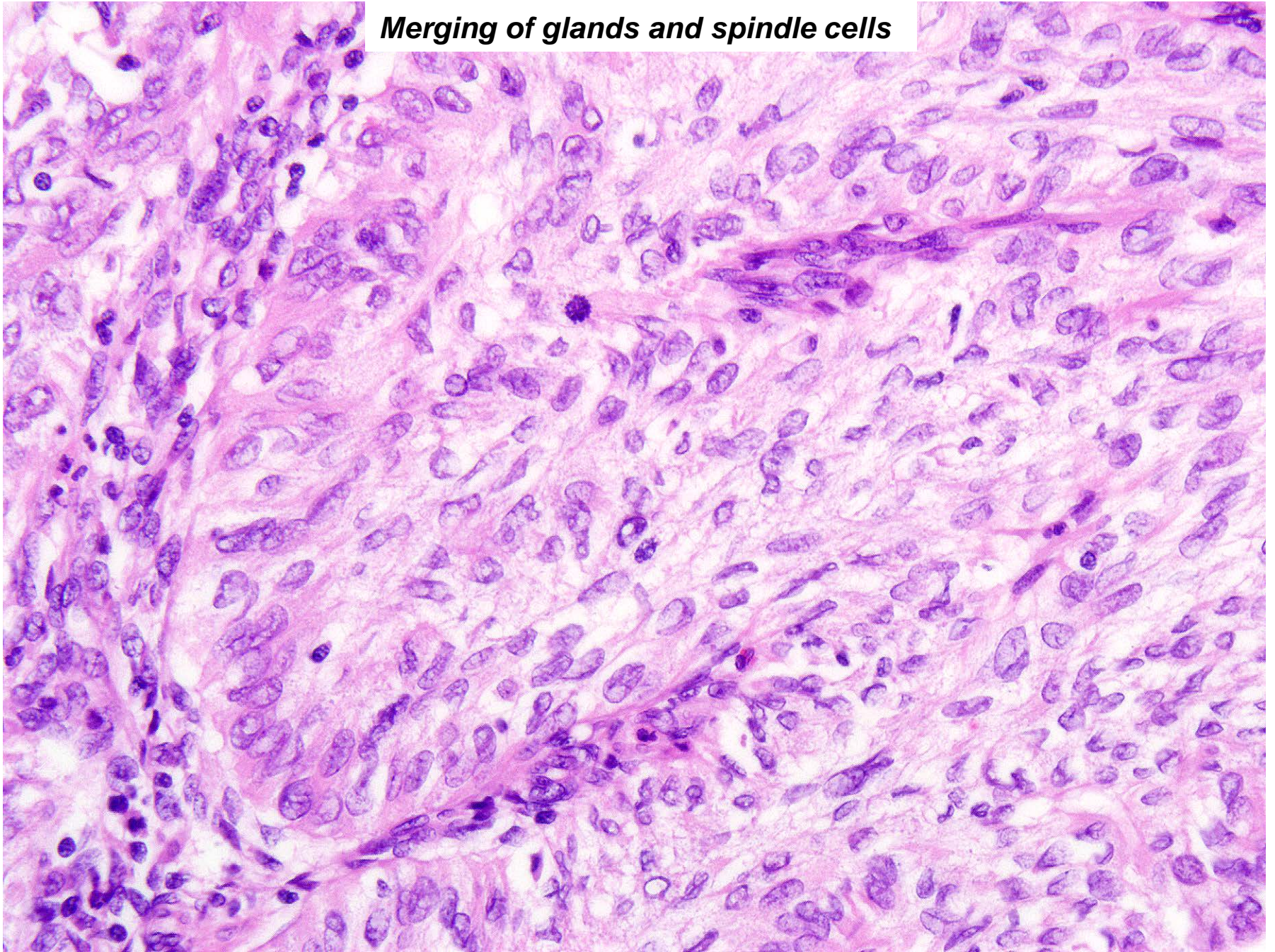
Endometrioid carcinoma with spindle cells

Merging of glands and spindle cells



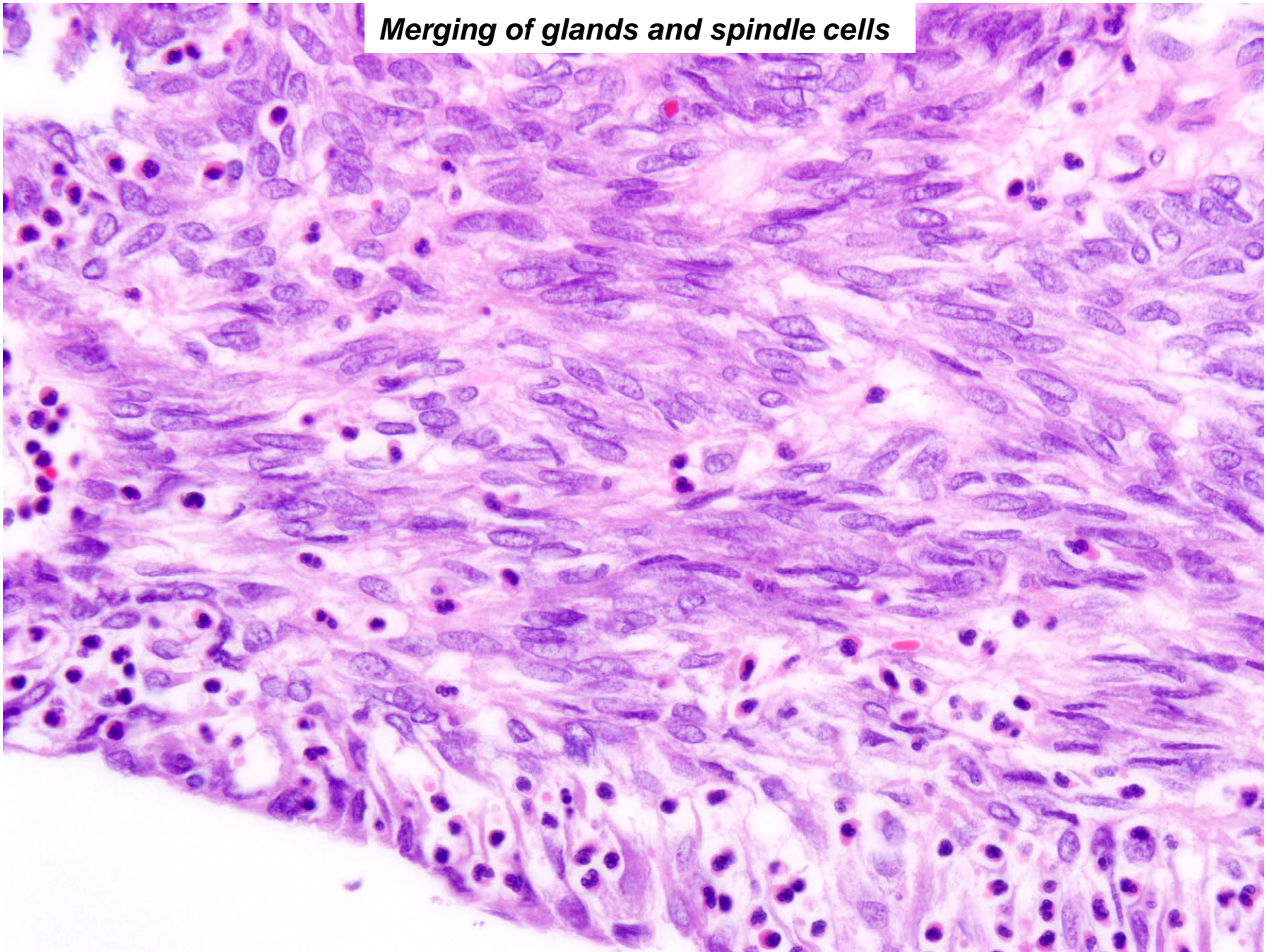
Endometrioid carcinoma with spindle cells

Merging of glands and spindle cells

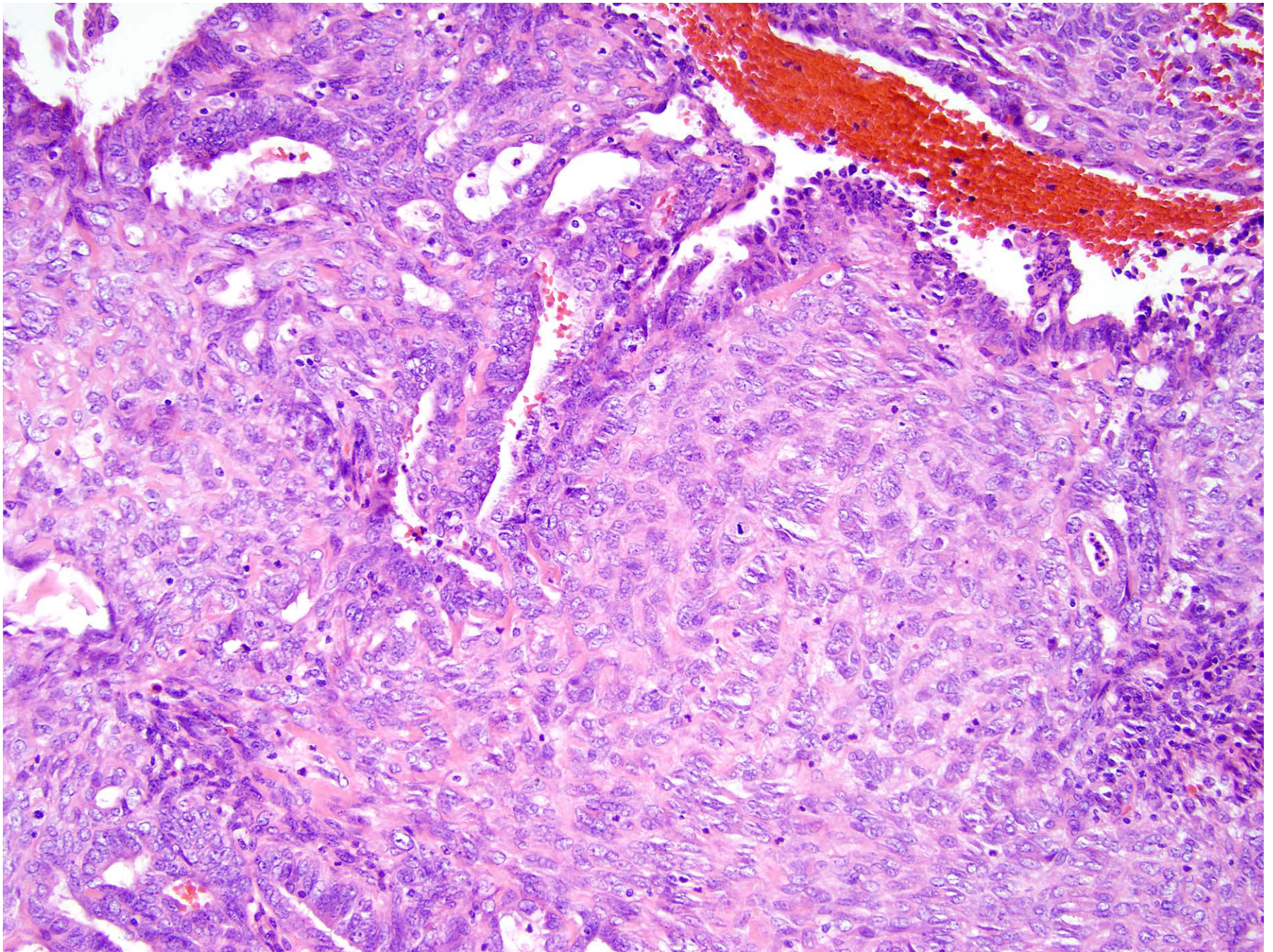


Endometrioid carcinoma with spindle cells

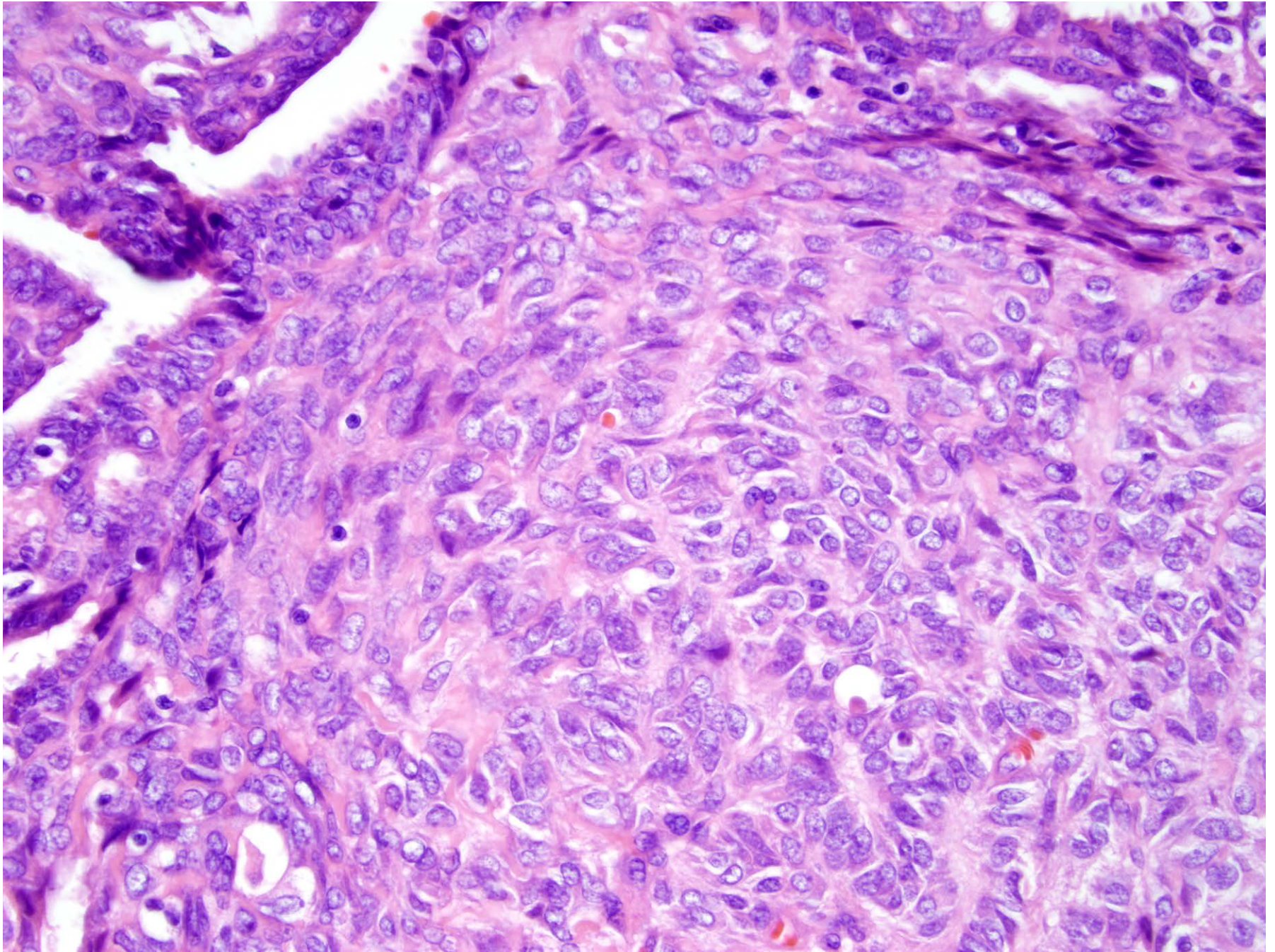
Merging of glands and spindle cells



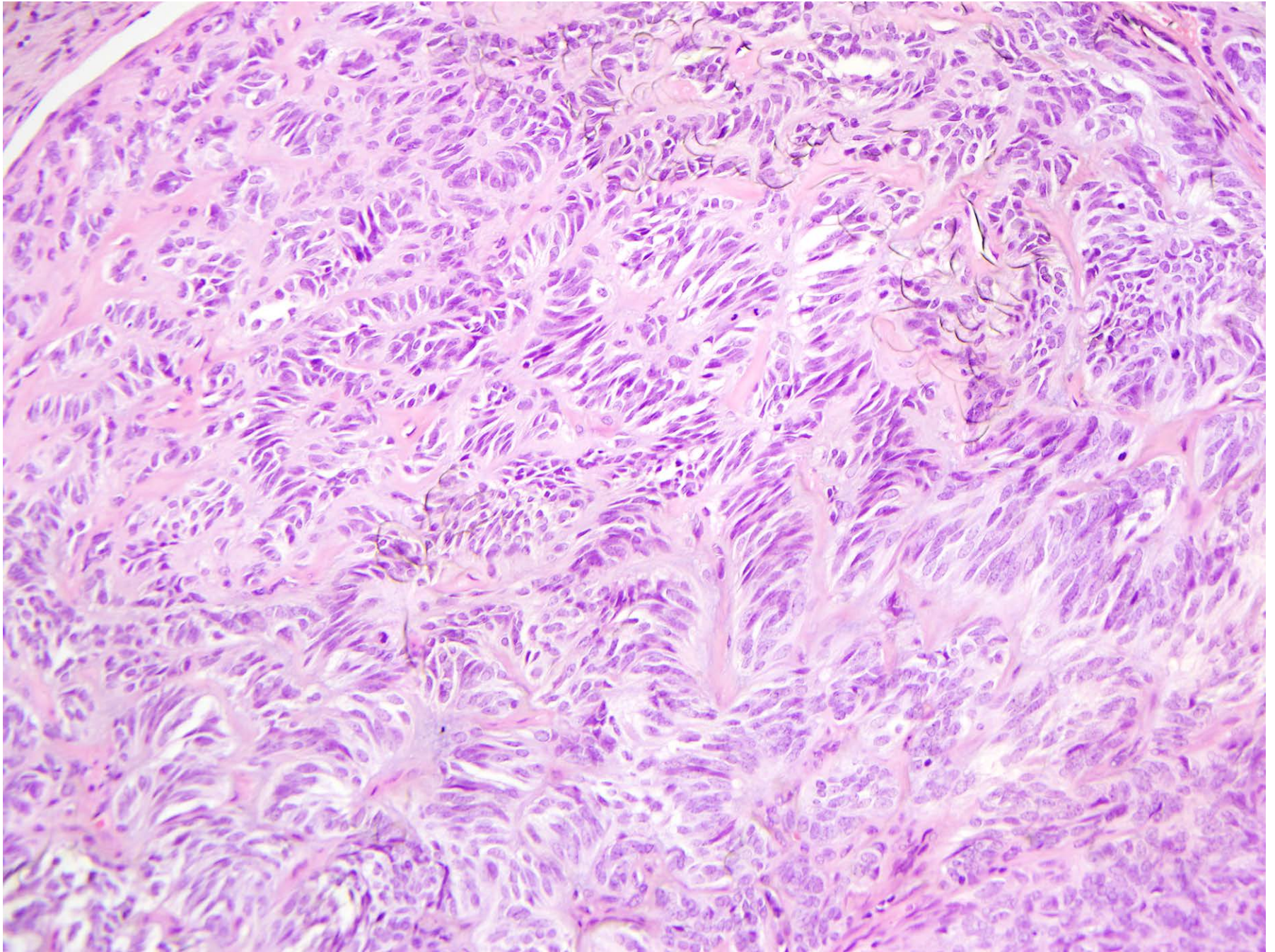
Endometrioid carcinoma, corded and hyalinized type



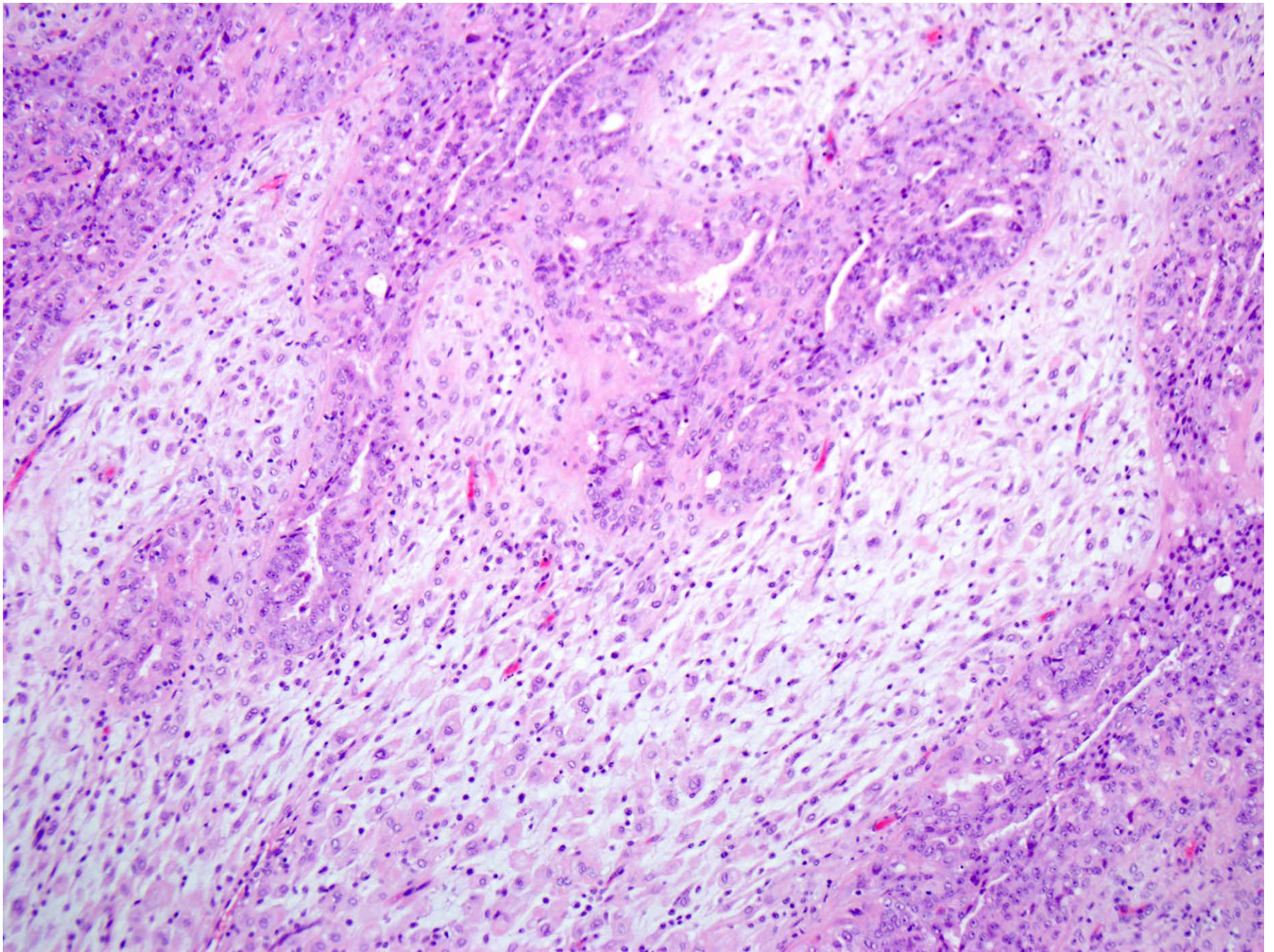
Endometrioid carcinoma, corded and hyalinized type



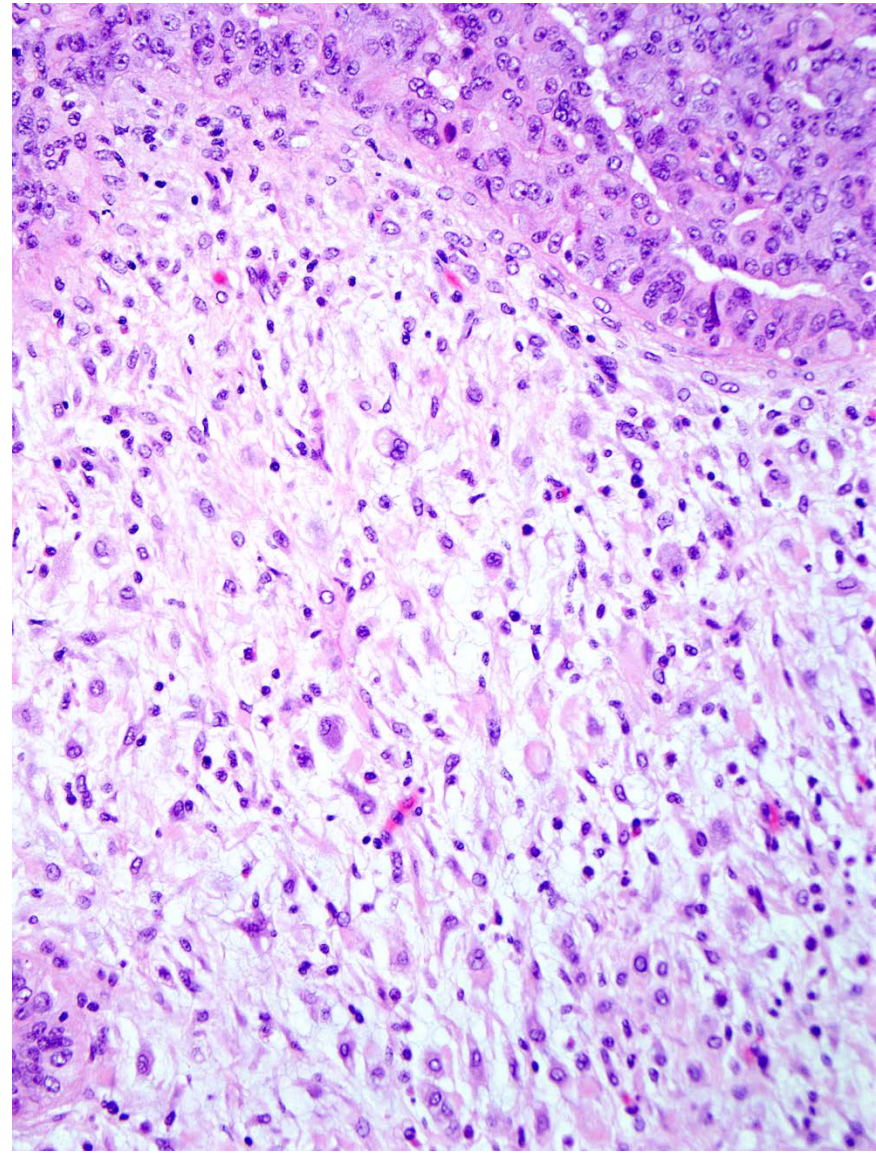
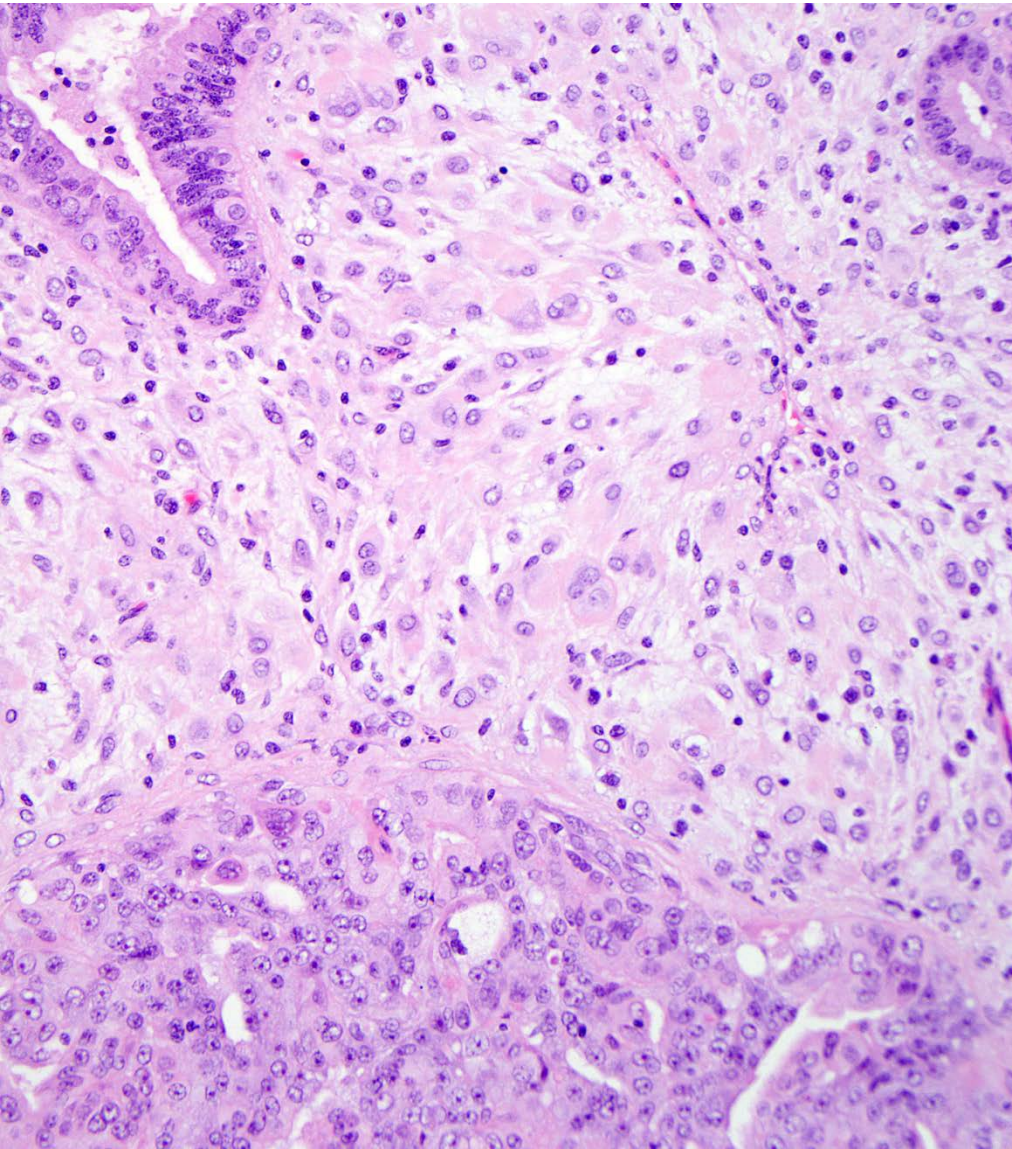
Endometrioid carcinoma, corded and hyalinized type



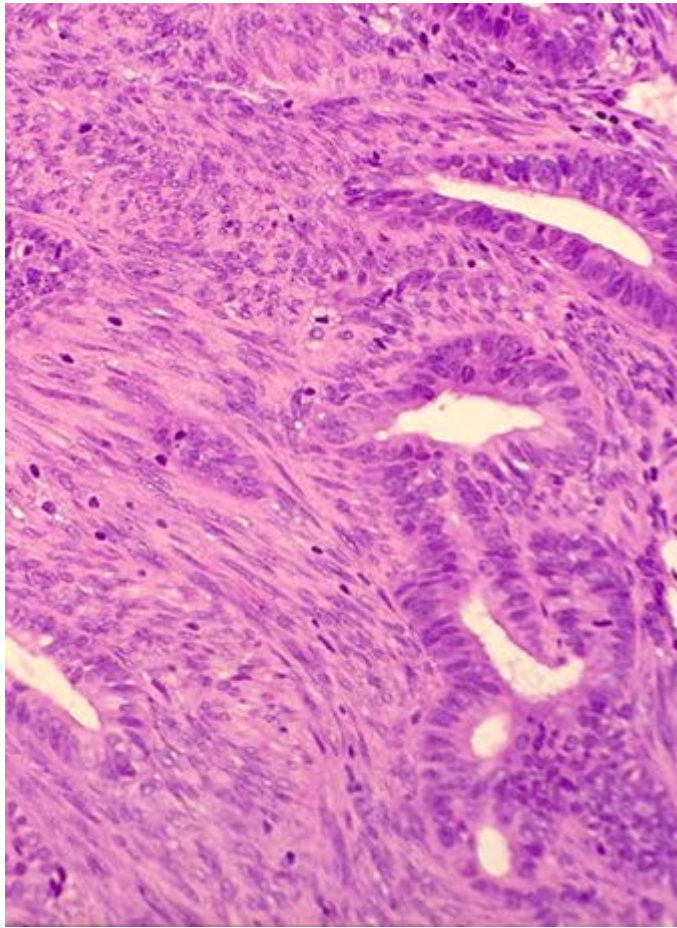
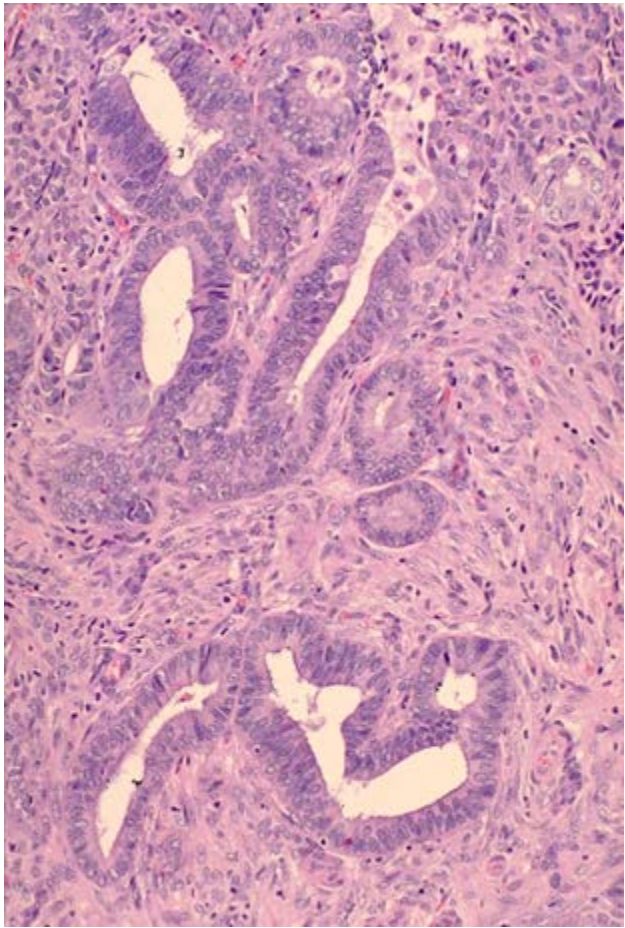
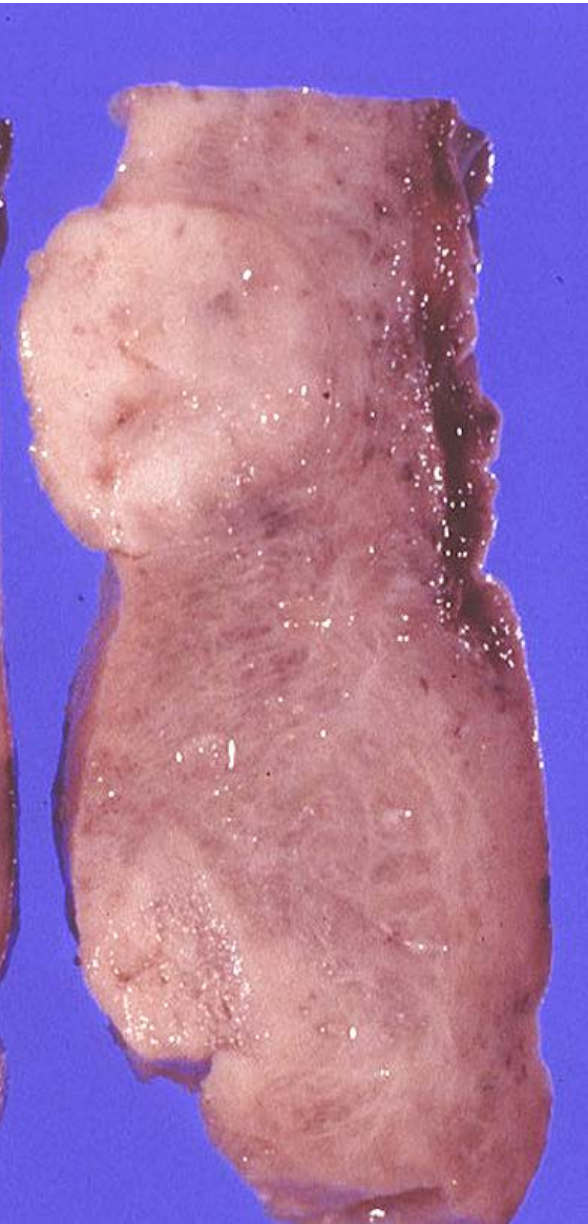Endometrioid carcinoma, partial response to progestins



Endometrioid carcinoma, partial response to progestins



Endometrioid carcinoma arising in atypical polypoid adenomyoma



Problematic Patterns of Uterine Cancer

- Glandular

- Papillary

- Spindled



- **Clear cell-rich**

- Necrosis in “low grade” tumor

- MELF-myoinvasion in low grade tumor

- Mucin-rich

- Solid pattern with high grade atypia

Clear cell-Rich Pattern

Low Risk Behavior

- Endometrioid adenocarcinoma with clear cells

High Risk Behavior

- Clear cell carcinoma
- Serous carcinoma with clear cells

What is the definition of endometrial clear cell carcinoma ?

- **Morphologic definition ?**
- **Immunohistochemical definition ?**
- **Molecular definition ?**

What is the definition of endometrial clear cell carcinoma ?

Even GYN pathologists cannot agree

ORIGINAL ARTICLE

The Diagnosis of Endometrial Carcinomas With Clear Cells by Gynecologic Pathologists: An Assessment of Interobserver Variability and Associated Morphologic Features

Oluwole Fadare, MD, Vinita Parkash, MD,† William D. Dupont, PhD,‡
Geza Acs, MD, PhD,§ Kristen A. Atkins, MD,|| Julie A. Irving, MD,¶
Edyta C. Pirog, MD,# Bradley J. Quade, MD, PhD,** M. Ruhul Quddus, MD,††
Joseph T. Rabban III, MD, MPH,‡‡ Russell Vang, MD,§§ and Jonathan L. Hecht, MD, PhD|||*

What is the definition of endometrial clear cell carcinoma ?

- Morphologic definition ?
- Immunohistochemical definition ?
- Molecular definition ?

2015 USCAP abstract #1125, DeLair et al.

29% exhibit “serous” carcinoma mutational profile

21% exhibit “endometrioid” carcinoma mutational profile

Clear Cell-rich Uterine Cancer

**Endometrioid
Carcinoma
With Clear Cells**

**Clear Cell
Carcinoma**

Cell shape

Columnar

Polygonal

Cell polarity

Preserved

Lost

**Tubulocystic plus
papillary growth**

Not common

Yes

Hyaline globules

No

Yes

Hyalinized stroma

No

Yes

Hobnail growth

No

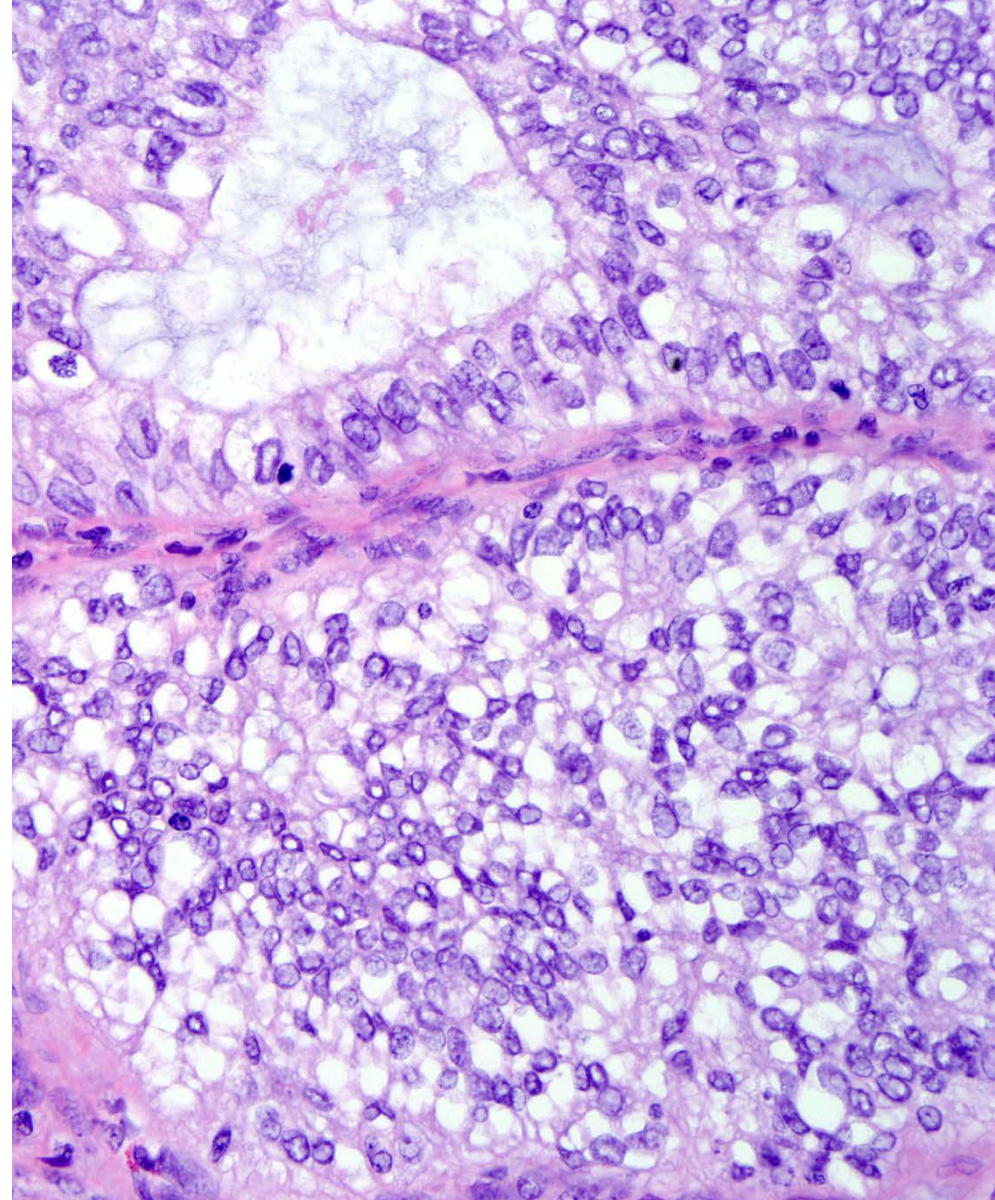
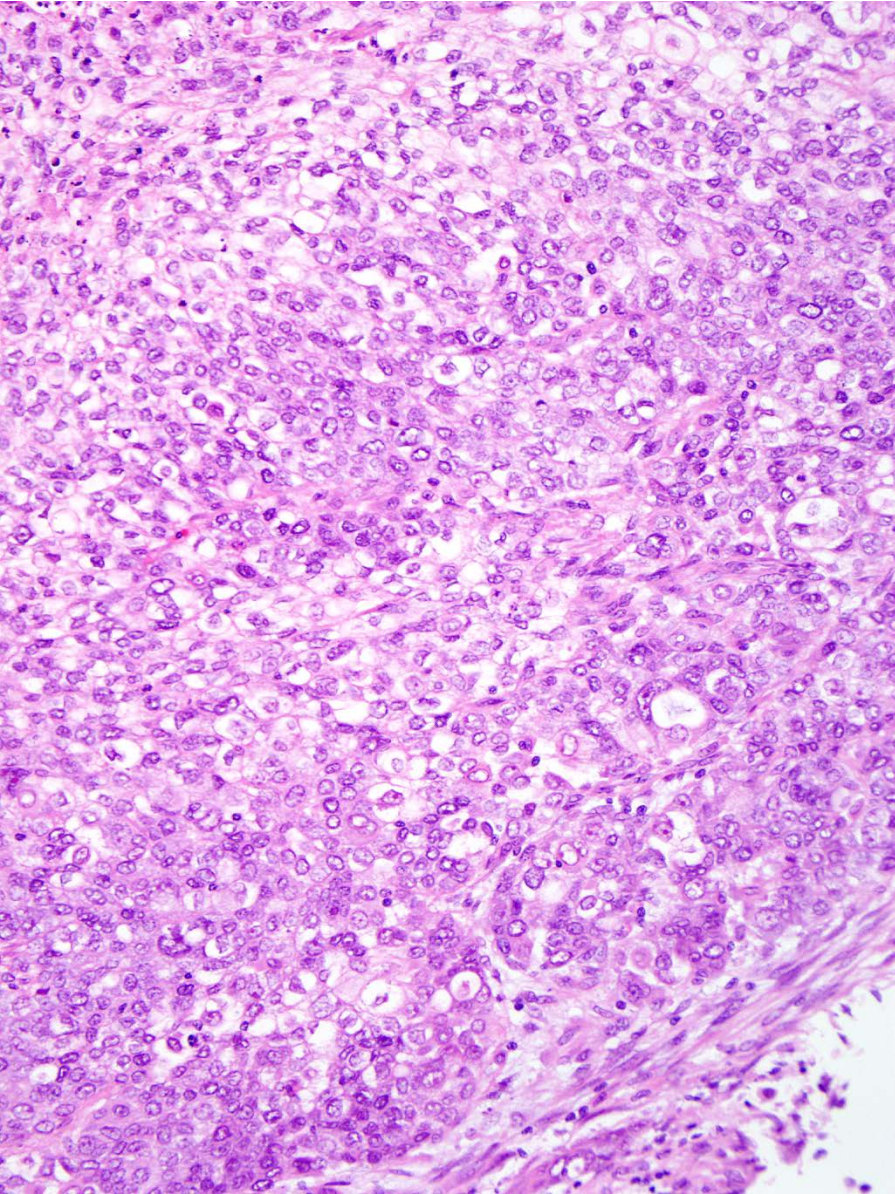
Yes

Open tumor rings

No

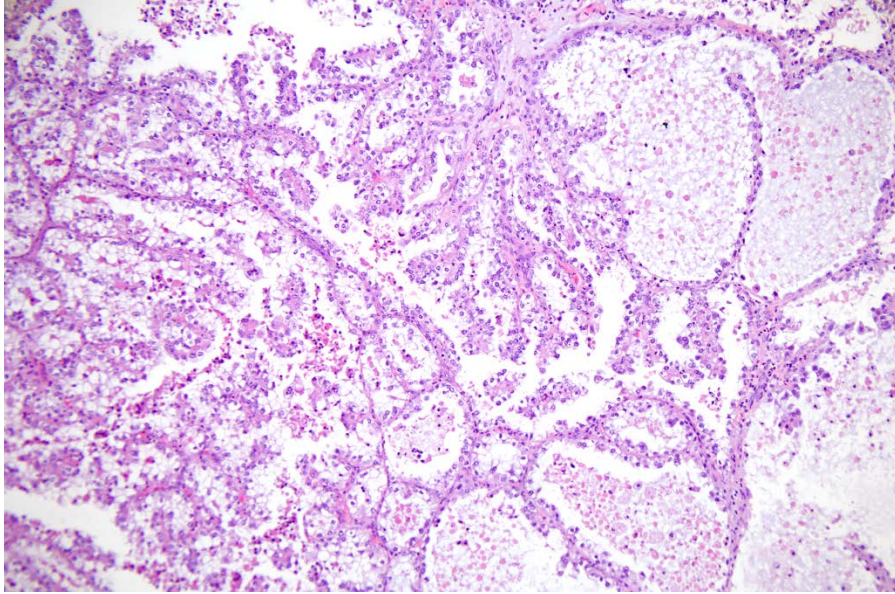
Yes

Endometrioid adenocarcinoma with clear cells

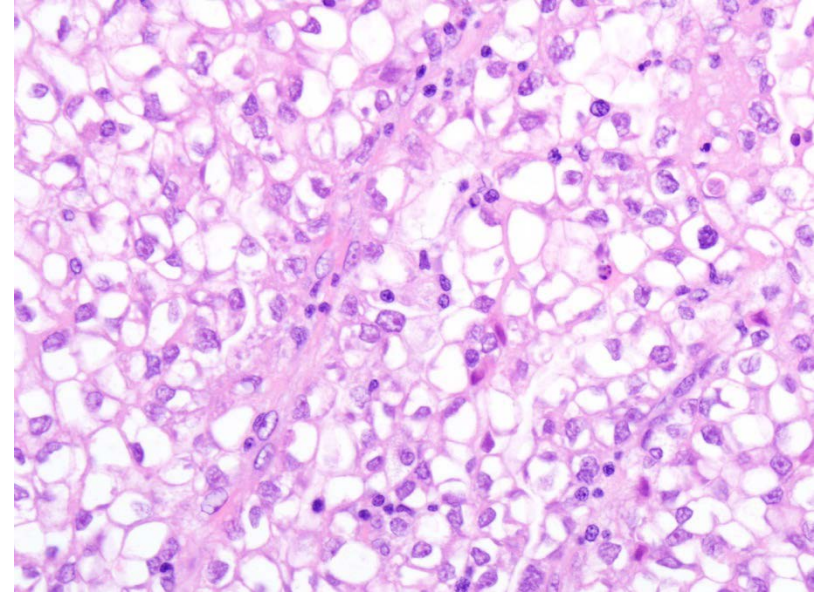


Clear cell carcinoma

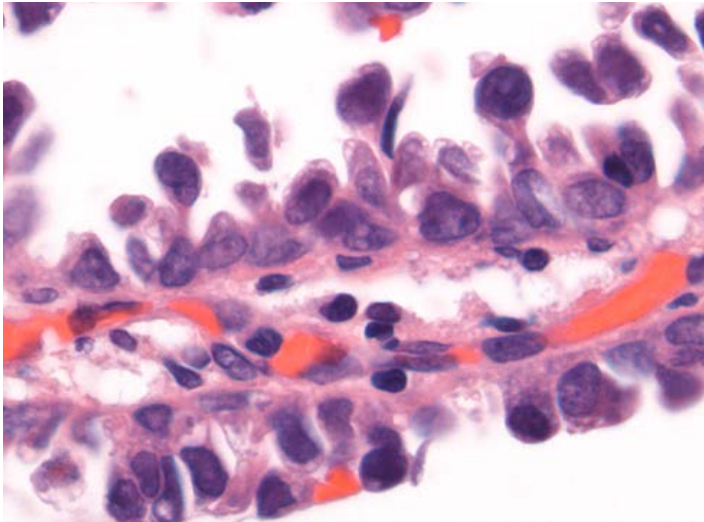
Papillary / tubulocystic



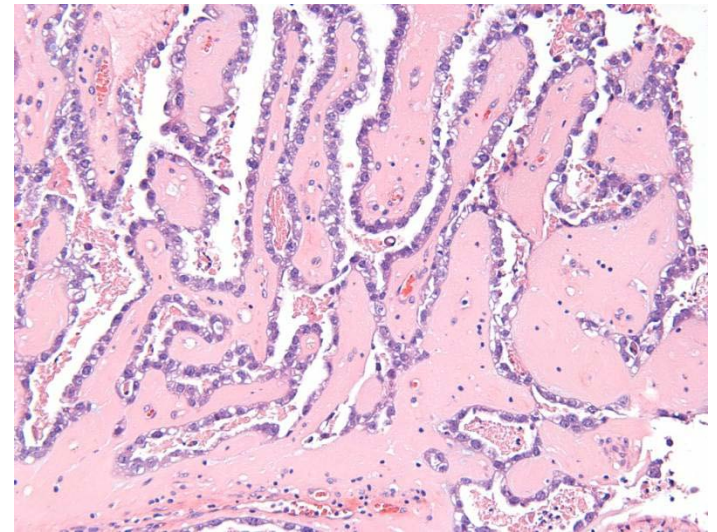
Solid



Hobnail



Hyaline stroma



Immunophenotype of Uterine Clear Cell Carcinoma

Mostly a “negative” profile

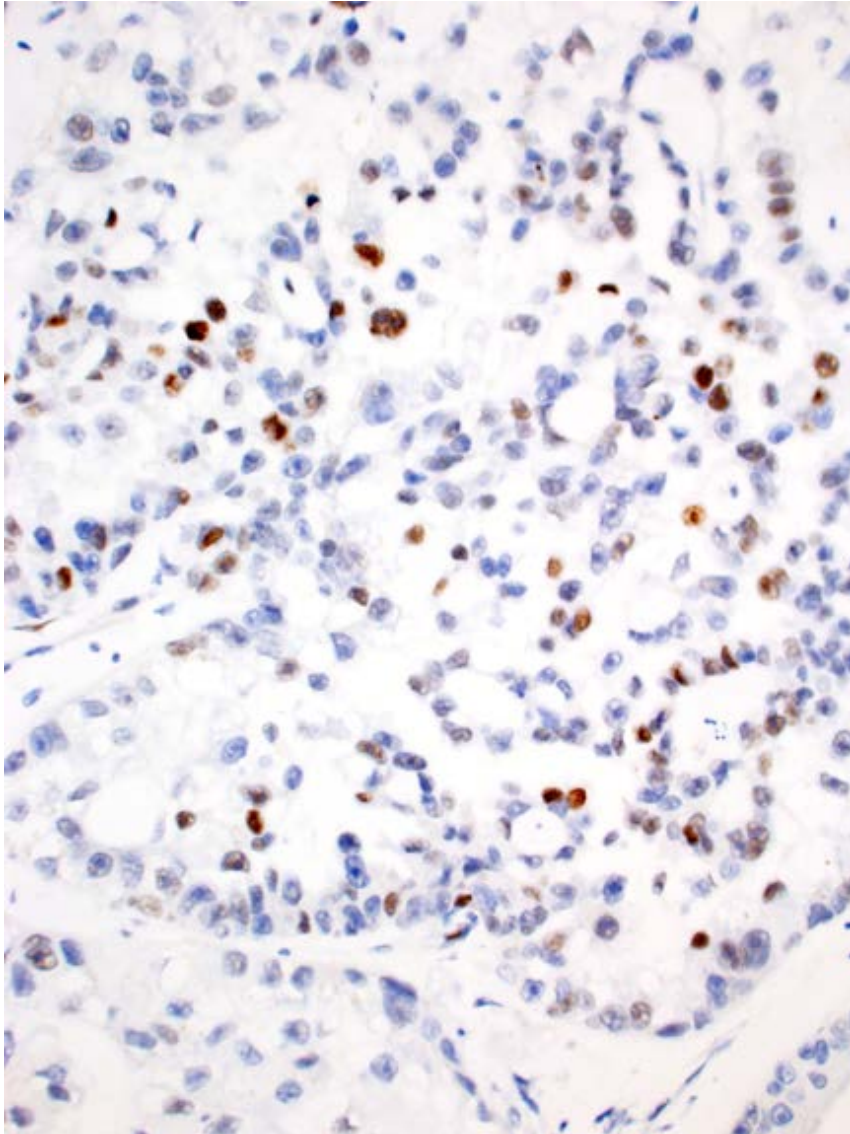
ER **negative or focal**

p53 **wild type**

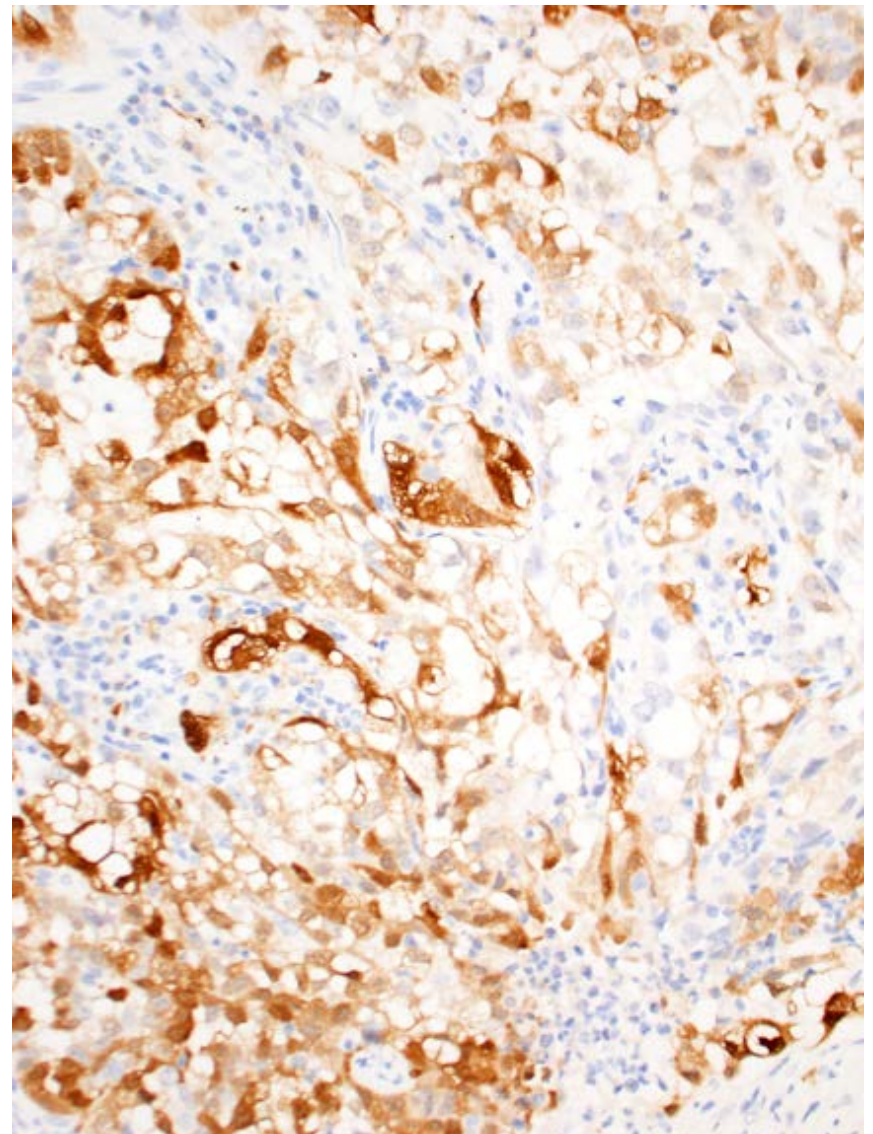
p16 **wild type**

Uterine clear cell carcinoma

p53 wild type



p16 wild type



Function

- Hepatocyte nuclear factor 1 homeobox B
- Transcription factor for glucose/glycogen homeostasis, anti-apoptosis
- Expressed in liver, GI, pancreas, kidney

Tumor Marker

- Ovarian clear cell carcinoma

Sensitivity	92%
Specificity	78%

HNF-1 B

	OVARY	UTERUS
Clear cell	94 - 98 %	73 - 100 %
Endometrioid	0 - 40 %*	0 - 35 %*
Serous	0 - 30 %*	0 - 60 %*
Secretory phase Gestational phase Arias Stella reaction	positive	

Kao 2012 Histopathol
Delair 2011 AJSP
Kobel 2009 AJSP
Kato 2006 Mod Pathol
Yamamoto 2007 Hum Pathol

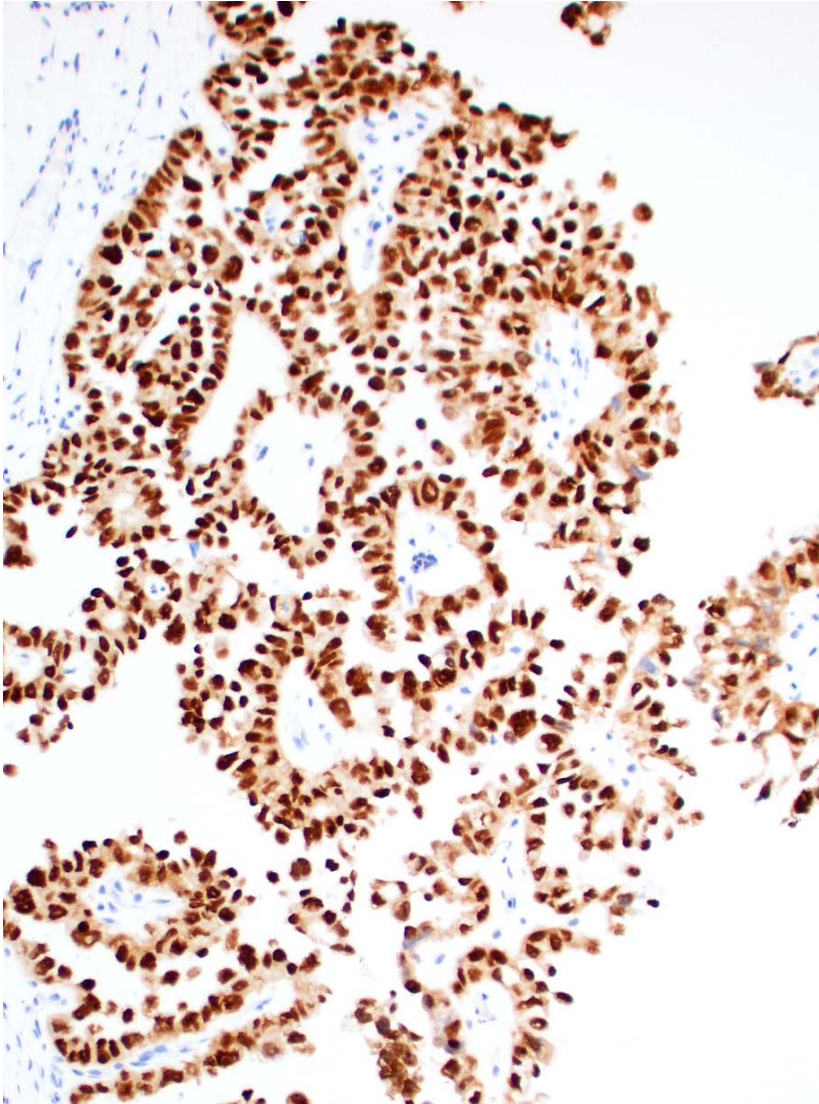
Yamamoto 2007 Hum Pathol
Fadare 2012 AIMM

*weak/patchy staining

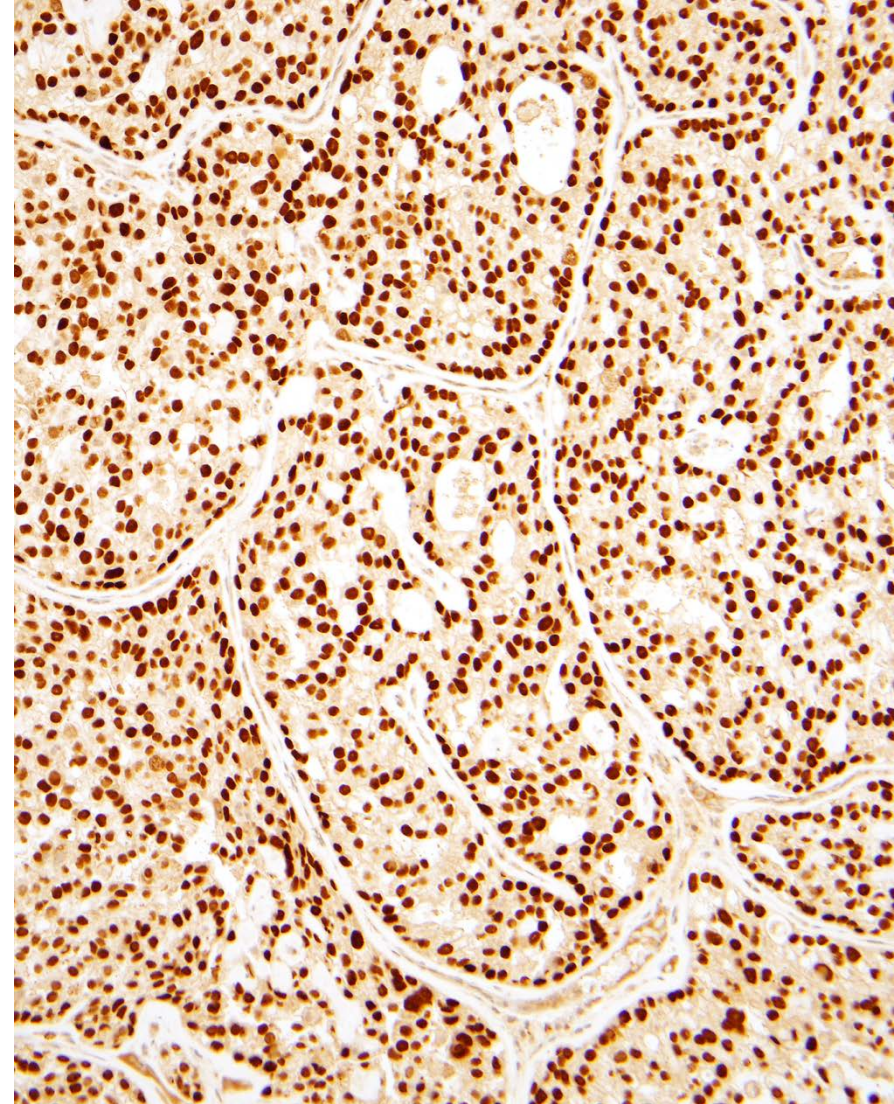
Uterine Clear Cell Carcinoma

HNF-1

Papillary pattern



Tubuloglandular pattern



Napsin A

Function

- **Protease**
- **Expressed in type II pneumocytes, proximal renal tubules**

Tumor Marker

- **Pulmonary adenocarcinoma**
- **Papillary renal cell carcinoma**

- **Ovarian clear cell carcinoma**

Sensitivity	82%
Specificity	99%



0 % Serous carcinoma
<10 % Endometrioid carcinoma

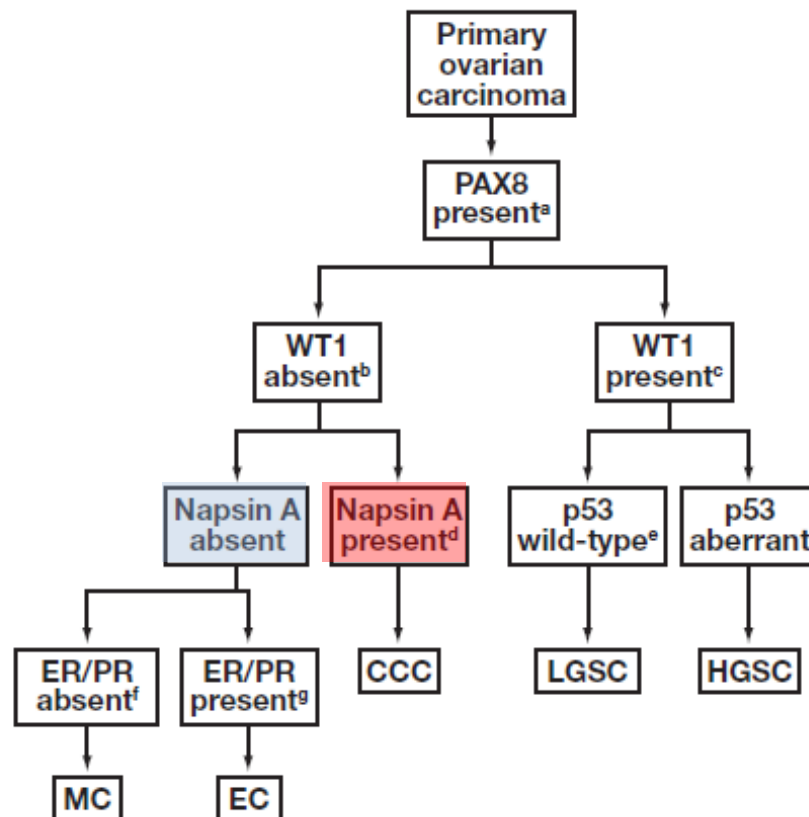
Napsin A

Another Milestone in the Subclassification of Ovarian Carcinoma

Martin Köbel, MD, and Máire A. Duggan, MD, FRCPC

From the Department of Pathology and Laboratory Medicine, University of Calgary and Calgary Laboratory Services, Calgary, Alberta, Canada.

Am J Clin Pathol December 2014;142:735-737



Napsin A in Uterine Cancer

Staining:

Pattern	Punctate cytoplasmic granules
Distribution	Diffuse
Intensity	Moderate to strong

Expression pattern:

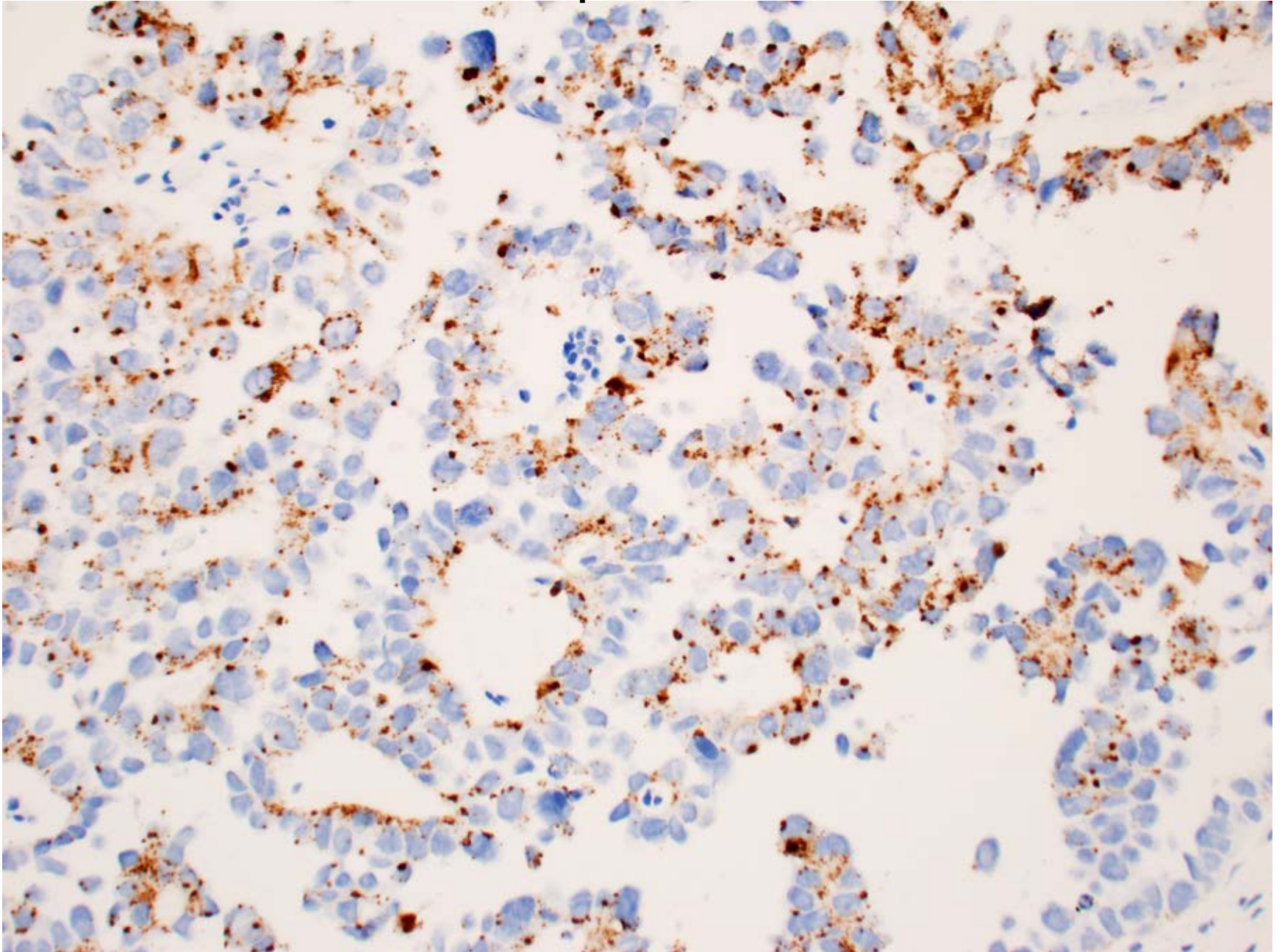
Clear cell carcinoma	88 %
Endometrioid adenocarcinoma	7 %
Serous carcinoma	0



98% Specificity

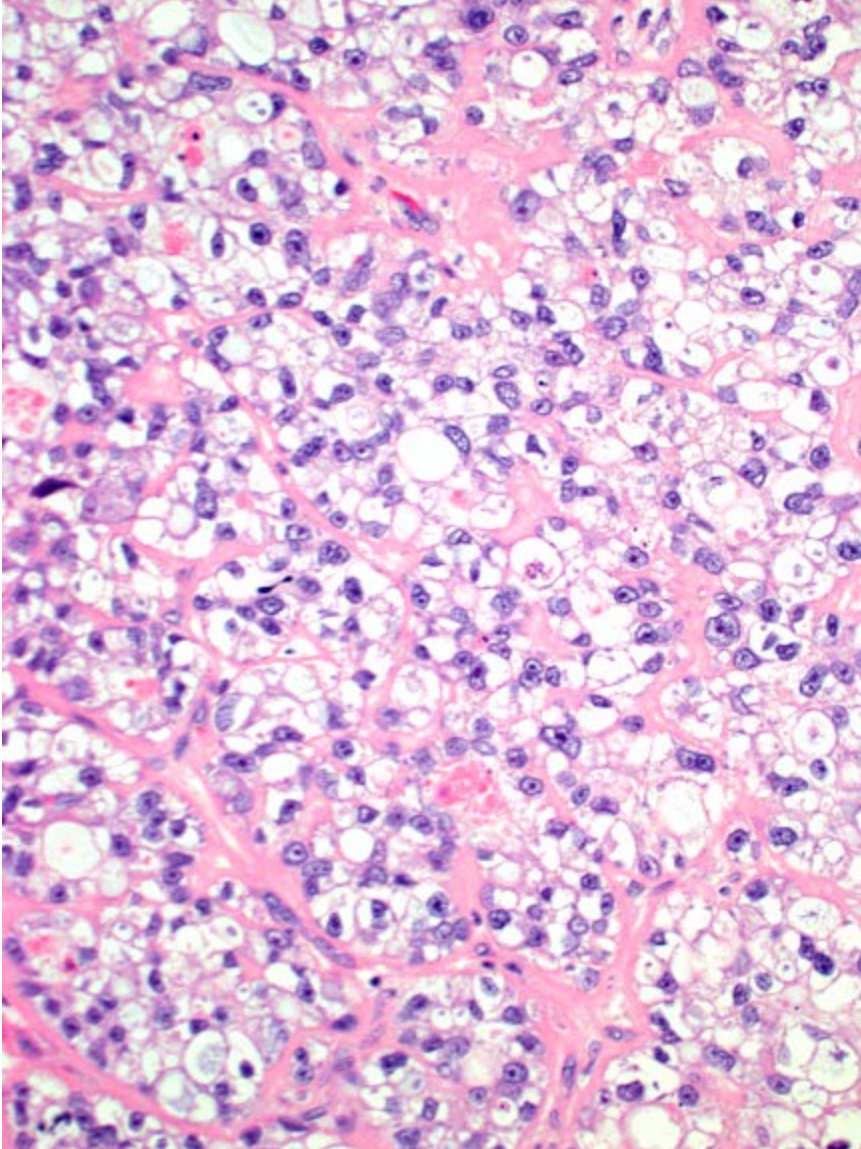
Uterine clear cell carcinoma

Napsin A

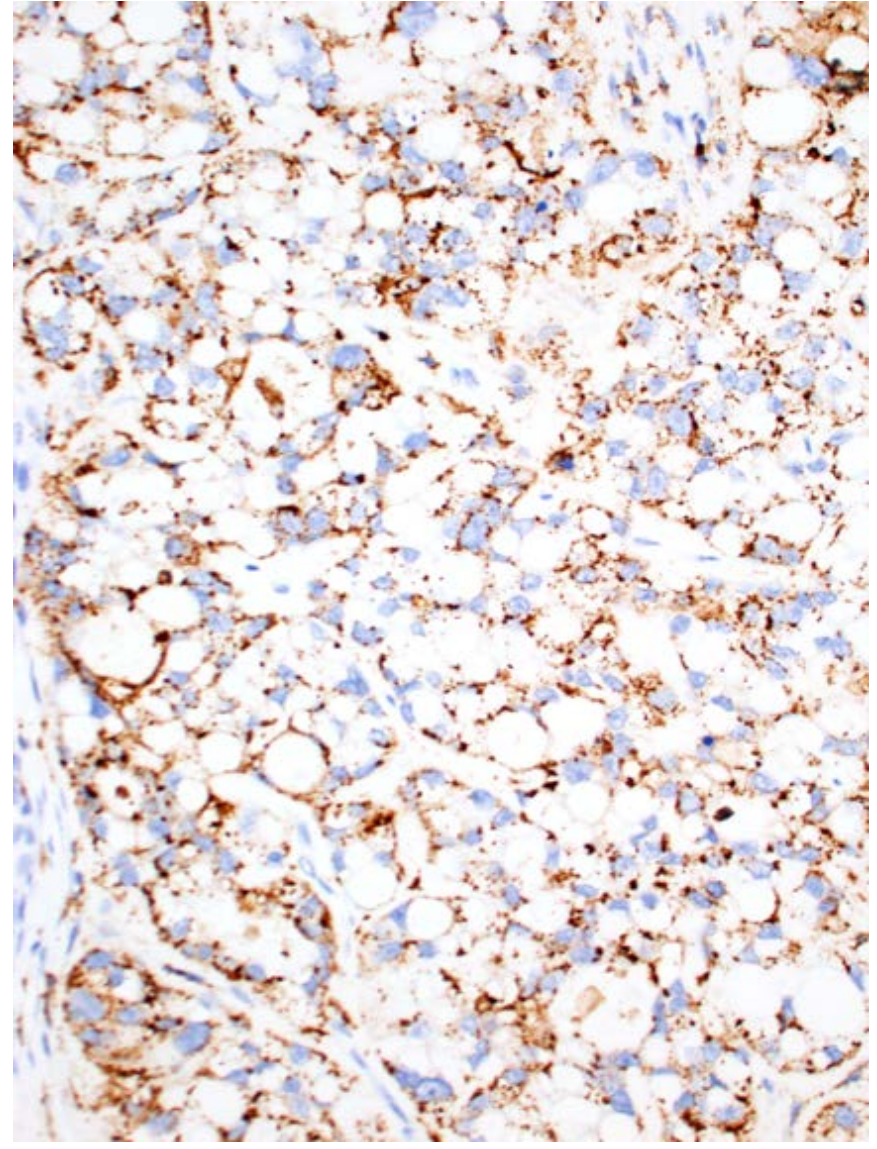


Uterine clear cell carcinoma

Solid pattern

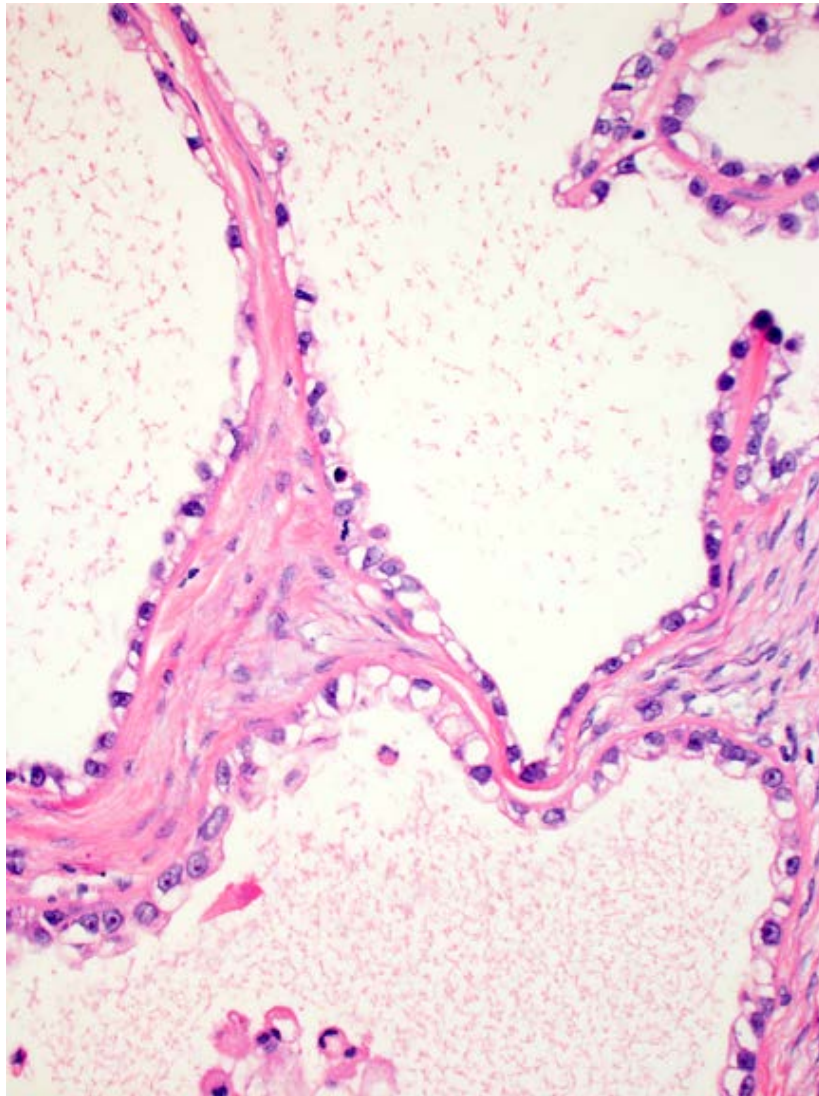


Napsin A

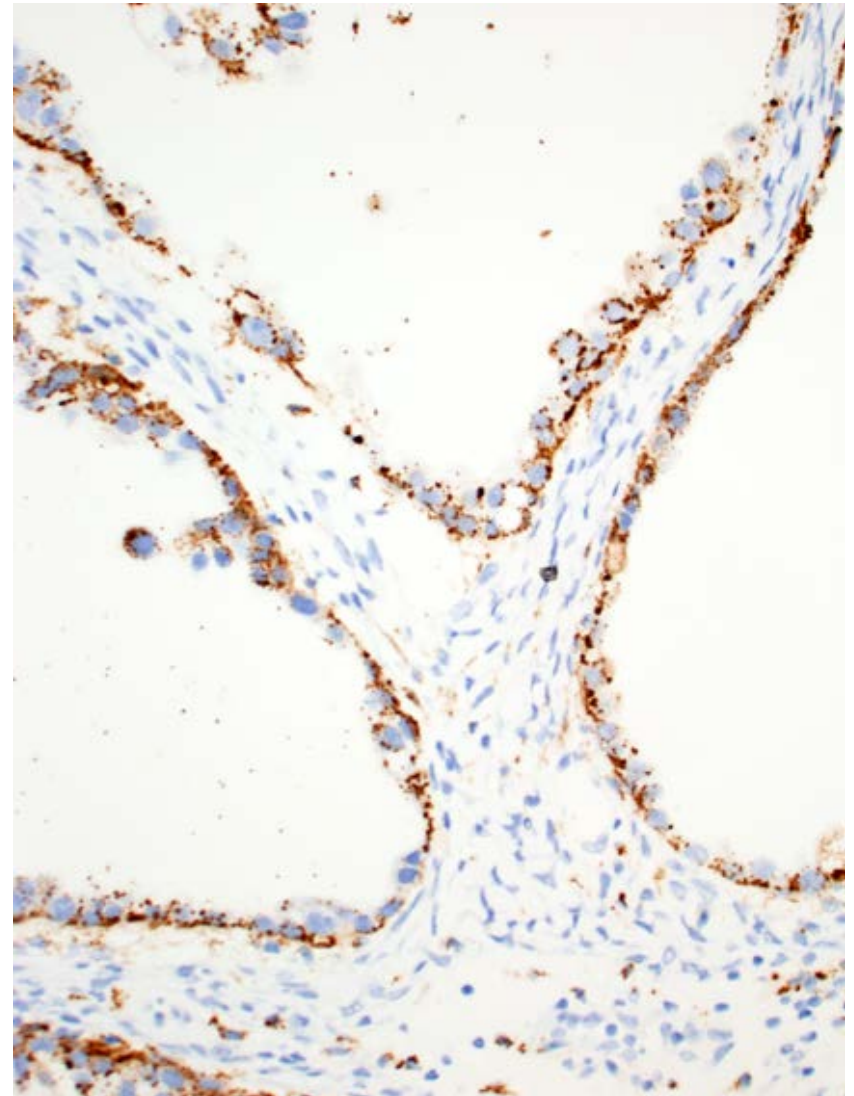


Uterine clear cell carcinoma

Tubulocystic pattern

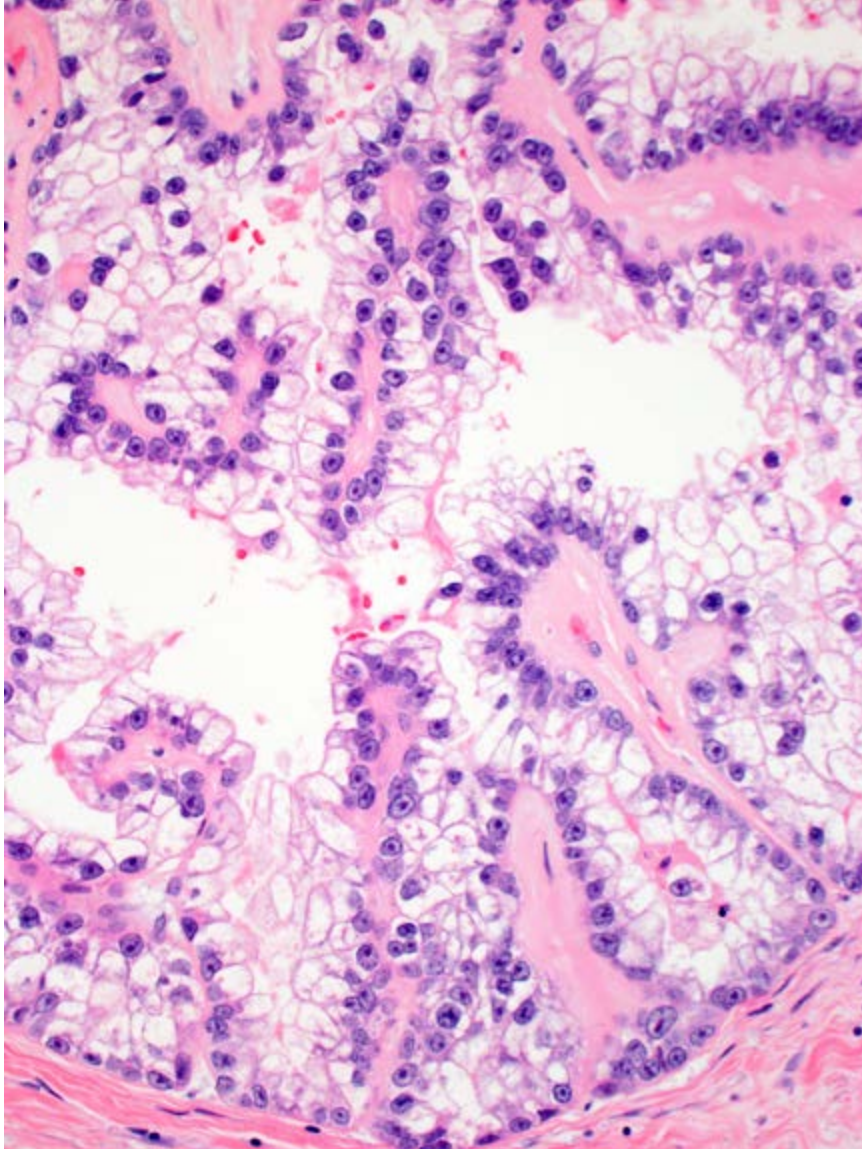


Napsin A

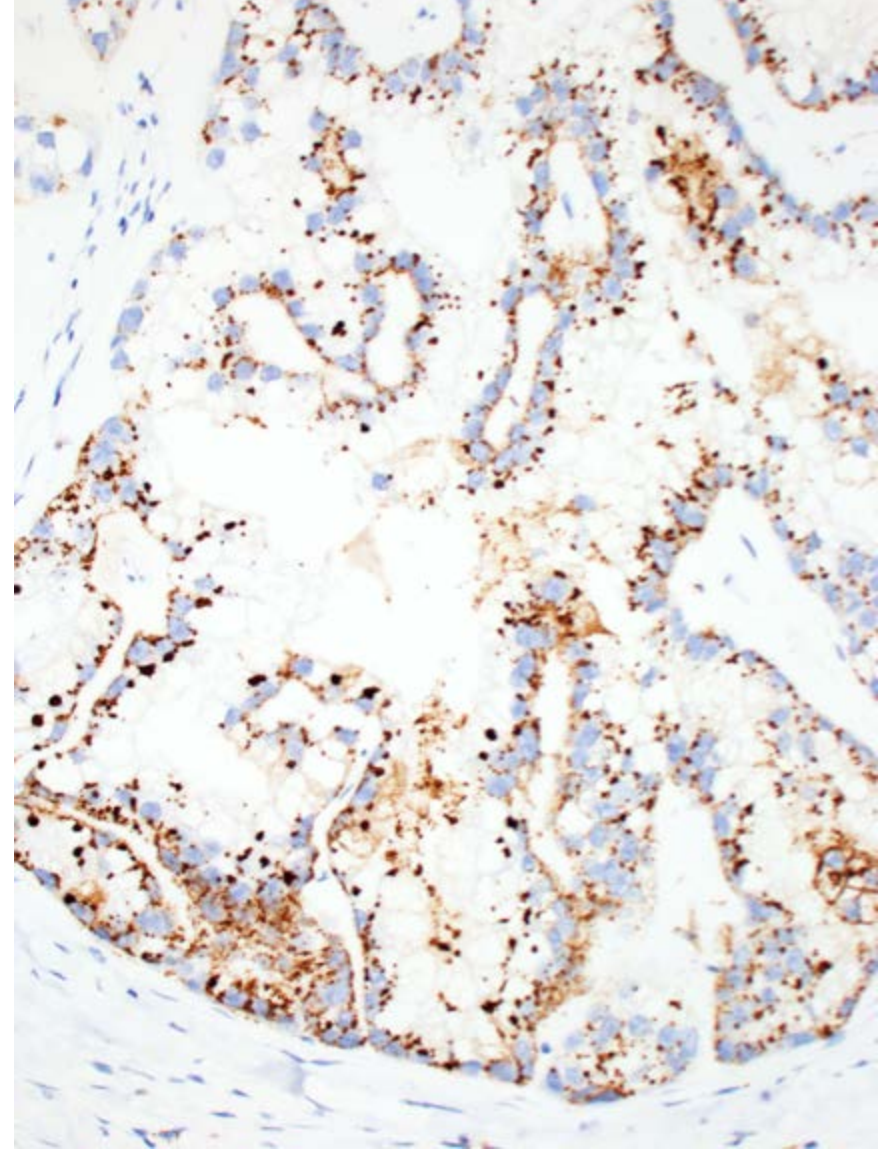


Uterine clear cell carcinoma

Tubuloglandular pattern



Napsin A



Uterine clear cell carcinoma

Napsin A **Diffuse, strong**

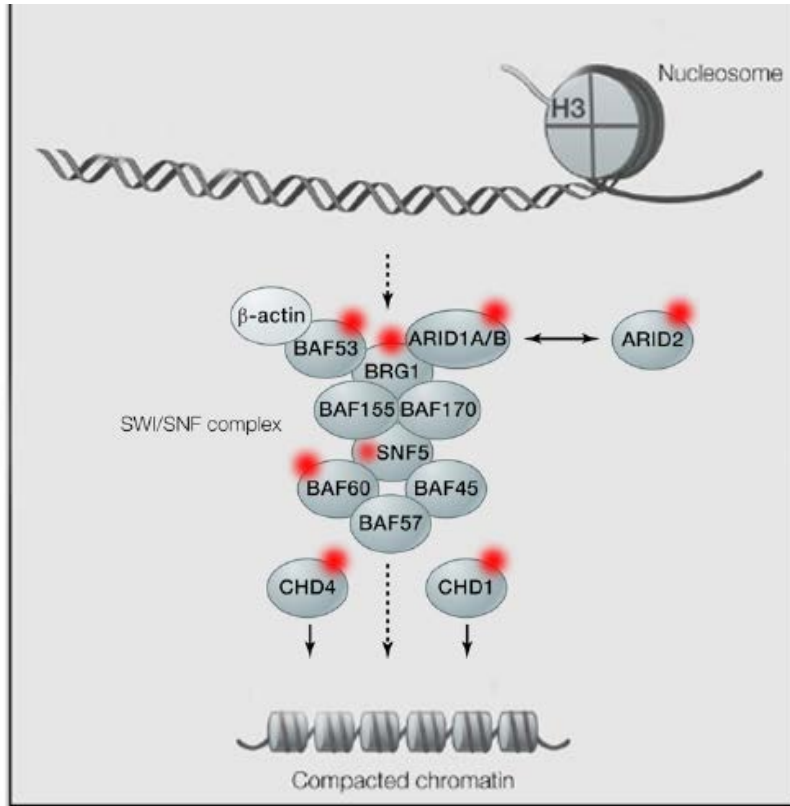
HNF1 **Diffuse, strong**

p53, p16 **Wild type**

ER **Variable**

ARID1A Mutation

**Common in Clear Cell Cancer
Endometrioid Cancer**



Cell 153, March 28, 2013

TCGA 2013 Nature
Jones 2010 Science
Wiegand 2010 NEJM

ARID1A Loss by IHC

Endometrioid, grade 1 or 2	29 %
Endometrioid, grade 3	39 %
Clear cell carcinoma	26 %
Serous carcinoma	18%

Wiegand 2011 J Pathol

Problematic Patterns of Uterine Cancer

- Glandular
- Papillary
- Spindled
- Clear cell-rich



Necrosis in “low grade” tumor

- MELF-myoinvasion in low grade tumor
- Mucin-rich
- Solid pattern with high grade atypia

Necrosis in biopsy containing low grade tumor

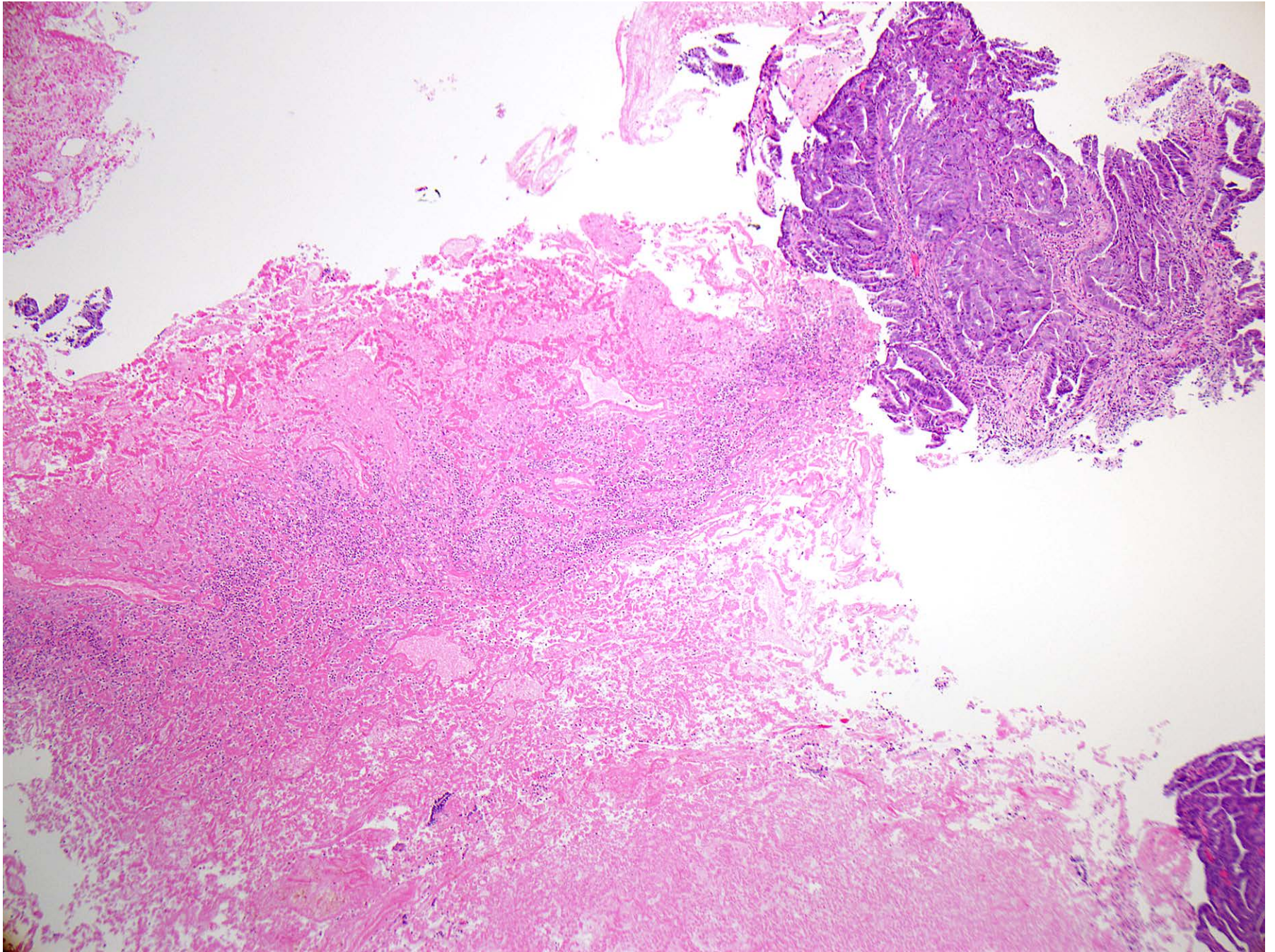
Low Risk Behavior

- Endometrioid adenocarcinoma with ischemic degeneration

High Risk Behavior

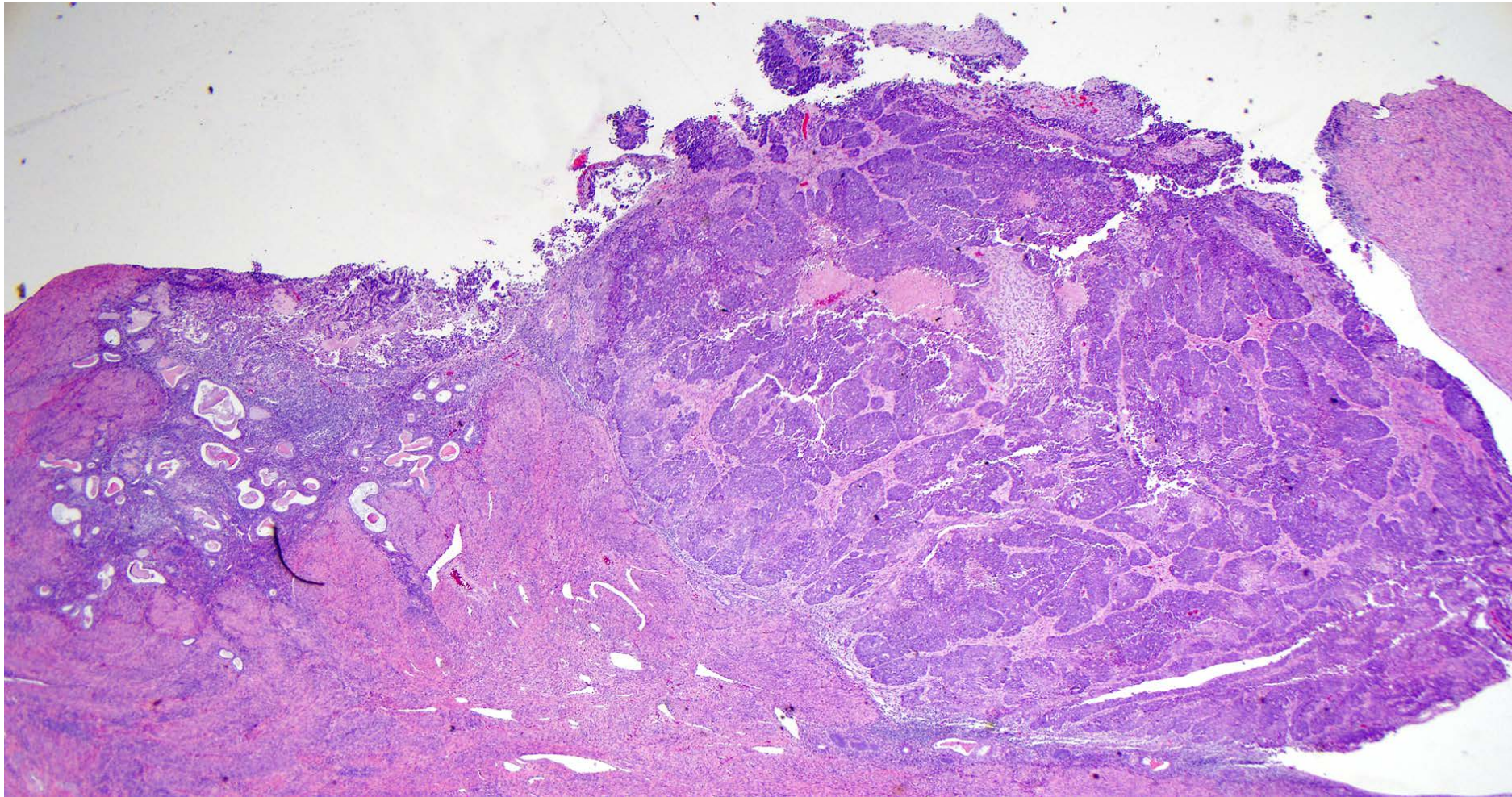
- Undersampled high grade tumor
 - Dedifferentiated cancer
 - Grade 2 or 3 endometrioid adenocarcinoma
 - Carcinosarcoma
 - Neuroendocrine carcinoma
- Myoinvasion

Necrosis + low grade adenocarcinoma

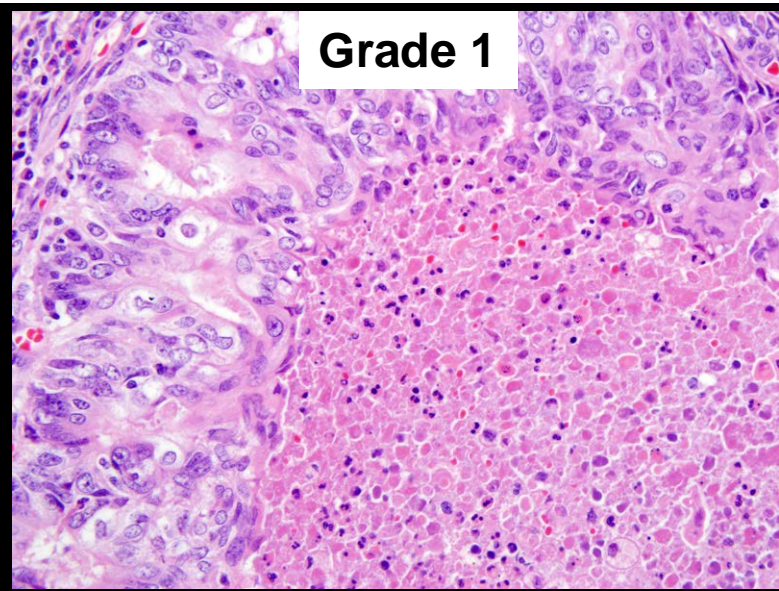


Biopsy = Grade 1 Endometrioid cancer with necrosis

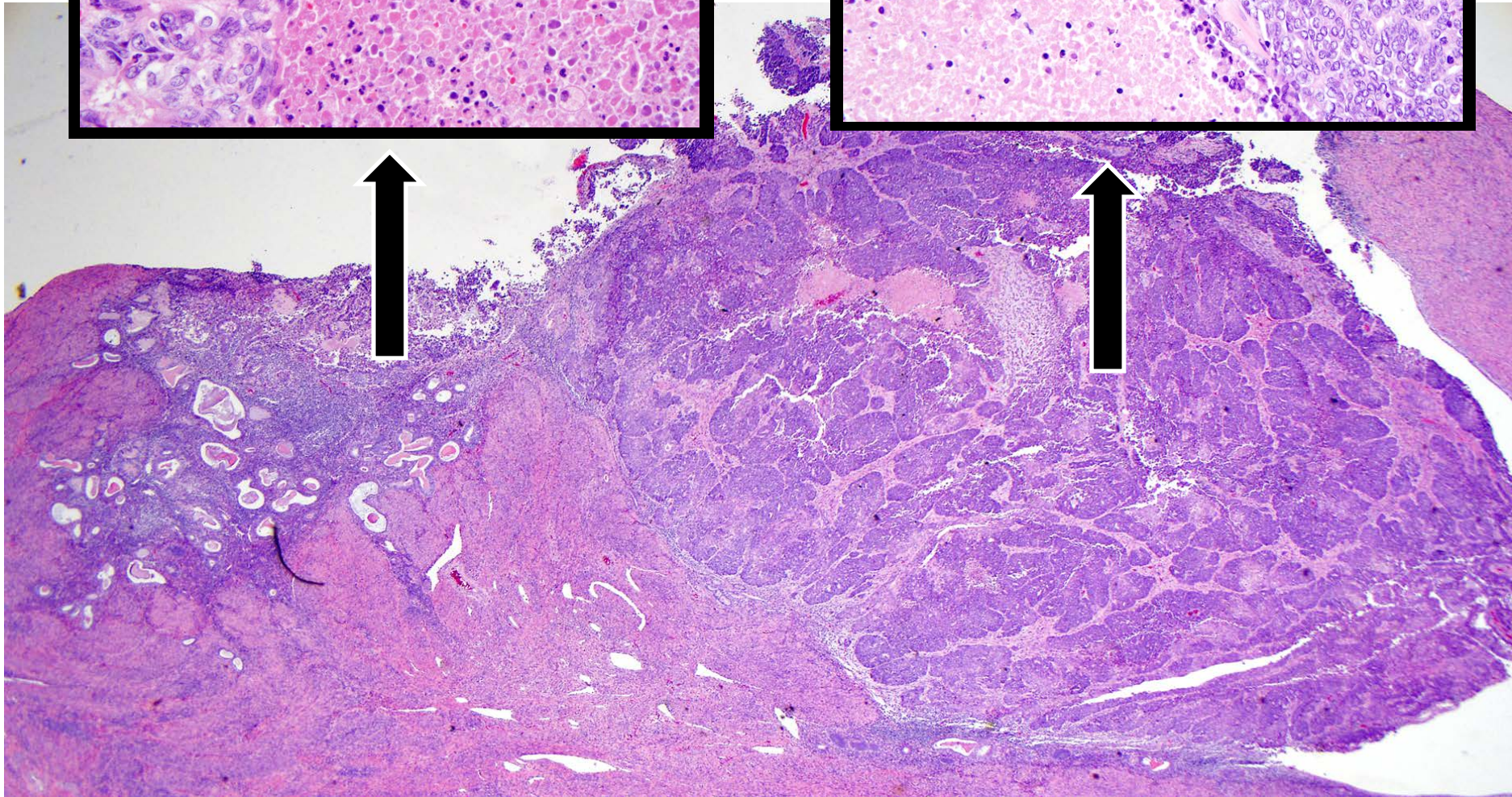
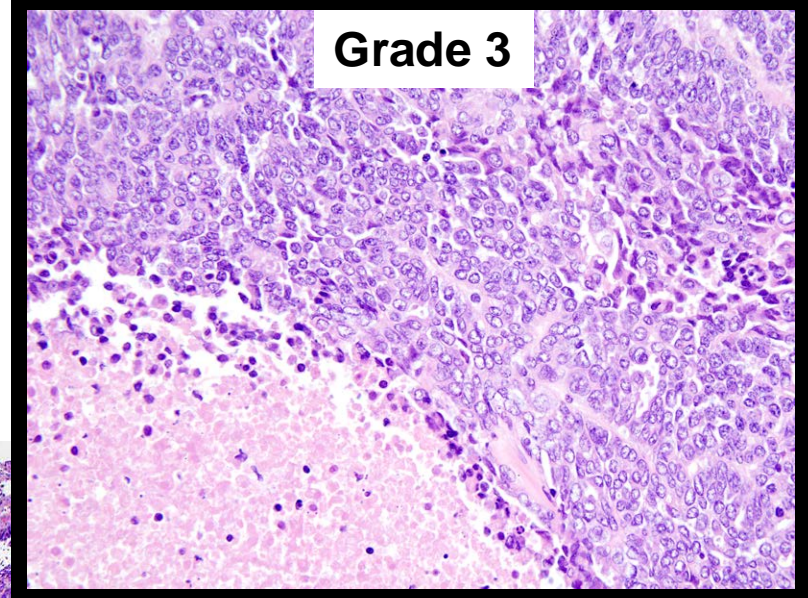
Hysterectomy = Grade 3 Endometrioid cancer



Grade 1



Grade 3



Necrosis in biopsy with low grade tumor

Biopsy reporting:

“Adenocarcinoma with extensive necrosis; see comment.

Comment: discuss differential diagnosis.

Problematic Patterns of Uterine Cancer

- Glandular
- Papillary
- Spindled
- Clear cell-rich
- Necrosis in “low grade” tumor
- MELF-myoinvasion in low grade tumor
- Mucin-rich
- Solid pattern with high grade atypia

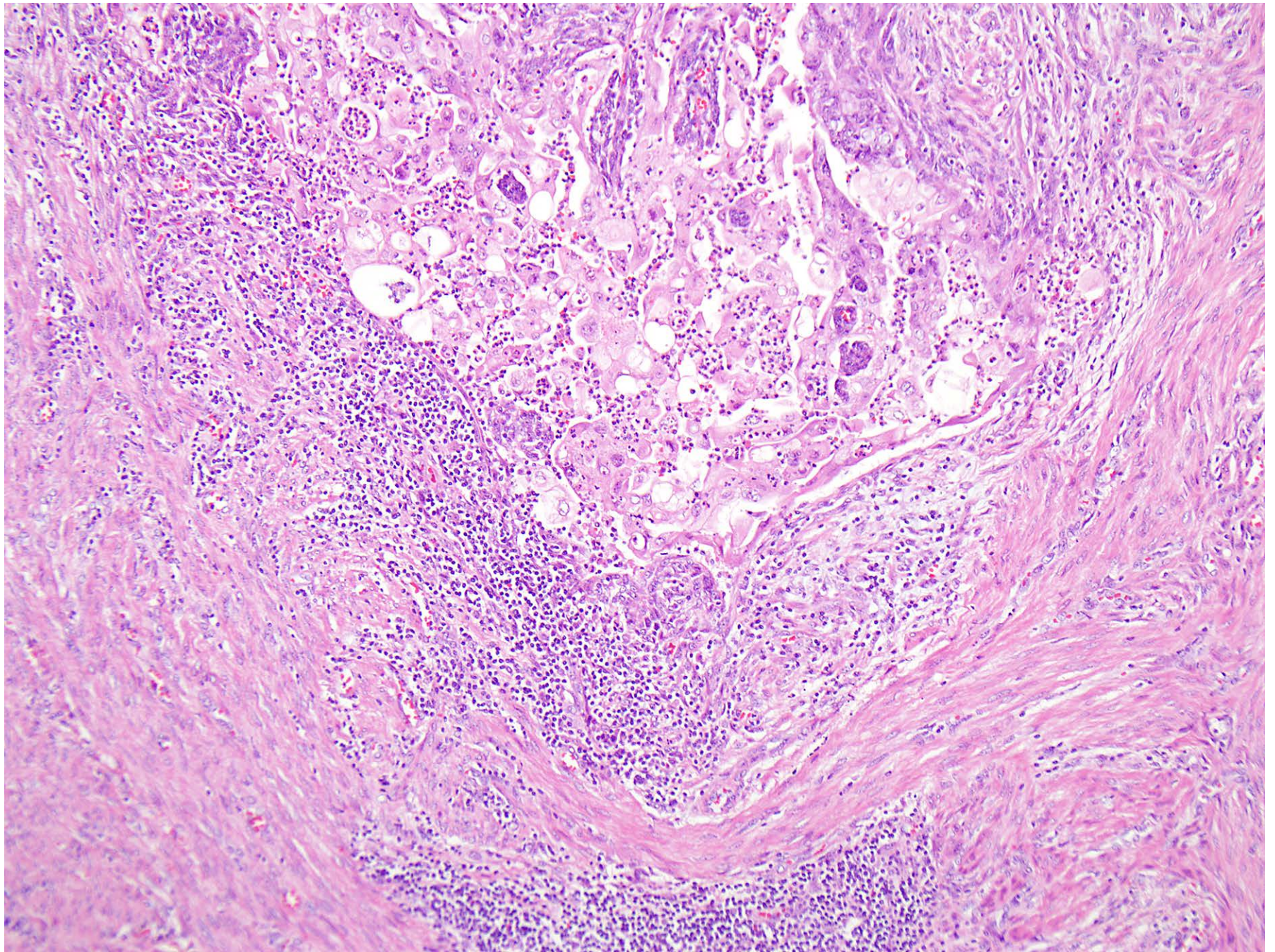
MELF-pattern Myoinvasion

- **MELF = Microcystic, Elongated, Fragmented Pattern**
 - **Seen in grade 1 endometrioid adenocarcinomas**
 - **Leading edge of tumor attenuates, pinches off**
 - **Glands resemble microcysts or lymphatics**
 - **Thin, eosinophilic cytoplasm**
 - **Acute inflammation in epithelium and lumen**
 - **Desmoplastic stroma**

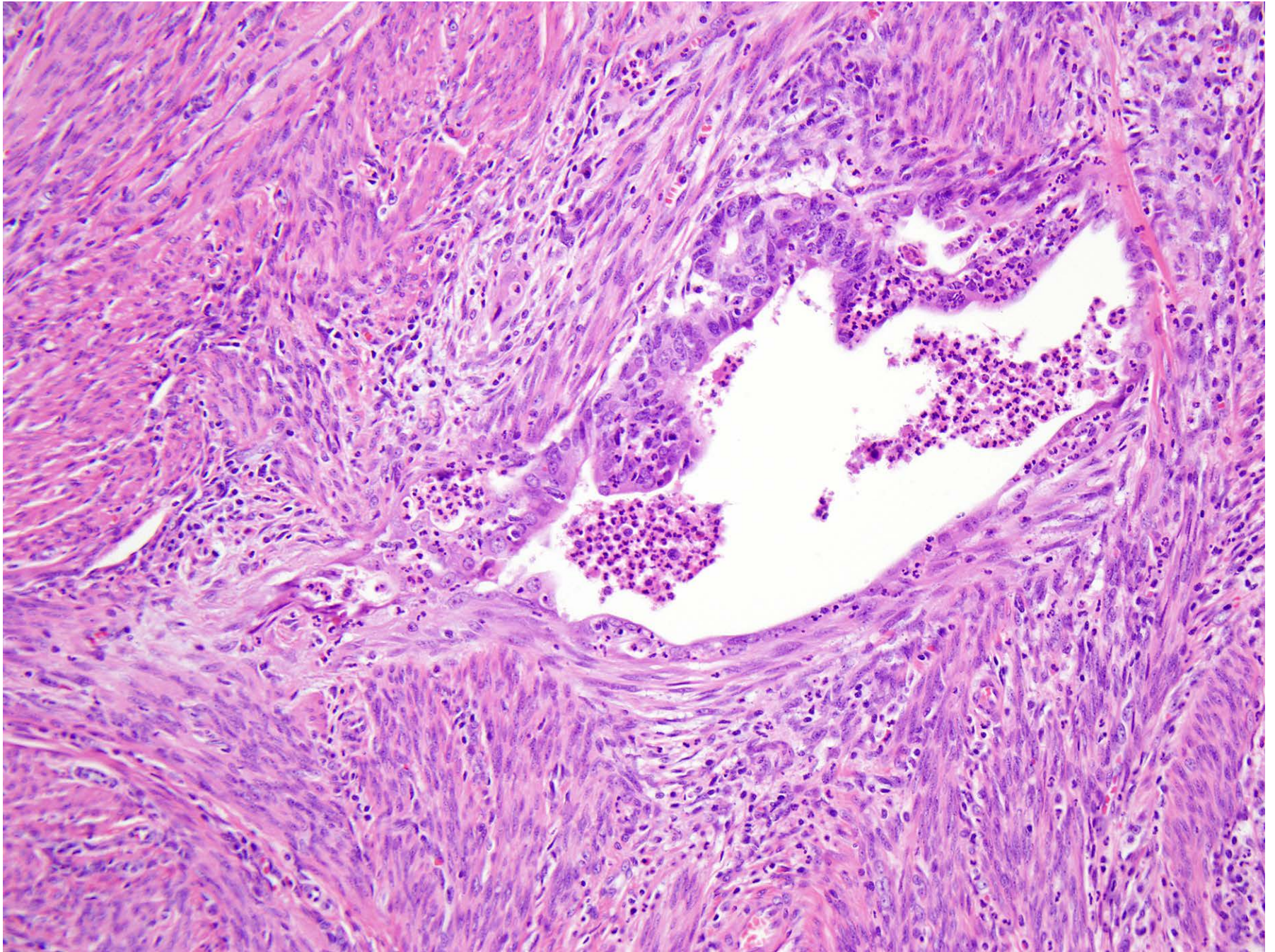
Pitfalls:

- **Under-recognized: foci are small, easy to miss**
 - **May cause under-staging of FIGO IB**
- **Mimics LVI, adenomyosis**
- **Nodal metastases may be difficult to recognize**

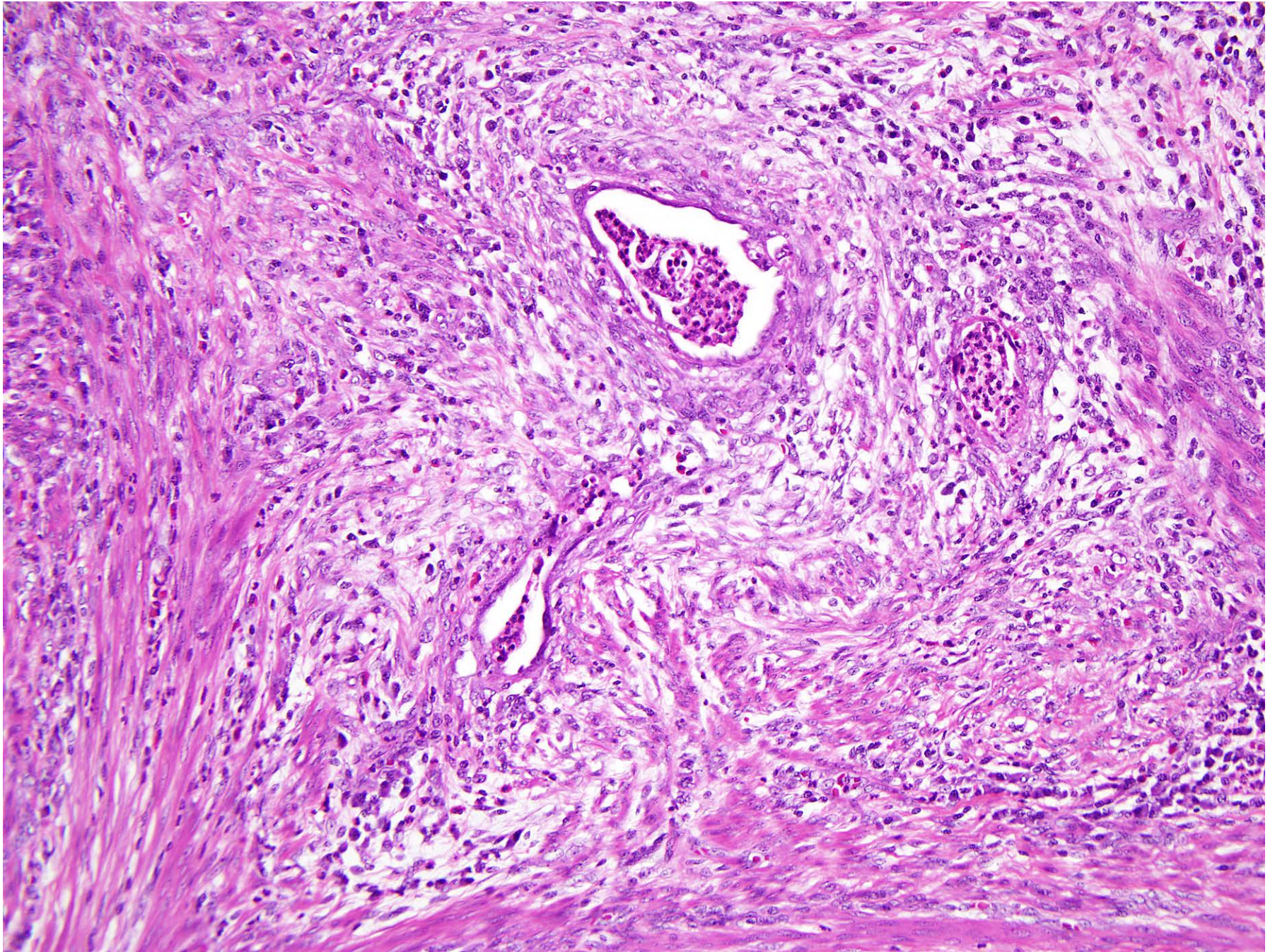
Beginning of MELF pattern of myoinvasion



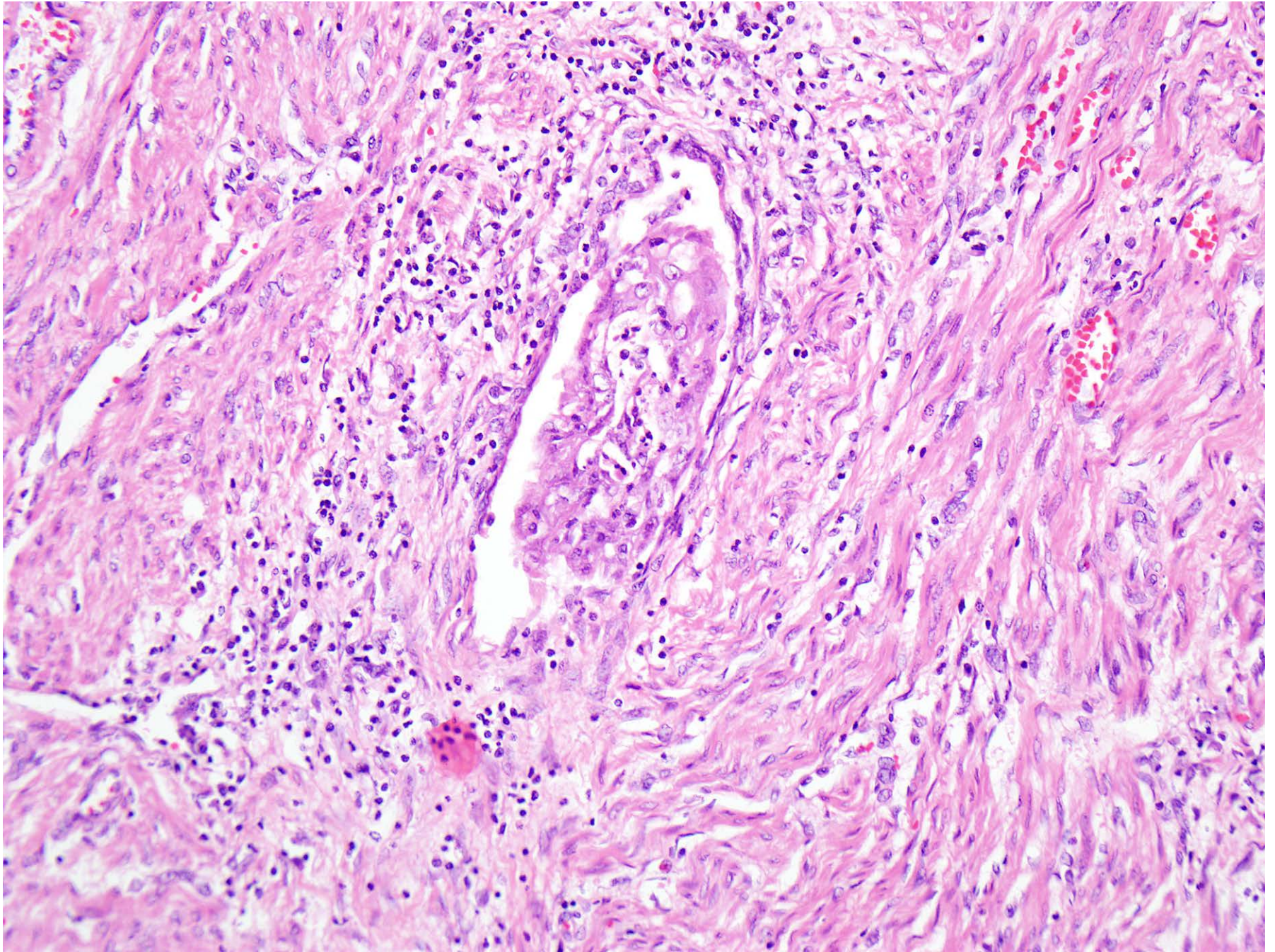
Beginning of MELF pattern of myoinvasion



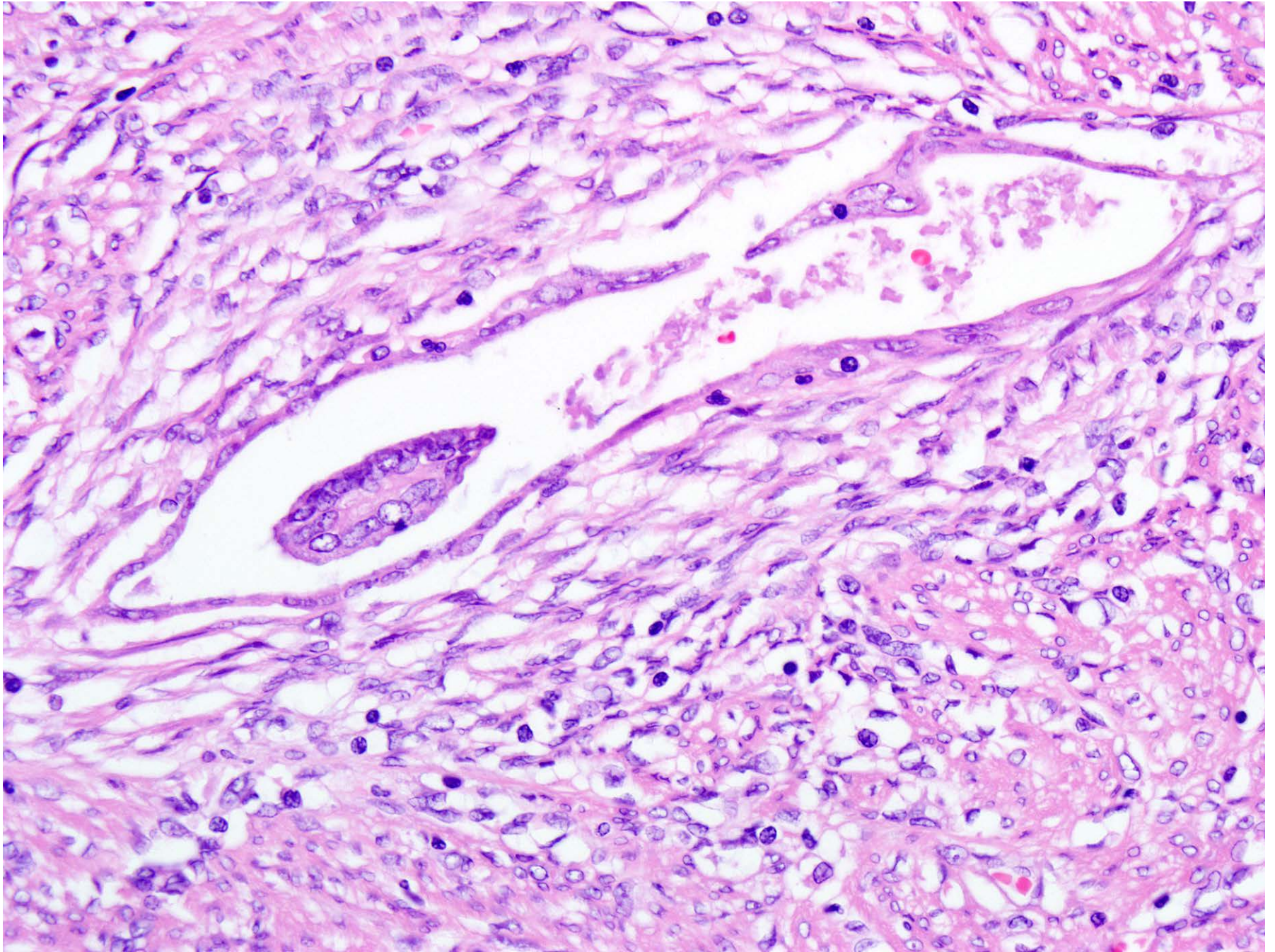
MELF pattern of myoinvasion



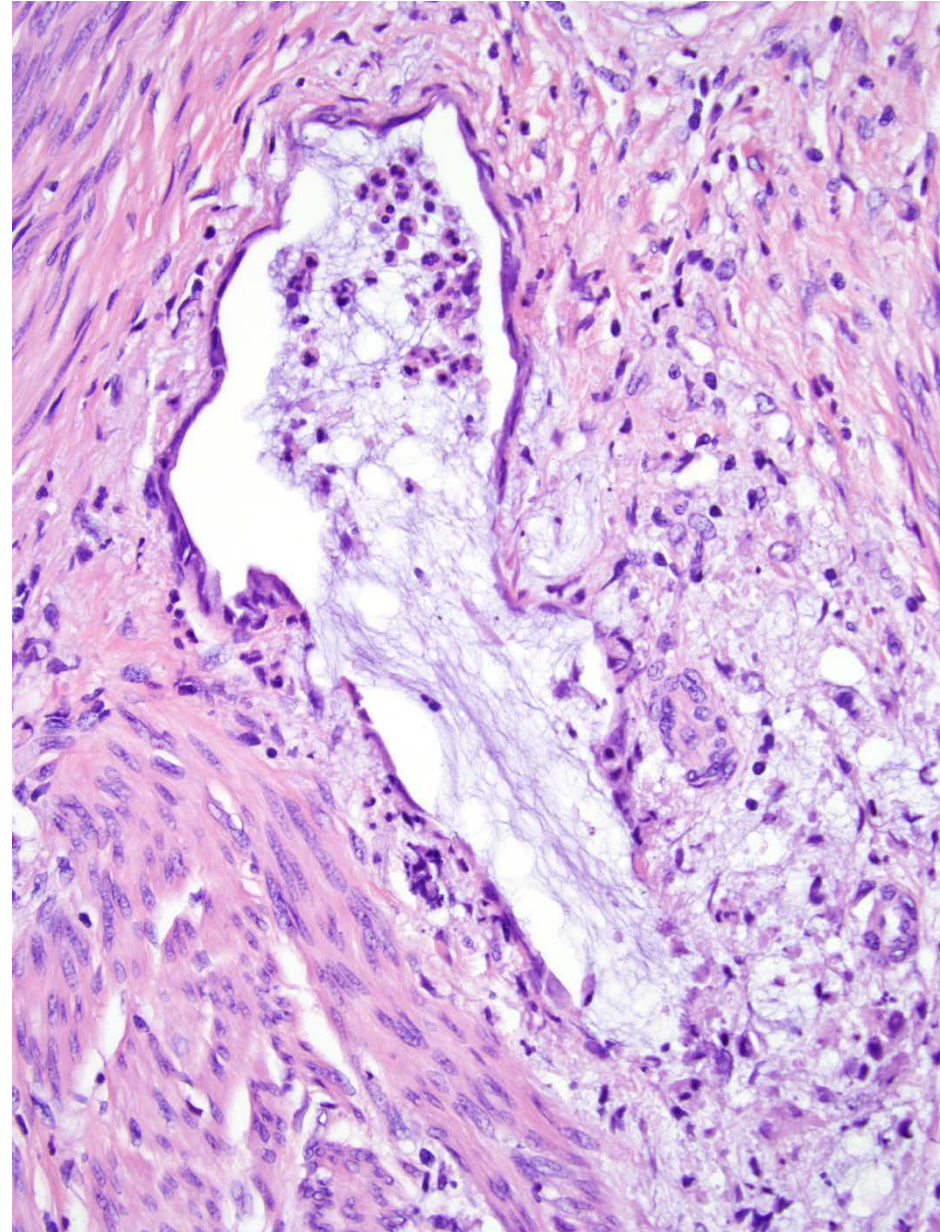
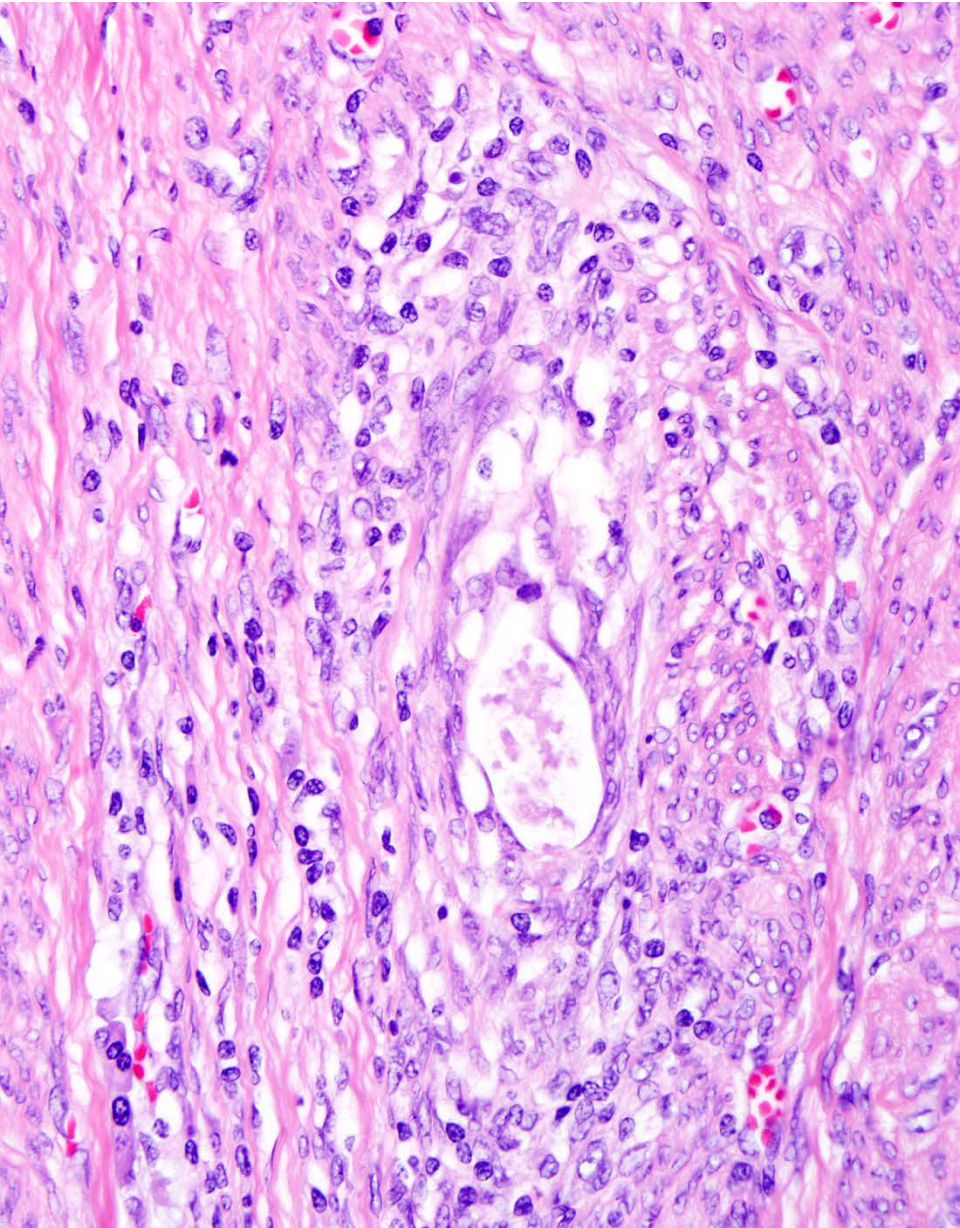
MELF pattern of myoinvasion



MELF pattern of myoinvasion: mimics LVI



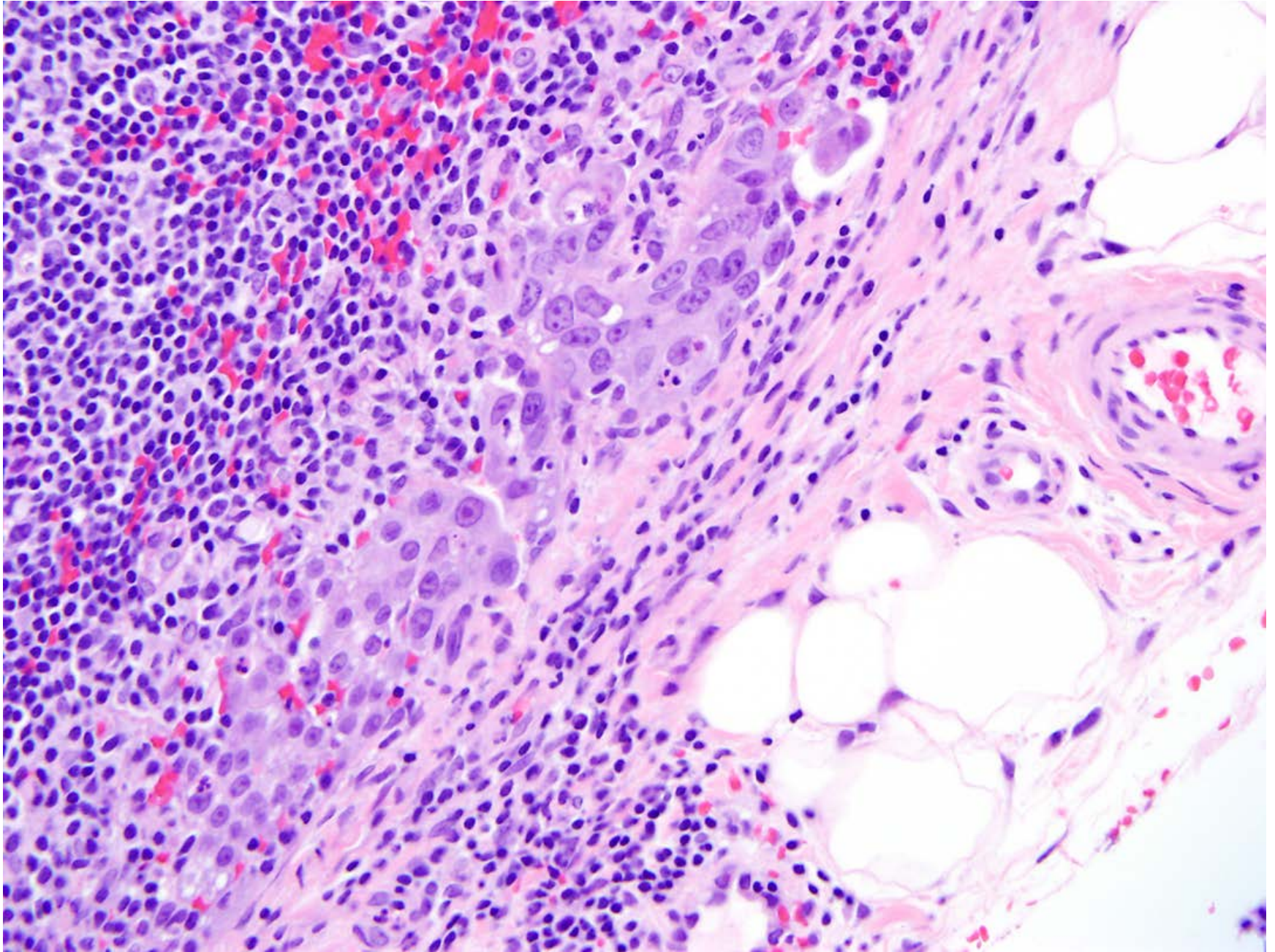
MELF pattern of myoinvasion: May be difficult to find



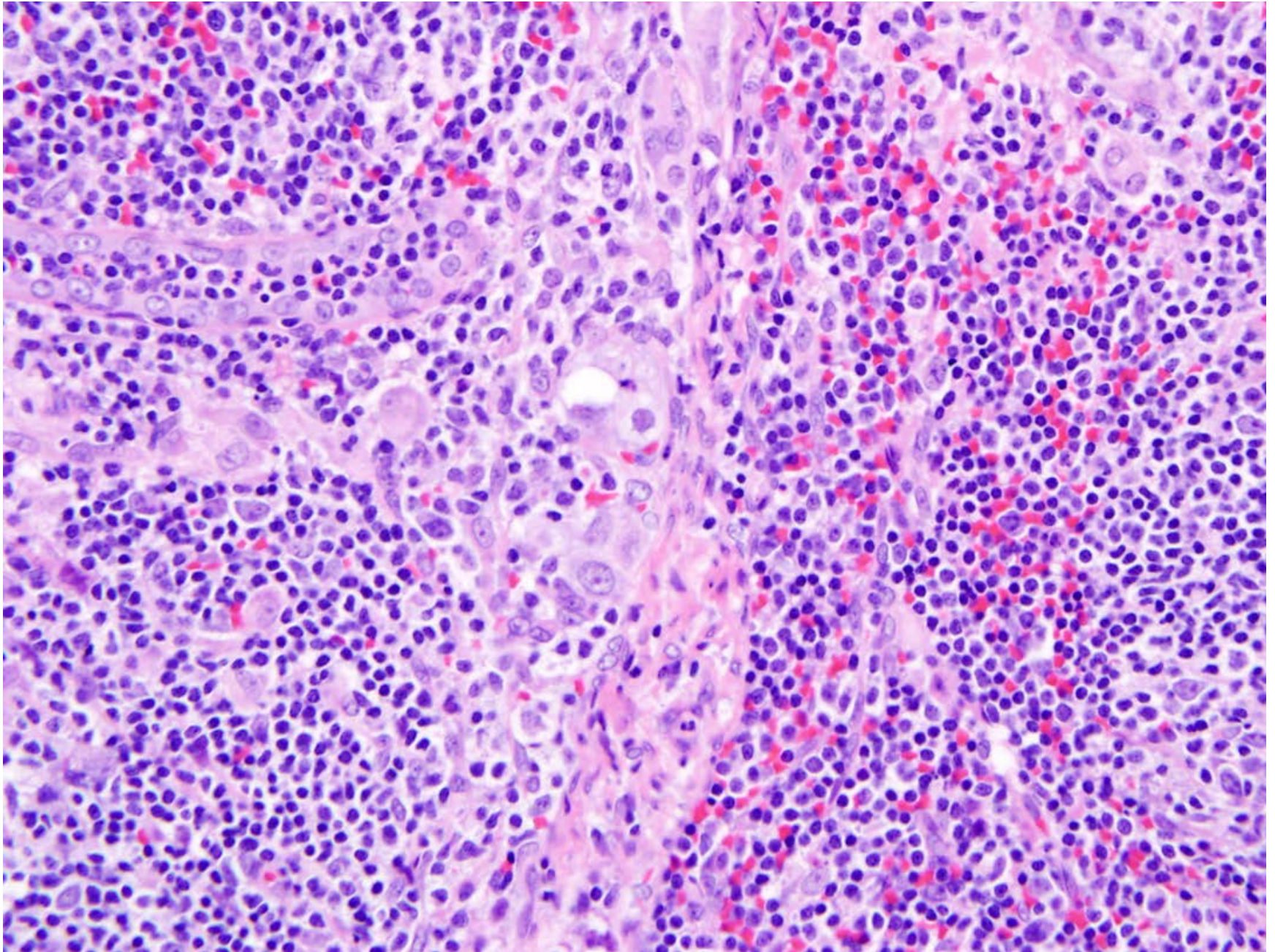
MELF type Myometrial Invasion and Nodal Metastasis

- **Lymph node metastases are often**
 - **Microscopic deposits**
 - **Bland**
 - **Resemble histiocytes**
 - **Easy to miss**

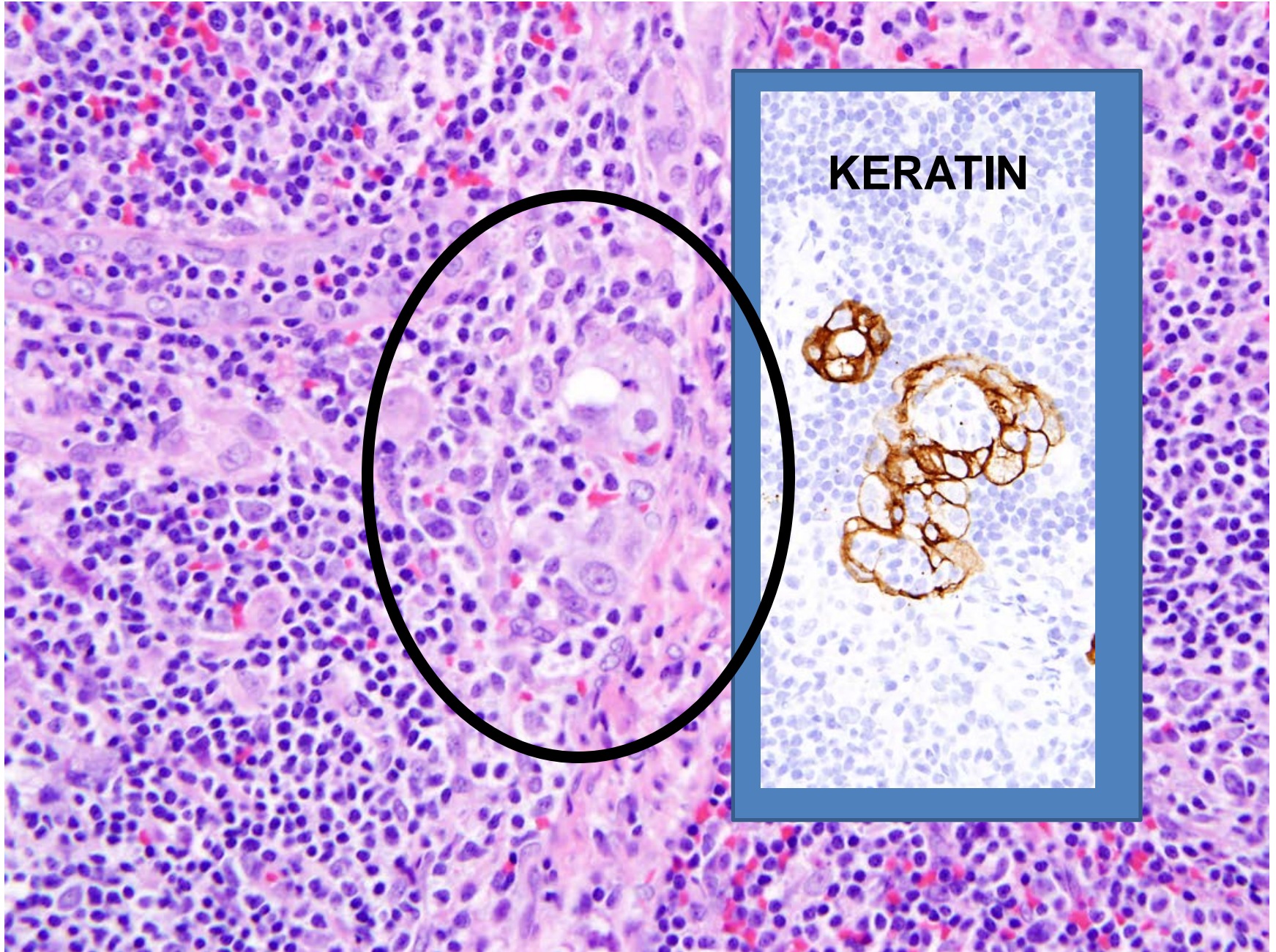
Histiocyte-like features of metastatic endometrial cancer (MELF type)



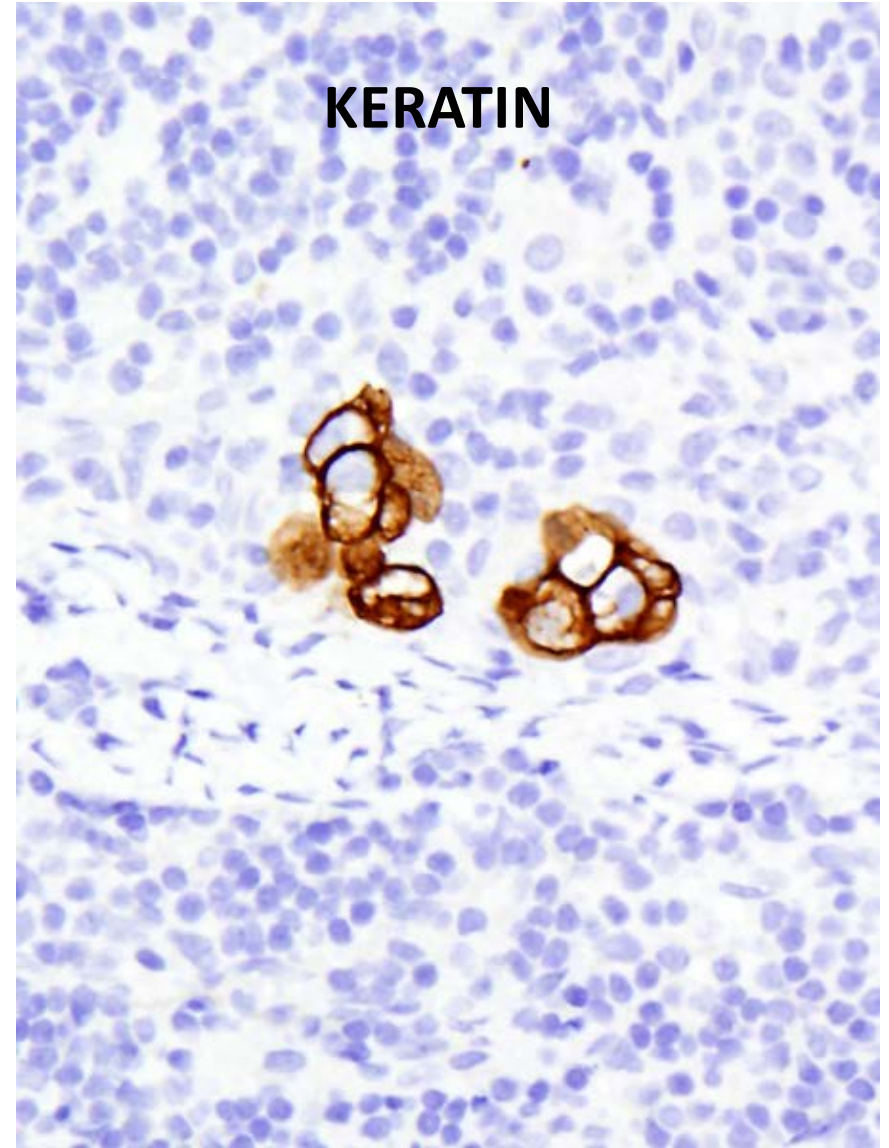
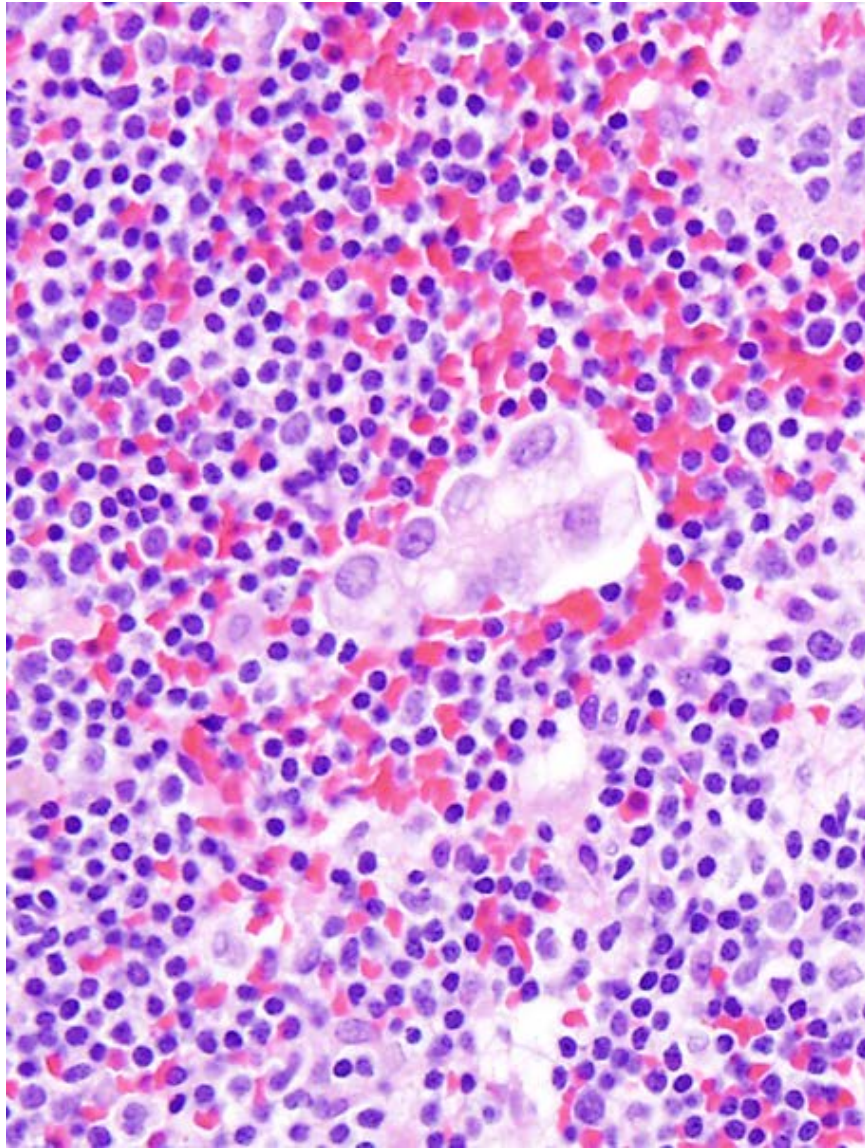
Histiocyte-like features of metastatic endometrial cancer (MELF type)



Histiocyte-like features of metastatic endometrial cancer (MELF type)



Histiocyte-like features of metastatic endometrial cancer (MELF type)



Controversies regarding MELF

- **Risk for nodal metastasis**

- **Conflicting data in literature**

- **Clinical significance of rare tumor cells in a lymph node of uterine cancer**

- **Not studied yet**

- **Assign stage pN1 or pN0 ?**

- **Our current approach: pN1, with a comment.**

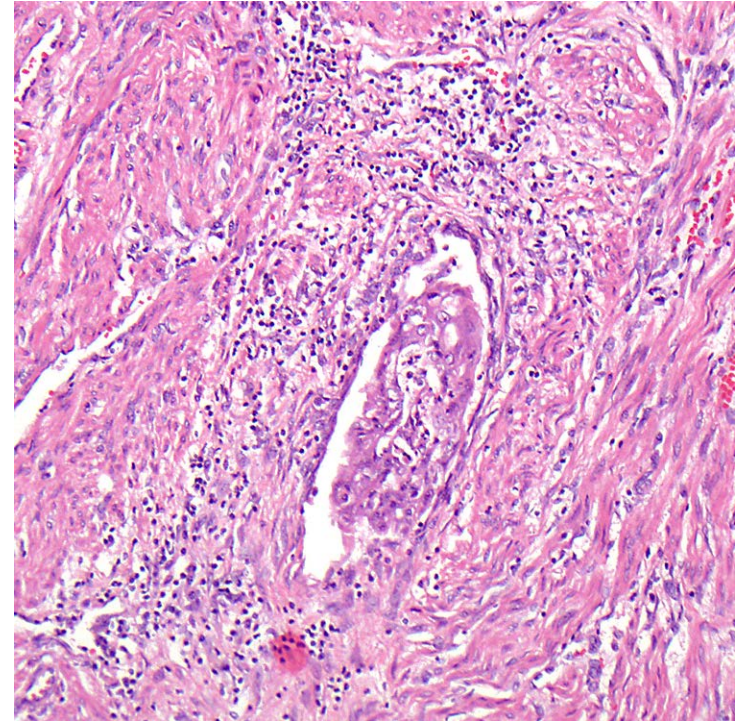
Clues to Recognizing MELF

Scan myometrium for

- **Clusters of lymphocytes**
- **Pale stroma / reactive stroma**


Scan lymph nodes for

- **Histiocyte-like cells**
- **Use keratin if suspicious**



Problematic Patterns of Uterine Cancer

- Glandular
- Papillary
- Spindled
- Clear cell-rich
- Necrosis in “low grade” tumor
- MELF-myoinvasion in low grade tumor



Mucin-rich

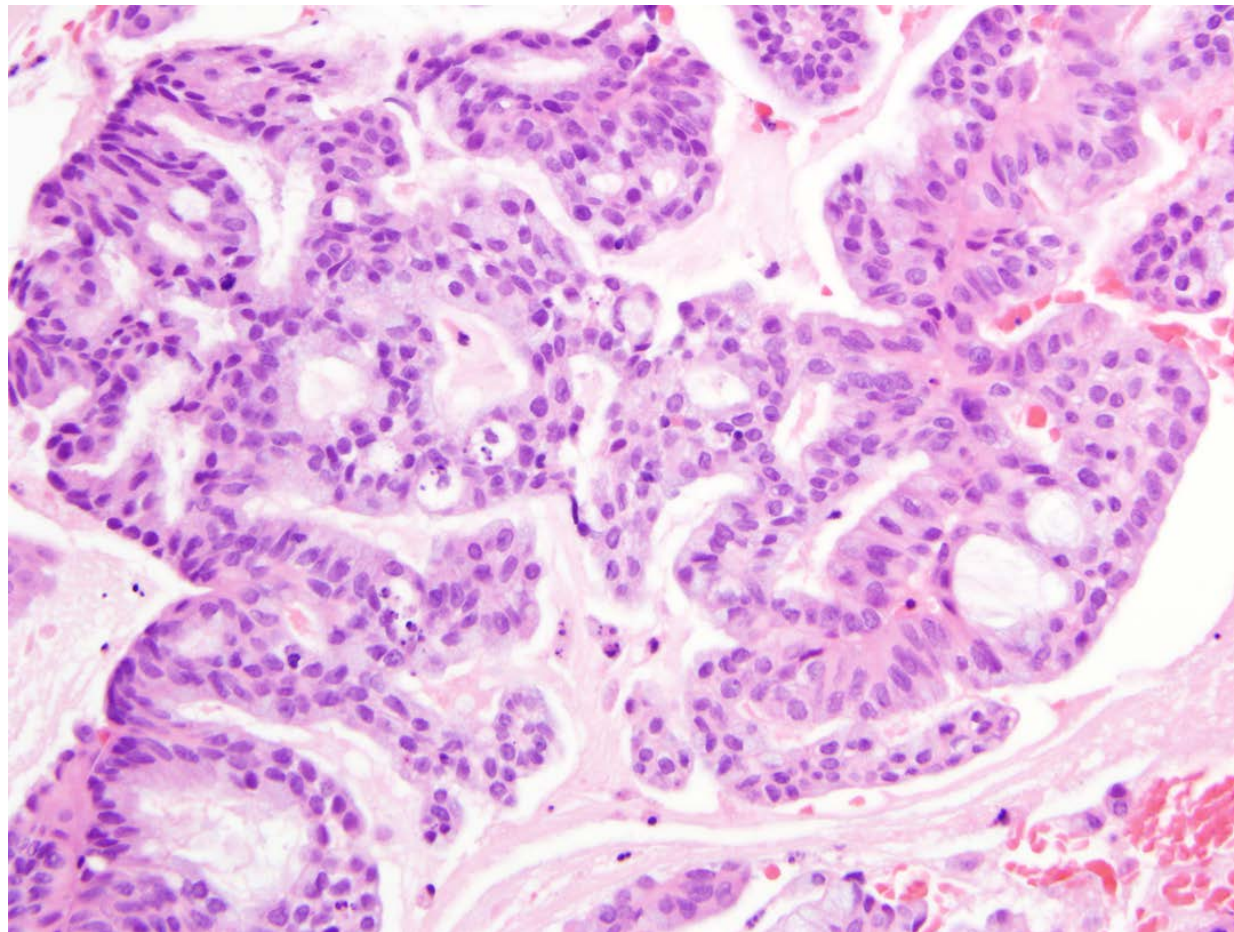
- Solid pattern with high grade atypia

Mucin-Rich Pattern

- **Endometrioid adenocarcinoma with mucin**
- **Endometrioid adenocarcinoma with microglandular hyperplasia like features**
- **Endocervical adenocarcinoma**

Endometrial carcinoma with microglandular hyperplasia-like features

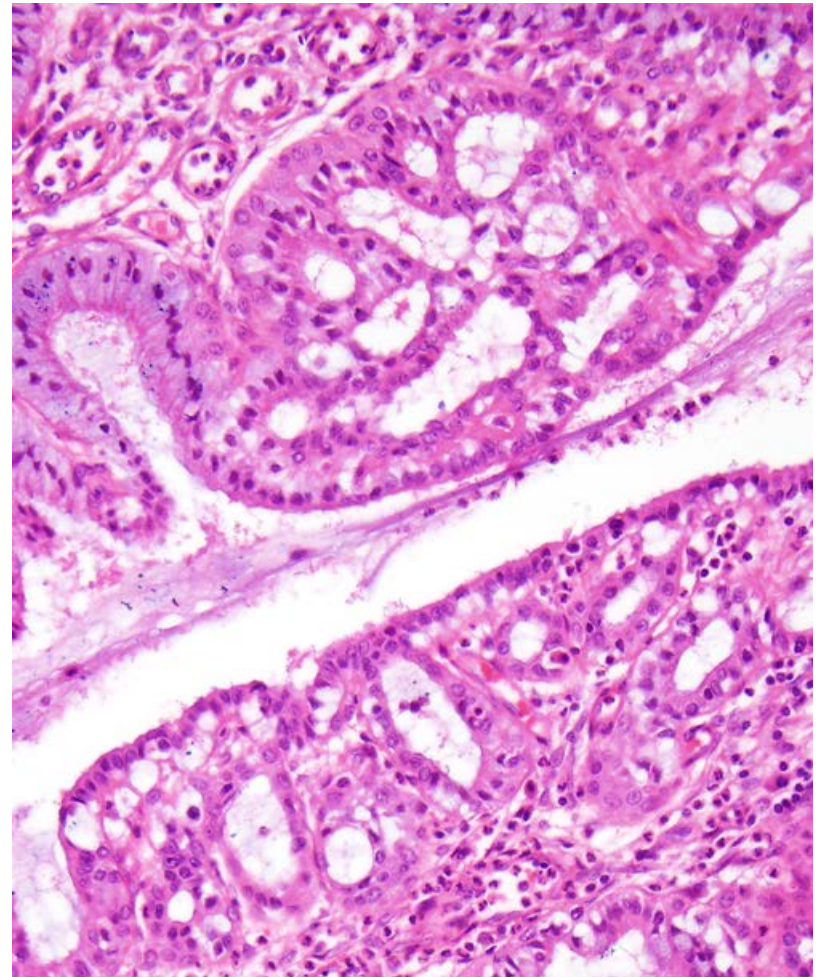
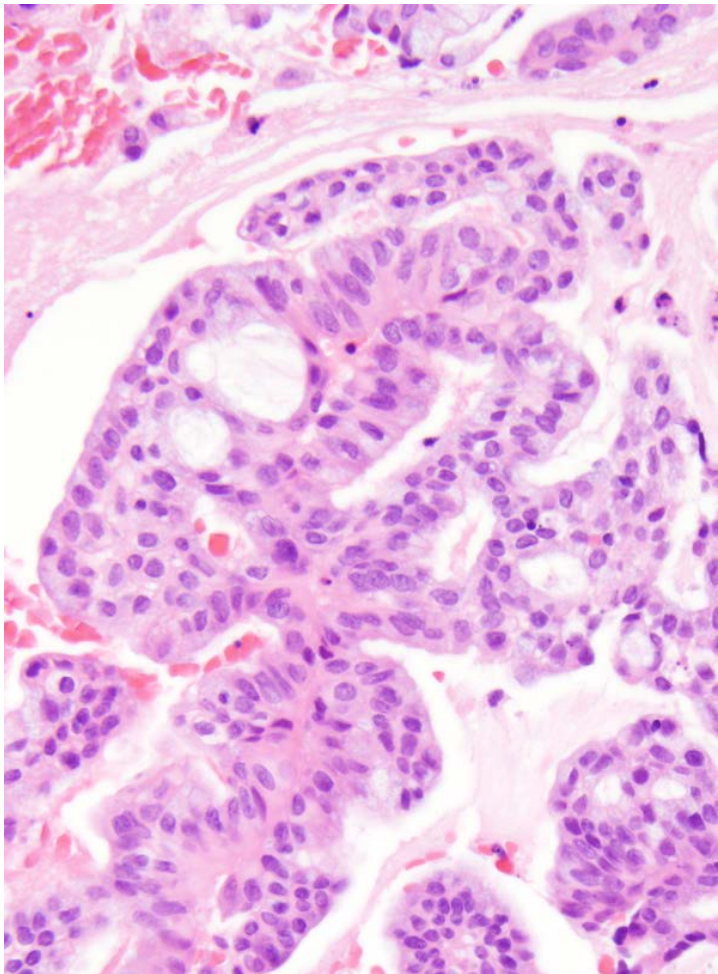
- Endocervical MGH-like changes at surface/periphery of endometrial cancer
- Low grade, low stage endometrioid / mucinous adenocarcinoma
- Older women



Endometrial biopsy: MGH-like features

One is benign MGH

The other is cancer with MGH features



Endometrial biopsy with microglandular hyperplasia-like features

Pre-menopausal age

**Reasonable to consider
Endocervical tissue with
Microglandular hyperplasia**

Post-menopausal age

**Need to consider
Endometrial cancer with
MGH-like features**

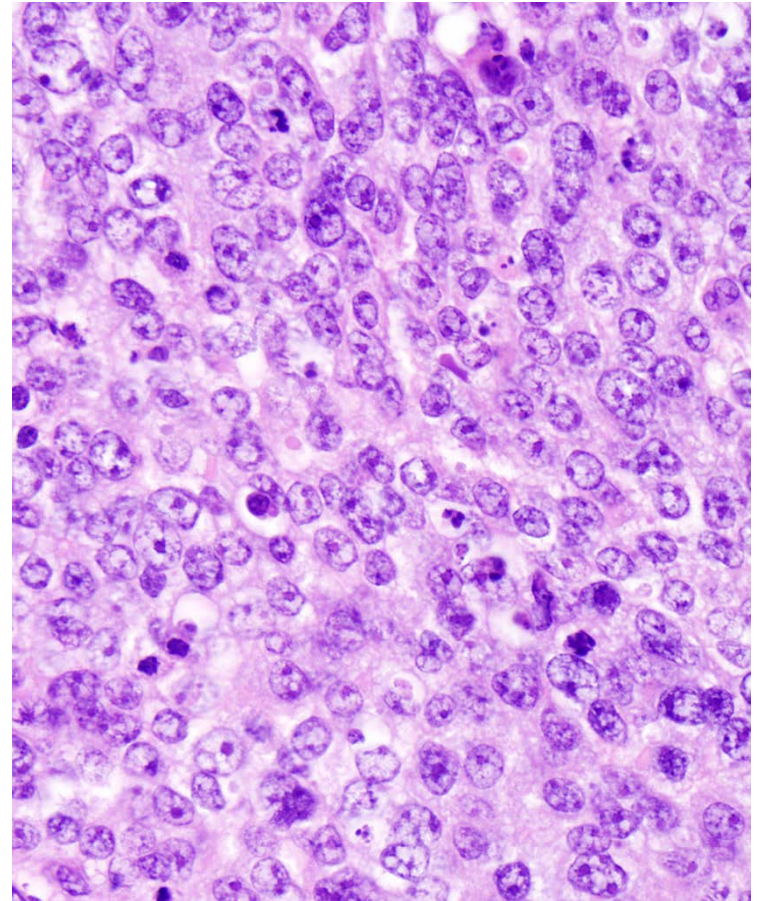
Problematic Patterns of Uterine Cancer

- Glandular
- Papillary
- Spindled
- Clear cell-rich
- Necrosis in “low grade” tumor
- MELF-myoinvasion in low grade tumor
- Mucin-rich

 **Solid pattern with high grade atypia**

Solid Pattern Uterine Cancer with High Grade Atypia

- Serous carcinoma
- Grade 3 endometrioid adenocarcinoma
- Undifferentiated uterine carcinoma
- Neuroendocrine carcinoma
- Undersampled carcinosarcoma
- Consider non-epithelial malignancies:
 - Leiomyosarcoma
 - Rhabdomyosarcoma
 - Lymphoma
 - Melanoma




Poor Interobserver Reproducibility in the Diagnosis of High-grade Endometrial Carcinoma

C. Blake Gilks, MD, FRCPC, Esther Oliva, MD,† and Robert A. Soslow, MD‡*

Am J Surg Pathol • Volume 37, Number 6, June 2013

Solid Pattern Uterine Cancer with High Grade Nuclei

- Serous carcinoma
- Grade 3 endometrioid adenocarcinoma
-  **Undifferentiated uterine carcinoma**
- Neuroendocrine carcinoma
- Undersampled carcinosarcoma
- Consider non-epithelial malignancies:
 - Leiomyosarcoma
 - Rhabdomyosarcoma
 - Lymphoma
 - Melanoma

Undifferentiated Uterine Carcinoma

Definition:

- Tumor without any morphologic or immunostain differentiation
- Two forms:
 - Pure = undifferentiated uterine carcinoma (UUC)
 - Mixed UUC with low grade endometrioid carcinoma = Dedifferentiated (DDUC)

Significance:

- Highly aggressive / fatal
 - UUC worse than grade 3 endometrioid
 - DDUC worse than grade 2 endometrioid
- Possible sign of Lynch syndrome

Undifferentiated Uterine Carcinoma

Architecture:

- Sheets, rarely cords. *No glands/tubules/squamous features.*
- Non-cohesive cells
- Geographic necrosis
- Myxoid stroma (sometimes)

Cytology:

- Monotonous polygonal cells
- Moderate atypia
- Nucleoli, mitoses
- Rhabdoid cells (sometimes)

Undifferentiated Uterine Carcinoma

Architecture:

- Sheets, rarely cords. No glands/tubules.
- Non-cohesive cells
- Necrosis
- Myxoid stroma

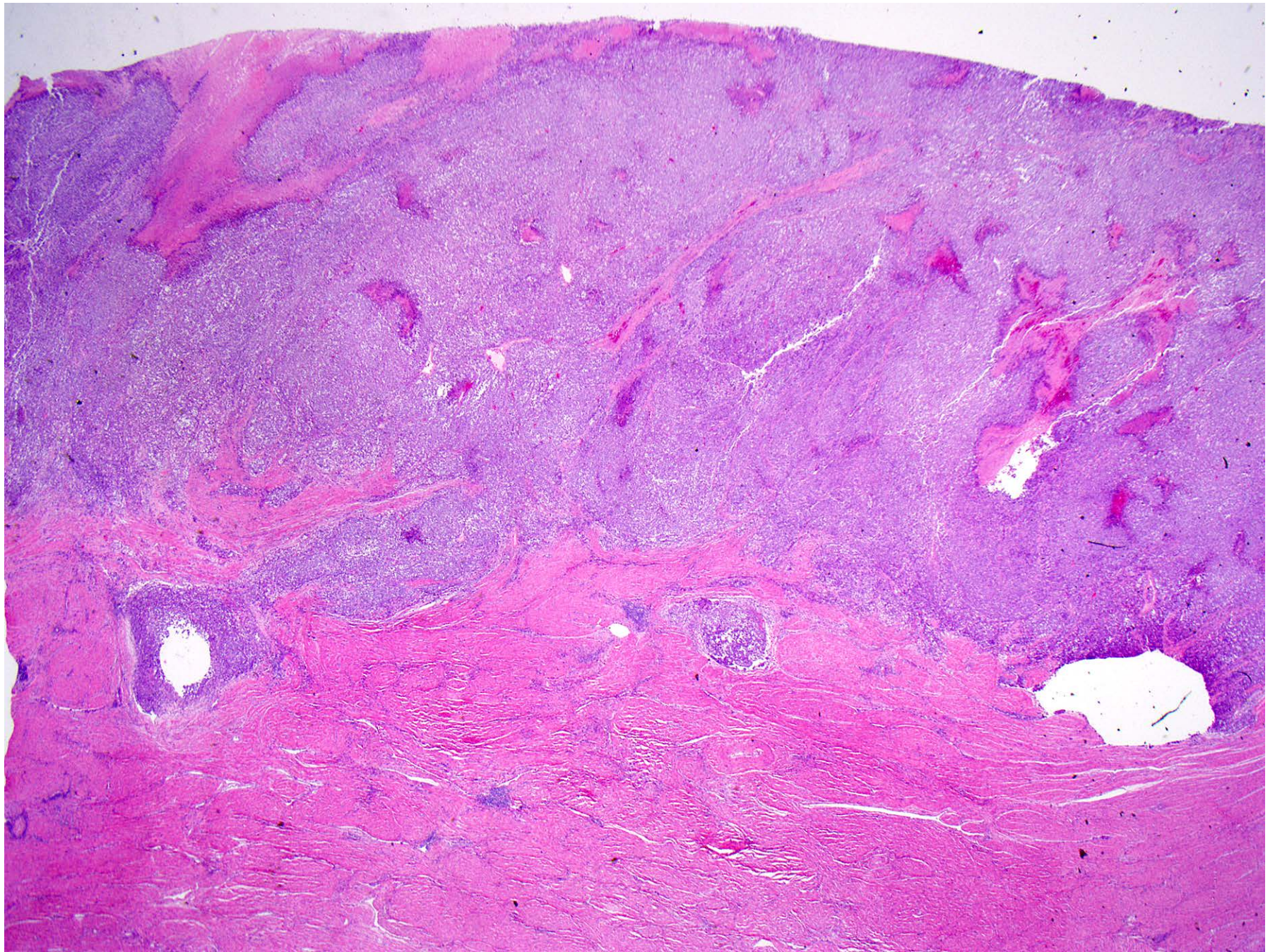
Cytology:

- Monotonous polygonal cells
- Moderate atypia
- Nucleoli, mitoses
- Rhabdoid

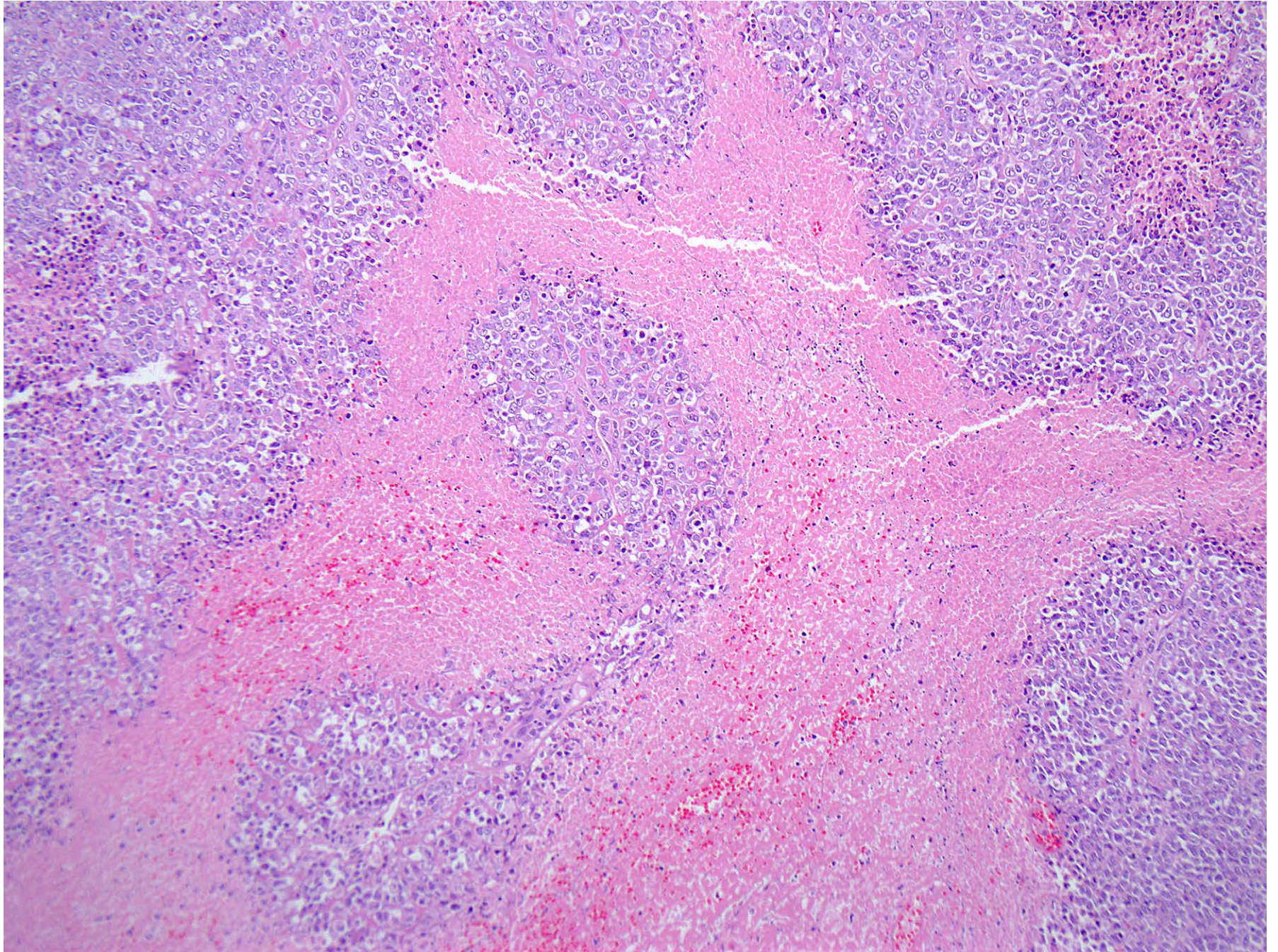
Immunostains:

- Keratin, EMA.....negative or focal (<10%)
- Neuroendocrine.....negative or focal (<10%)
- p16..... Positive
- ER/PR.....conflicting data

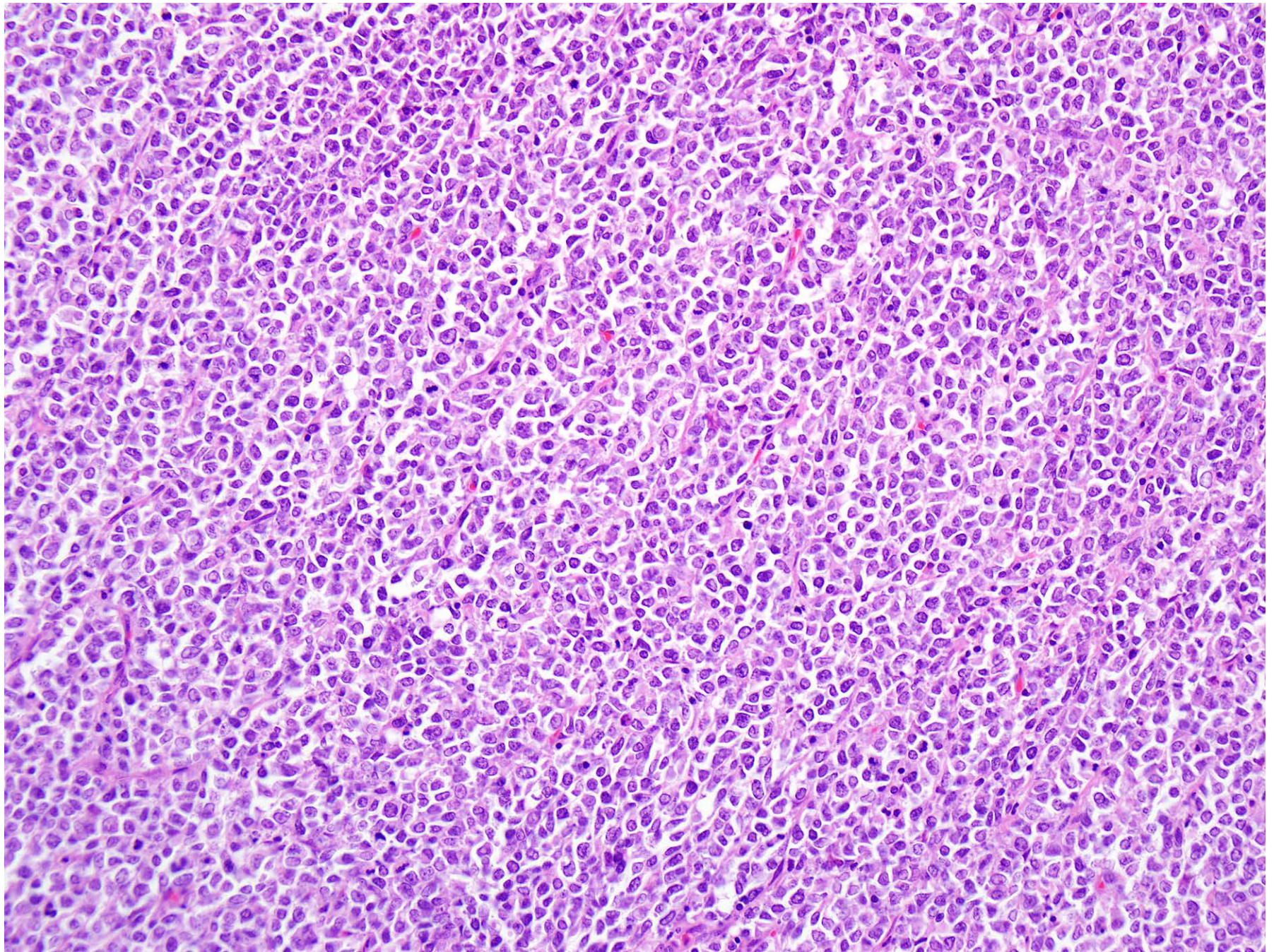
Undifferentiated Uterine Carcinoma



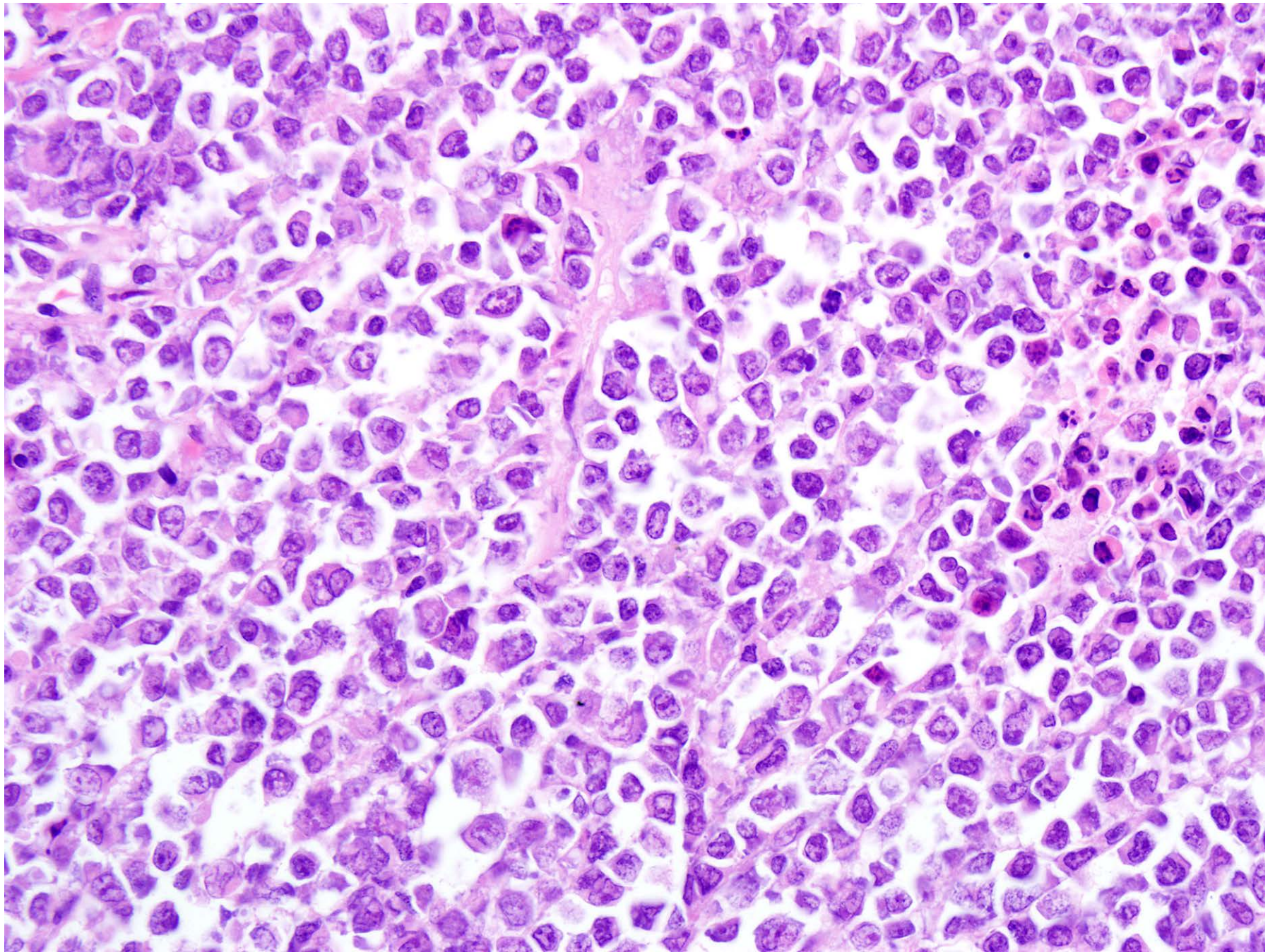
Undifferentiated Uterine Carcinoma



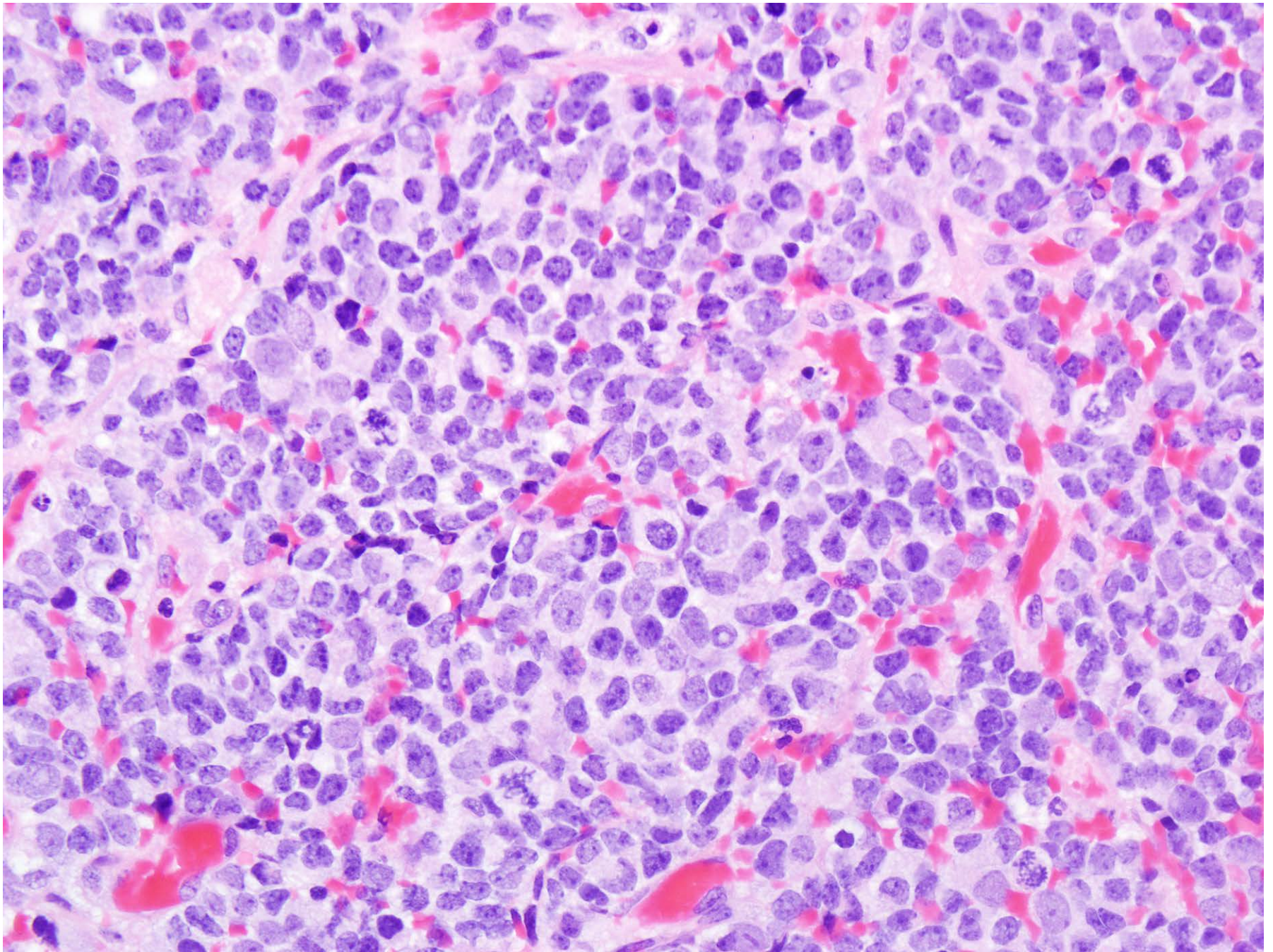
Undifferentiated Uterine Carcinoma



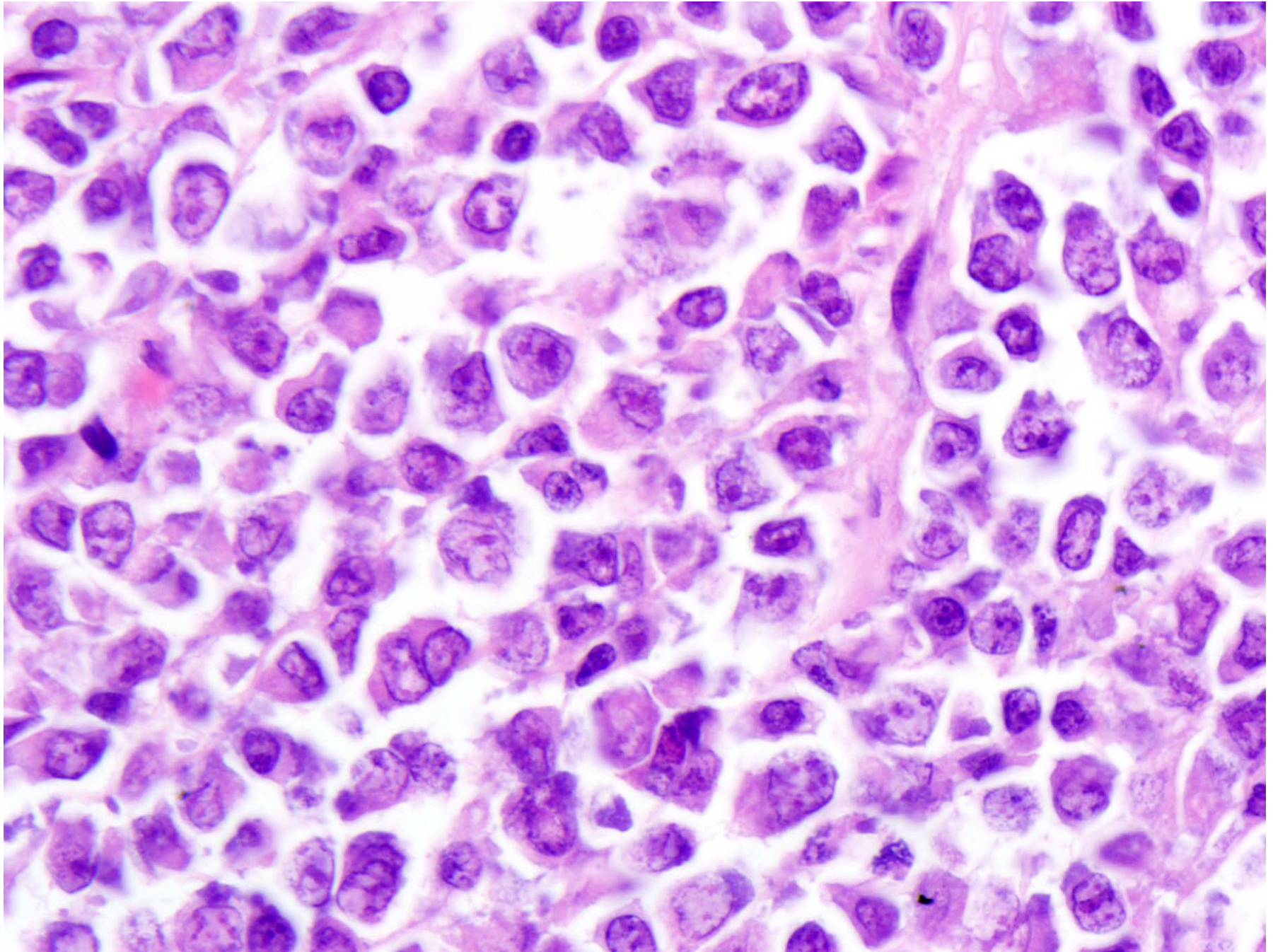
Undifferentiated Uterine Carcinoma: Non-cohesive tumor cells



Undifferentiated Uterine Carcinoma : Moderate atypia

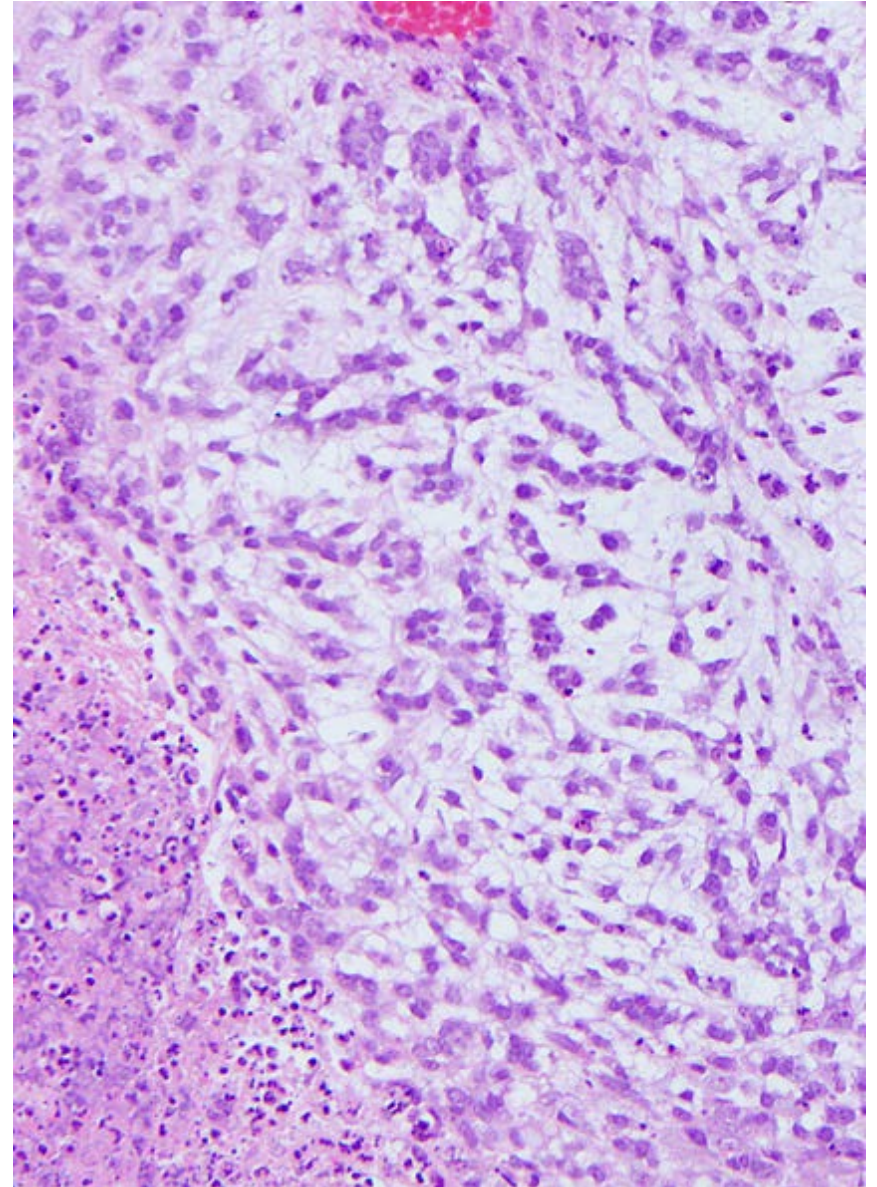
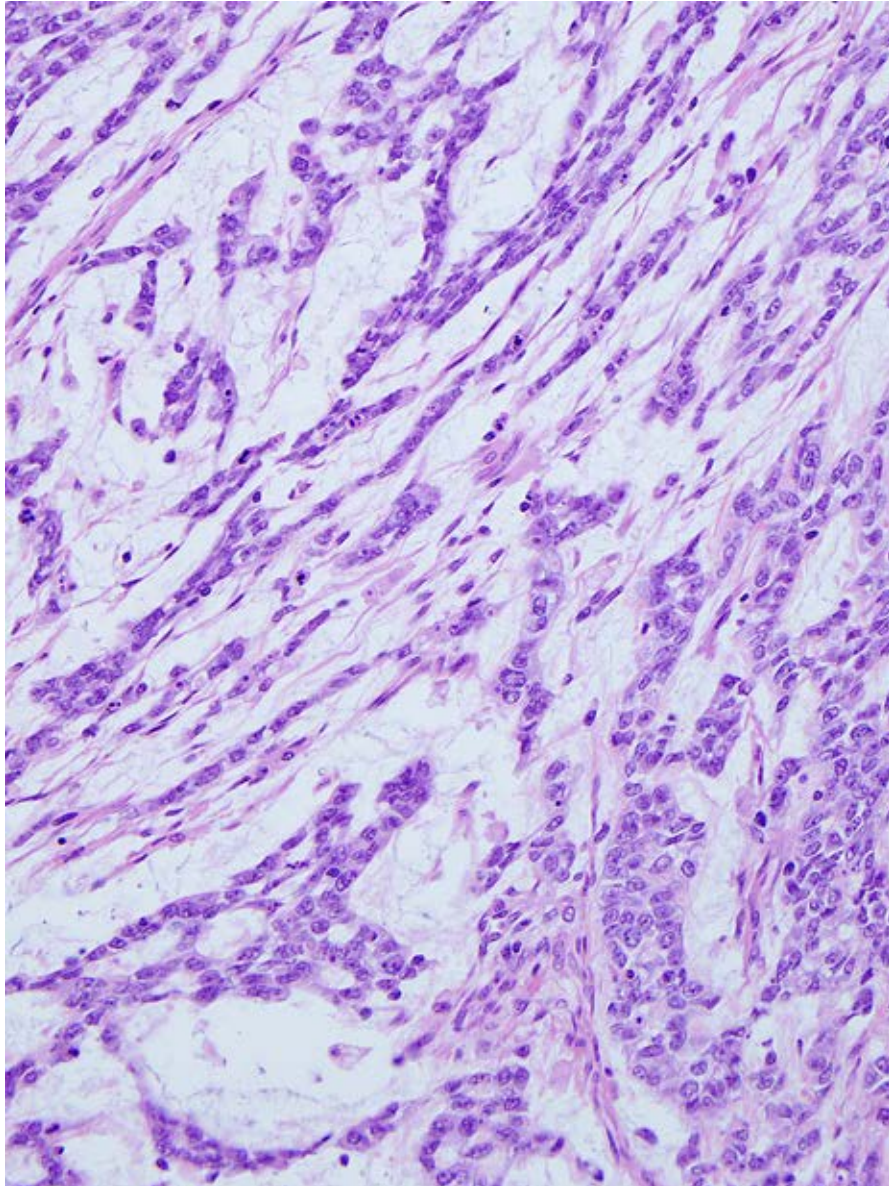


Undifferentiated Uterine Carcinoma: Rhabdoid cells

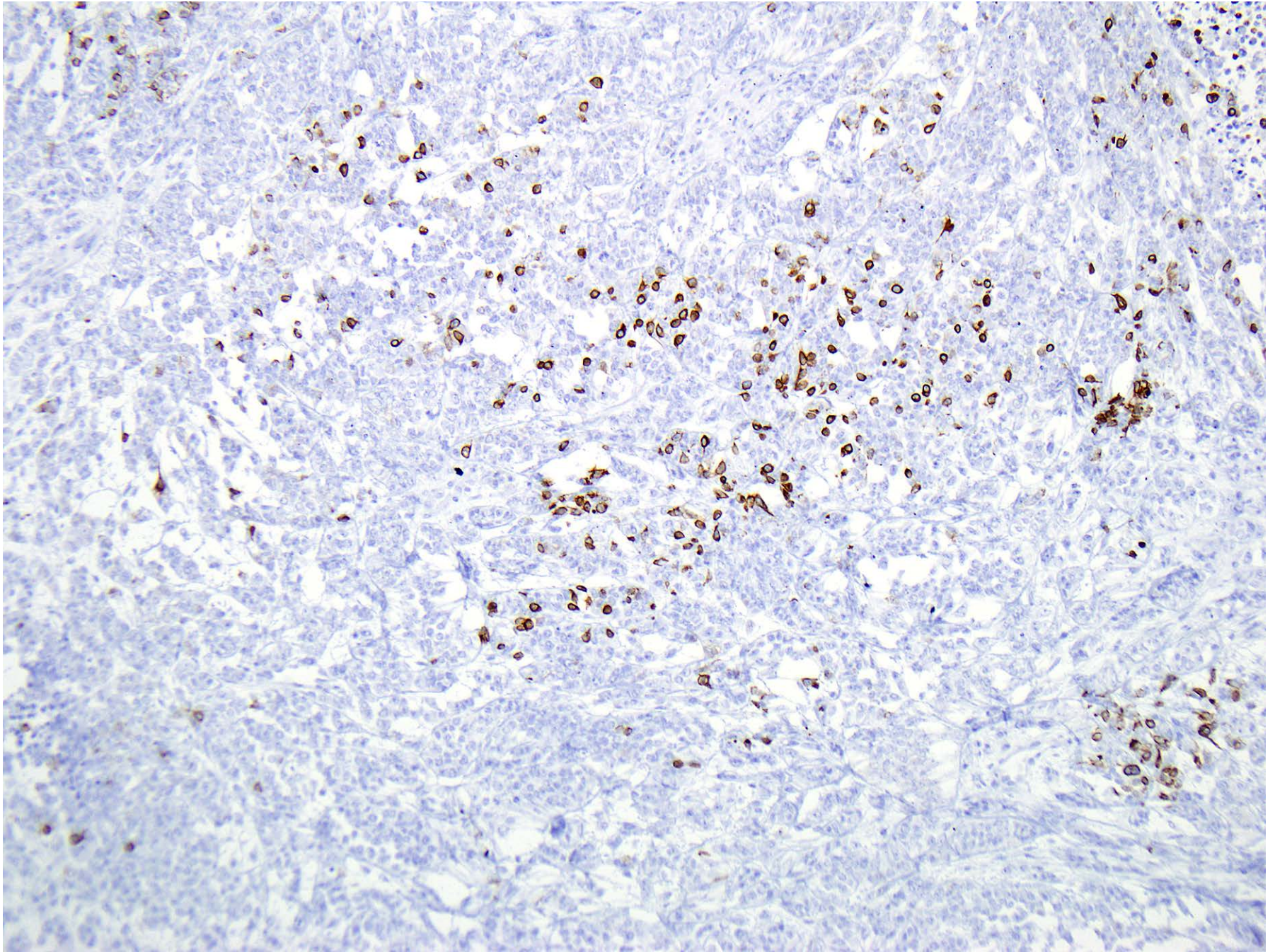


Undifferentiated Uterine Carcinoma

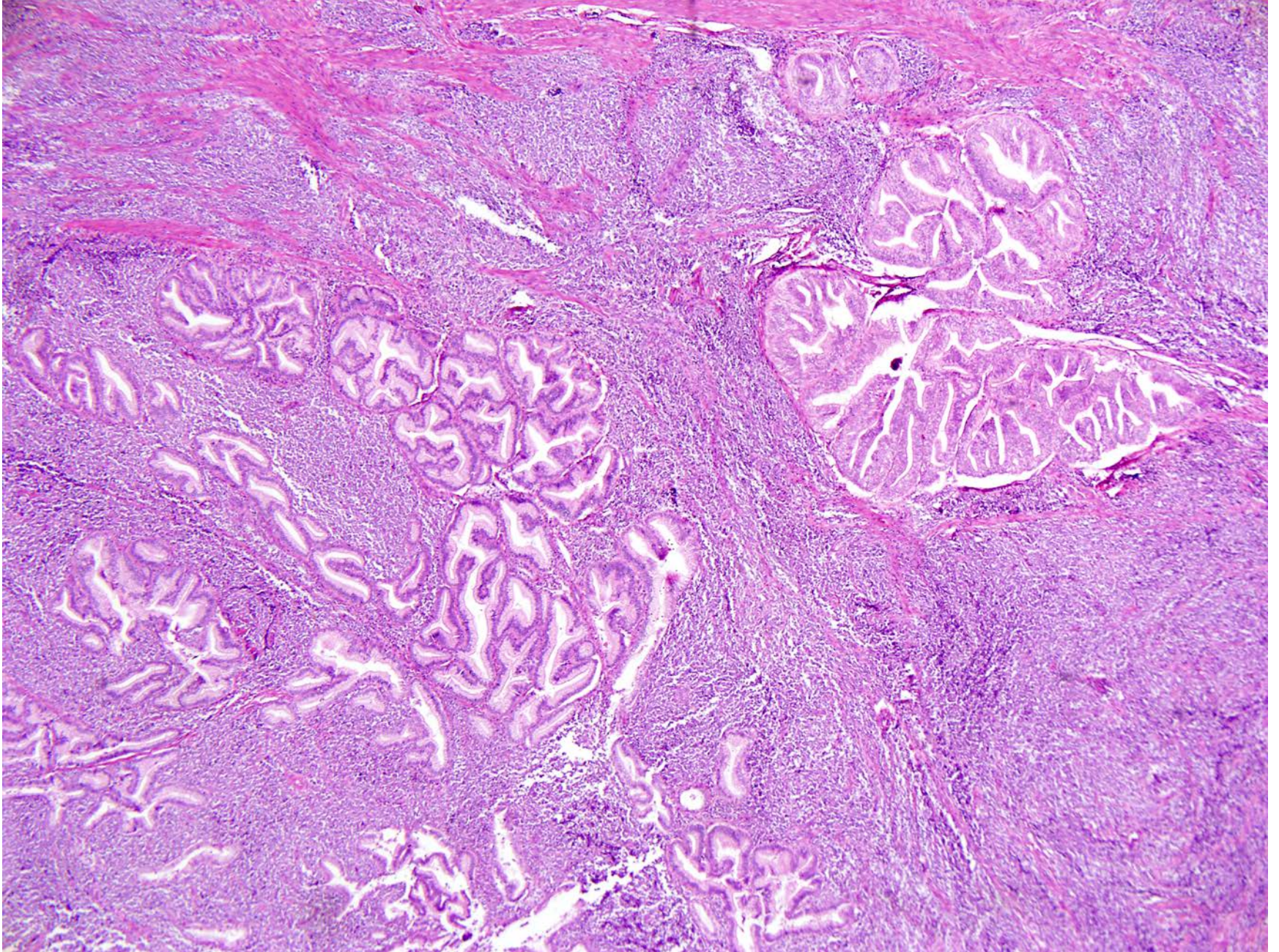
Myxoid Stroma



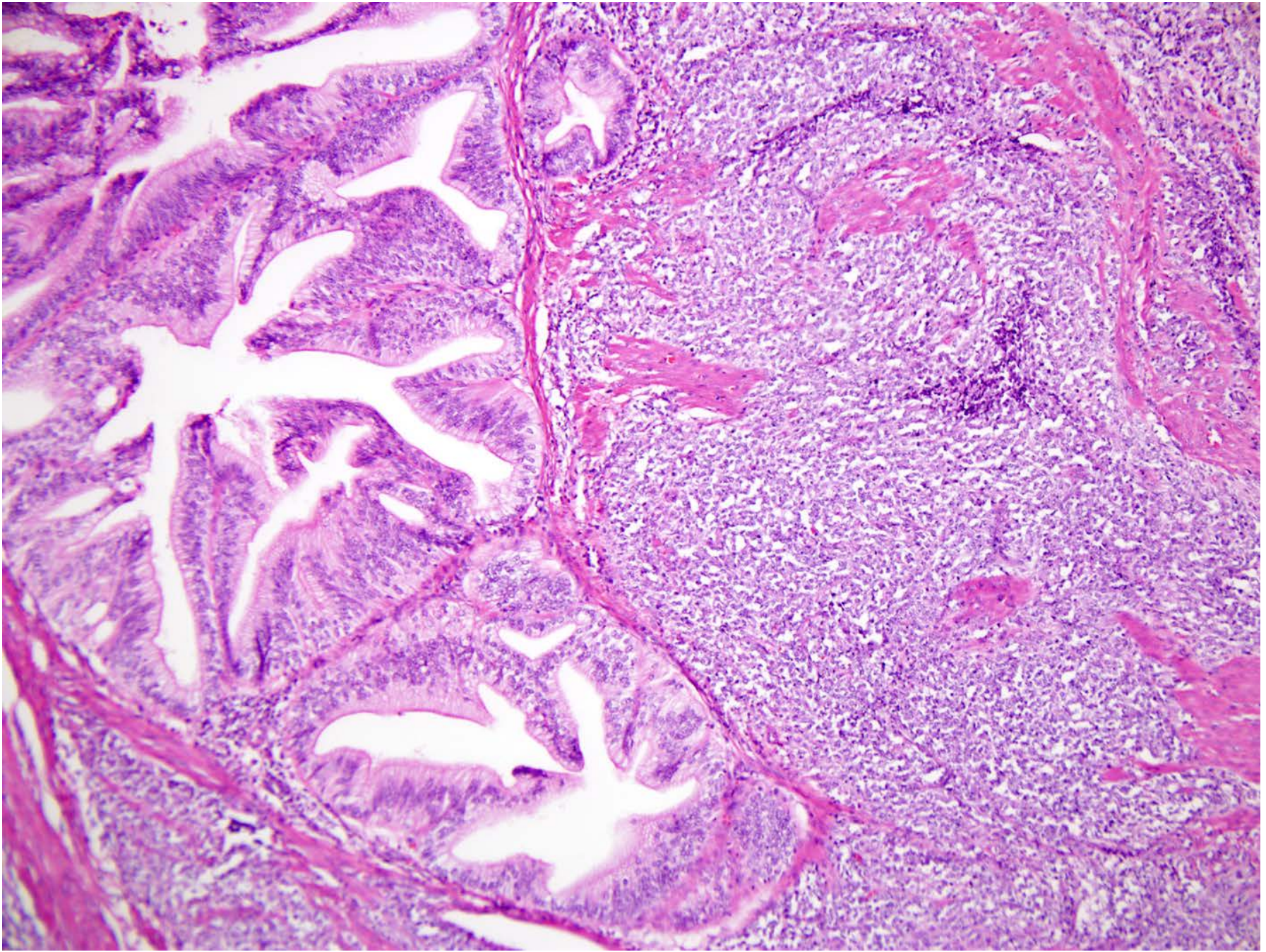
Keratin: Undifferentiated Uterine Carcinoma



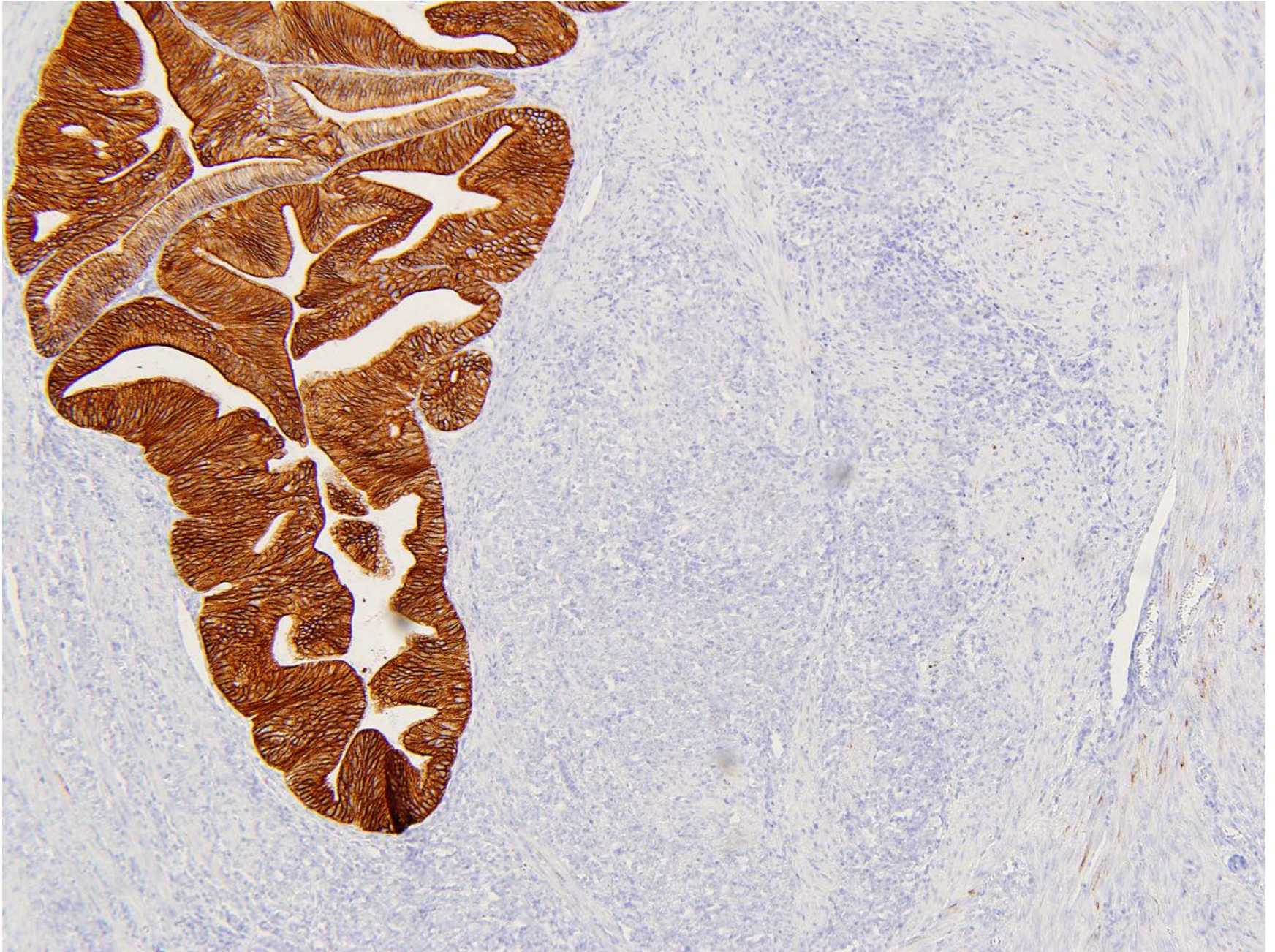
Dedifferentiated Uterine Carcinoma



Dedifferentiated Uterine Carcinoma



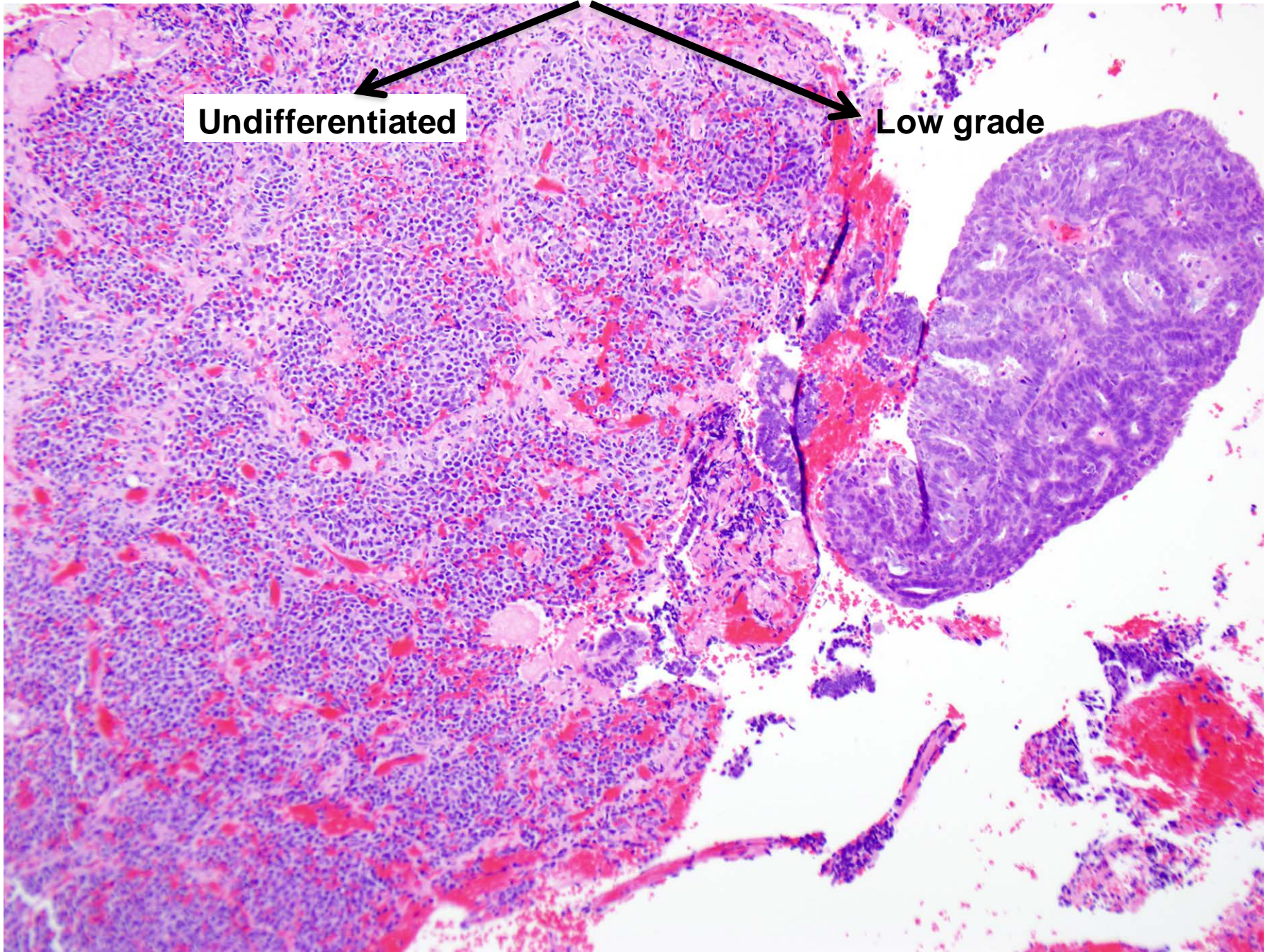
Dedifferentiated Uterine Carcinoma
Keratin



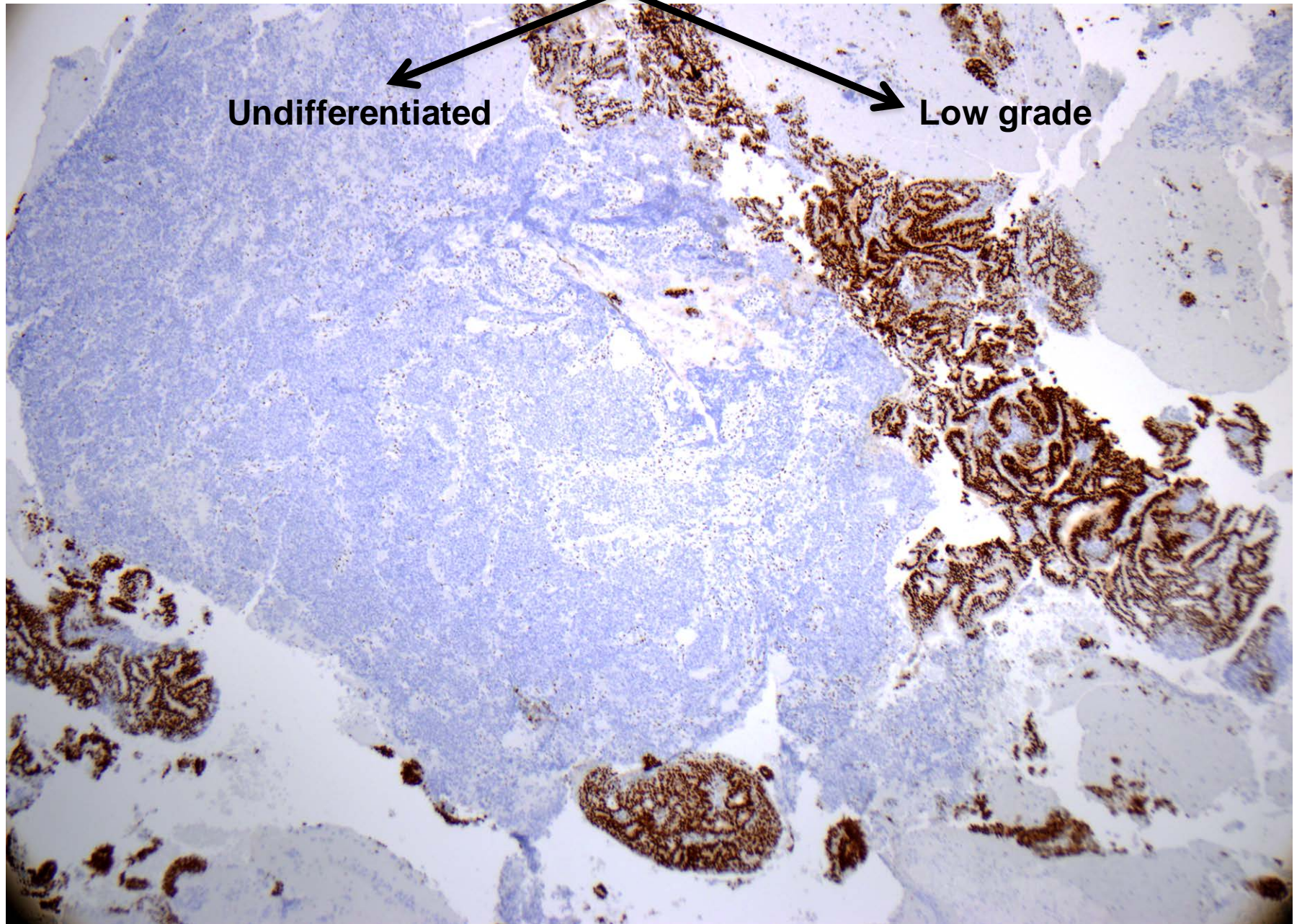
Dedifferentiated Uterine Carcinoma

Undifferentiated

Low grade



Keratin: Dedifferentiated Uterine Carcinoma



Undifferentiated

Low grade

Undifferentiated Uterine Carcinoma

Behavior:

- 40% to 60% die
- Median survival is 6 months
- Most deaths are within 5 years

- For dedifferentiated uterine carcinoma, prognosis is the same even if only 20% is undifferentiated carcinoma

--Don't underestimate as "grade 2" endometrioid cancer

Treatment:

- Same as for high grade cancer

- Often MSI-high so testing for Lynch syndrome is advised

Undifferentiated Uterine Carcinoma vs Endometrioid Carcinoma

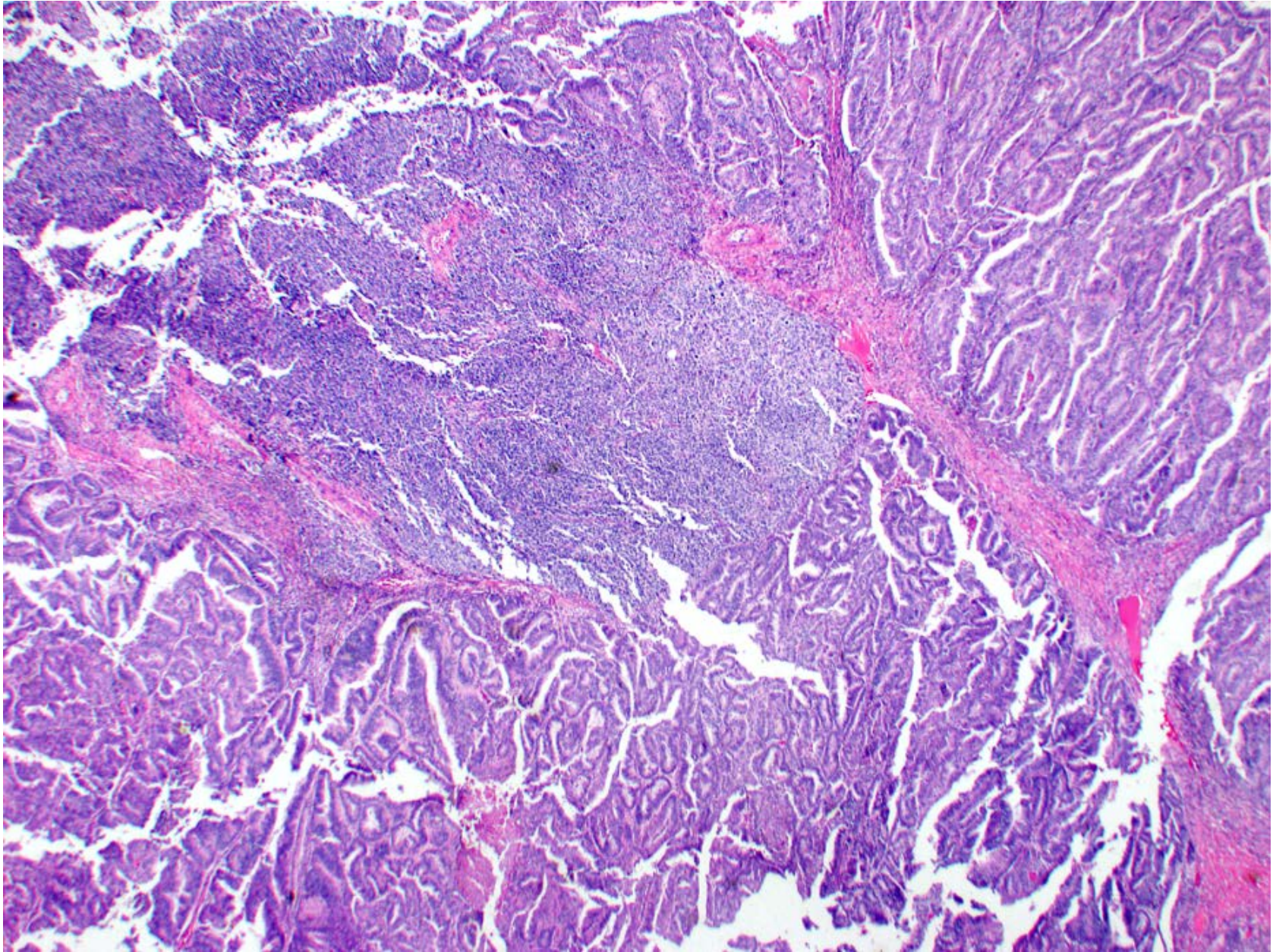
	UUC	Grade 3 Endometrioid
Tubules, glands	No	Usually focally
Squamous differentiation	No	Focally
Geographic necrosis	Common	Rare
Non-cohesive cells	Yes	No
Rhabdoid cells	Yes	No
Keratin/EMA	<10% cells	Diffuse

Undifferentiated Uterine Carcinoma vs Serous Carcinoma

	UUC	Serous Carcinoma
Papillary growth	No	Usually focally
Slit like spaces	No	Focally
Nuclei	Monotonous	Pleomorphic
Geographic necrosis	Common	Rare
Non-cohesive cells	Yes	No
Rhabdoid cells	Yes	No
Keratin/EMA	<10% cells	Diffuse

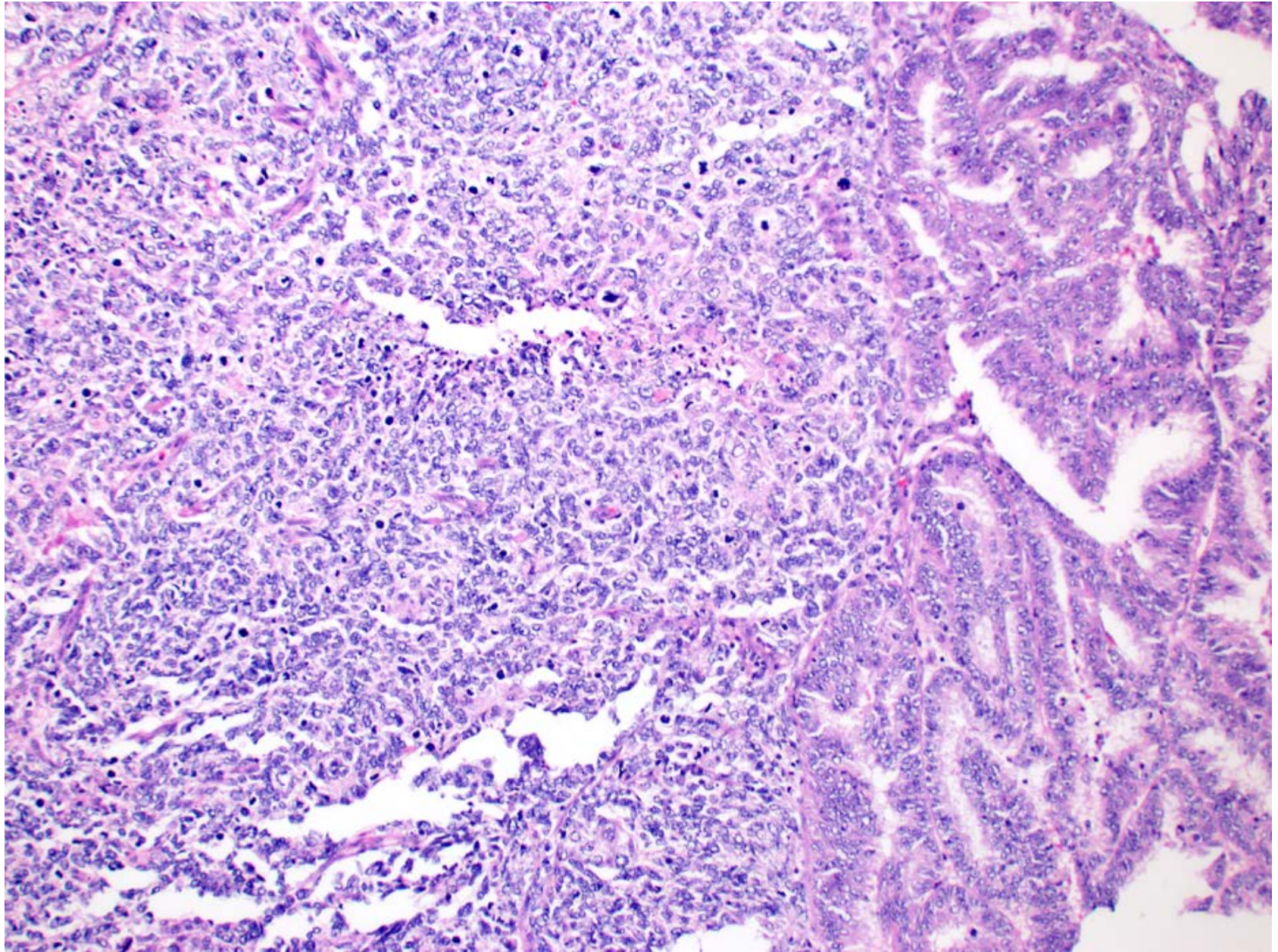
Neuroendocrine Carcinoma with Low Grade Endometrioid Carcinoma

Potential Confusion as Solid Pattern Endometrioid Cancer



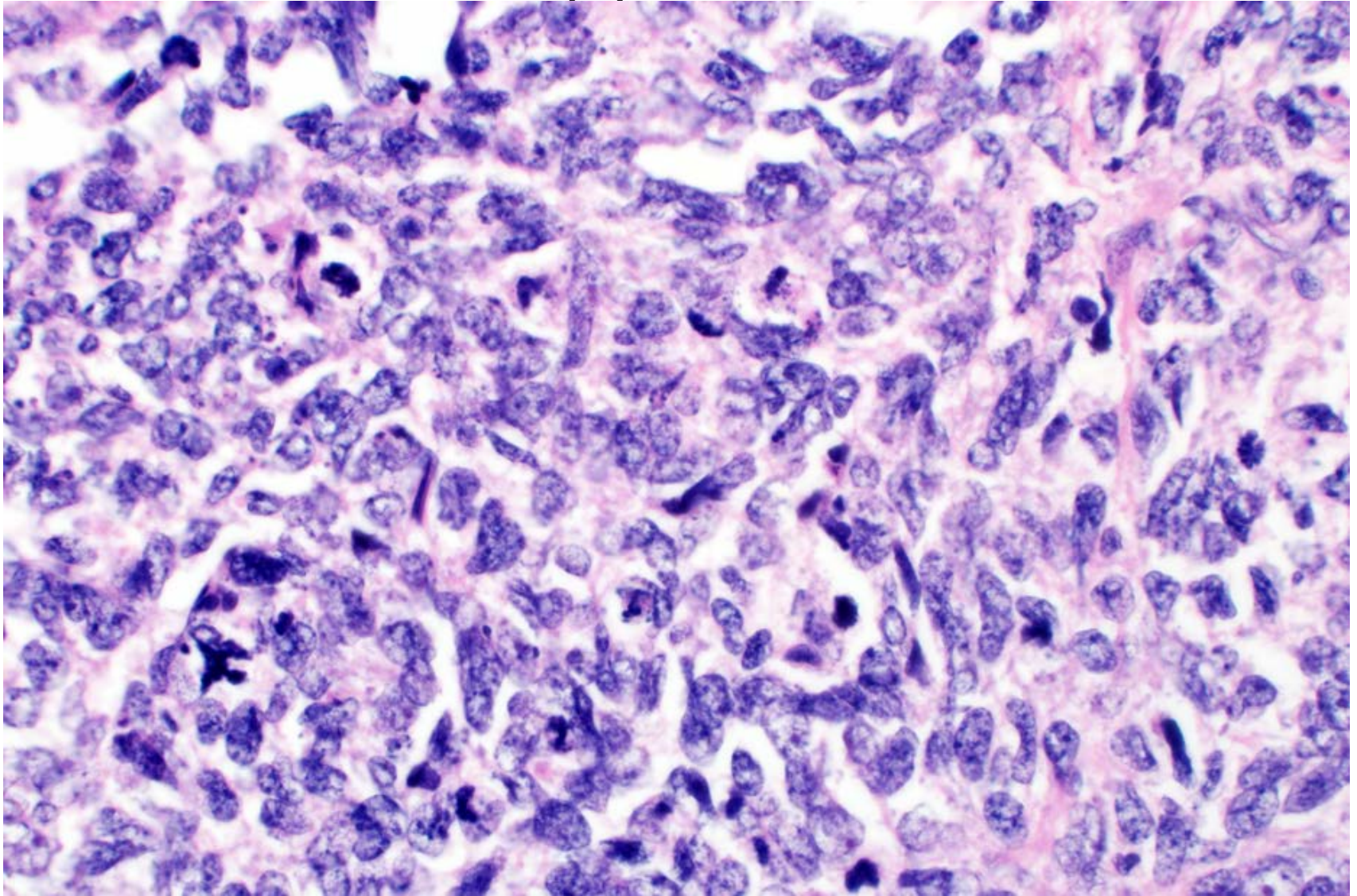
Neuroendocrine Carcinoma with Low Grade Endometrioid Carcinoma

Potential Confusion as Solid Pattern Endometrioid Cancer



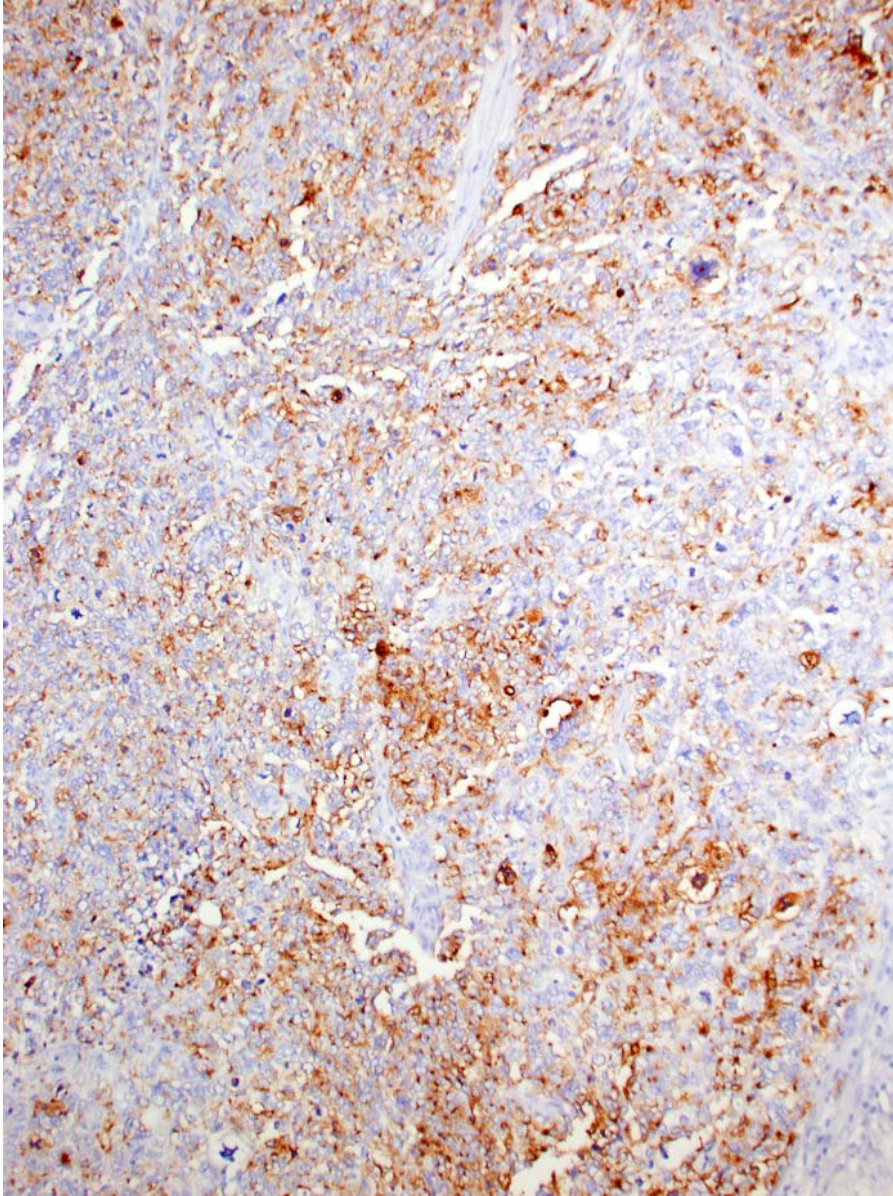
Neuroendocrine Carcinoma with Low Grade Endometrioid Carcinoma

- Severe Atypia
- Atypical Mitoses
- Apoptosis

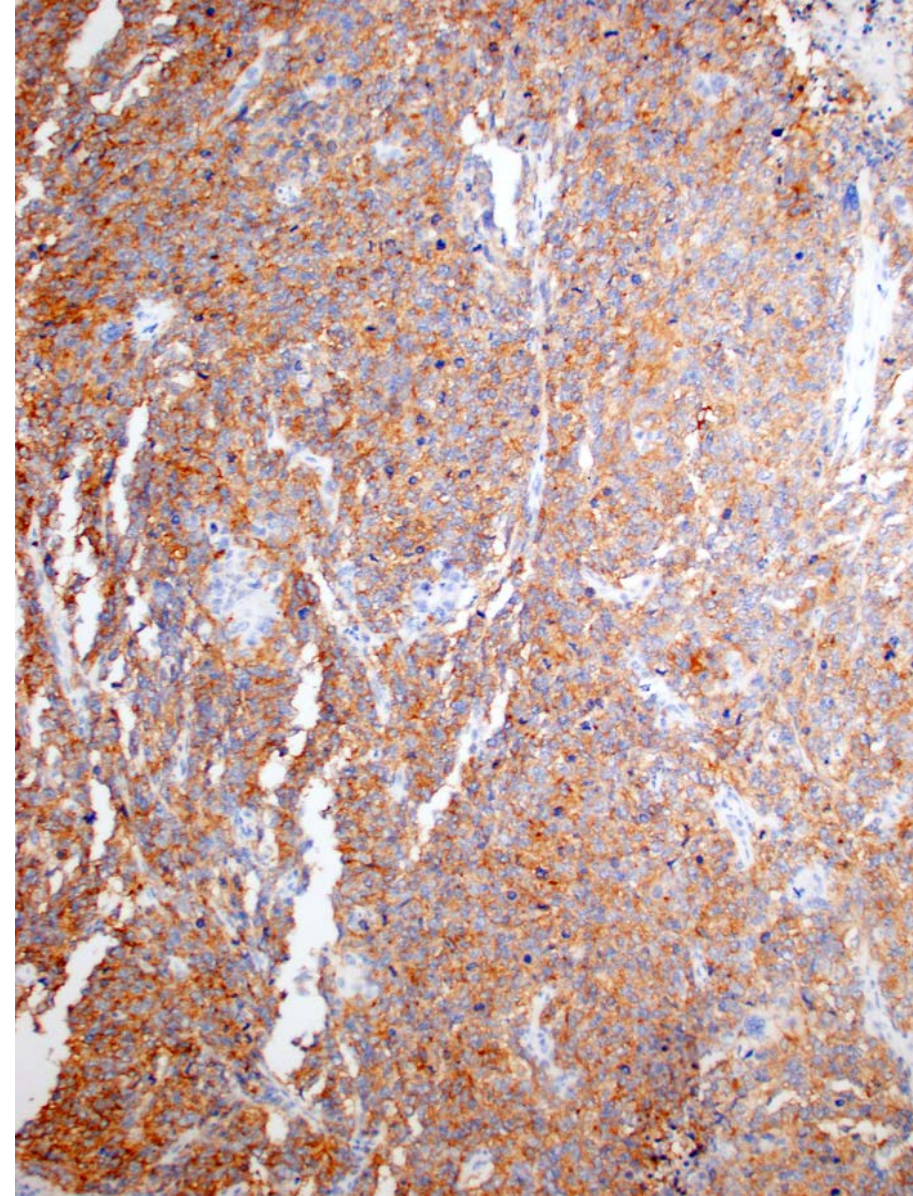


Neuroendocrine Carcinoma with Low Grade Endometrioid Carcinoma

Chromogranin



Synaptophysin



Biopsy with solid pattern high grade malignancy

How specific does the sub-typing need to be in a biopsy?

Reasonable to report as “high grade adenocarcinoma” with a comment.

- Serous carcinoma
- Grade 3 endometrioid adenocarcinoma
- Undifferentiated uterine carcinoma
- Neuroendocrine carcinoma
- Undersampled carcinosarcoma



**Any of these Requires
Full Surgical Staging**

Outline of Talk

Practical problems in sub-typing uterine carcinoma:

- Variants of g1 endometrioid adenocarcinoma that mimic high risk tumors
- MELF-pattern myoinvasion in g1 endometrioid adenocarcinoma
- New to 2014 WHO: undifferentiated / dedifferentiated carcinoma

