

**GASTROPATOLOJİ KURSU**  
**14 Ekim 2015**  
**ENDOSKOPIK BİYOPSİ VE REZEKSİYON**  
**MATERYALLERİNE YAKLAŞIM VE RAPORLAMA**

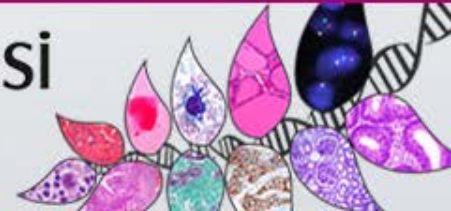**Gastrointestinal kanalda lenfomaya yaklaşım**

**Işinsu Kuzu**  
**Ankara Üniversitesi Tıp Fakültesi**  
**Patoloji AD**



**25. Ulusal Patoloji Kongresi**  
**6. Sitopatoloji Kongresi**

14 - 17 Ekim 2015 / Merinos AKKM - BURSA



# SUNUM AKIŐI

- Mukozal immün sistem organizasyonu
- Lenfoid lezyonların deęerlendirmesinde genel kavramlar
- Benign Lenfoid Hiperplaziler
- B hücreli lenfomalar
- T /NK Hücreli lenfomalar
- İmmünyetmezlik ilişkili proliferasyonlar



**25.** Ulusal Patoloji Kongresi  
**6.** Sitopatoloji Kongresi

14 - 17 Ekim 2015 / Merinos AKKM - BURSA



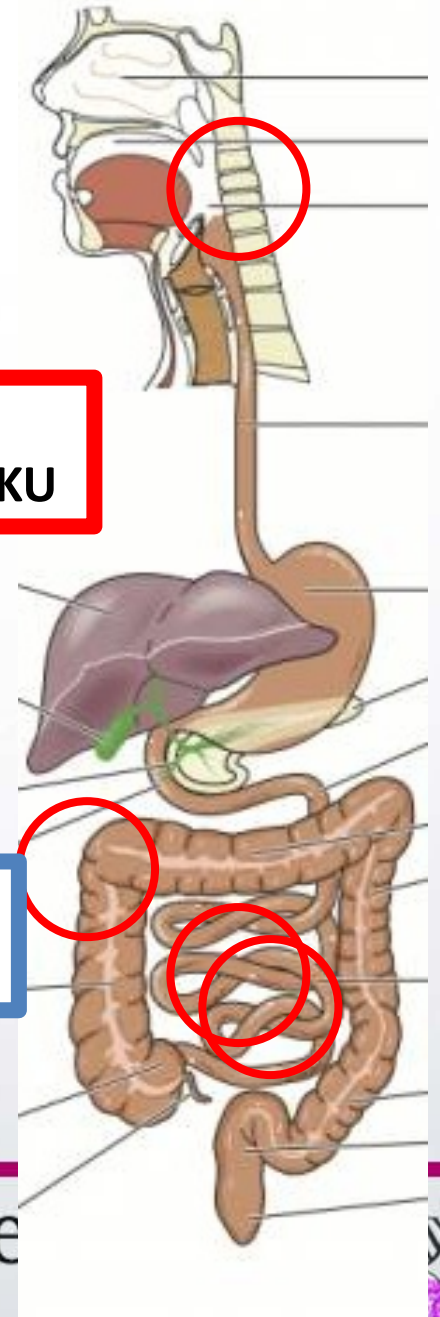
# Normal Gastrointestinal Kanal Mukozal İmmunsistem Organizasyonu

Yapısal Organize lenfoid doku

- Orofarenks
- Özofagus
- Mide
- Duodenum -İleum-jejunum
- Kolon-rektum

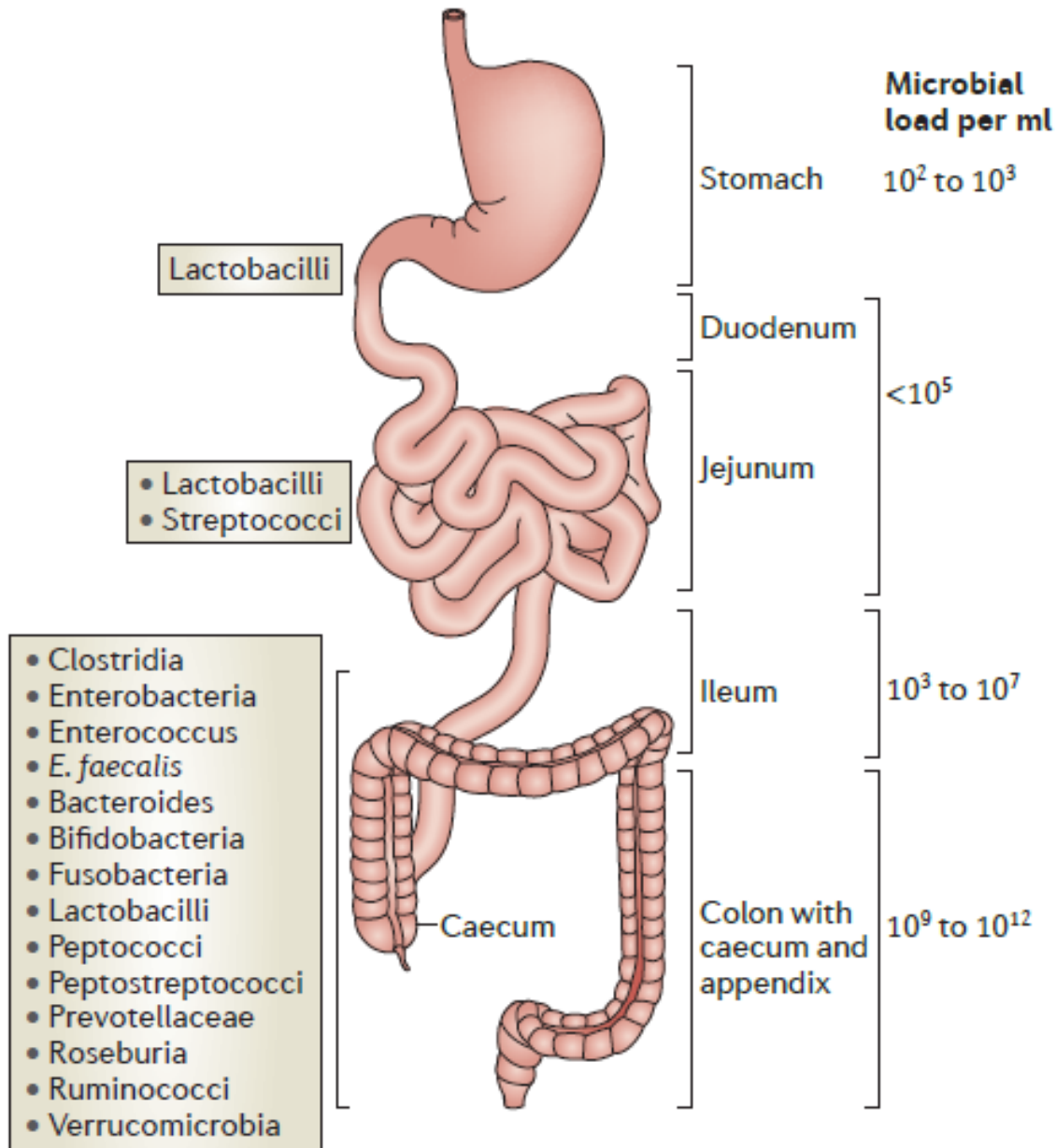
ORGANİZE  
LENFOİD DOKU

DİFFÜZ  
LENFOİD DOKU



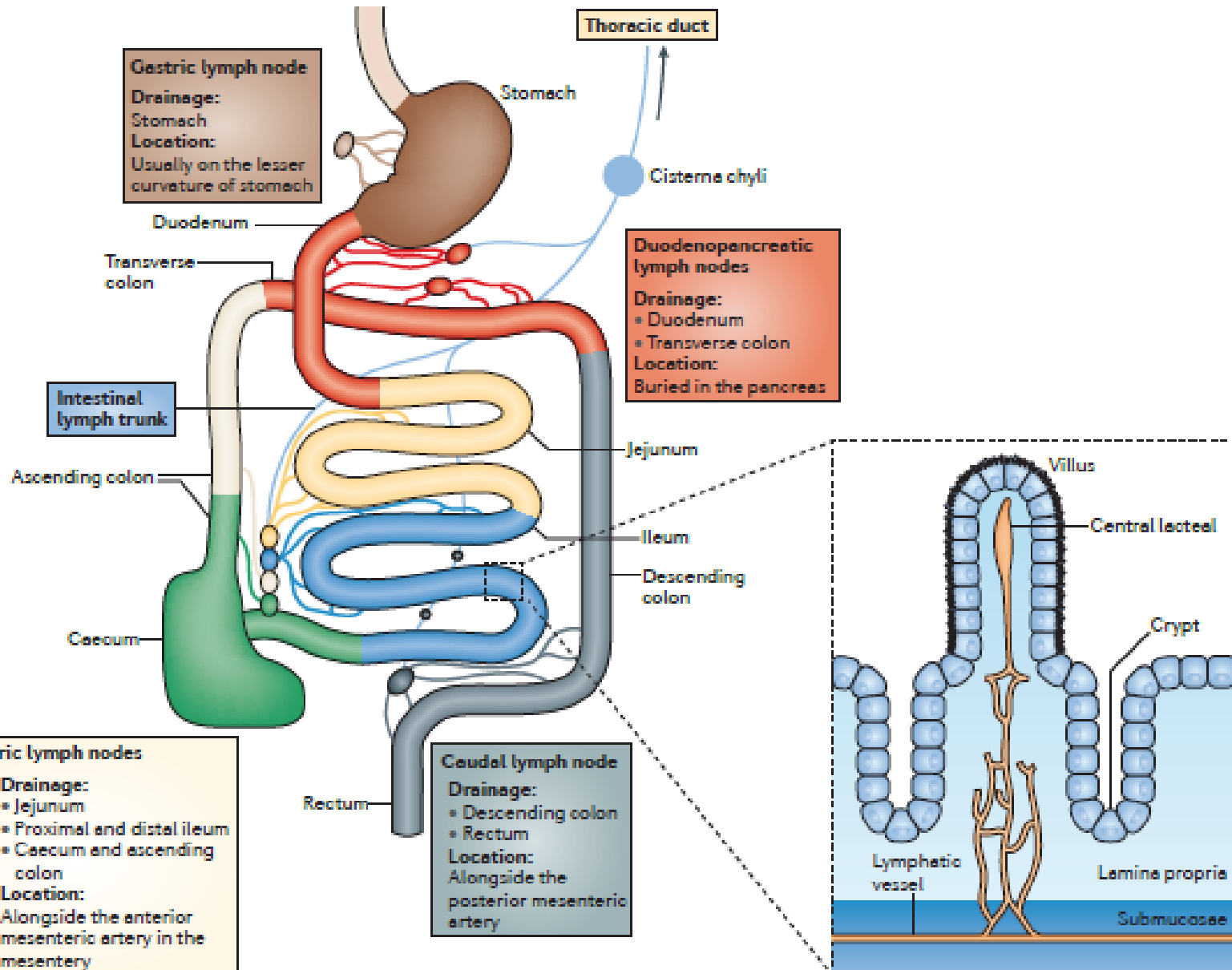
**25.** Ulusal Patoloji Kongresi  
**6.** Sitopatoloji Kongresi

14 - 17 Ekim 2015 / Merinos AKKM - BURSA



ongresi





**Gastric lymph node**  
 Drainage:  
 Stomach  
 Location:  
 Usually on the lesser curvature of stomach

**Thoracic duct**

**Duodenopancreatic lymph nodes**  
 Drainage:  
 • Duodenum  
 • Transverse colon  
 Location:  
 Buried in the pancreas

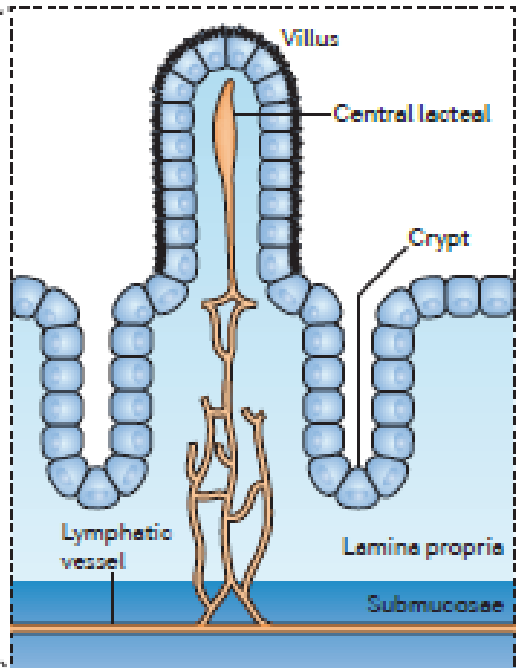
**Intestinal lymph trunk**

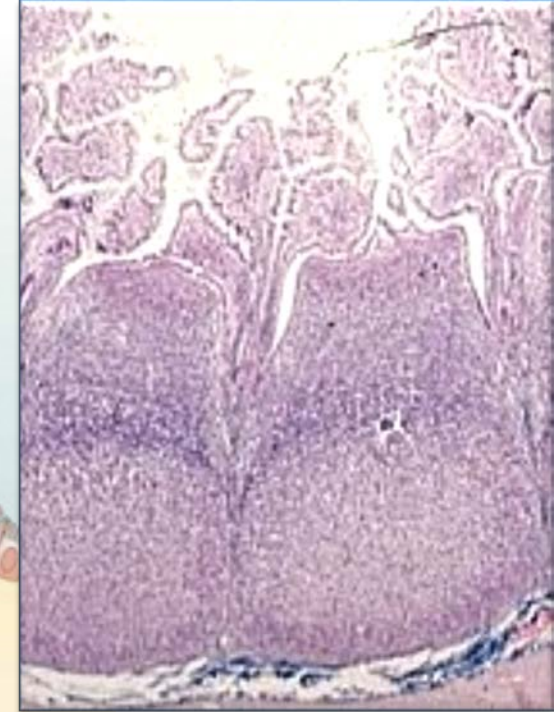
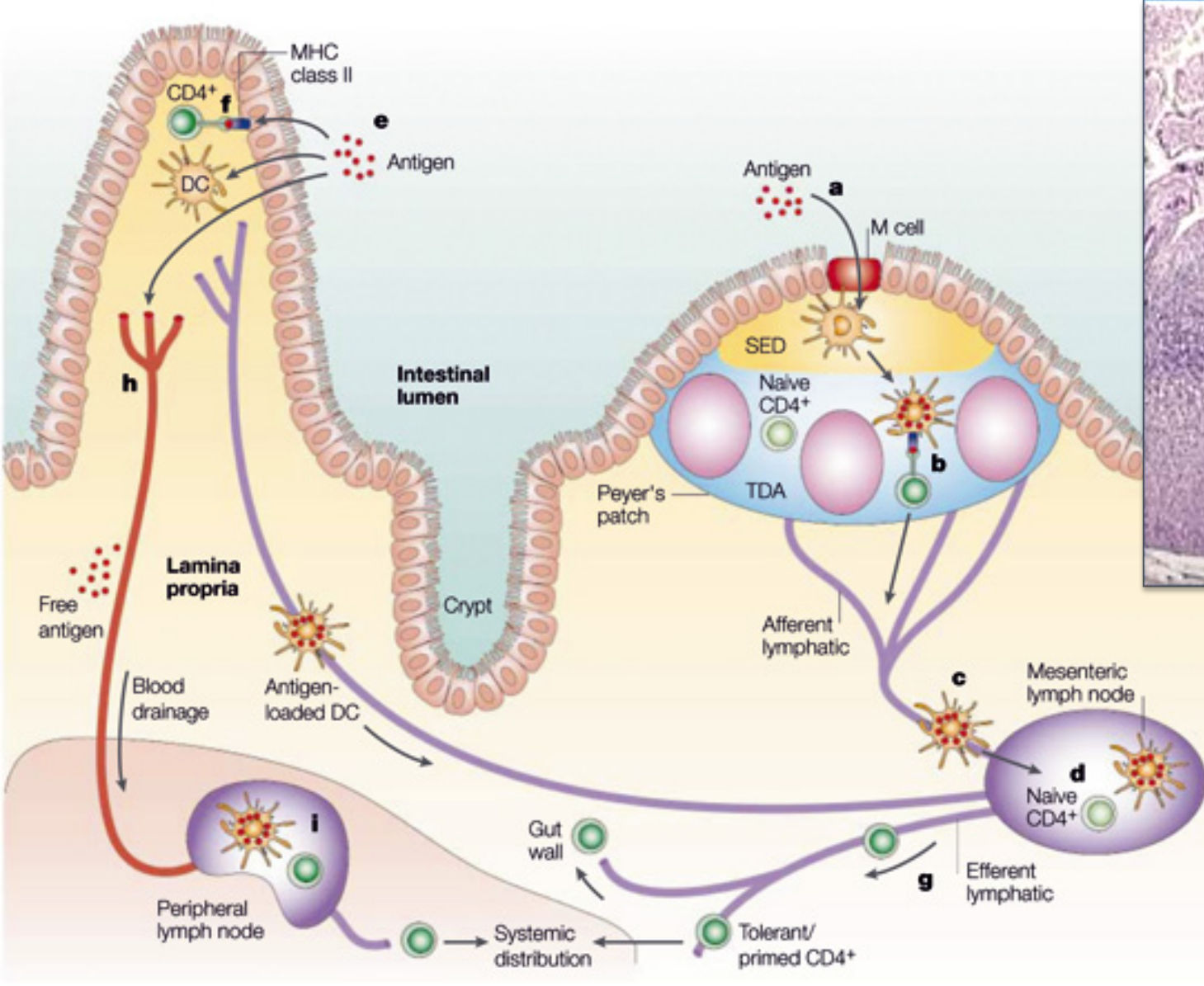
**Mesenteric lymph nodes**

- Jejunum
- Proximal and distal ileum
- Caecum and ascending colon

Location:  
 Alongside the anterior mesenteric artery in the mesentery

**Caudal lymph node**  
 Drainage:  
 • Descending colon  
 • Rectum  
 Location:  
 Alongside the posterior mesenteric artery



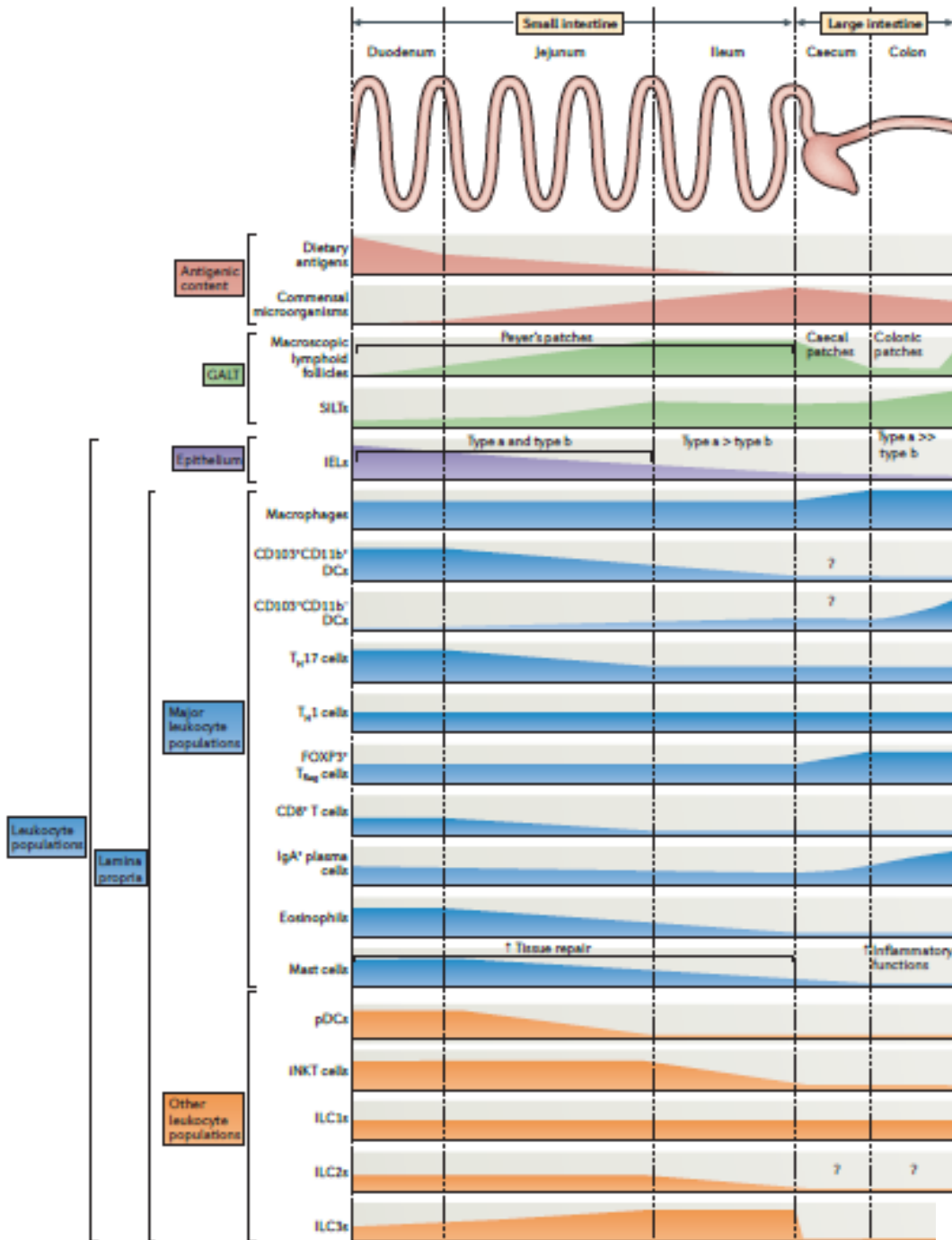


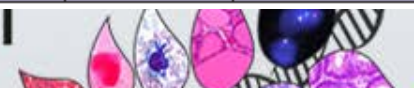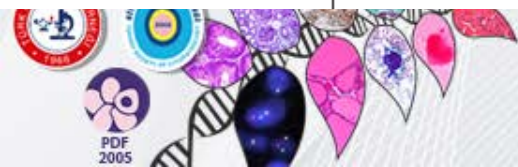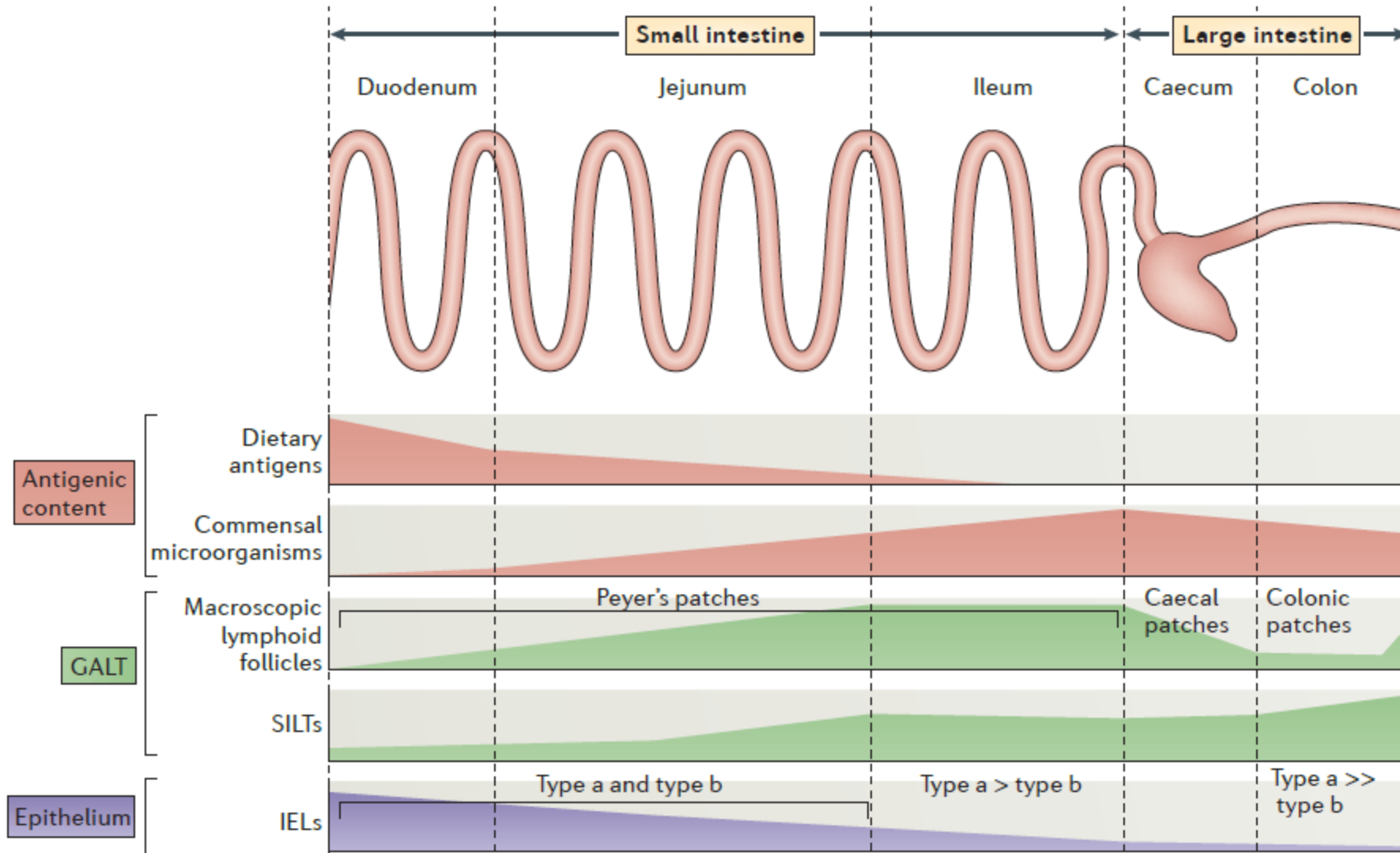
# 25. Ulusal Patoloji Kongresi

## 6. Sitopatoloji Kongresi

14 - 17 Ekim 2015 / Merinos

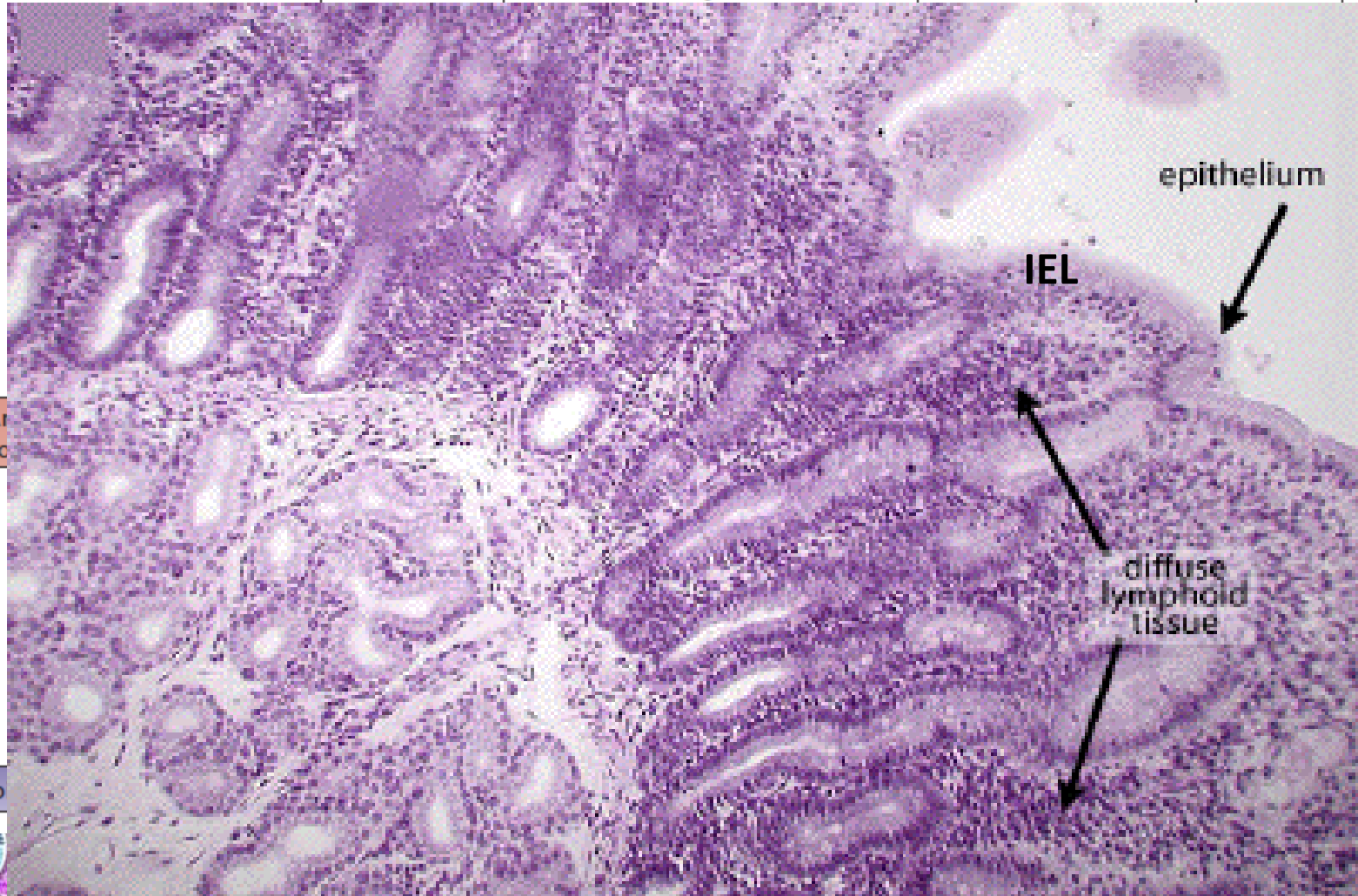
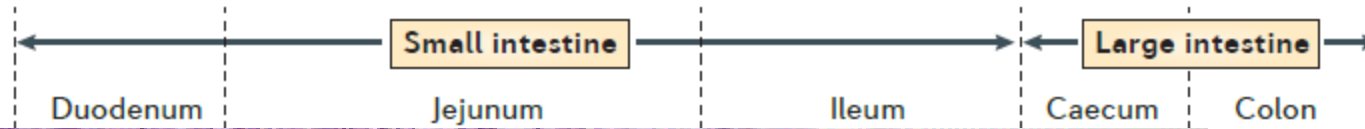
Mowat, Nature Rev Immunol 2015







# DUODENUM



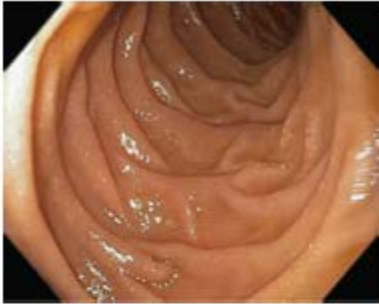Ar  
cc

Ep

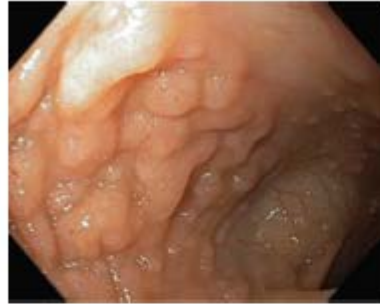

# JEJENUM-ILEUM-KOLON

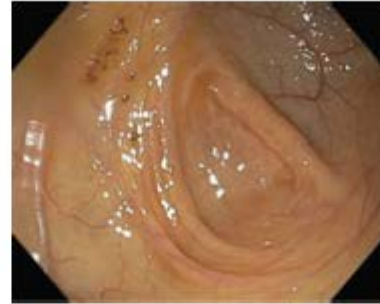Jejunum



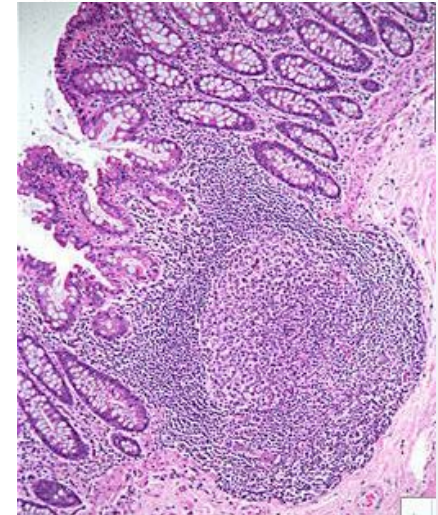
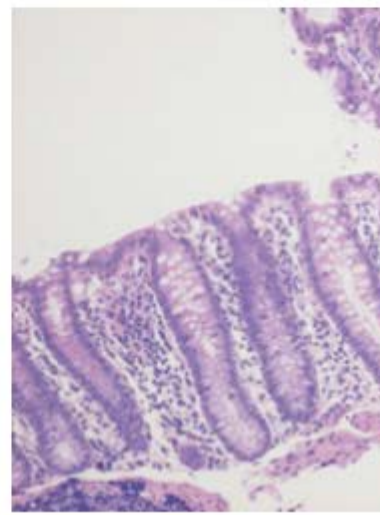
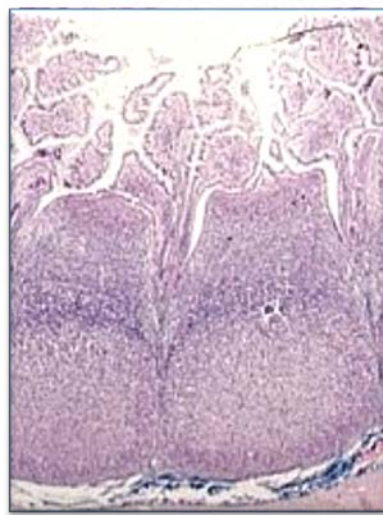
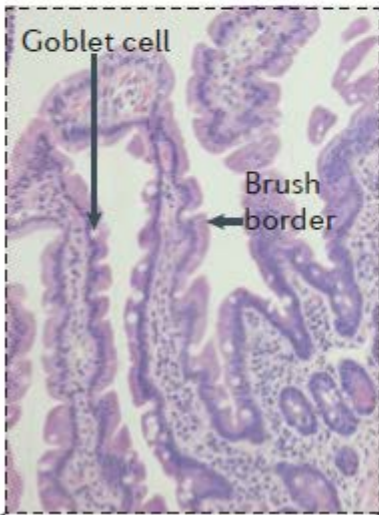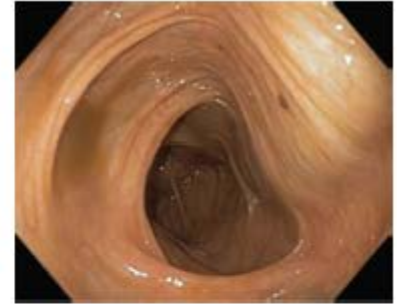Ileum



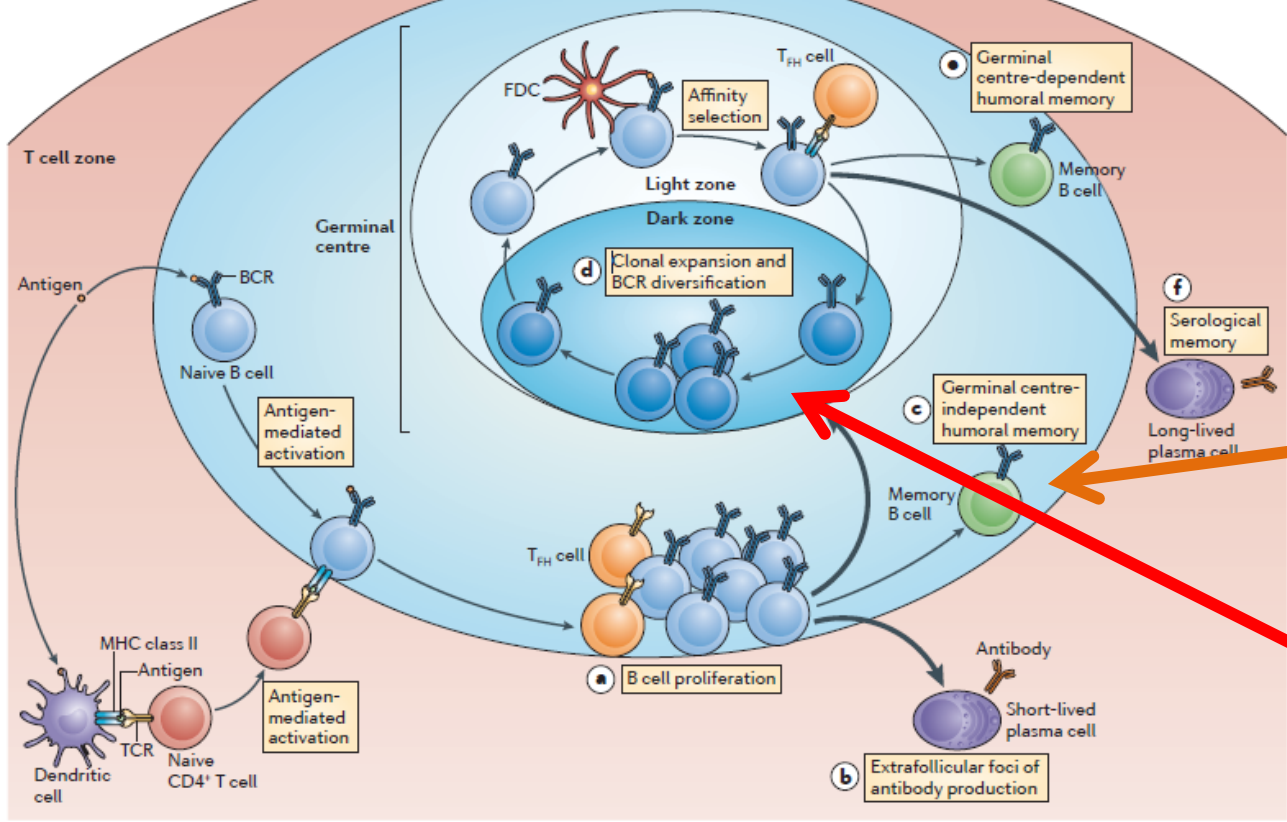
Caecum



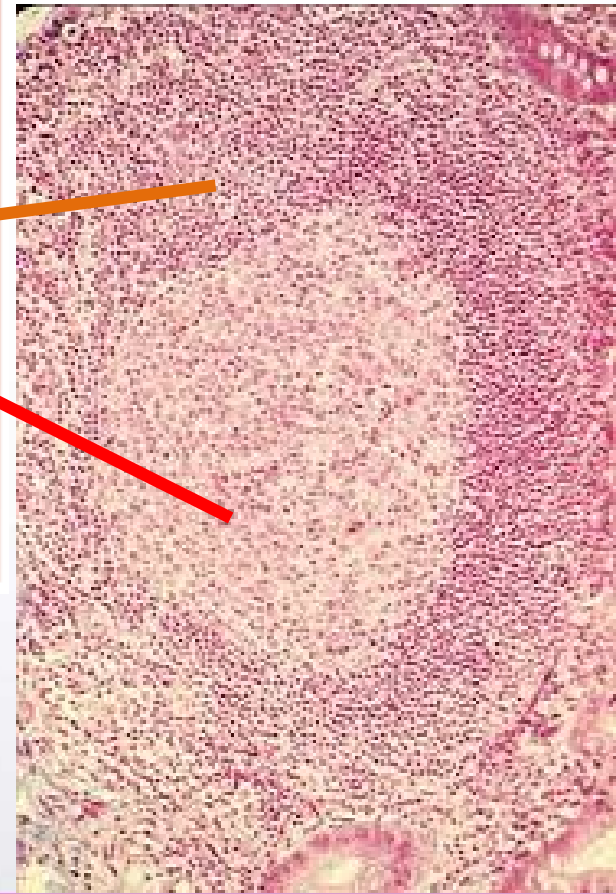
Colon



Secondary lymphoid organ



**ORGANIZE  
LENFOİD DOKU**

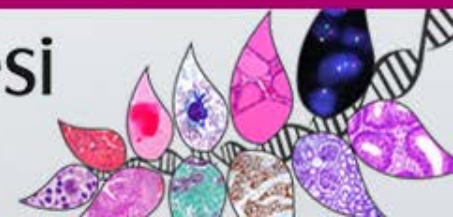

**LENFOİD FOLİKÜL**



**25.** Ulusal Patoloji Kongresi  
**6.** Sitopatoloji Kongresi

14 - 17 Ekim 2015 / Merinos AKKM - BURSA



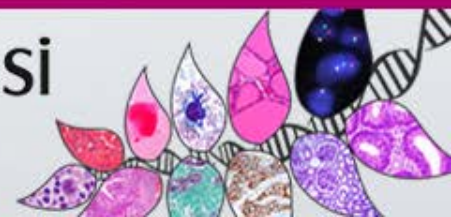# GASTROİNTESTİNAL KANALDA LENFOİD LEZYONLARIN TANI GÜÇLÜĞÜ

- Küçük biyopsi materyalleri
- Benign reaktif lenfoid proliferasyonlar sıktır.
  - Enfeksiyon
  - Otoimmün sebepli
  - İnflamatuvar hastalıklar
  - İmmün yetmezlik sendromları (çocuk ve erişkin)



**25.** Ulusal Patoloji Kongresi  
**6.** Sitopatoloji Kongresi

14 - 17 Ekim 2015 / Merinos AKKM - BURSA

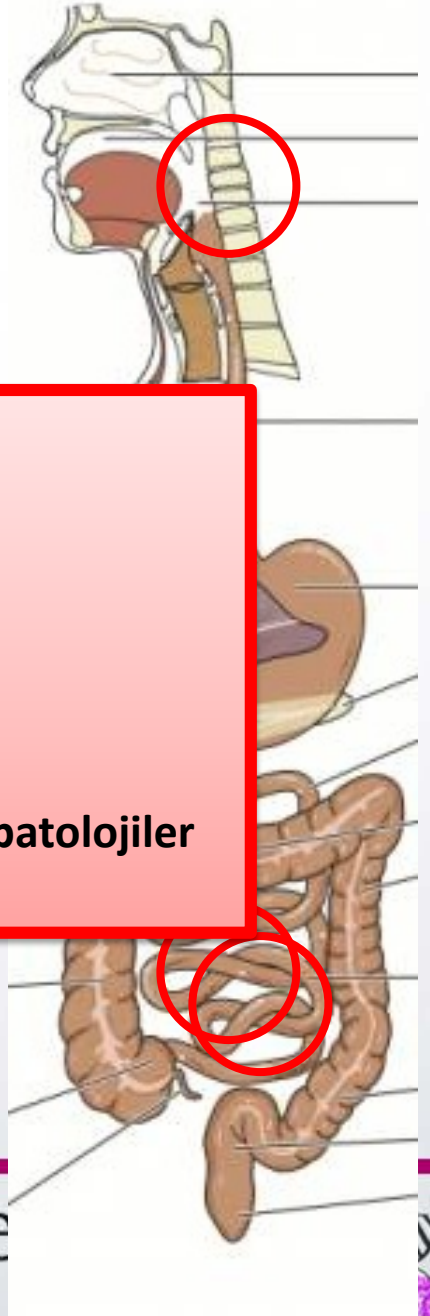


# Lenfoma ile karışacak benign proliferasyonlar

Yapısal Organize lenfoid doku

- Orofarenks
- Özofagus
- Mide
- Duodenum -İleum-jejunum
- Kolon-rektum

Candida  
Bacterial  
Licken Planus  
Tekrarlayan stomatitler  
İmmun yetmezlikler  
Viral(HSV,EBV)  
EBV ilişkili lenfoproliferatif patolojiler



25. Ulusal Patoloji Kongresi  
6. Sitopatoloji Kongresi

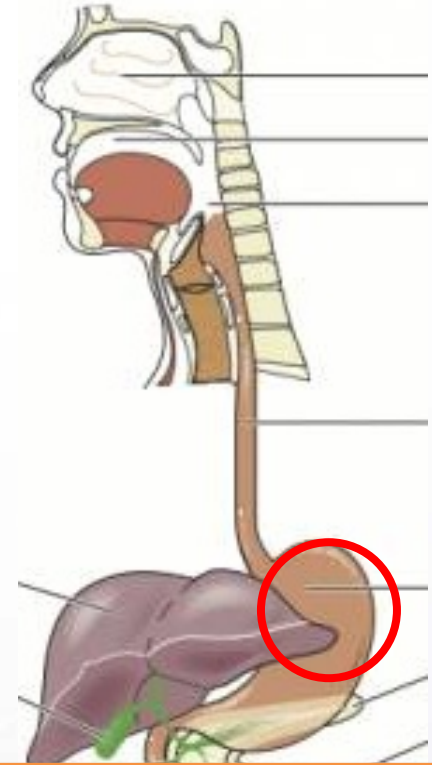
14 - 17 Ekim 2015 / Merinos AKKM - BURSA

# Lenfoma ile karışacak benign proliferasyonlar

Yapısal Organize lenfoid doku

- Orofarenks
- Özofagus
- Mide
- Duodenum -Ileum-jejunum
- Kolon-rektum

HP Gastriti  
Otoimmün Gastrit  
Lenfositik Gastrit  
Lenfomatoid Gastropati (NK hücreli enteropati) ??  
Yavaş seyirli T hücreli lenfoproliferatif hastalıklar



**25.** Ulusal Patoloji Kongresi  
**6.** Sitopatoloji Kongresi

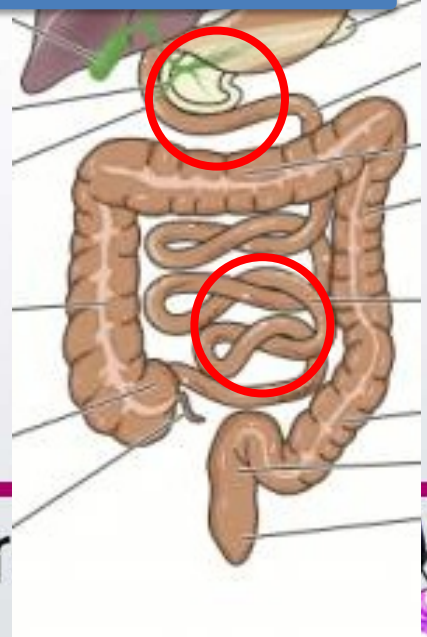
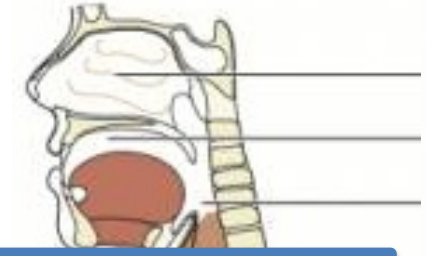14 - 17 Ekim 2015 / Merinos AKKM - BURSA

# Lenfoma ile karışacak benign proliferasyonlar

Yapısal Organize lenfoid doku

- Orofarenks
- Özofagus
- Mide
- Duodenum -İleum-jejenum
- Kolon-rektum

Gluten Enteropatisi  
H pylori gastroduodenitii  
Gluten dışı besin allerjisi  
bacterial overgrowth,  
İlaç reaksiyonları  
Crohn Hastalığı  
GVHD

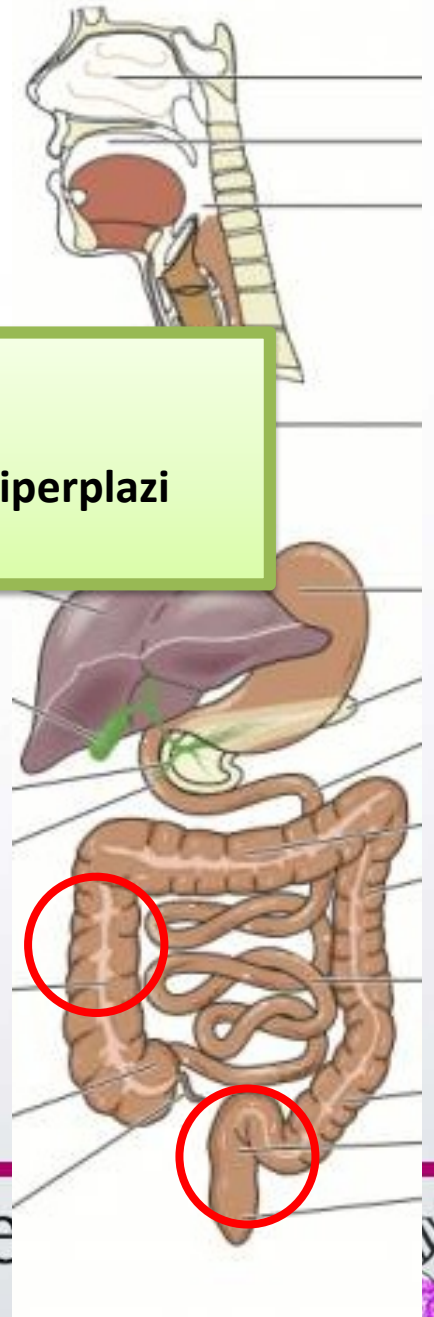

# Lenfoma ile karışacak benign proliferasyonlar

Yapısal Organize lenfoid doku

- Orofarenks
- Özofagus
- Mide
- Duodenum -İleum-jejunum
- Kolon-rektum

Lenfositik kolit  
Crohn Hastalığı  
Rekta lenfoid hiperplazi  
GVHD

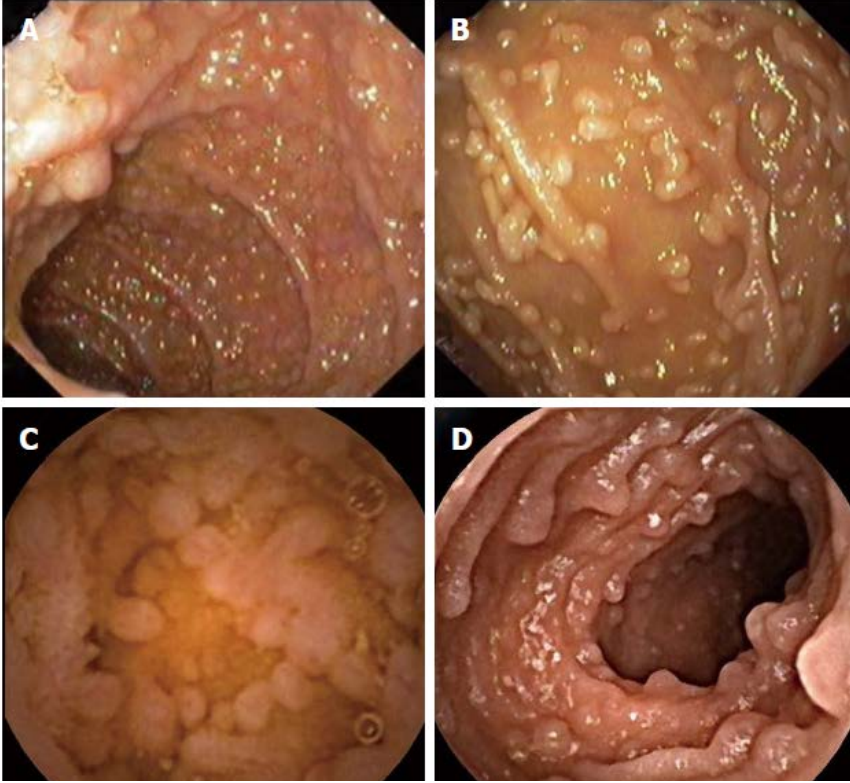




# **GASTROİNTESTİNAL KANALDA LENFOİD LEZYONLARI DEĞERLENDİRİRKEN**

- **Normal komponentler ile lezyonları karşılaştırmak (lenfositler, plazma hücreleri, diğer inflamatuvar hücreler)**
- **Herhangi bir hücre komponentinin hakim olup olmadığına bakmak (T, B , Plazma)**
- **Lenfoid infiltrasyonun yaygınlığını değerlendirmek**
- **Atipik özellikler (hücre , organizasyon)**

# BENIGN NODÜLER LENFOİD HİPERPLAZİ

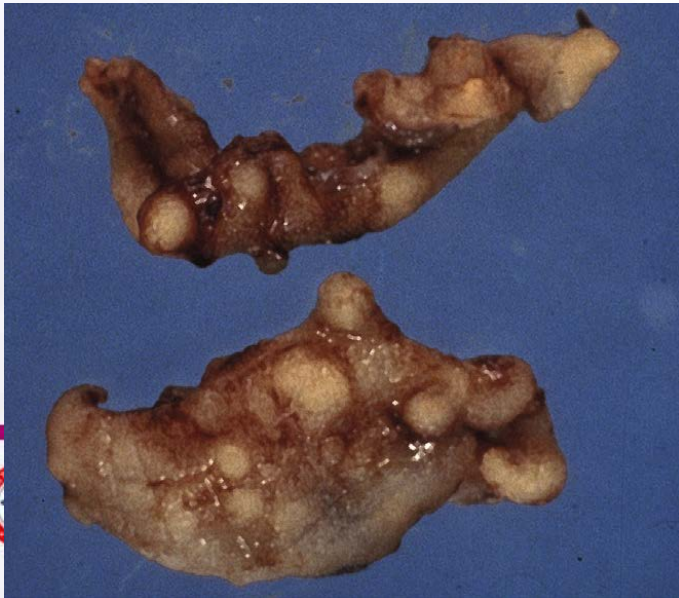
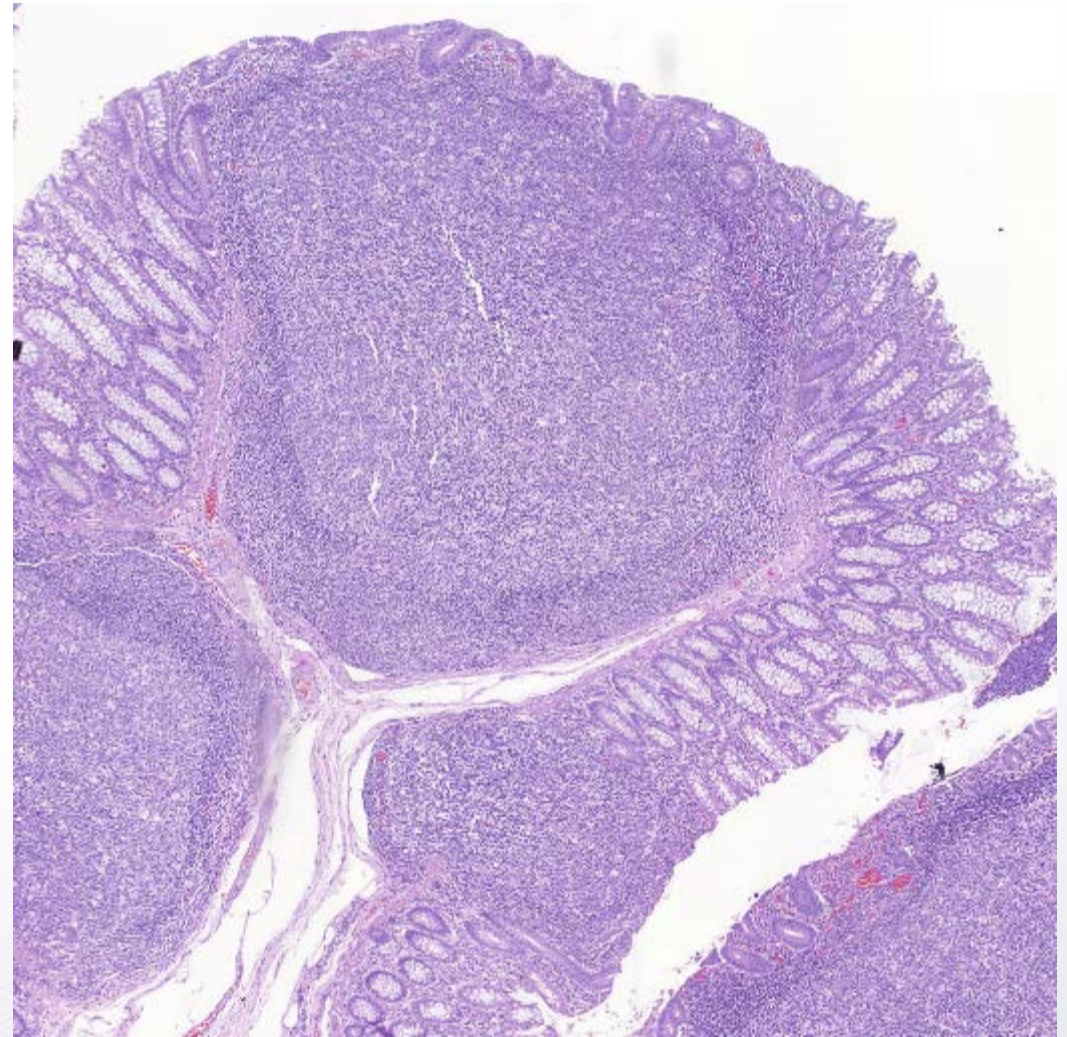
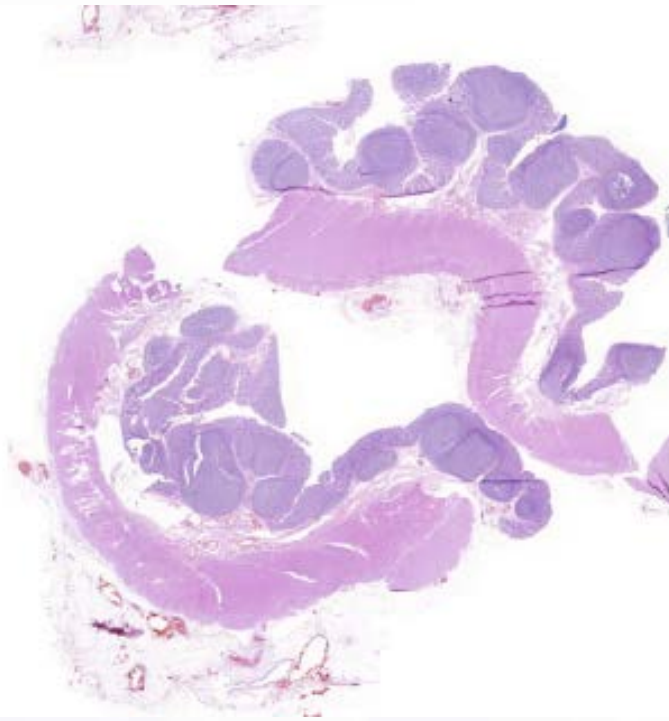


**Diffüz Nodüler  
Fokal (ileum, Rektum)**

**Çocuk > Erişkin**

## **PATOGENEZ**

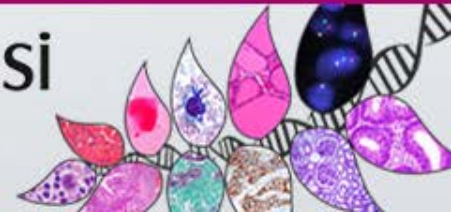- 1- İmmun yetmezlik: CVID (IgG, IgA ve /veya IgM Hipo gammaglobulinemi)  
(selektif IgA eksikliği)**
- 2- Enfeksiyonlar: Giardia,  
H Pylori,**

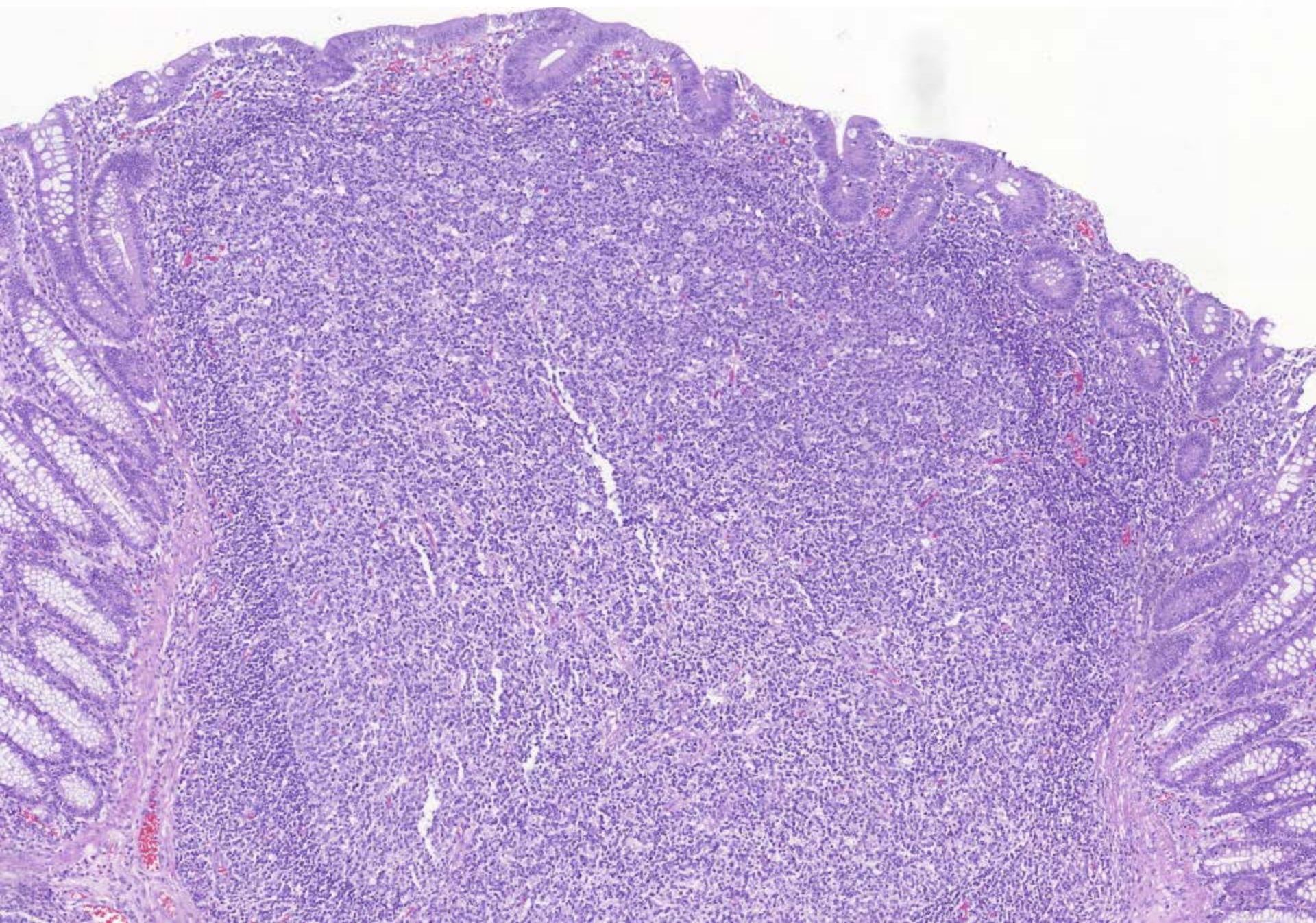


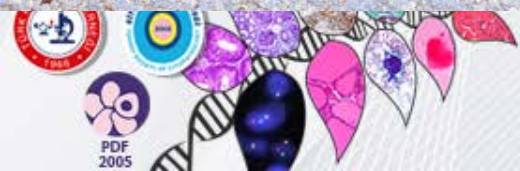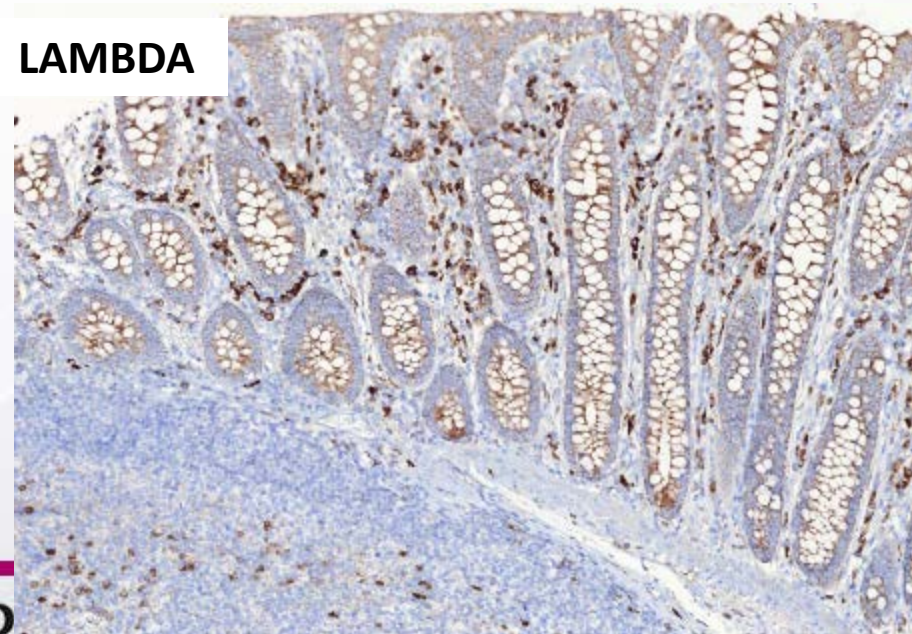
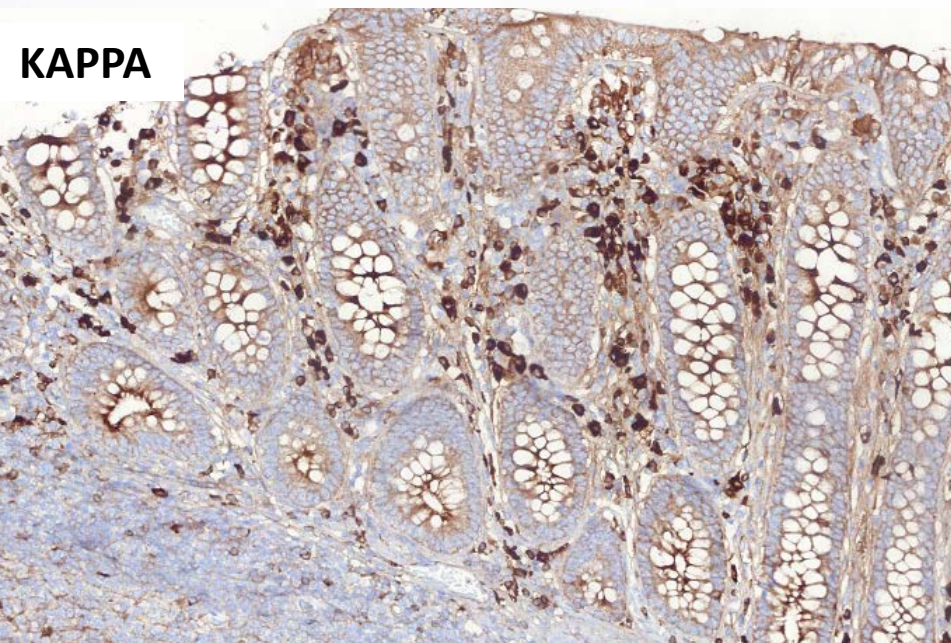
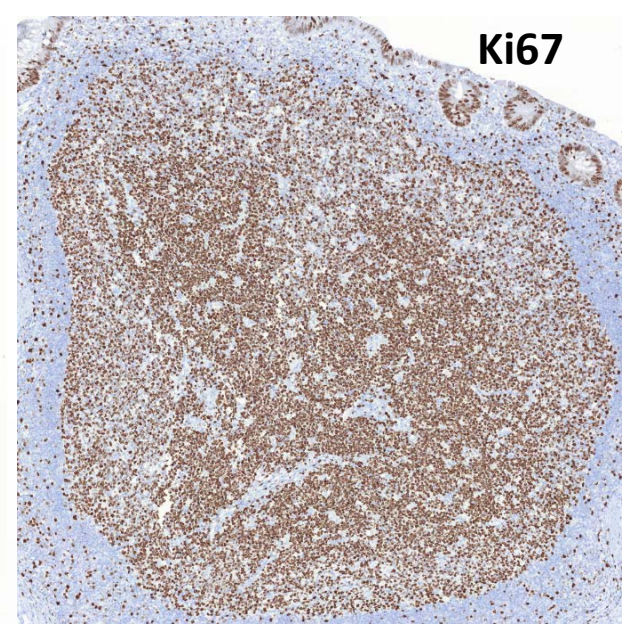
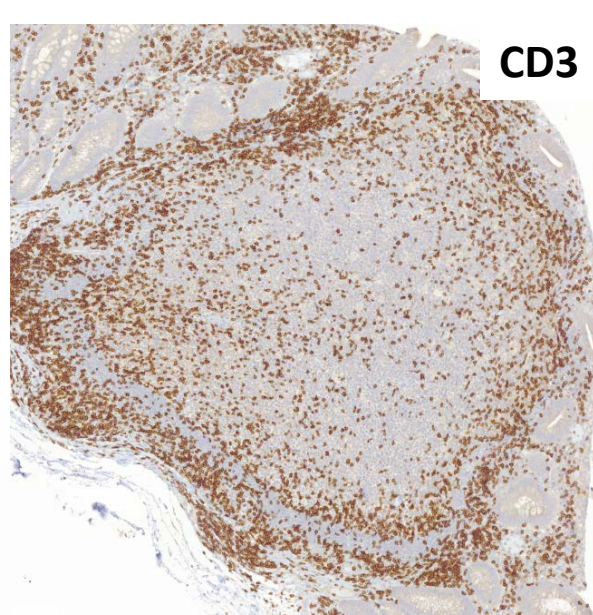
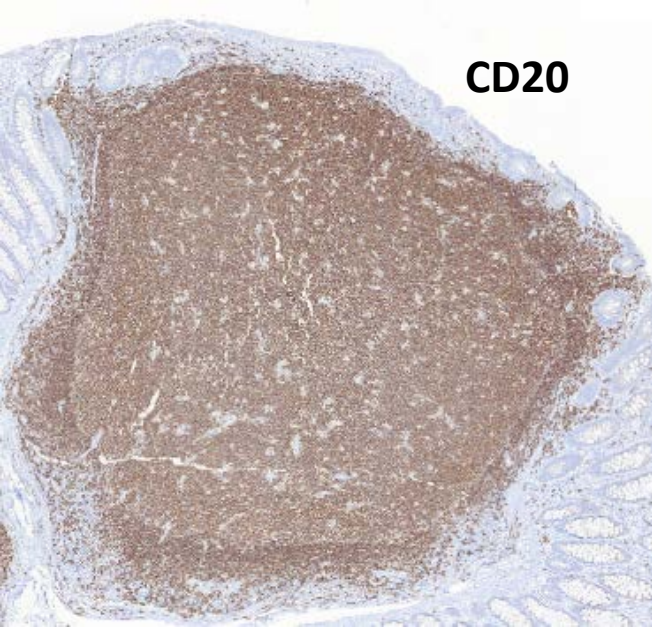
# Ulusal Patoloji Kongresi

## 6. Sitopatoloji Kongresi

14 - 17 Ekim 2015 / Merinos AKKM - BURSA

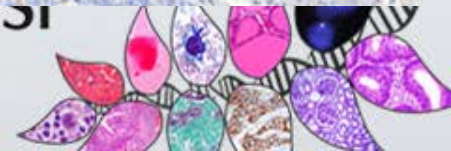



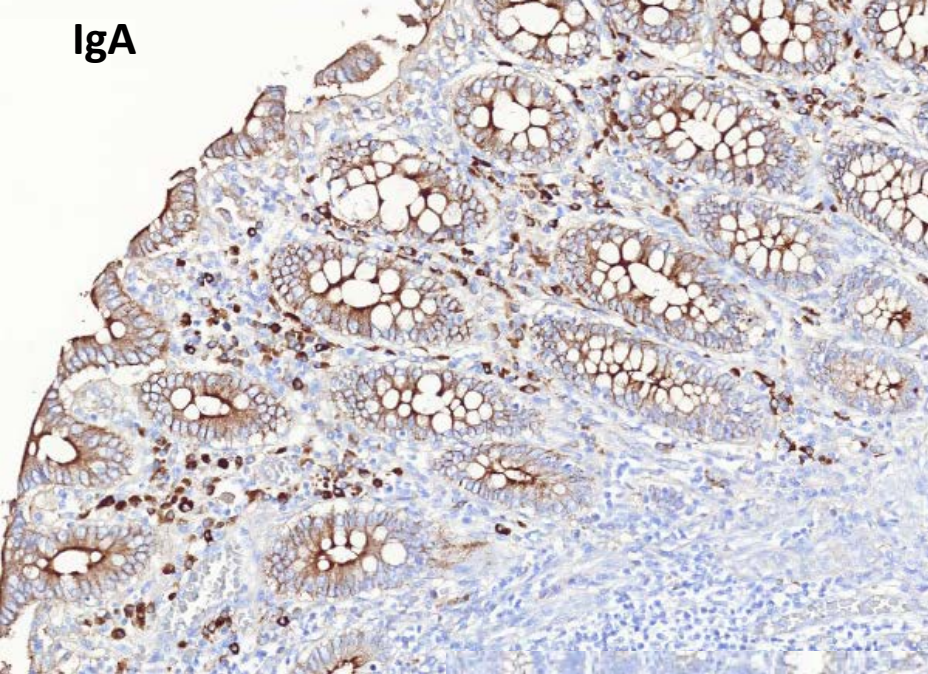


**25.** Ulusal Patoloji Kongresi  
**6.** Sitopatoloji Kongresi

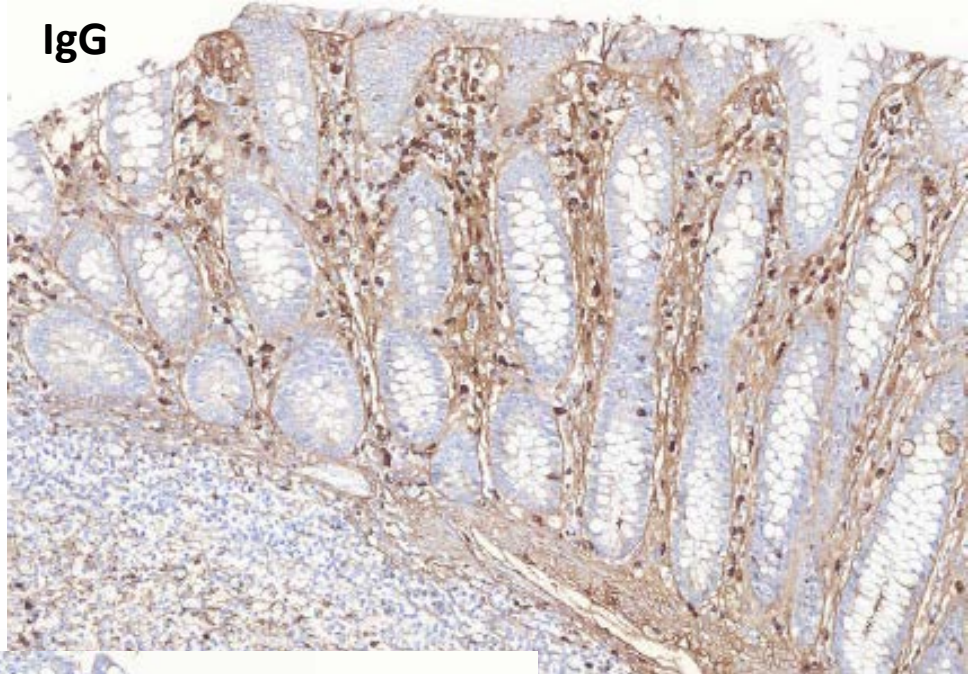14 - 17 Ekim 2015 / Merinos AKKM - BURSA



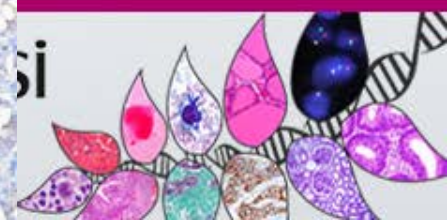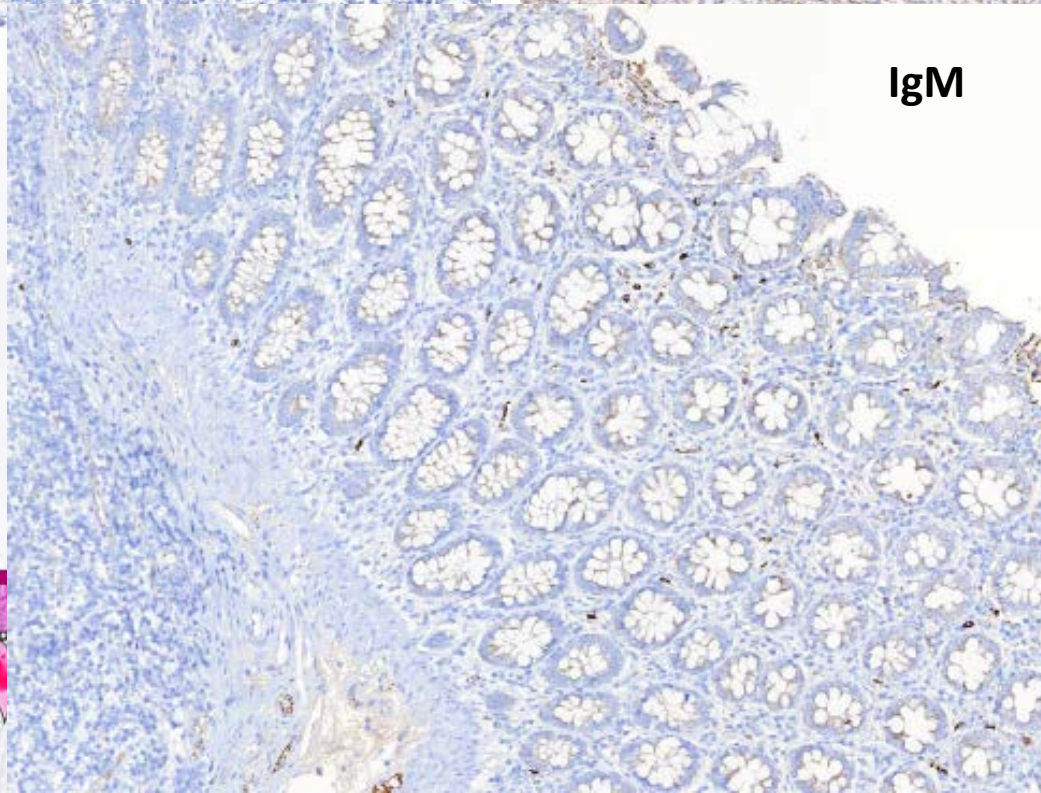
IgA



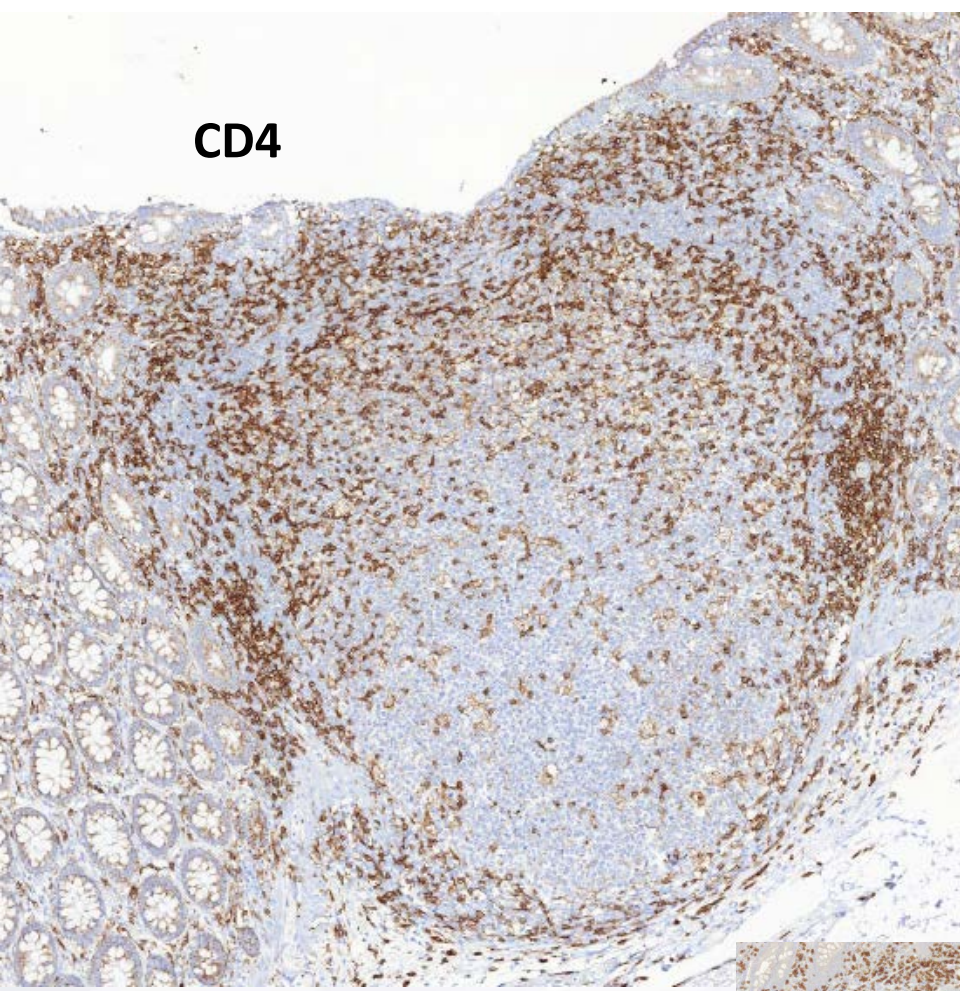
IgG



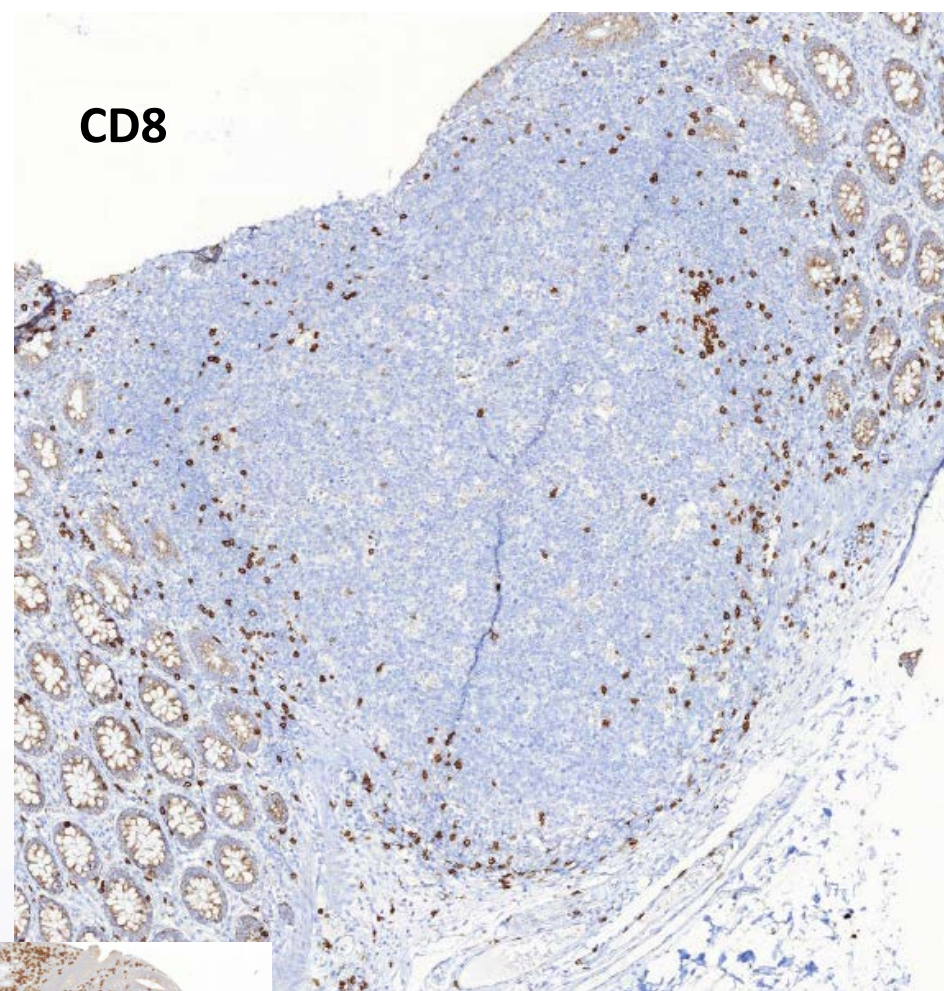
IgM



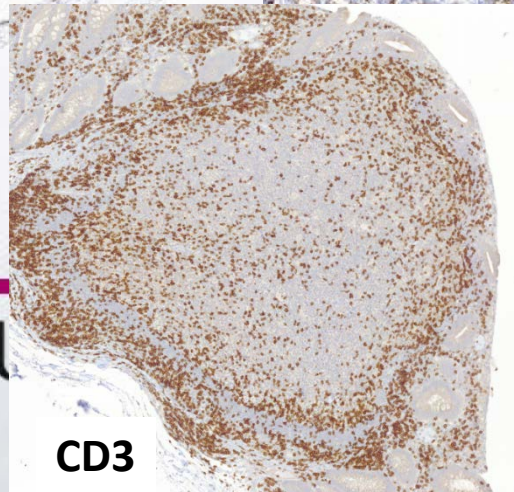
CD4



CD8



CD3



25

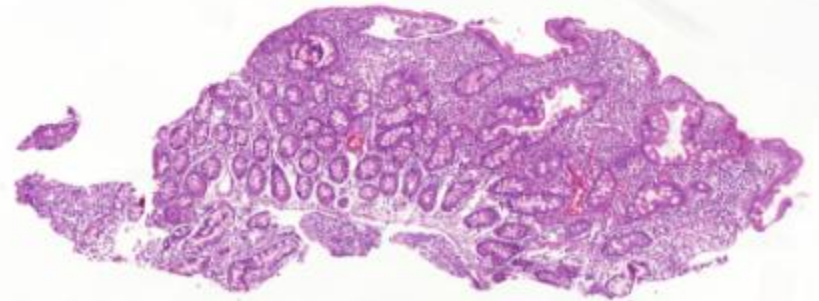
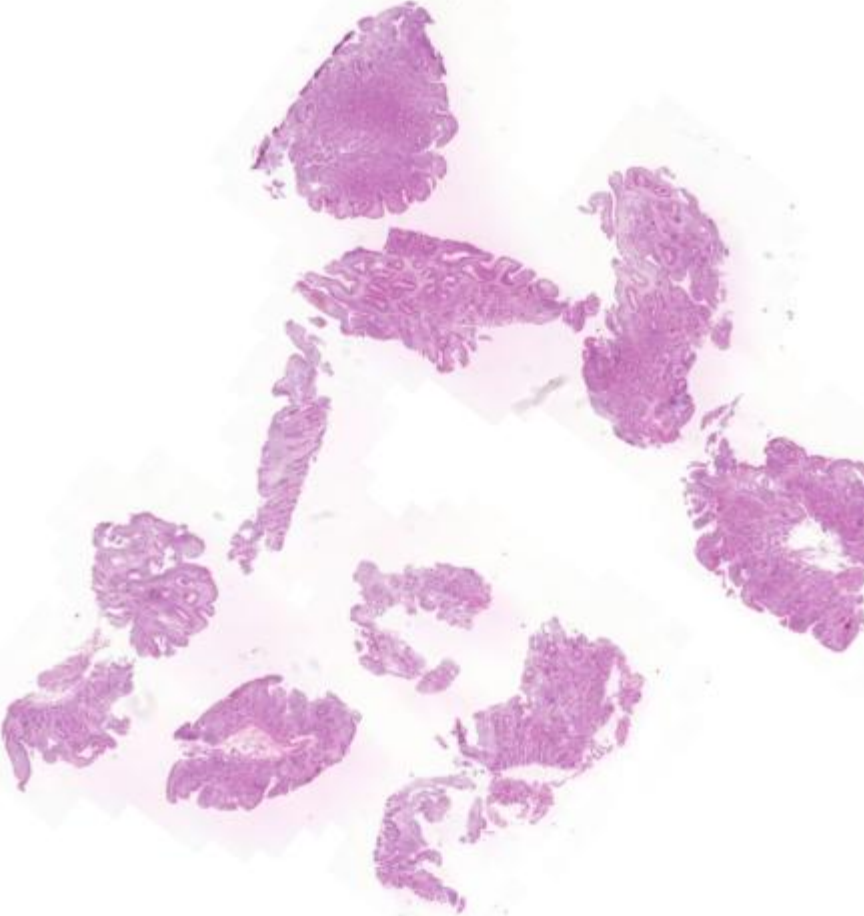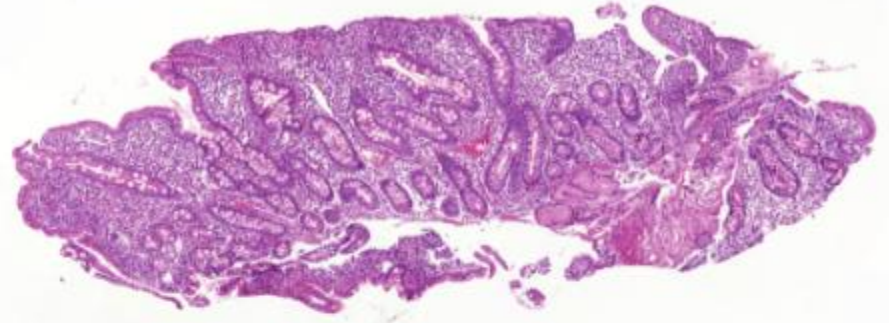
Kongresi  
ğresi  
- BURSA



# HASTA

7 Yaş Erkek

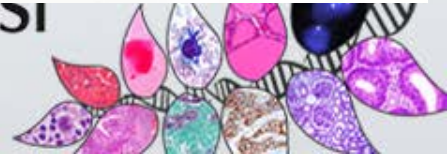Abdominal ağrı / diyare /  
deri döküntüsü öyküsü /  
pulmoner enfeksiyon



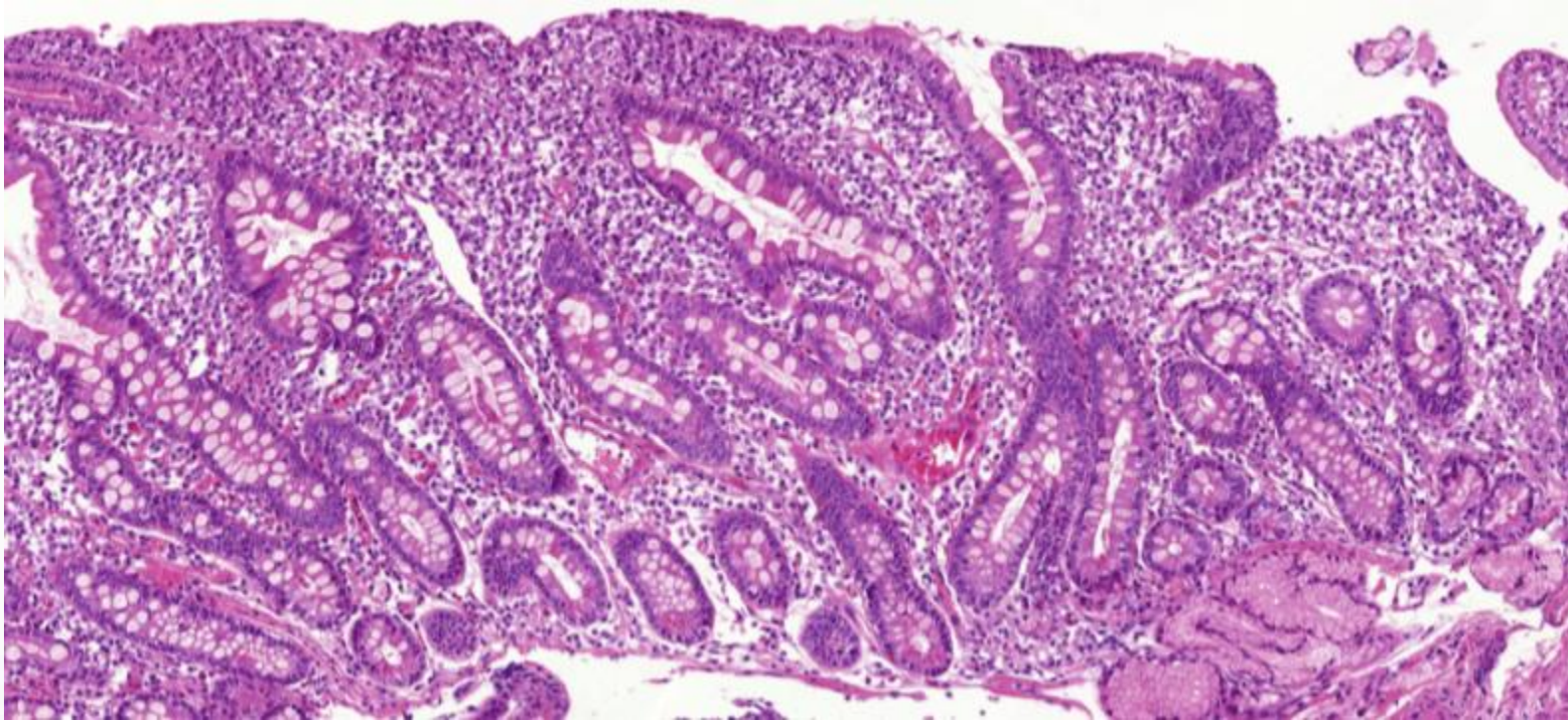
OGU KONGRESİ

ve Stomatoloji Kongresi

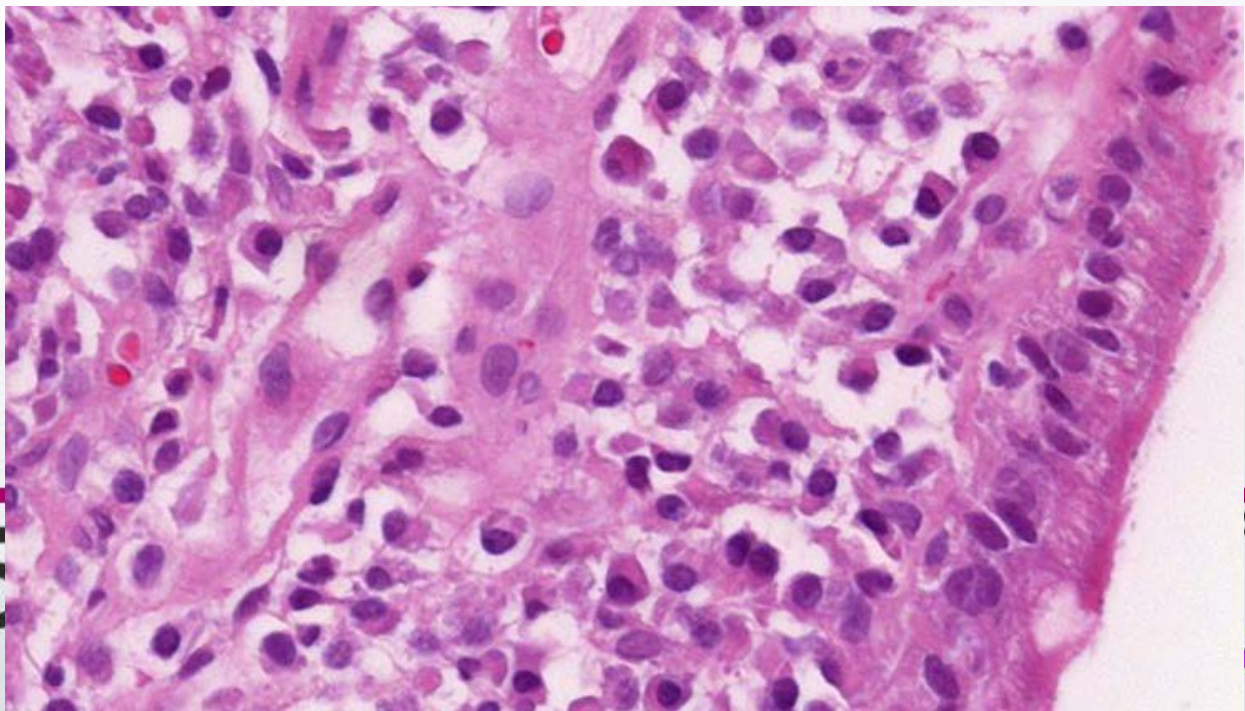
14 - 17 Ekim 2015 / Merinos AKKM - BURSA



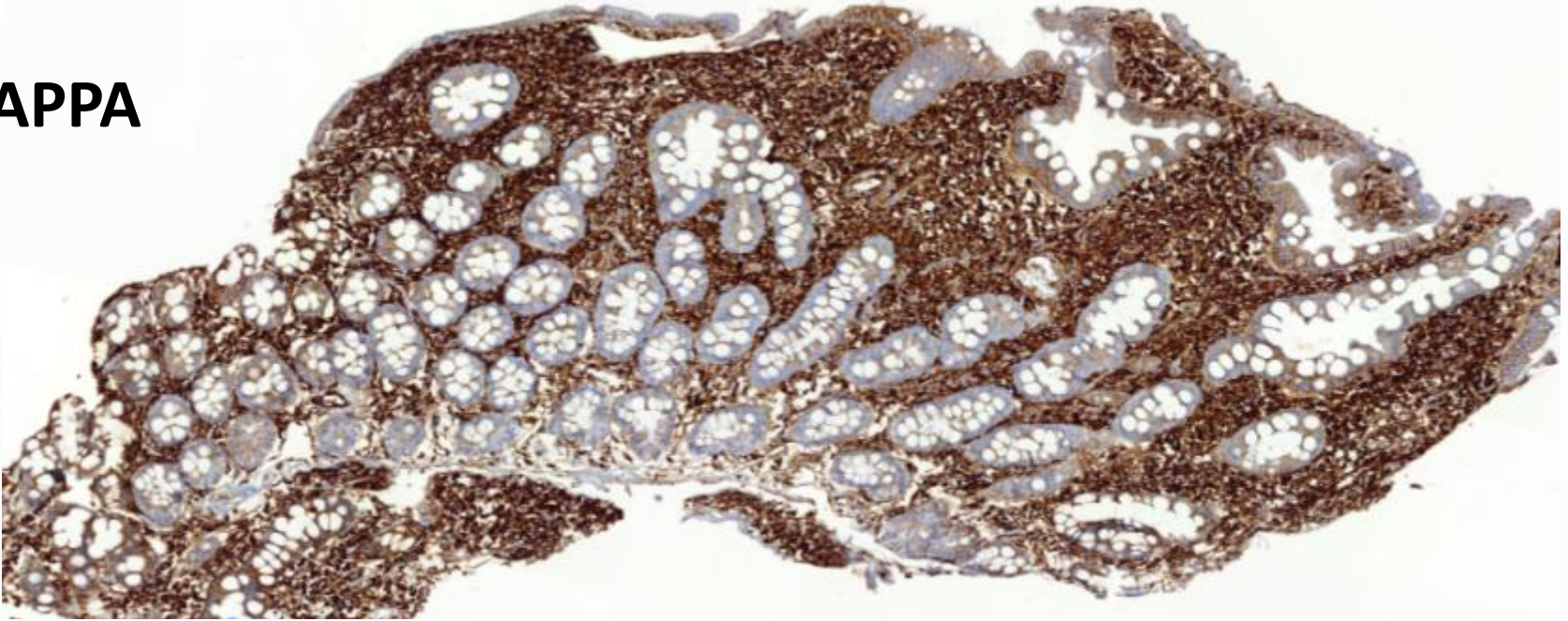




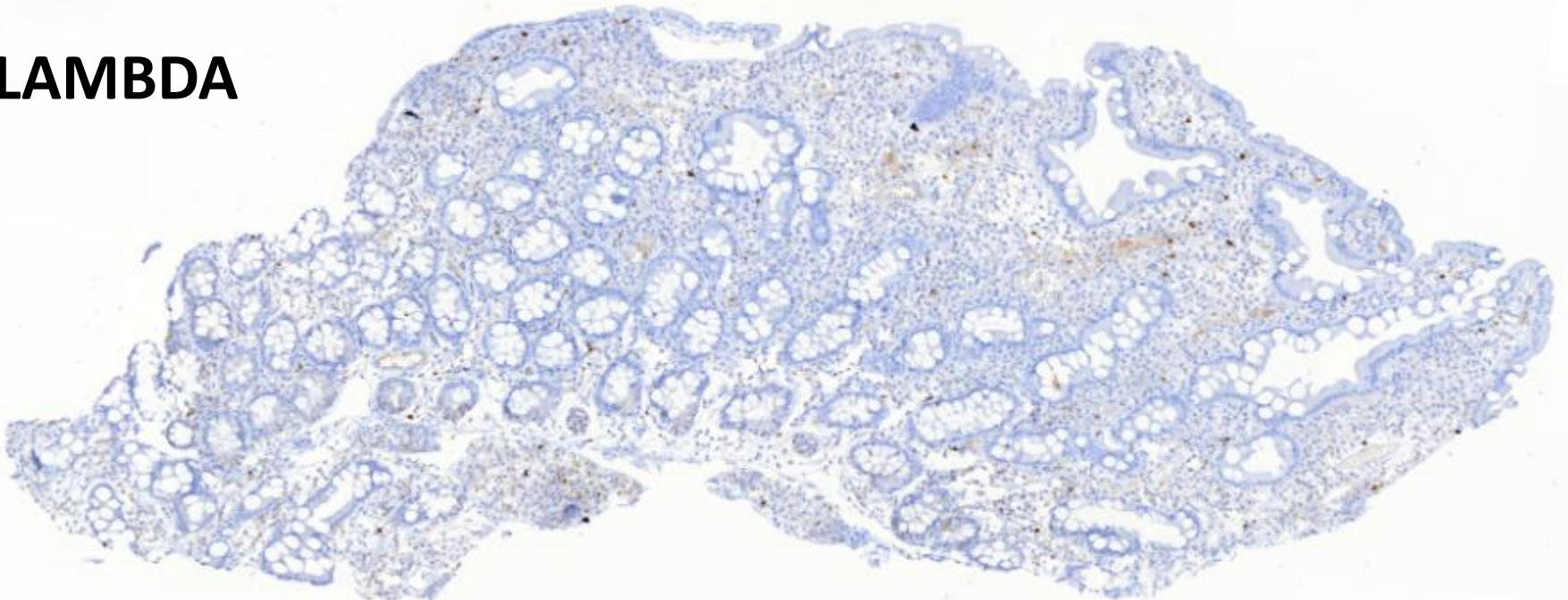
**Duodenum**



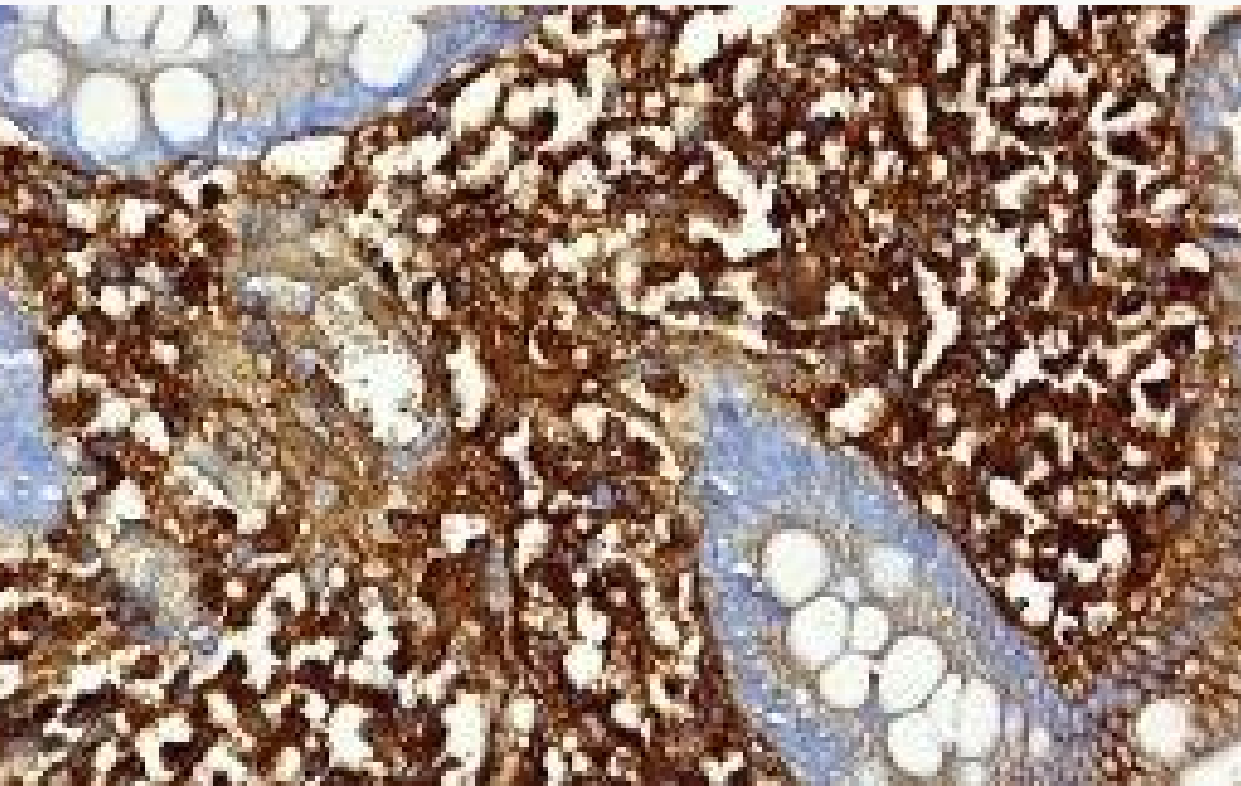
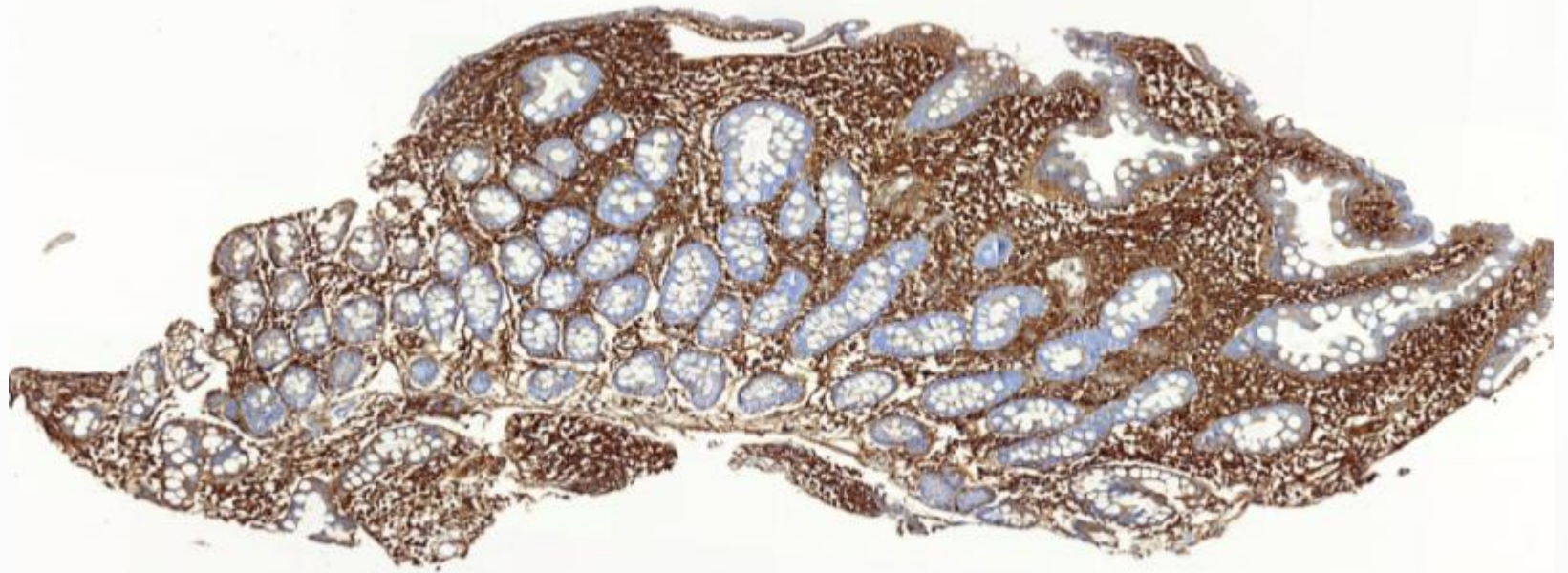
**KAPPA**



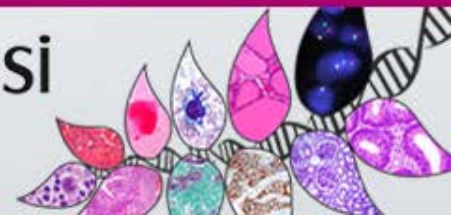**LAMBDA**



**IGA**

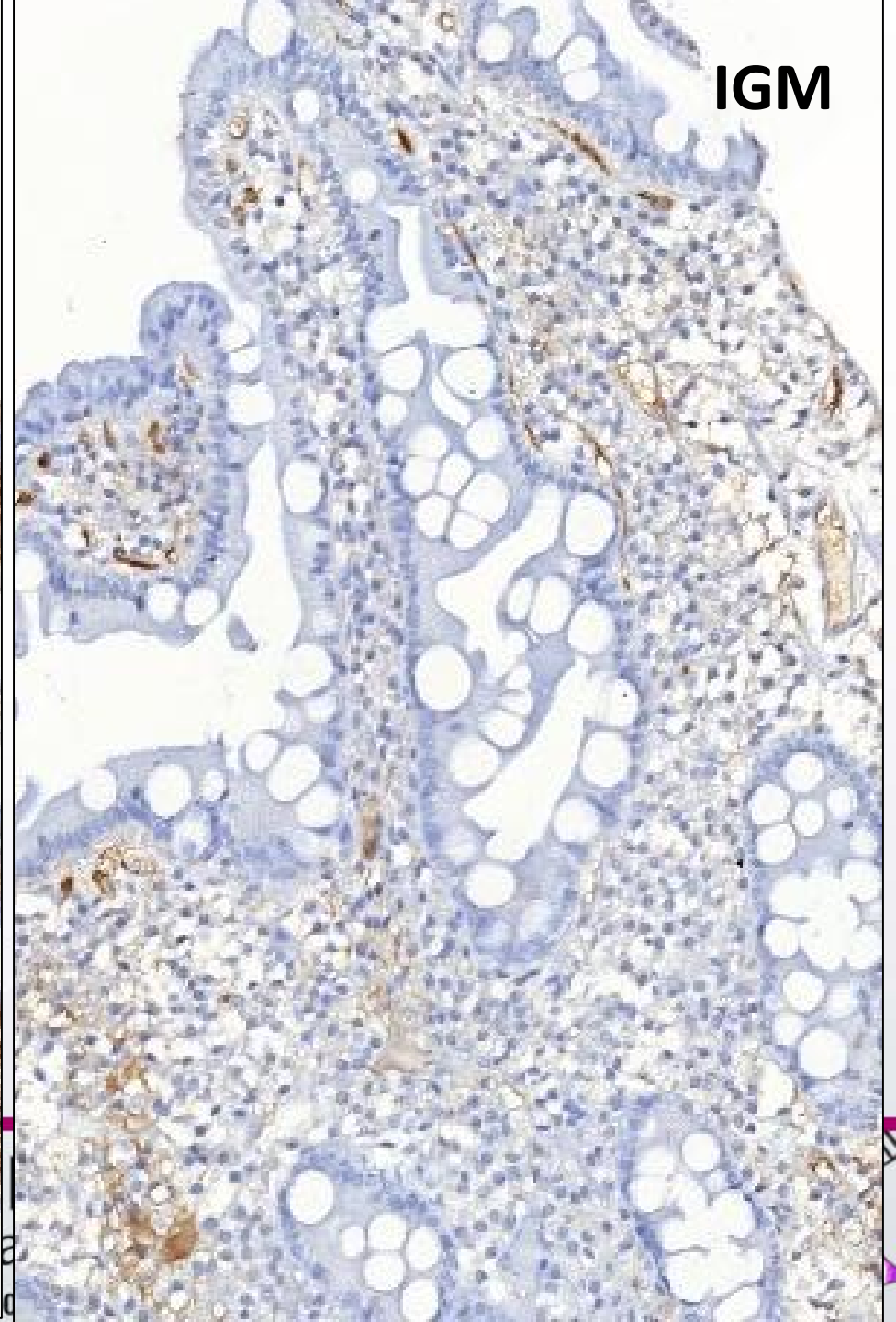
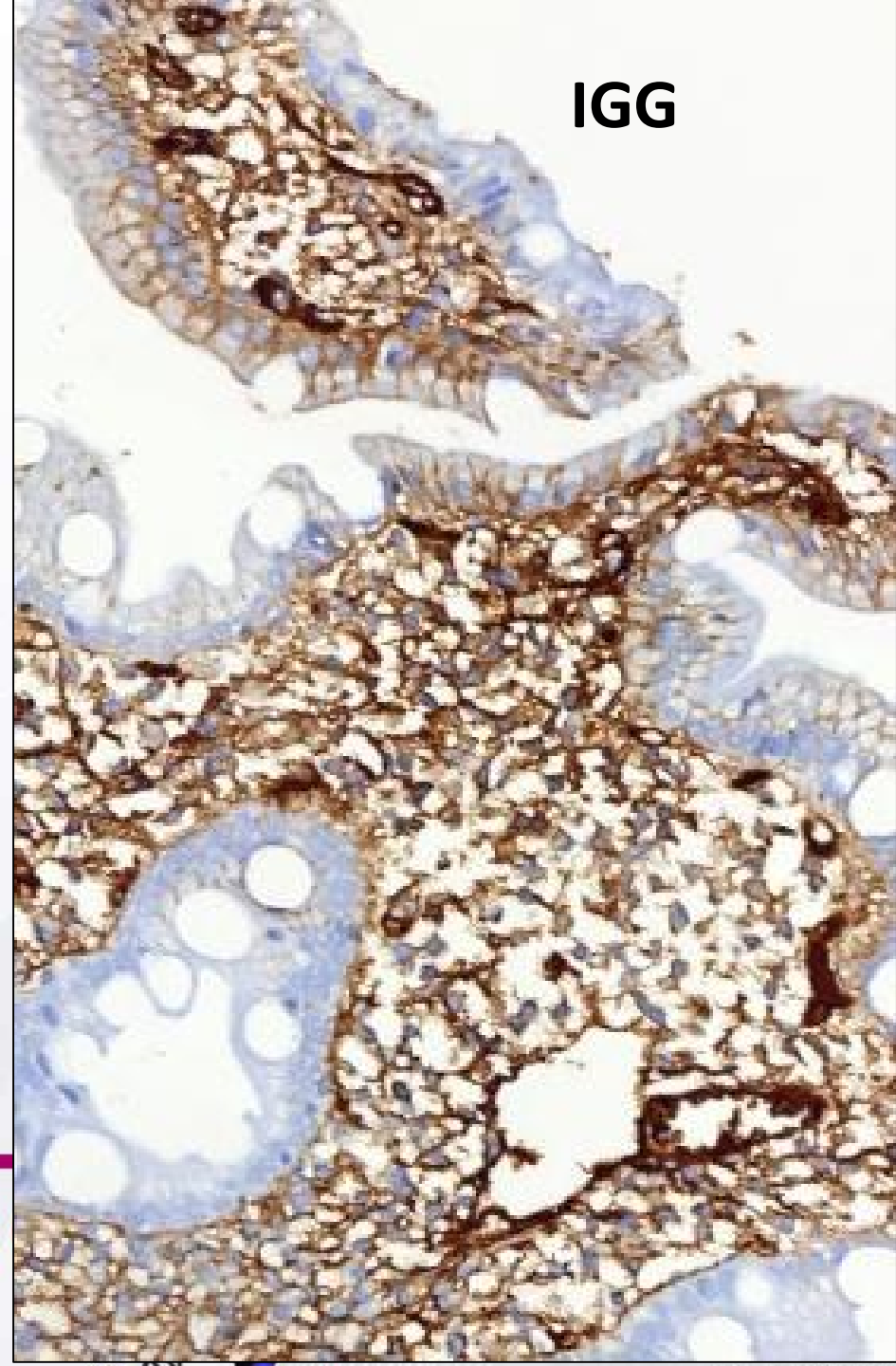


Kongresi  
gresi  
- BURSA



**IGG**

**IGM**



# DİFFÜZ İGA KAPPA MONOTİPİK PLAZMA HÜCRELERİ

TANI ?

**PLAZMA HÜCRELİ NEOPLAZİ ?**

!!!!!!!!!!!!

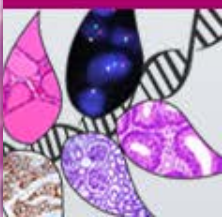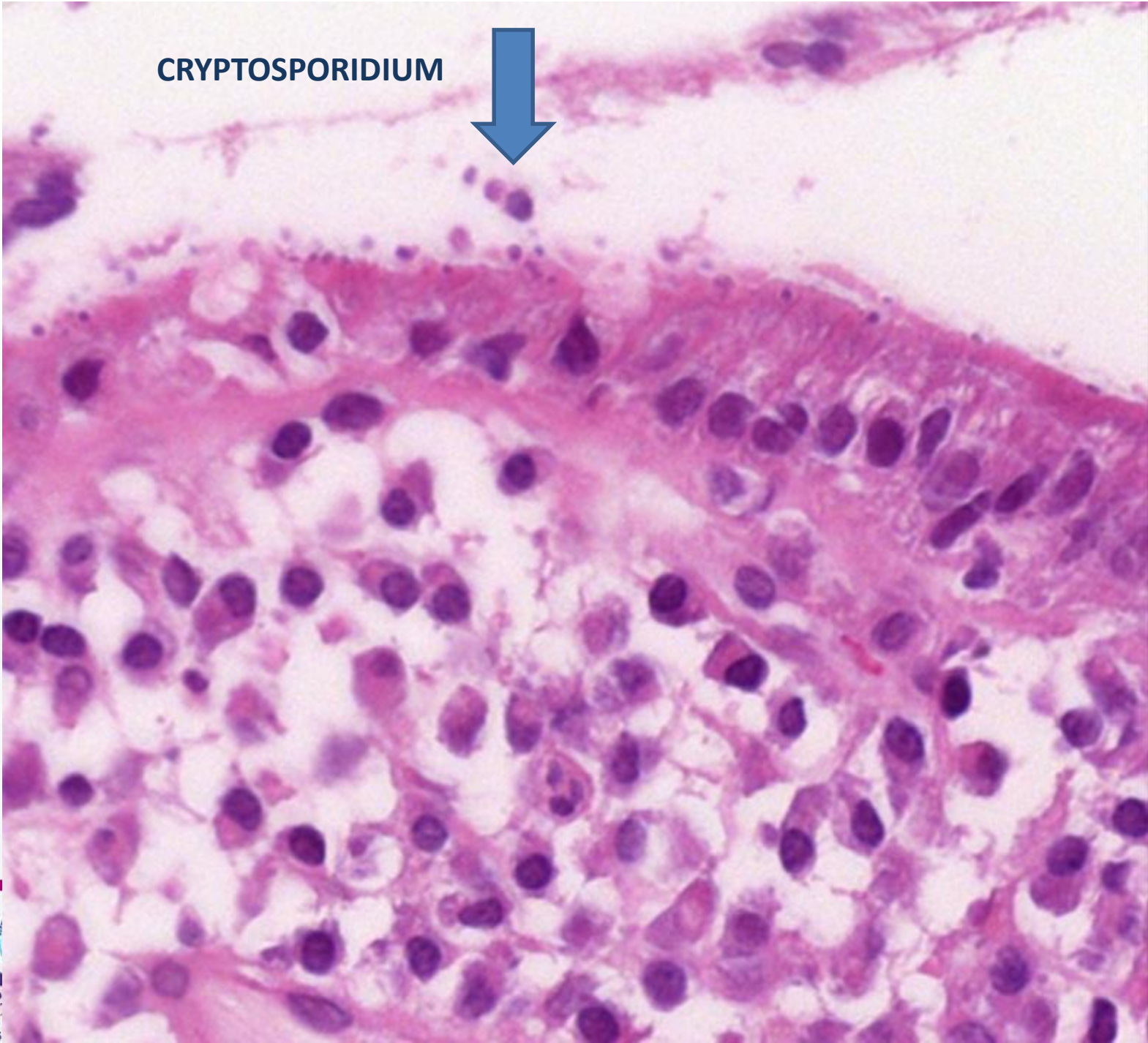


**25.** Ulusal Patoloji Kongresi  
**6.** Sitopatoloji Kongresi

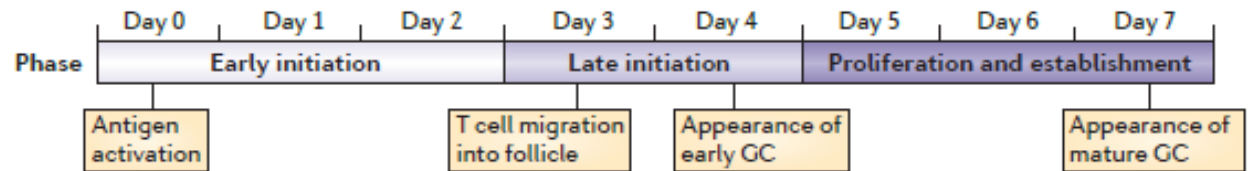
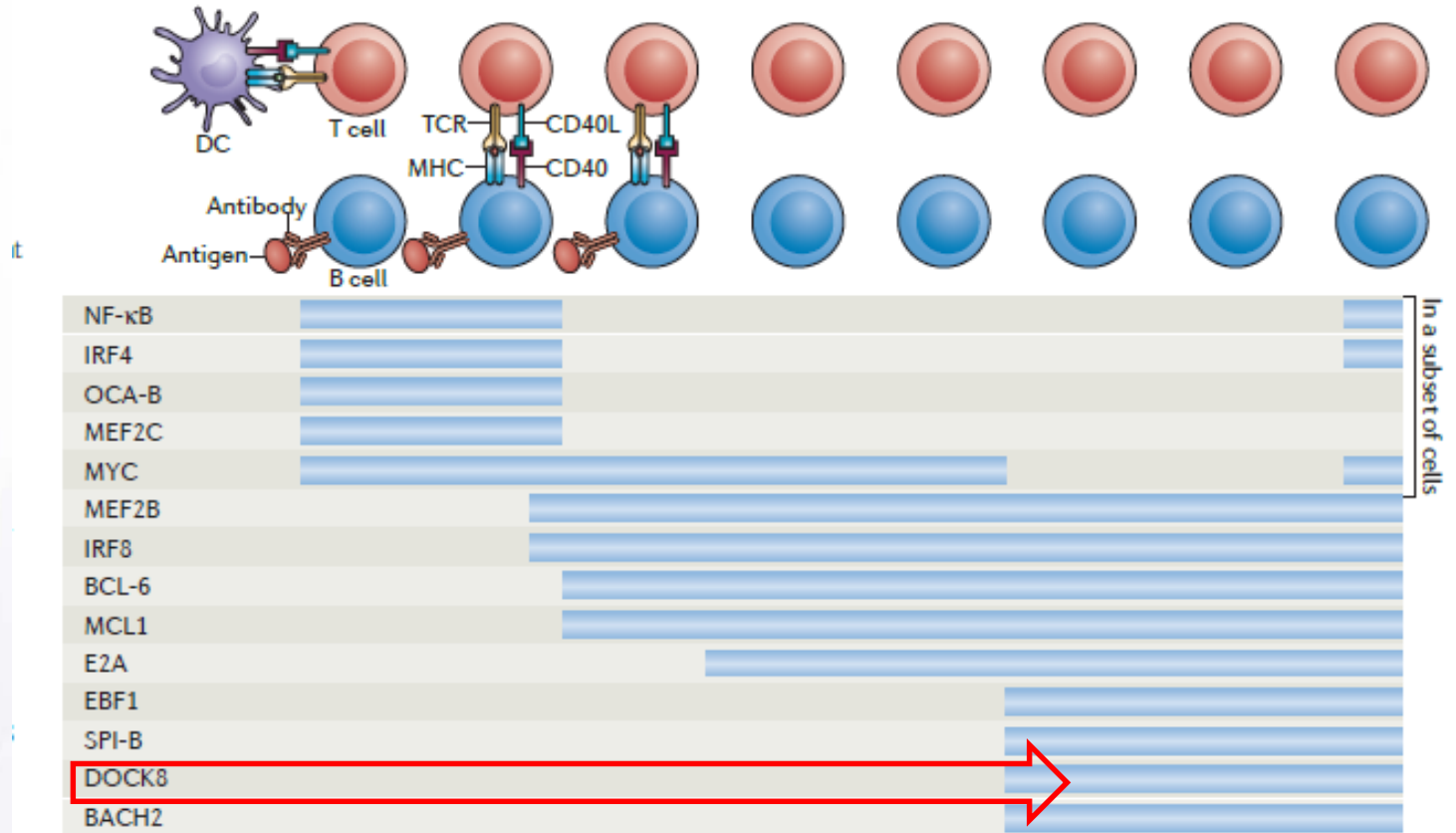
14 - 17 Ekim 2015 / Merinos AKKM - BURSA



**CRYPTOSPORIDIUM**

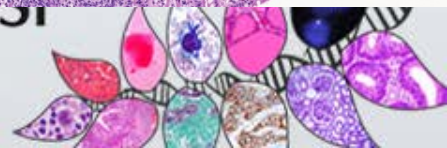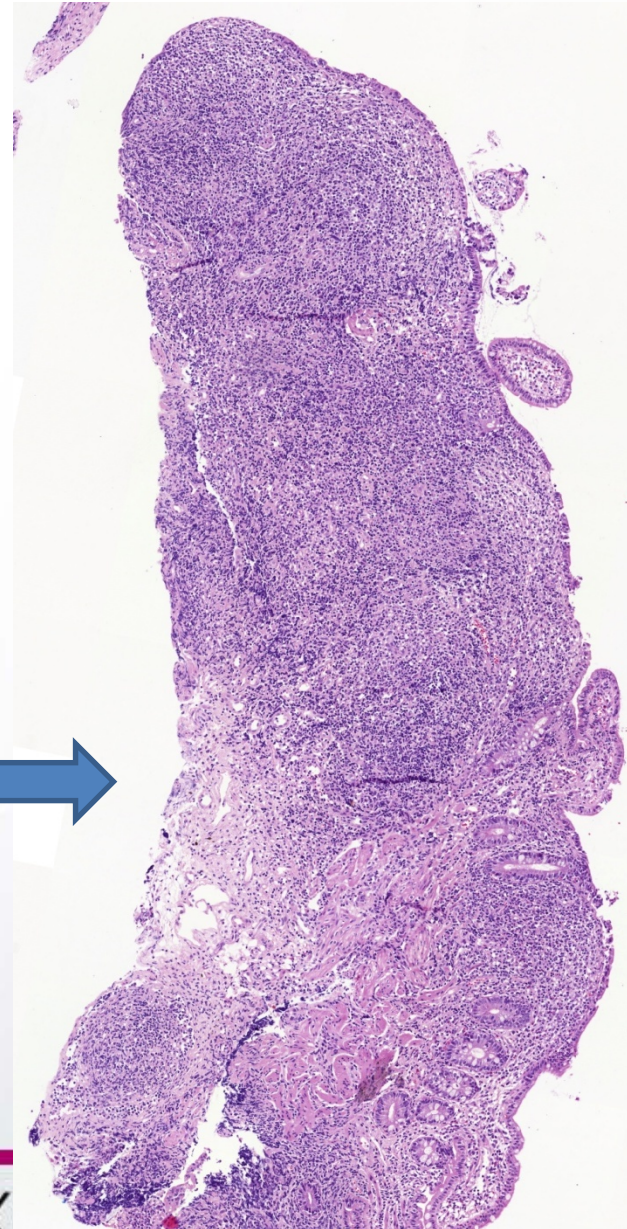
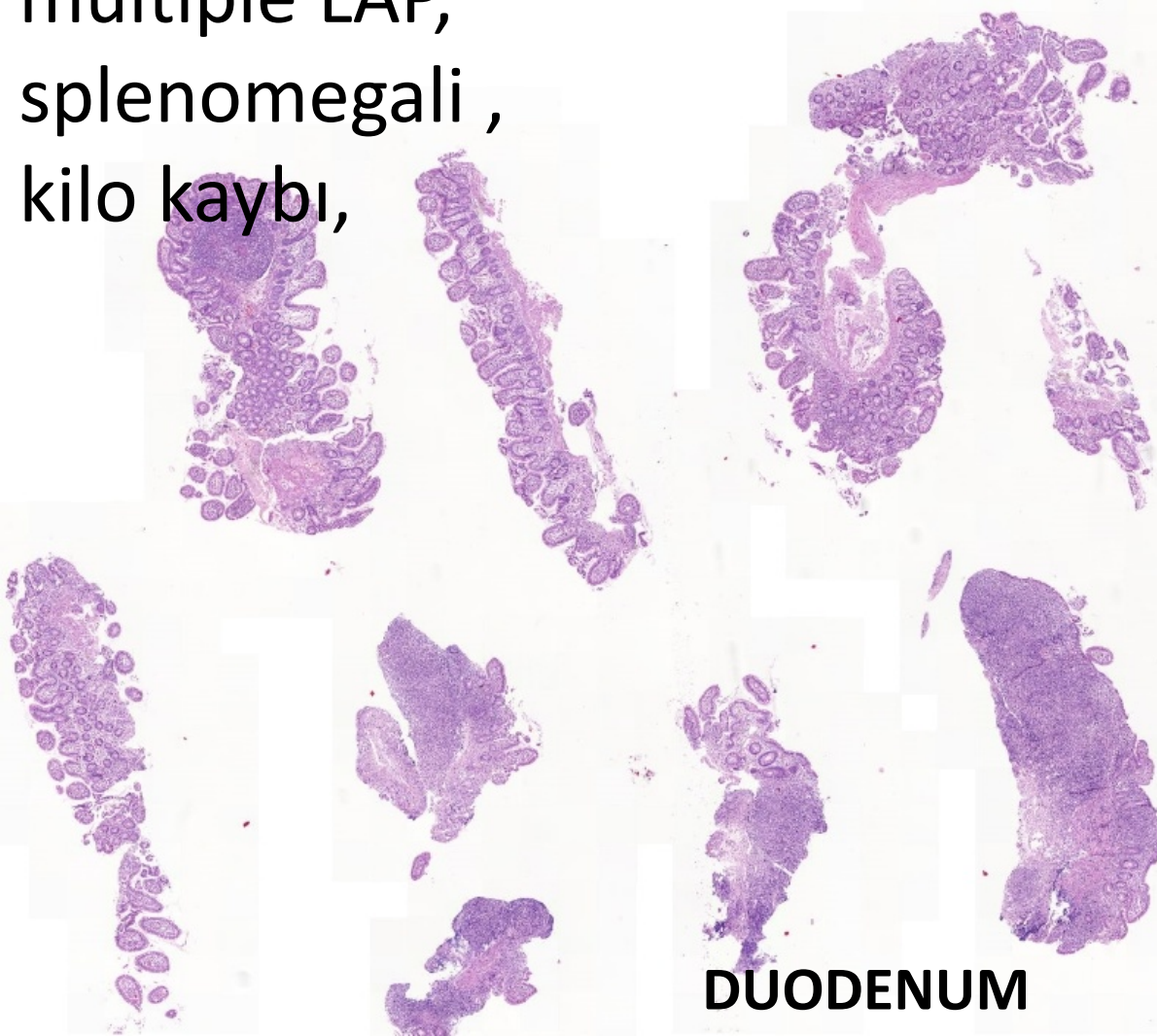


# KONGENİTAL İMMUN YETMEZLİK DOCK 8 EKSİKLİĞİ ENFEKSİYONA REAKTİF MONOTİPİK / MONOKLONAL PLAZMA HÜCRE YAPIMI



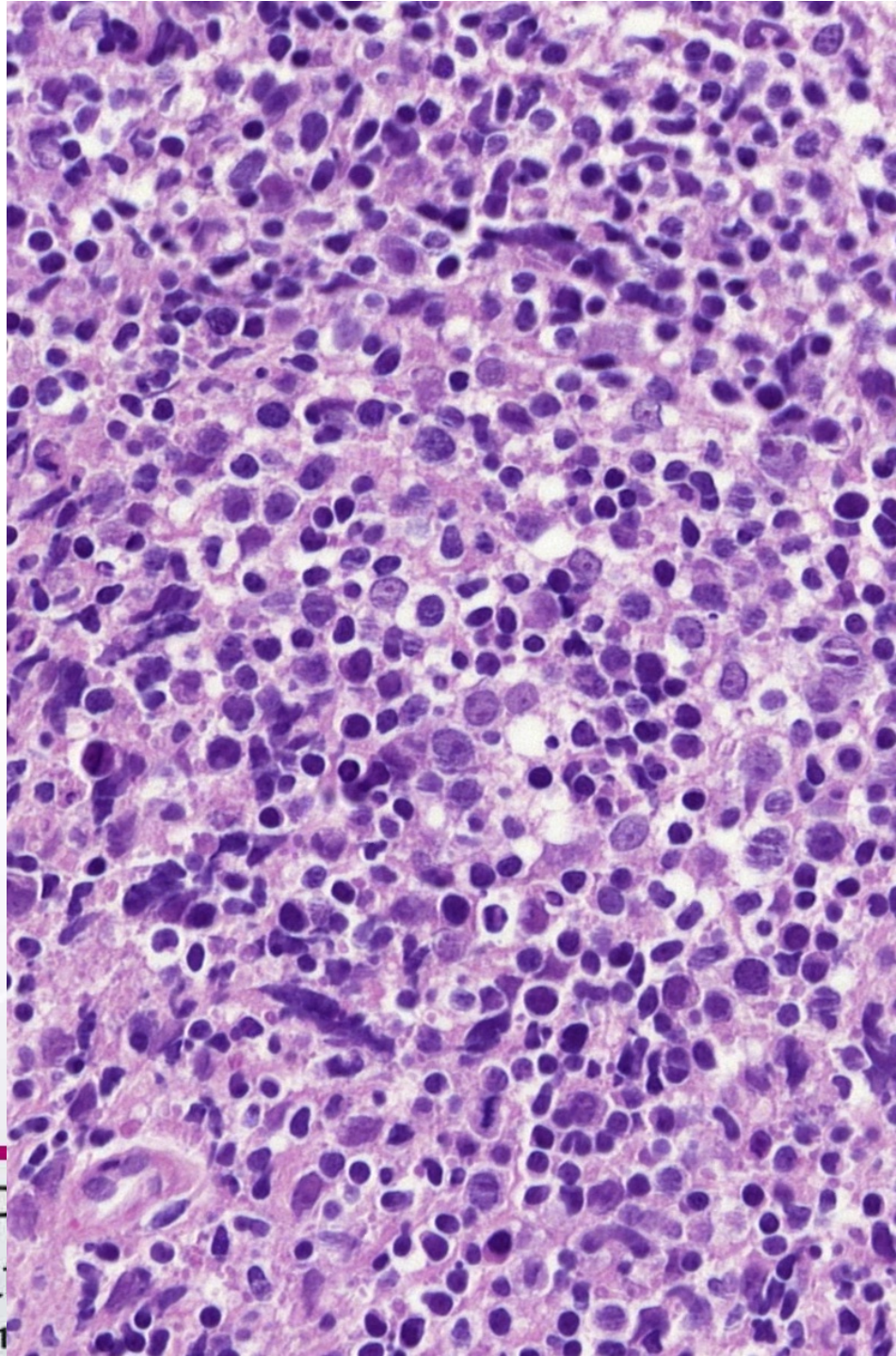
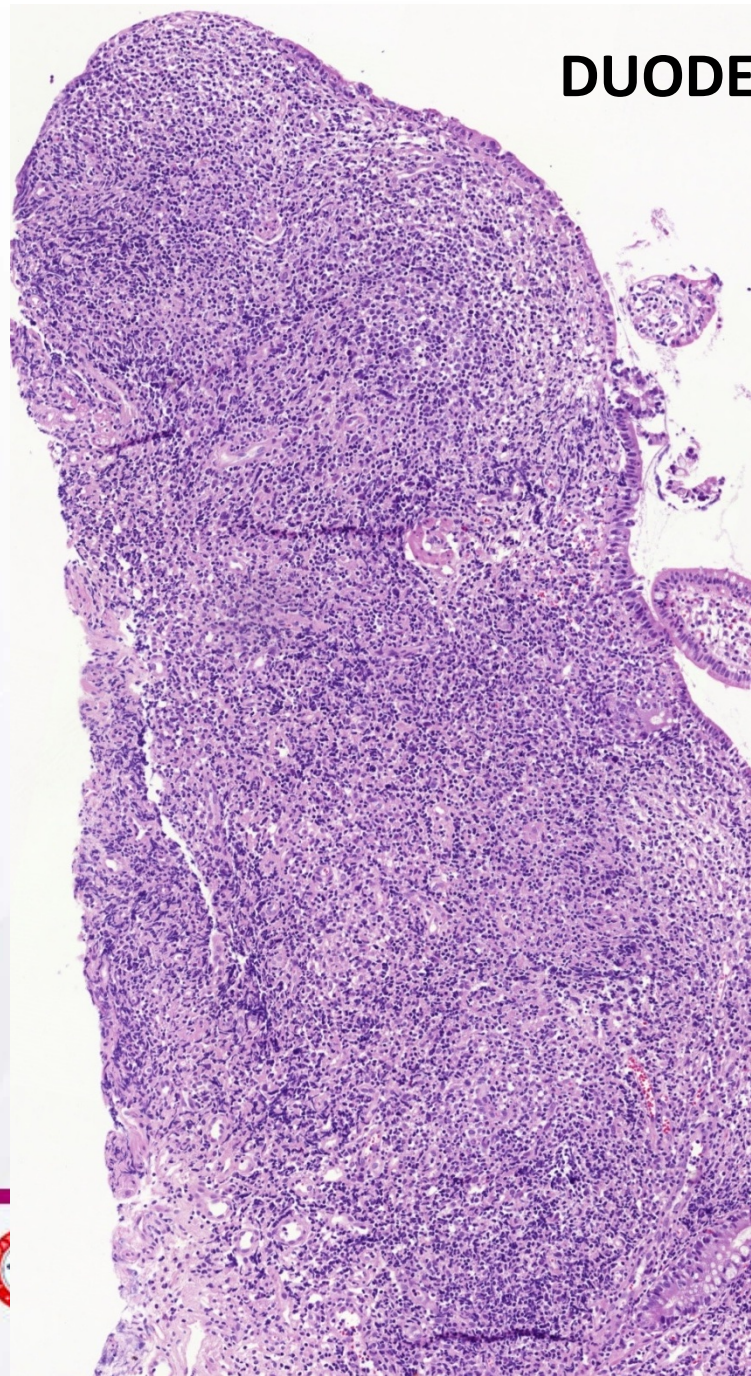
50 /E diyare atakları,  
ateş,  
gece terlemesi,  
multiple LAP,  
splenomegali ,  
kilo kaybı,

**HASTA**





# DUODENUM



usal F  
a, Sitopa

14 - 17 Ekim 201

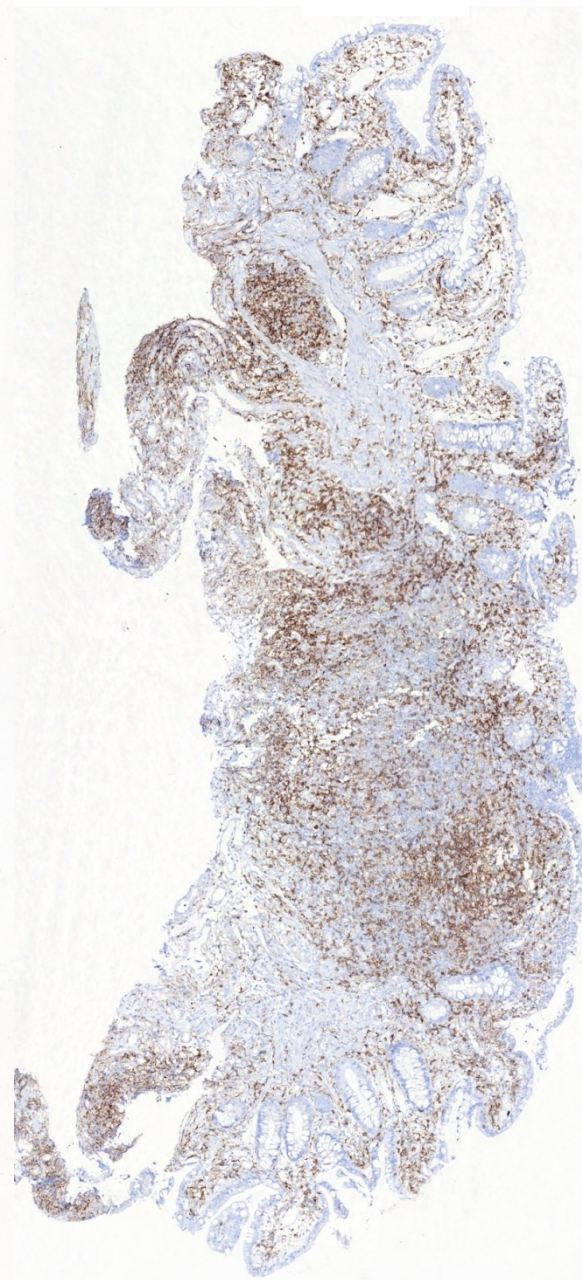**CD3**

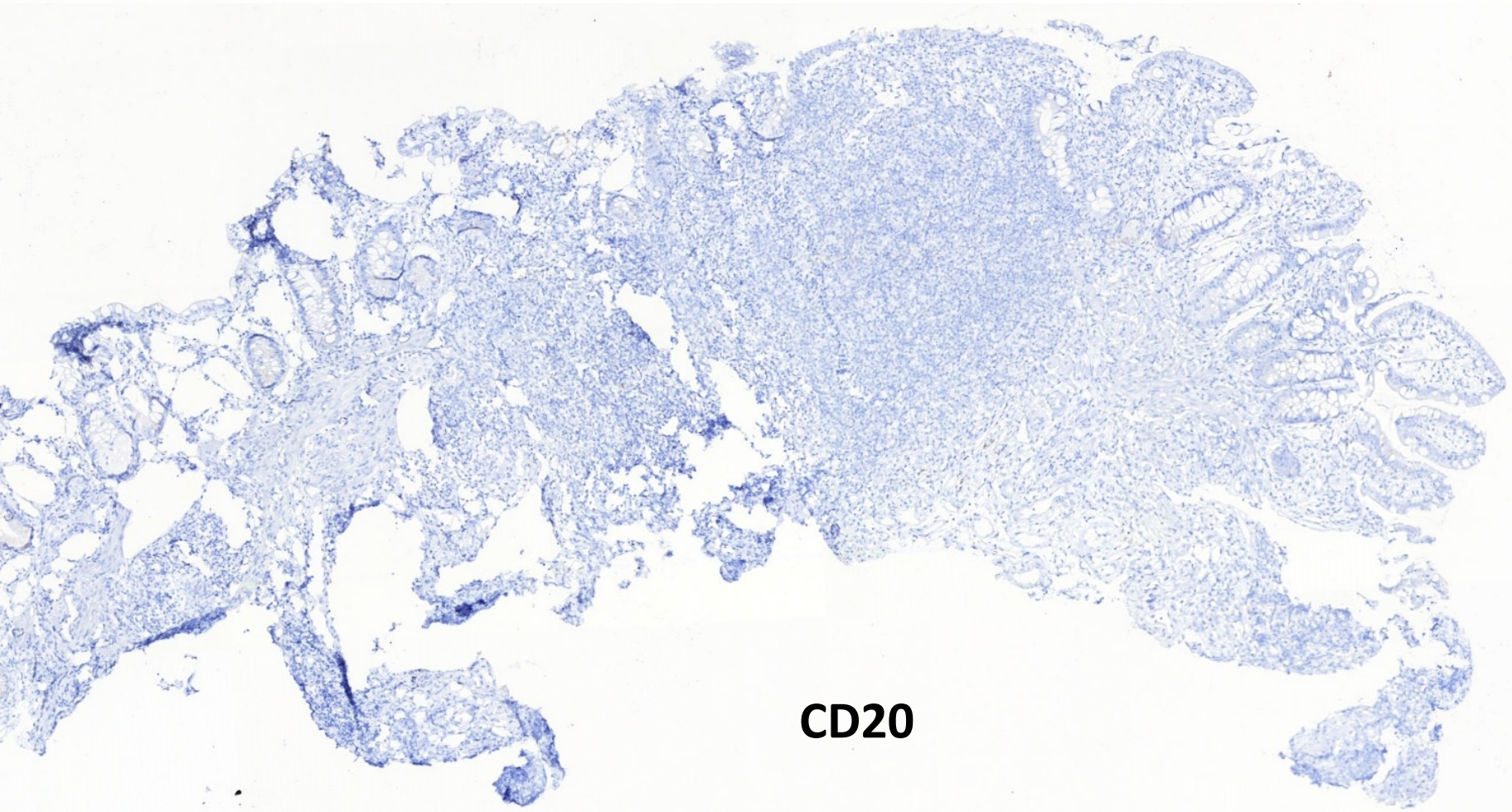


**CD8**



**CD4**





**CD20**

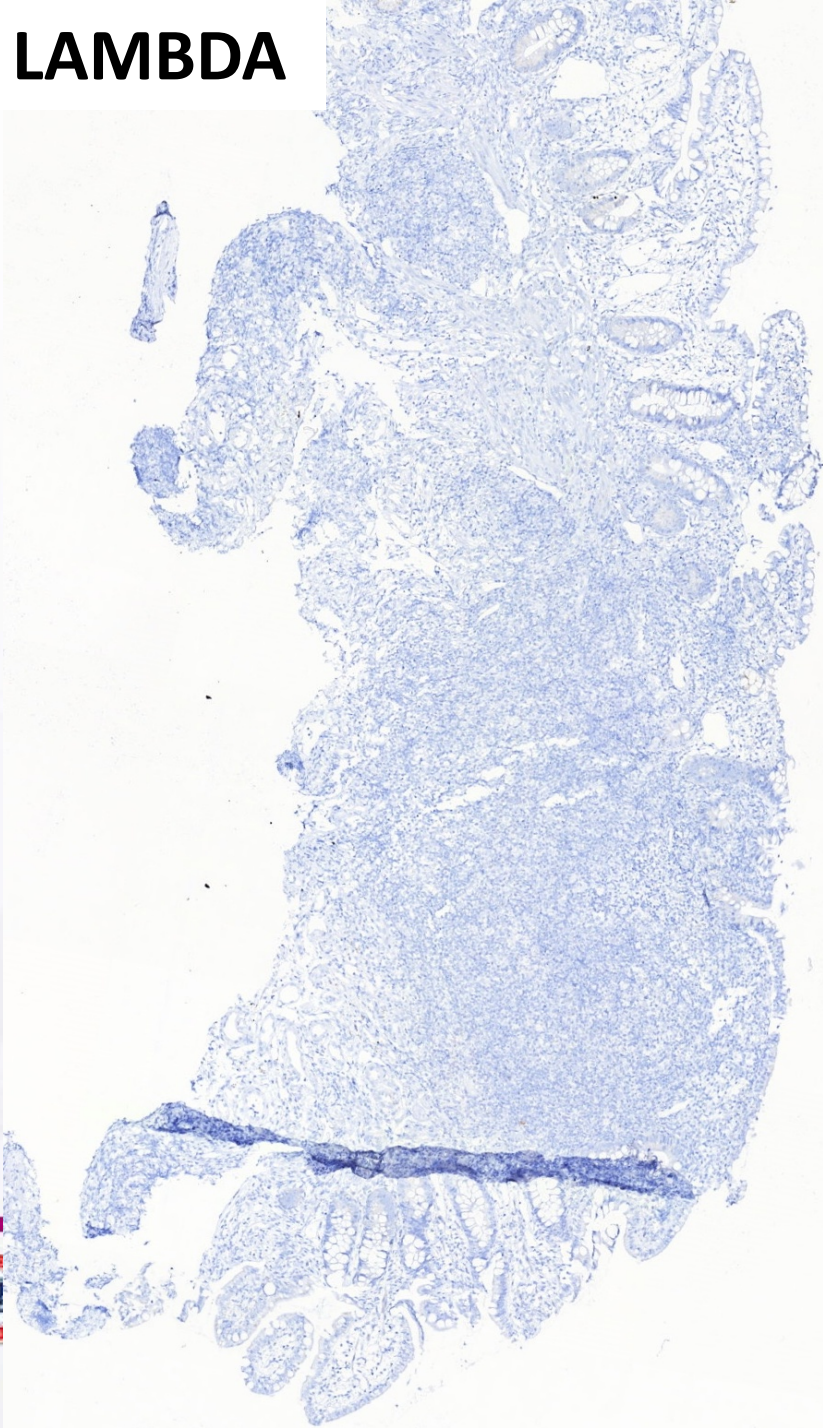


**25** Ulusal Patoloji Kongresi  
**6.** Sitopatoloji Kongresi

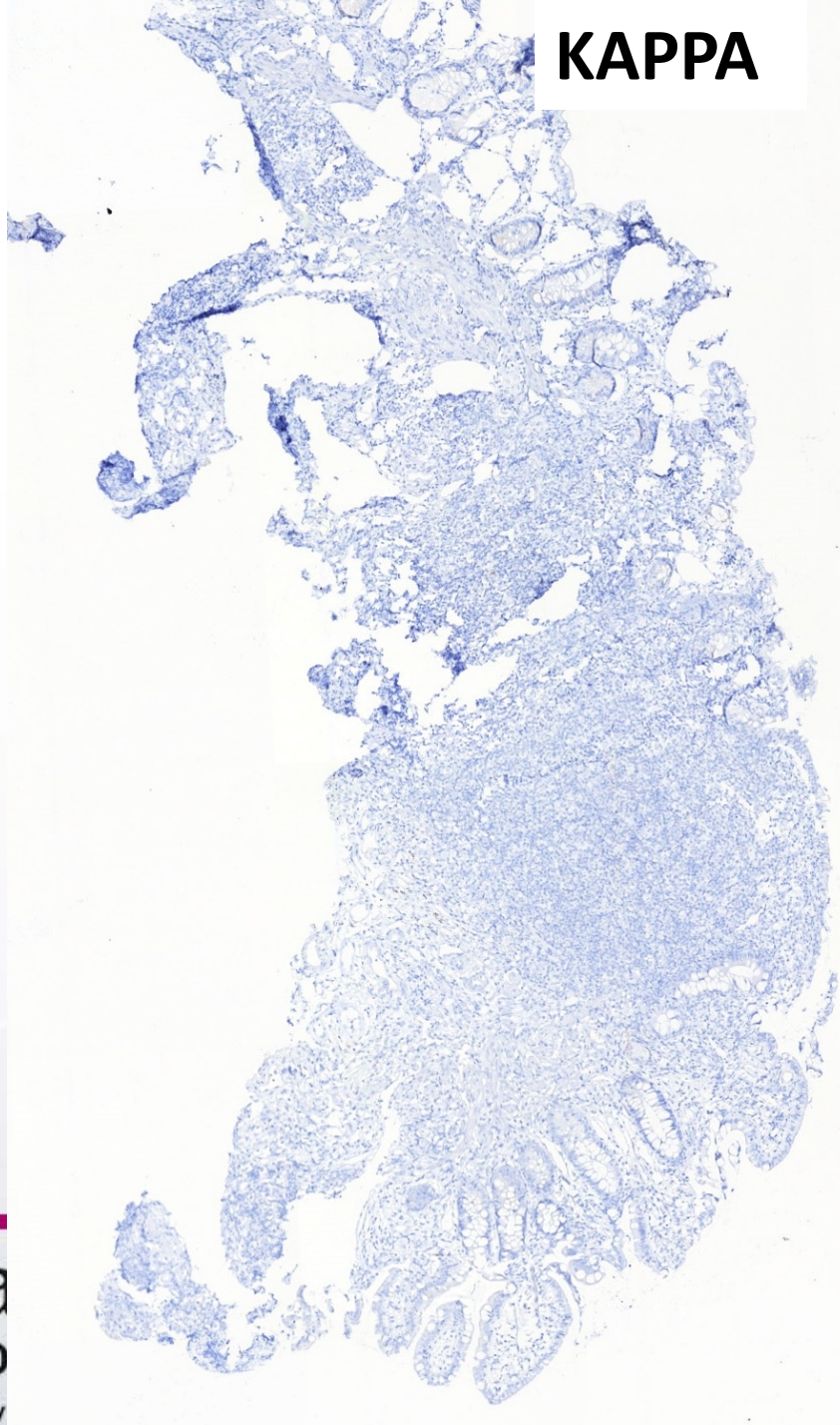
14 - 17 Ekim 2015 / Merinos AKKM - BURSA

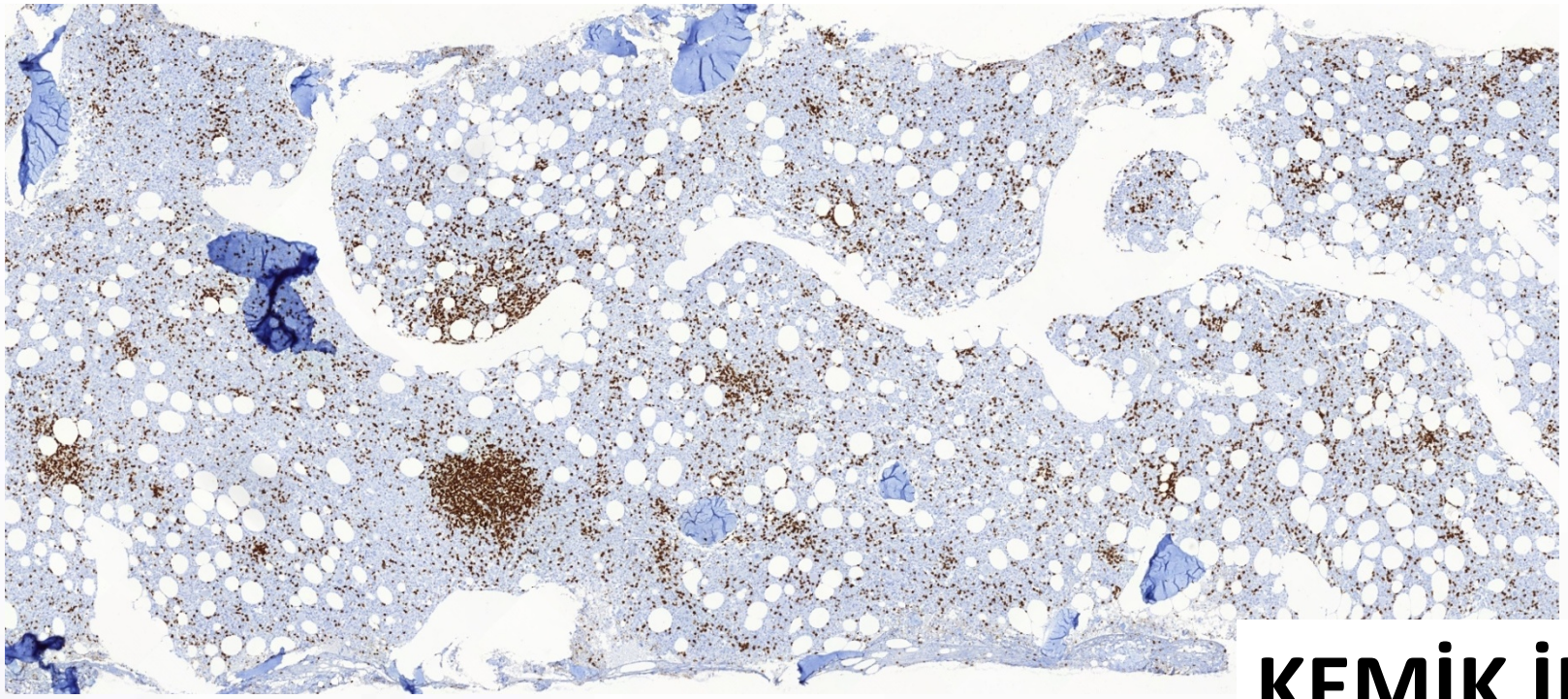


**LAMBDA**



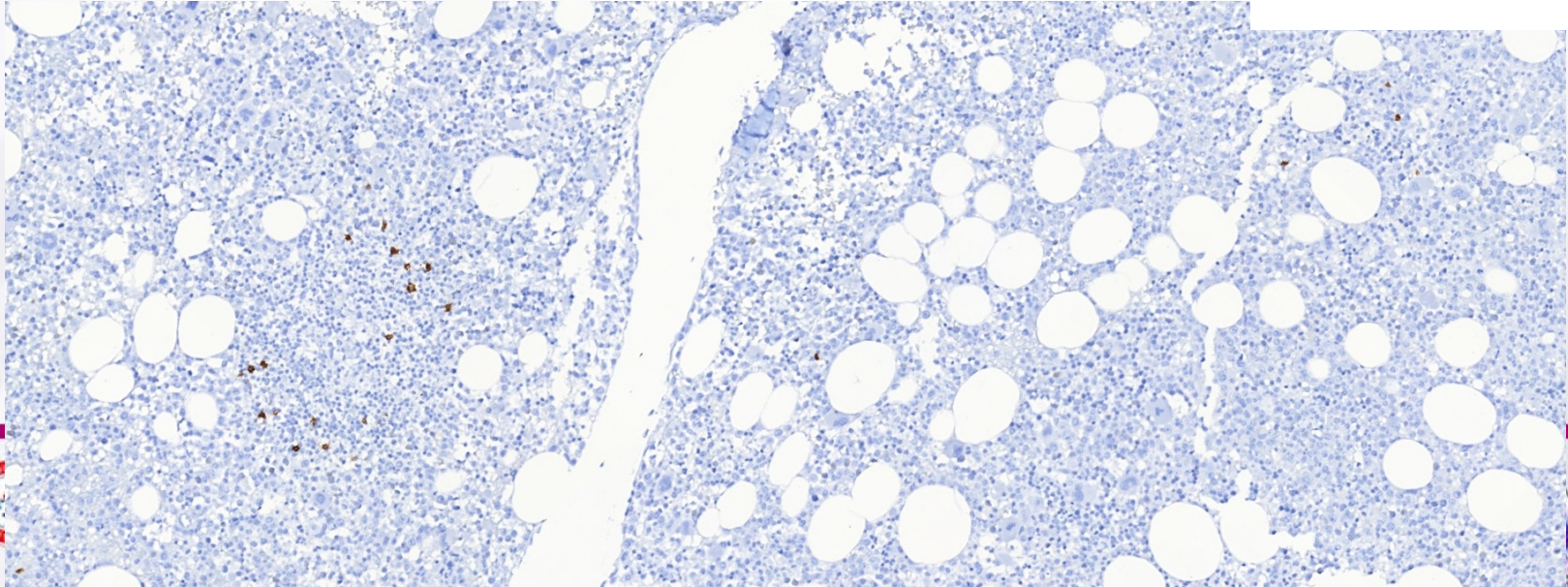
**KAPPA**



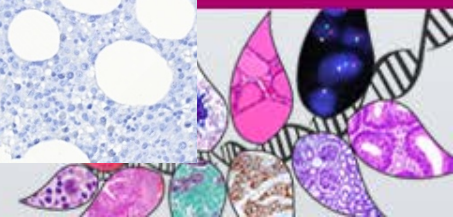


**CD3**

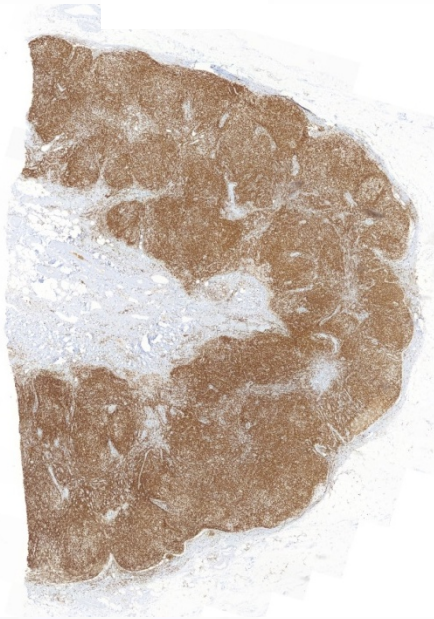
**KEMİK İLİĞİ**



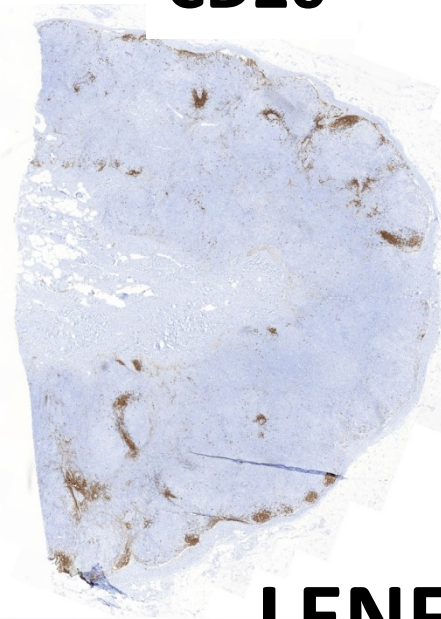
**CD20**



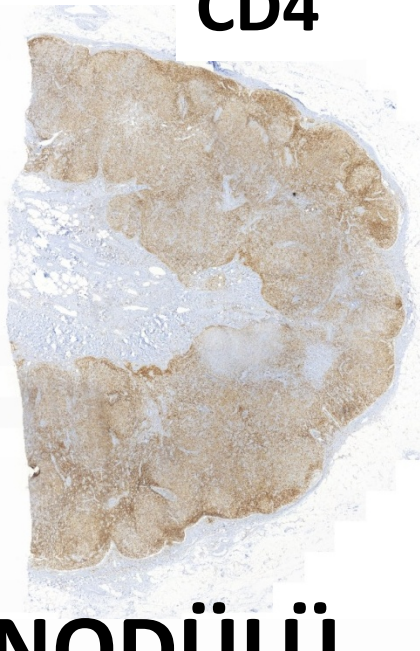
**CD3**



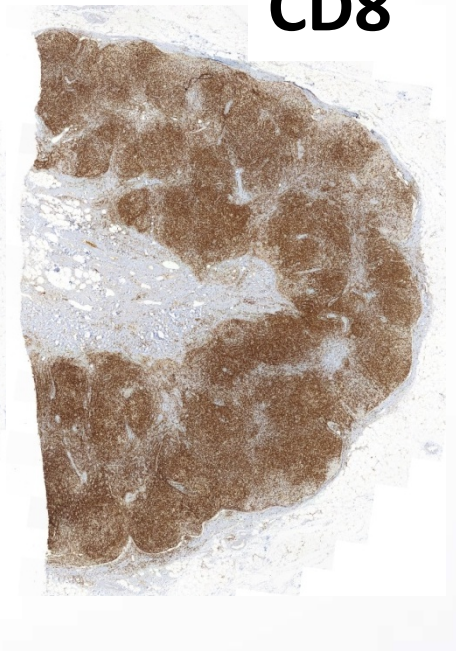
**CD20**



**CD4**

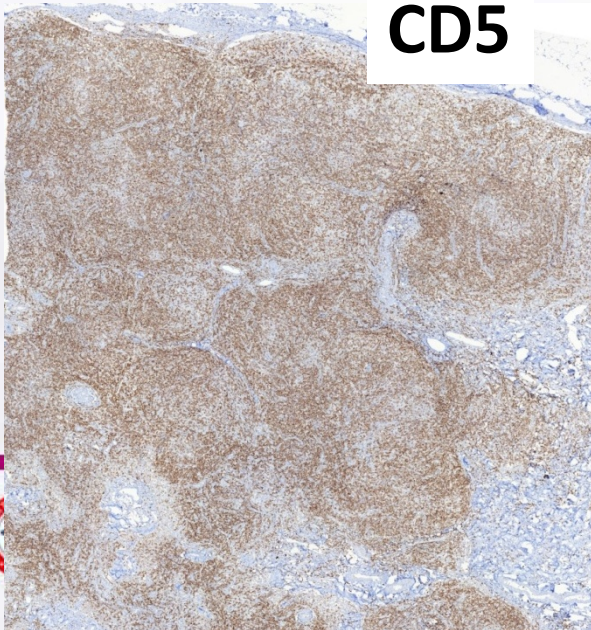


**CD8**

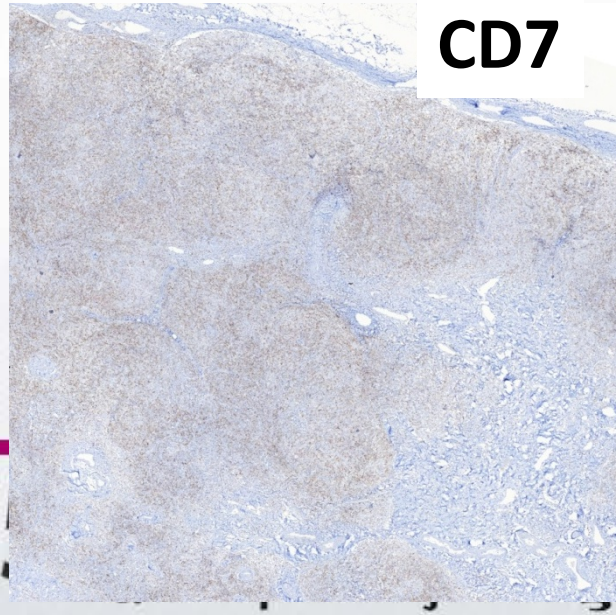


## **LENF NODÜLÜ**

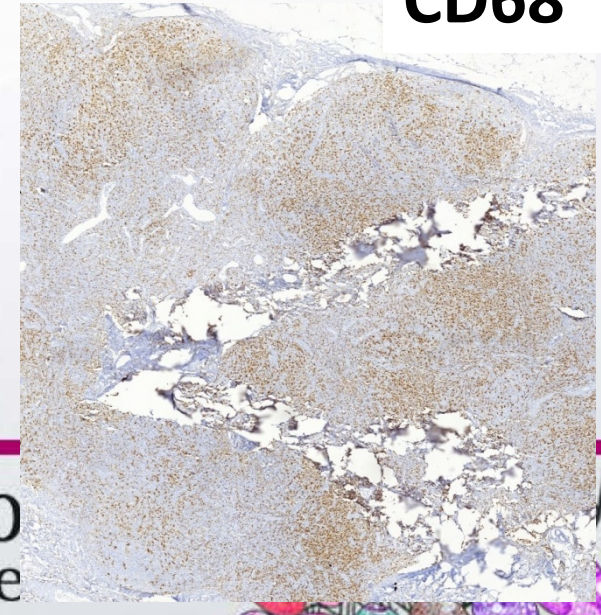
**CD5**



**CD7**



**CD68**



# LN

# Ki

## Pozitif:

TIA 1  
granzyme  
perforin

## Negatif:

CD56,  
CD57,  
PD1,  
CD30,  
EBER

## TCR KLONALİTE

TCR B & TCR G (BIOMED)  
POLİKLONAL

## CVID :

COMON VARIABLE  
IMMUNE DEFICIENCY

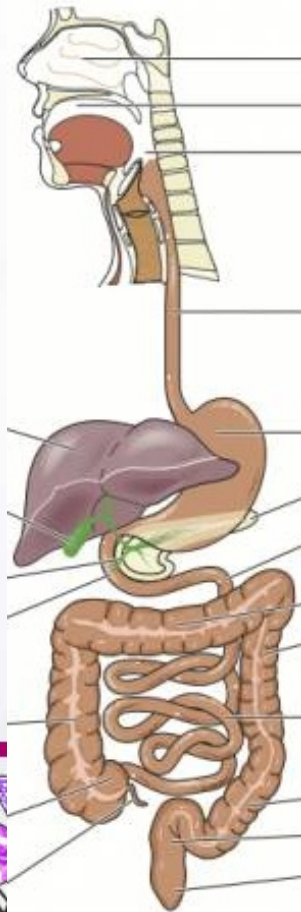
## TCR KLONALİTE

TCR B & TCR G(BIOMED)  
POLİKLONAL

TEDAVİ : Intravenöz Ig



# GASTROİNTESTİNAL KANAL LENFOMALARI



**Table 2** Primary GI non-Hodgkin lymphoma cases according to GI site and histologic type

	% by site	% of all sites
<b>Esophagus</b>		
BCL-NOS	100	0.7
<b>Stomach</b>		
DLBCL	38	10
EMZL	37	17
MCL	3	1
<b>Small intestine</b>		
DLBCL	38	10
FL	23	6
EATL	10	3
PTLD	10	3
BL	8	2
EMZL	5	1
<b>Colon</b>		
DLBCL	50	9
EMZL	23	4
FL	8	1
MCL	4	0.7
PTLD	4	0.7
<b>Multiple GI Sites</b>		
DLBCL	31	3
MCL	31	3
EMZL	8	0.7
BL	15	1
FL	8	0.7
PTLD	8	0.7

25. Ul  
6.





# GASTROINTESTINAL KANAL LENFOMALARI

**Table 1** Most frequent sites of occurrence of gastrointestinal lymphomas

Site	Oropharynx	Esophagus	Stomach	Small intestine	Large intestine	Rectum
DLBCL	+	+	+	+	+	+
PBL	++					+
MCL	+	+	+	++	++	+
FL				+ <sup>a</sup>		
ENKTL	++			+		
BL	+			+	+	
EATL	+	+	+	++	+	+
EMZL	+	+	++	+	+	+

Abbreviations: DLBCL, diffuse large B cell lymphoma; PBL, plasmablastic lymphoma; MCL, mantle cell lymphoma; FL, follicular lymphoma; ENKTL, extranodal nasal type NK/T cell lymphoma; BL, Burkitt lymphoma; EATL, enteropathy associated T-cell lymphoma; EMZL, extranodal B marginal zone lymphoma; +, found in this site; ++, classic GI site of this lymphoma type.

<sup>a</sup> Specific clinical entity “follicular lymphoma of small intestine”. Typical systemic follicular lymphoma may occur at all sites.

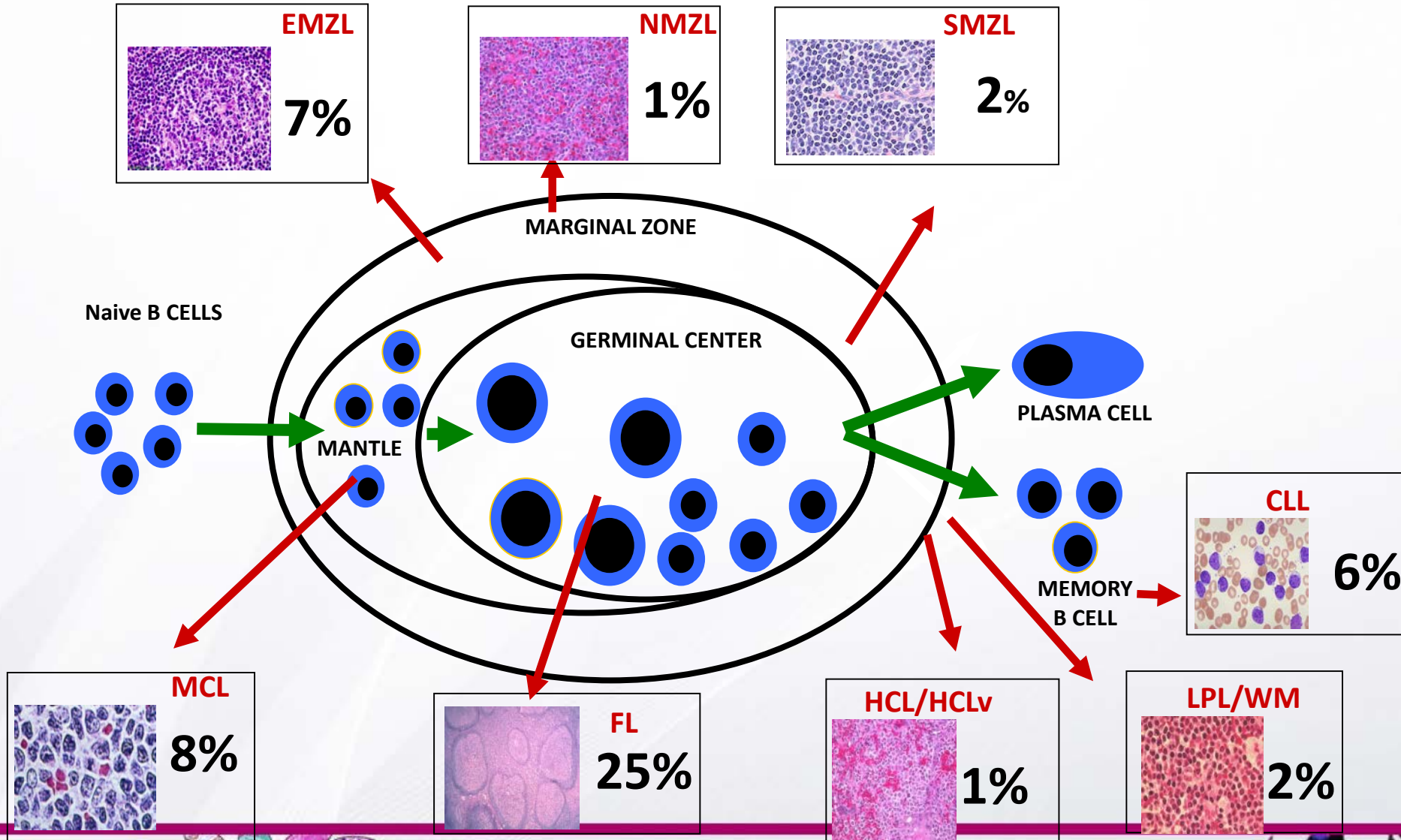


**25** Ulusal Patoloji Kongresi  
**6** Sitopatoloji Kongresi

14 - 17 Ekim 2015 / Merinos AKKM - BURSA

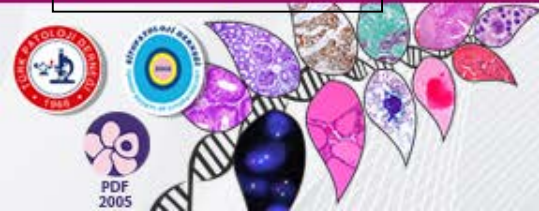

# Küçük B Hücreli Lenfomalar Görülme Sıklığı

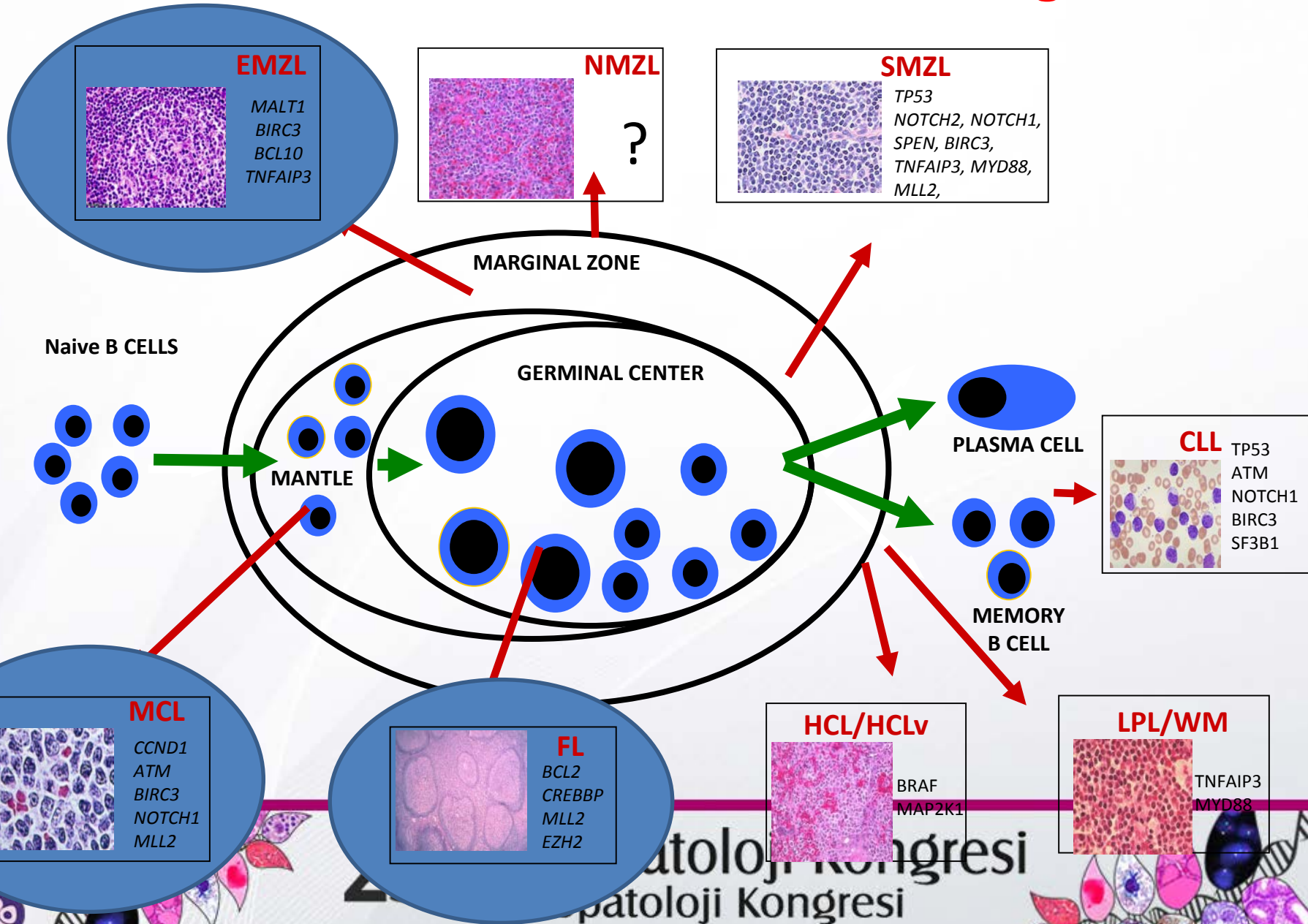


**25.** Ulusal Patoloji Kongresi  
6. Sitopatoloji Kongresi

14 - 17 Ekim 2015 / Merinos AKKM - BURSA · Fitzgibbon 2014



# Küçük B Hücreli Lenfomalar Moleküler Değişiklikler



# MALT LENFOMA

## Ekstrandal NHL

%24-29 (USA, Kanada, Tayvan)

% 36-44 İsrail, Danimarka,  
Hollanda)

%48 **İtalya**

**1/3 GASTROİNTESTİNAL**



**2/3 GIS LENFOMA  
TÜM EKSTRANODAL  
LENFOMALARIN  
%30-45  
MİDE YERLEŞİMLİ**

**TÜM MİDE  
TÜMÖRLERİNİN  
%2-8**

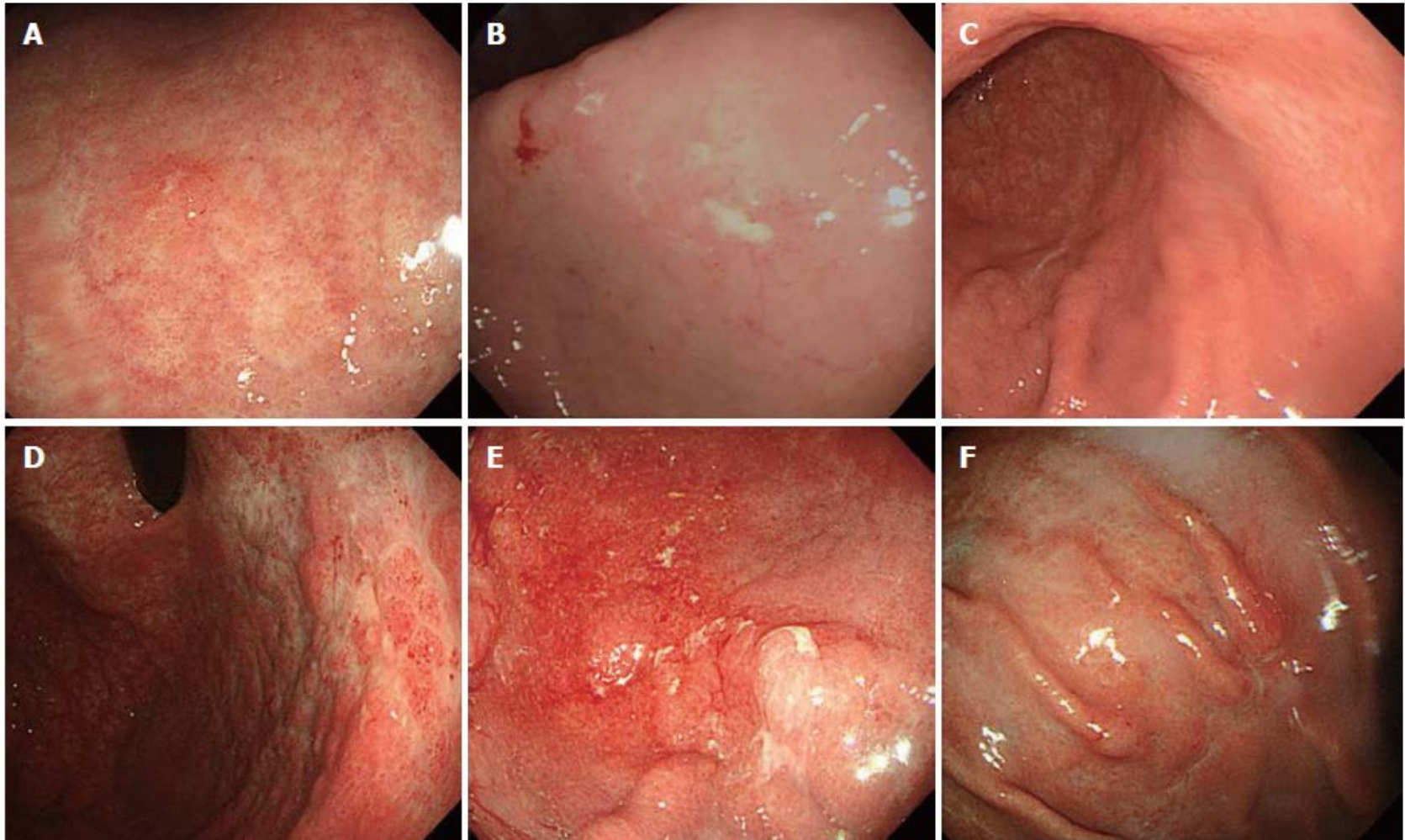


**25.** Ulusal Patoloji Kongresi  
**6.** Sitopatoloji Kongresi

14 - 17 Ekim 2015 / Merinos AKKM - BURSA

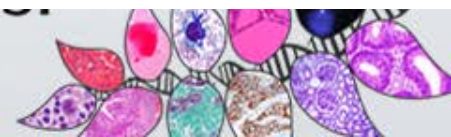


# GASTRIK MALT LENFOMA

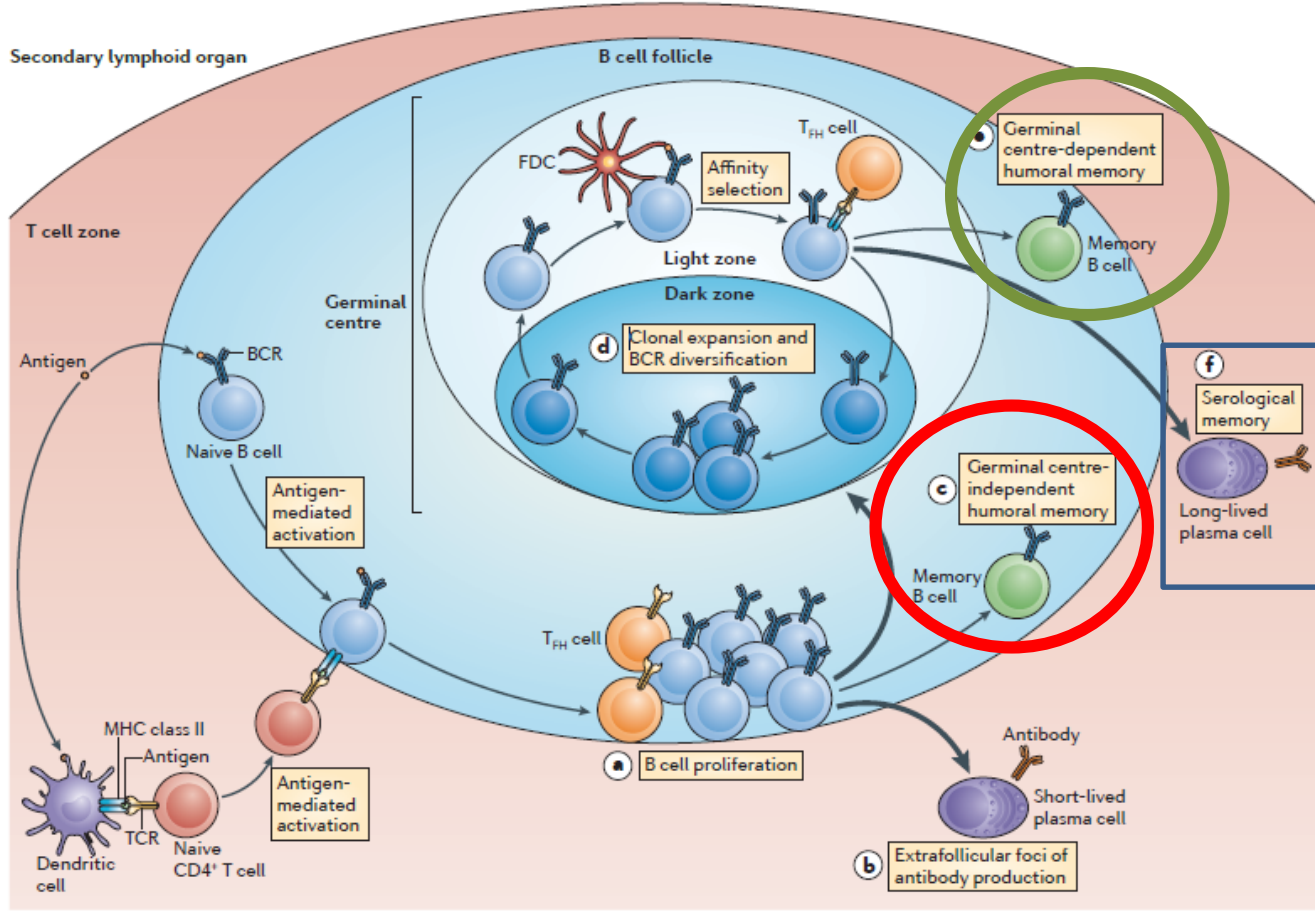


**25.** Ulusal Patoloji *Chun World J Gastroenterol 2014*  
**6.** Sitopatoloji Kongresi

14 - 17 Ekim 2015 / Merinos AKKM - BURSA



# MARGİNAL ZON B HÜCRELERİ



ANTİJENE KARŞI  
REAKTİF YANIT

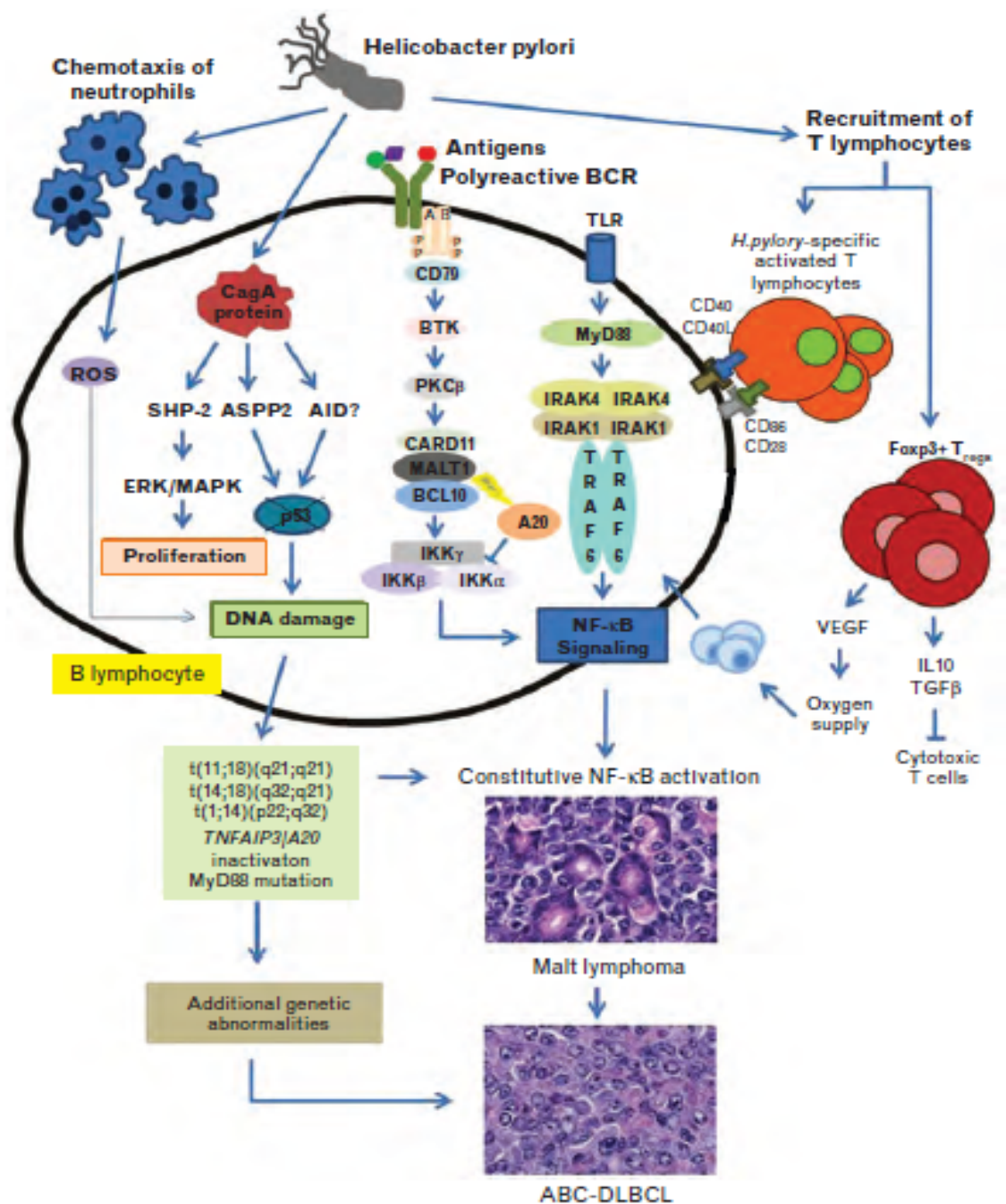
ANTİJENLE TETİKLENEN  
NEOPLASTİK  
PROLİFERASYON



25. Ulusal Patoloji Kongresi  
6. Sitopatoloji Kongresi

14 - 17 Ekim 2015 / Merinos AKKM - BURSA





**KRONİK İNFLAMASYON**  
  
**NEOPLAZİ**

- %22** t(11;18)(q21;q21)
- %3** t(1;14)(p22;q32)
- %1** t(14;18)(q32;q21)

**Table 1.** Frequencies of the principal genetic abnormalities in the different MALT lymphomas according to location, and in comparison to ABC-DLBCL and GCB-DLBCL

	MALT lymphomas									ABC-DLBCL	GCB-DLBCL
	Gastric	Lung	Ocular adnexa	Salivary gland	Skin	Intestine	Liver	Thyroid	All MALTs		
t(11;18)(q21;q21)	25%	40%	6%	2%	8%	12%	0%	0%	25-30%	0%	0%
t(14;18)(q32;q21)	1%	8%	7%	10%	14%	0%	50%	0%	10-15%	<1%	0%
t(1;10)(p21;q32)	4%	8%	0%	2%	0%	10%	0%	0%	2%	0%	0%
t(3;14)(p13;q32)	5%	0%	20%	0%	10%	0%	0%	50%	5%	5%	0%
A20 inactivation <sup>a</sup>	7-13%	17%	28%	NA	NA	NA	NA	NA	20-25%	30-35%	8%
MyD88 mutation <sup>b</sup>	9%	NA	6%	NA	NA	NA	NA	NA	6-9%	35%	10%
Gain of 3q	NA	NA	NA	NA	NA	NA	NA	NA	30%	25%	2%
Gain of 18q	NA	NA	NA	NA	NA	NA	NA	NA	21%	38%	10%





**KRONİK İNFLAMASYON**



**NEOPLAZİ**

**TANI**



**25.** Ulusal Patoloji Kongresi  
**6.** Sitopatoloji Kongresi

14 - 17 Ekim 2015 / Merinos AKKM - BURSA



# İLERİ TESTLERE GEREKSİNİM DUYULAN DURUMLAR

- BÜYÜK LENFOİD HÜCRELERLE YOĞUN İNFİLTRASYON
- FOLİKÜL YAPISINDA BOZULMA MONOTON HÜCRELER
- MANTLE ZON ALANLARINDA KALINLAŞMA GENİŞLEME
- POLİPOİD YAPILAR OLUŞTURAN LENFOİD HÜCRELER
- BEZLERDE YIKIM İNFİLTRASYON
- BELİRGİN ATİPİK HÜCRLERDEN OLUŞAN İNFİLTRASYON



**25.** Ulusal Patoloji Kongresi  
**6.** Sitopatoloji Kongresi

14 - 17 Ekim 2015 / Merinos AKKM - BURSA

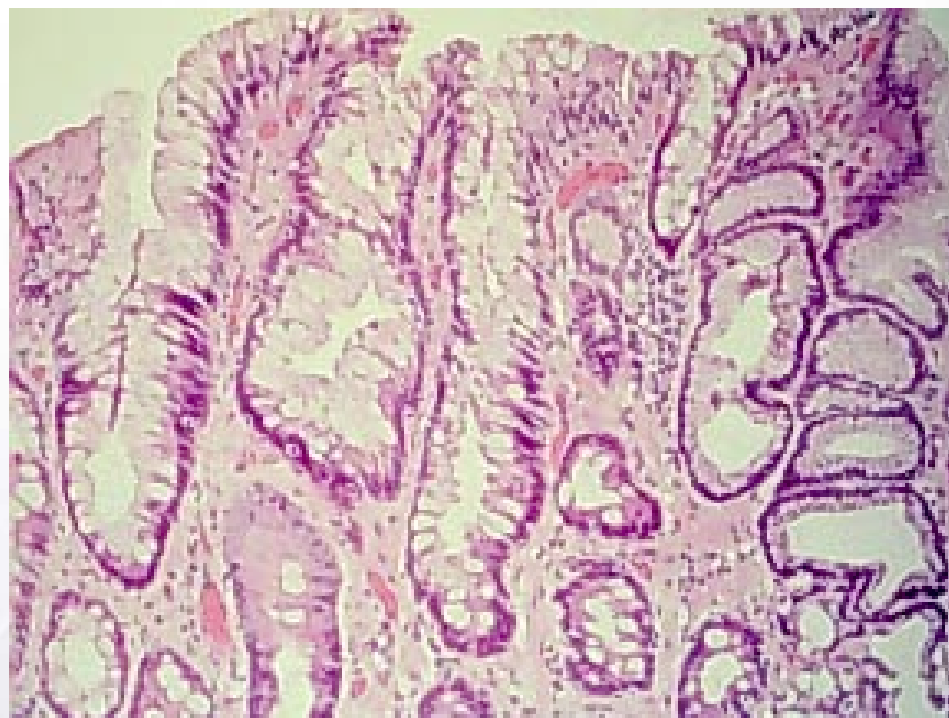
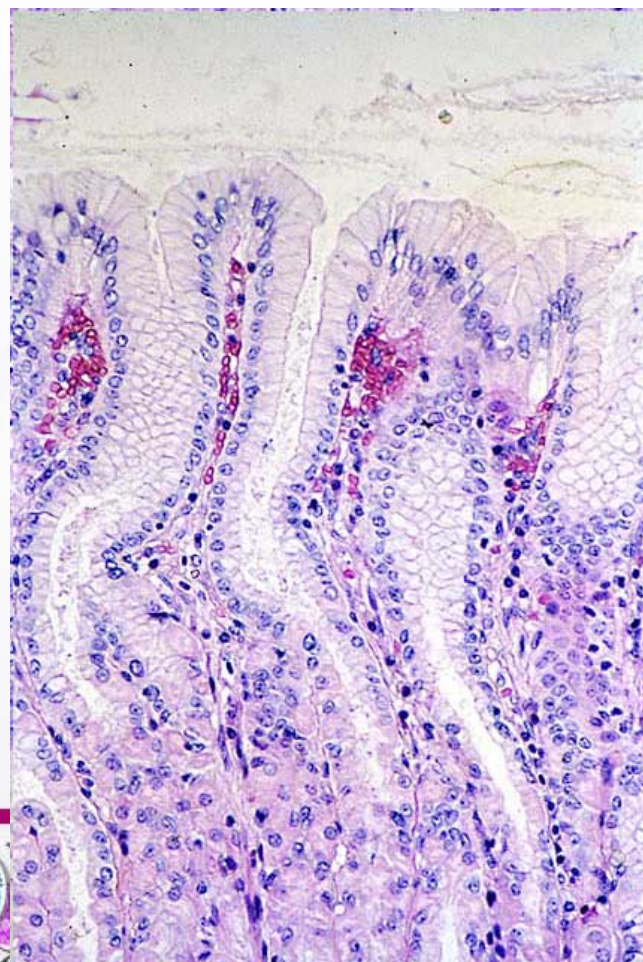

# Wotherspoon Kriterleri

Skor	Tanı	Histolojik özellik
0	Normal	Lamina propriada dağınık lenfoid hücreler. Follikül oluşumu yok
1	Kronik aktif gastrit	Lamina propriada küçük lenfoid hücre grupları. Follikül ve LEL yok
2	Beligin lenfoid follikül oluşumuyla karakterli kronik aktif gastrit.	Marginal zonu belirgin lenfoid folliküller, LEL (-).
3	Reaktif olma olasılıklı, şüpheli lenfoid infiltrasyon.	Lenfoid folliküller ve lamina propriada diffüz infiltrasyon, çok seyrek LEL (+).
4	Lenfoma olasılıklı şüpheli lenfoid infiltrasyon.	Lenfoid folliküller ve lamina propriada diffüz infiltrasyon, küçük gruplar şeklinde LEL (+).
5	MALT lenfoma	Lamina propriada marginal zon hücreleriyle yoğun infiltrasyon ve belirgin LEL (+)



Skor 0  
NORMAL



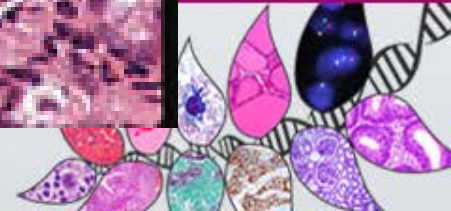
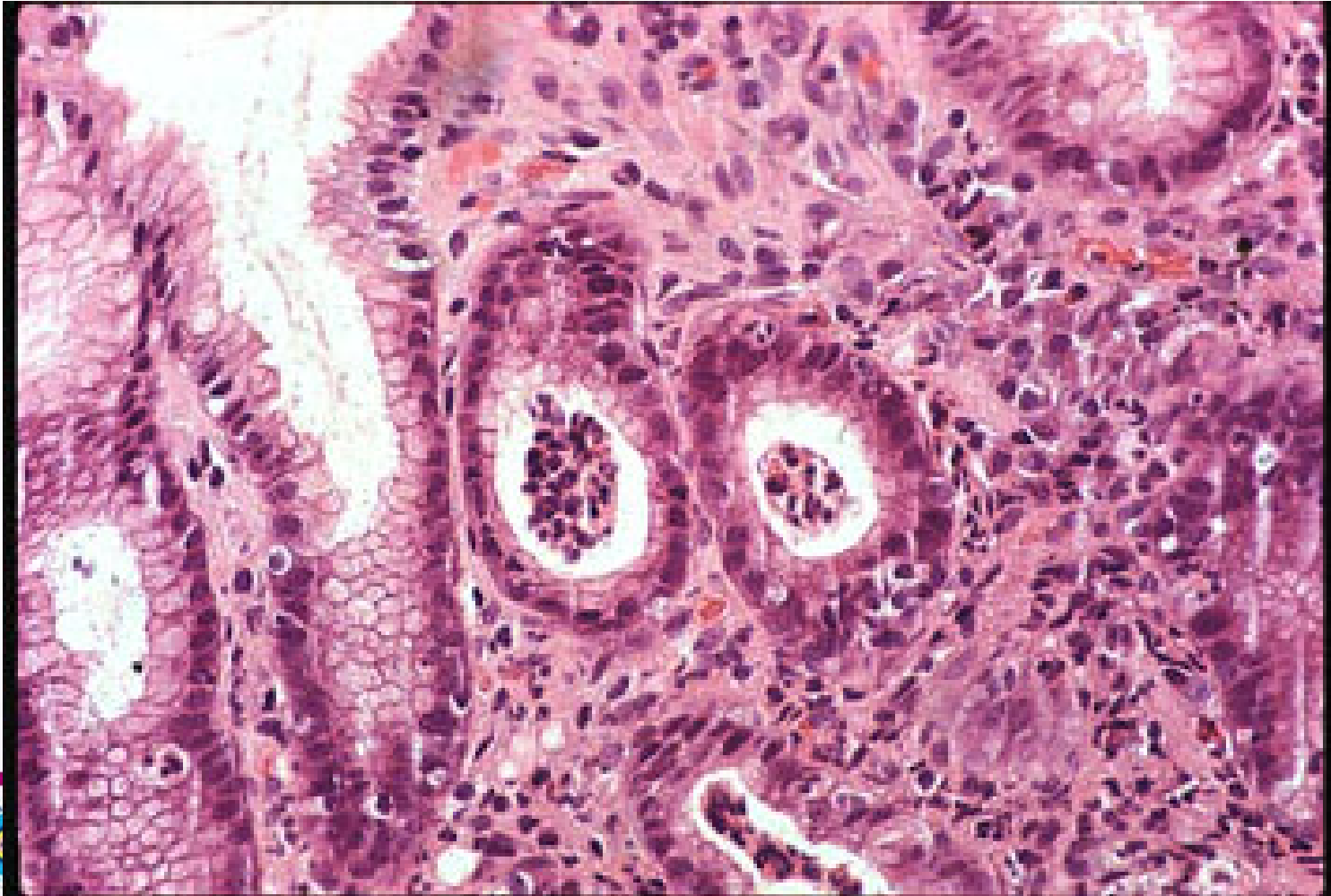14. Ulusal Patoloji Kongresi  
15. Sitopatoloji Kongresi

14 - 17 Ekim 2015 / Merinos AKKM - BURSA



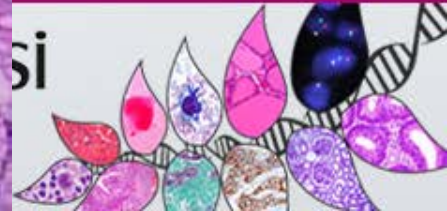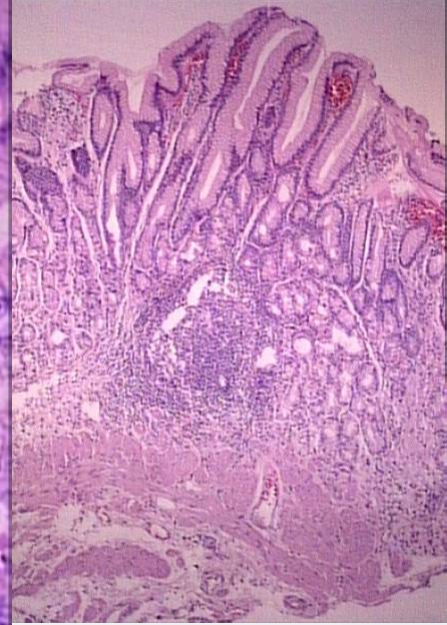
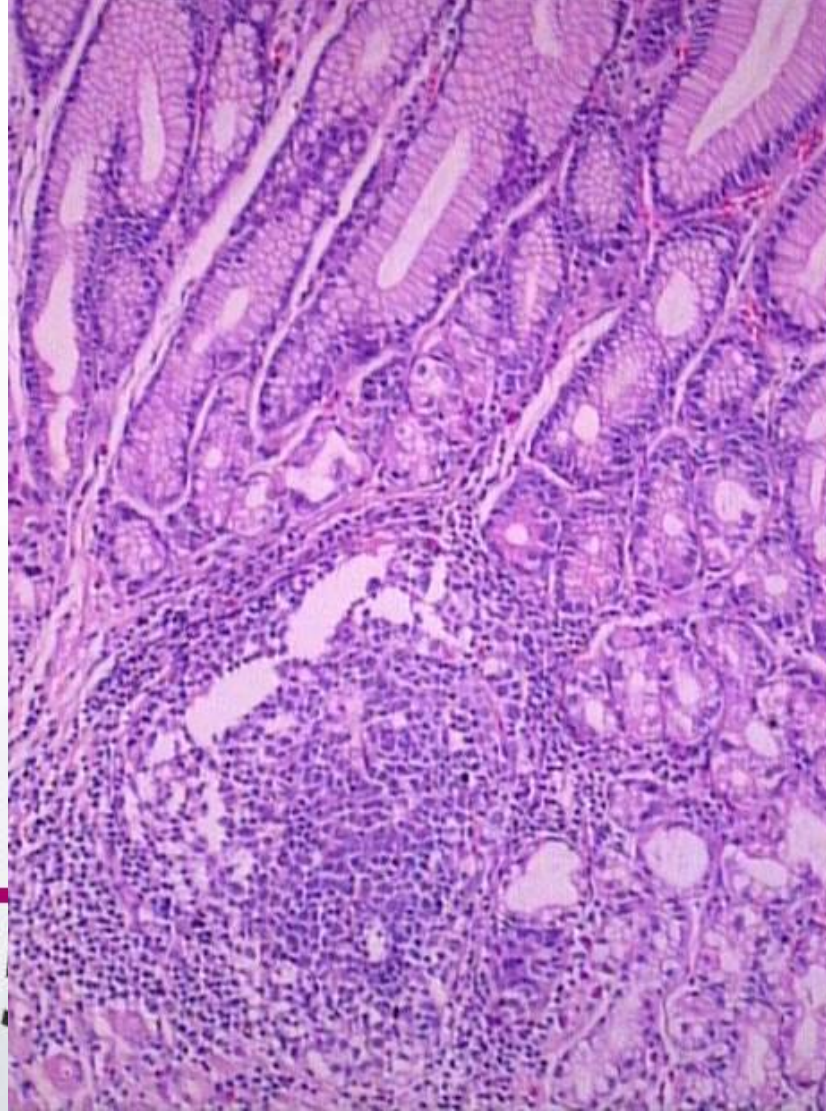
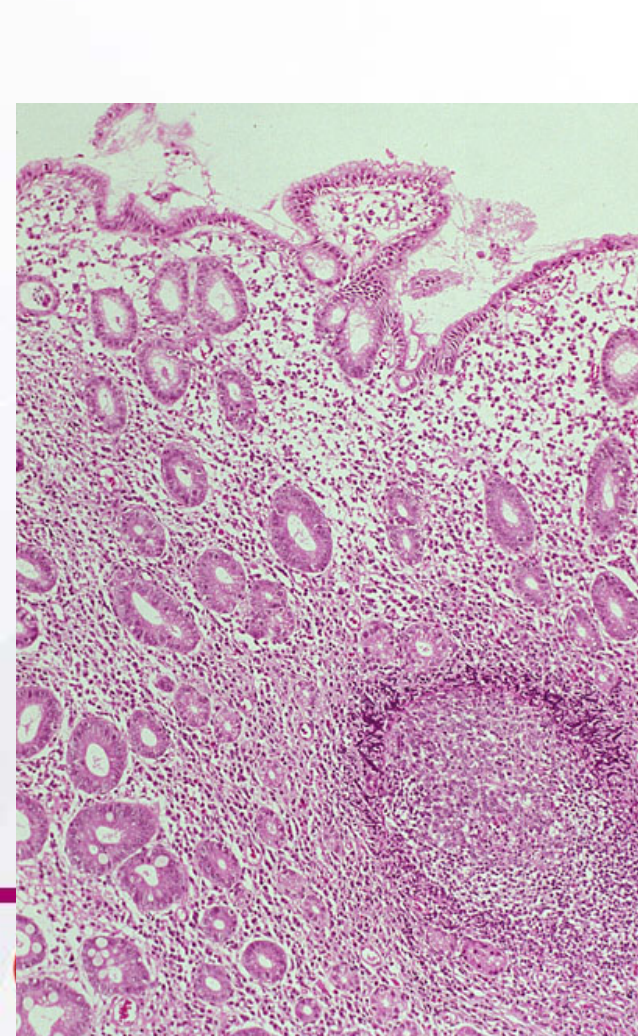
# Skor 1

## KRONİK AKTİF GASTRİT



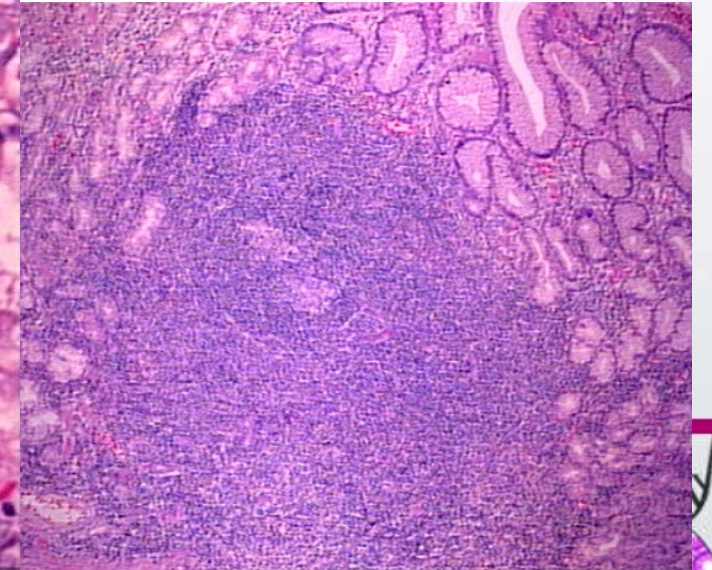
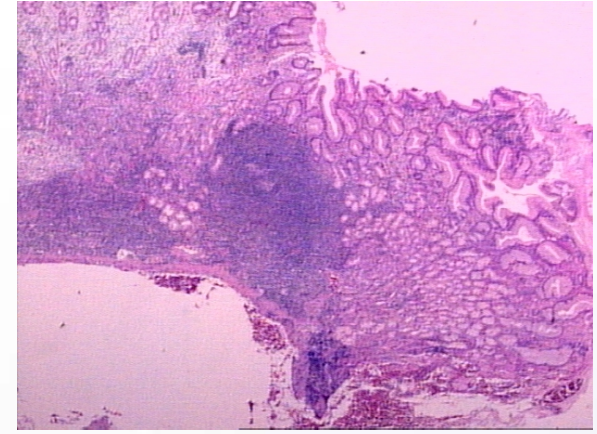
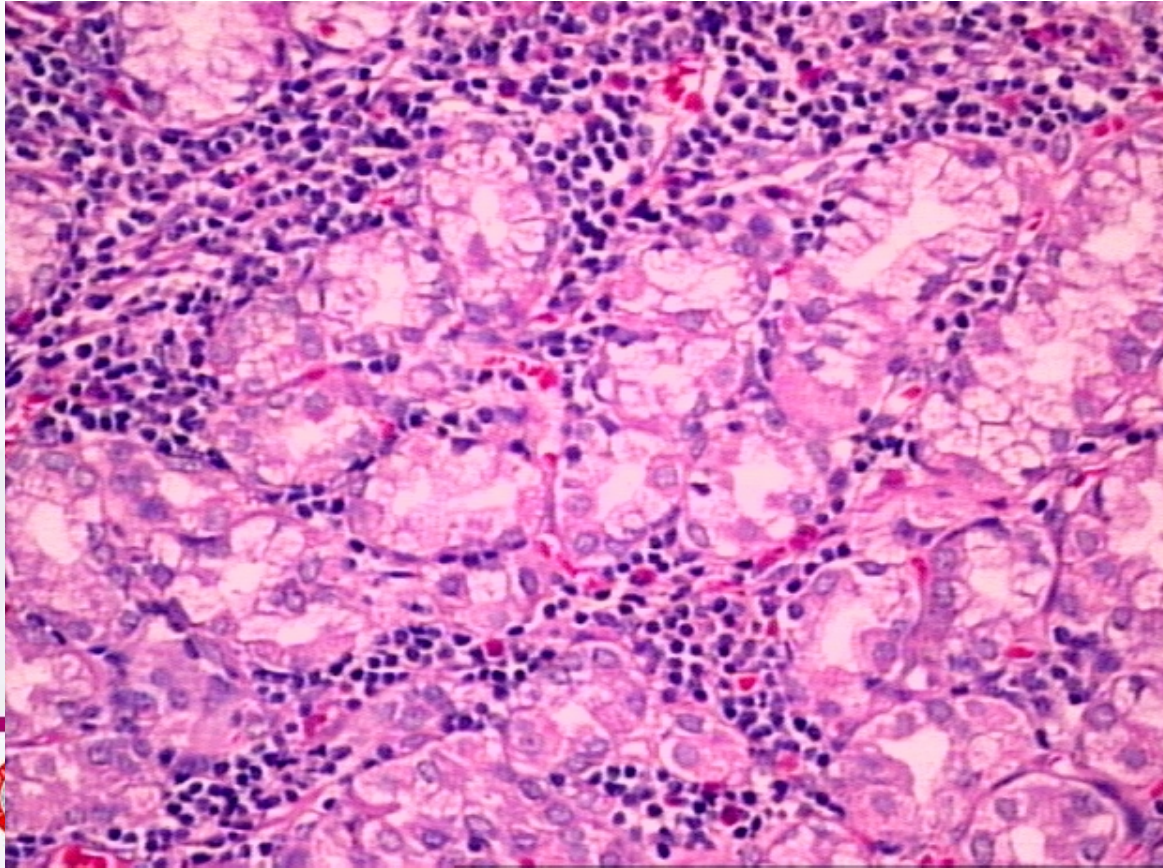
# Skor 2

LENFOİD FOLLİKÜL YAPIMIYLA KARAKTERLİ KRONİK AKTİF GASTRİT



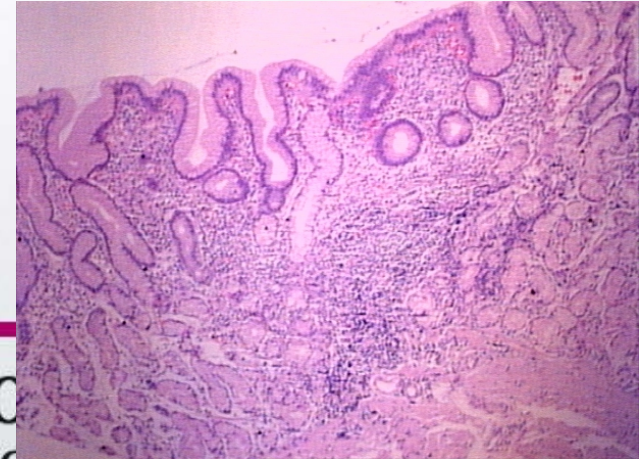
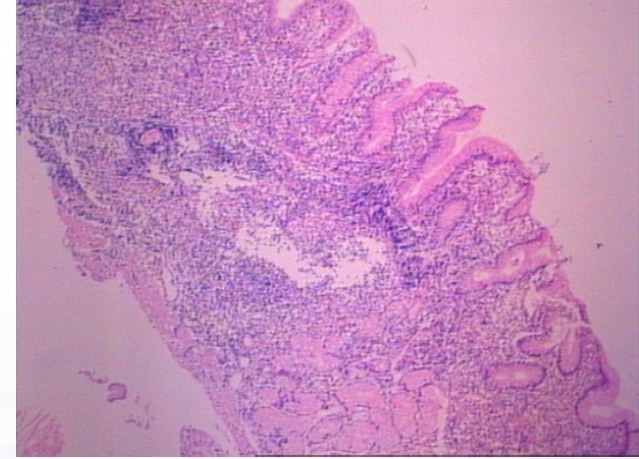
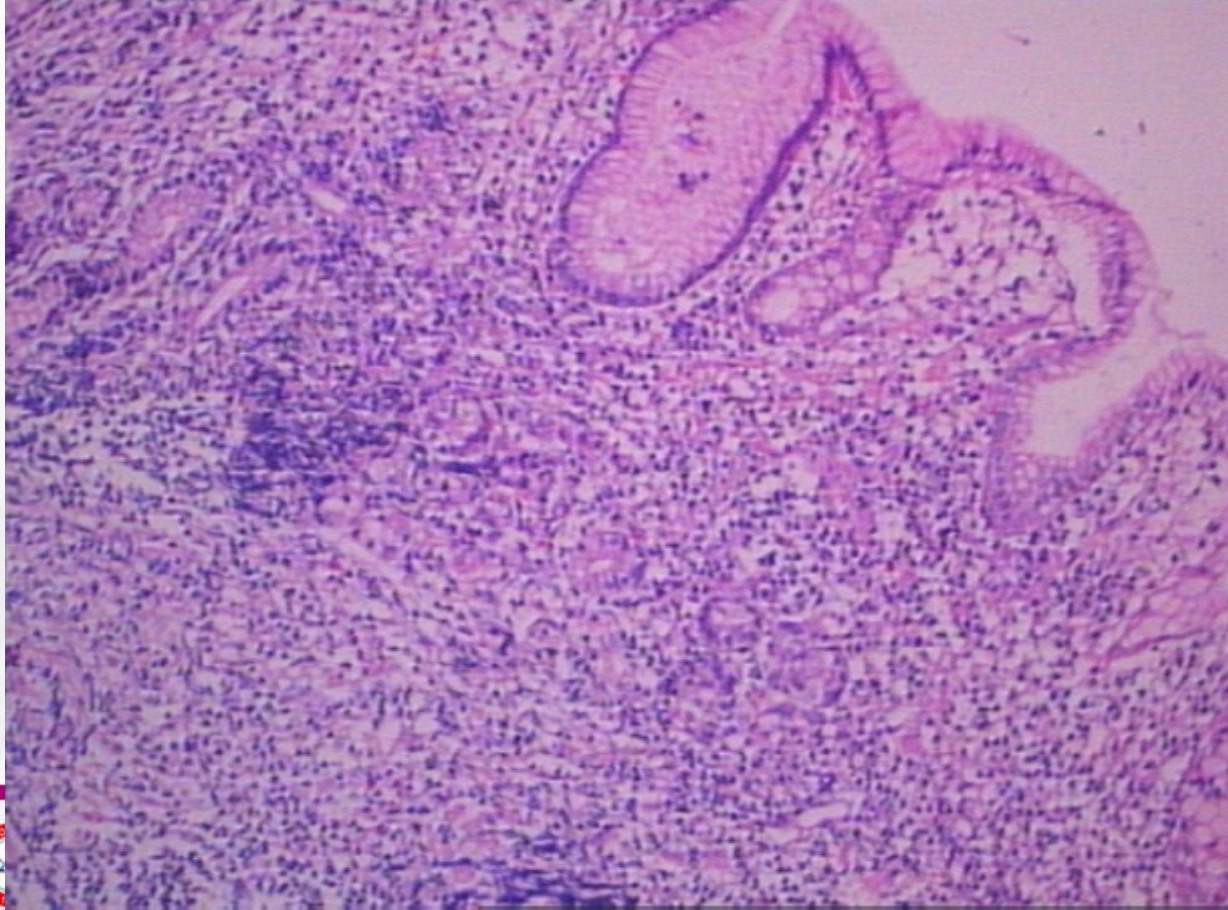
# Skor 2

LENFOİD FOLLİKÜL YAPIMIYLA KARAKTERLİ KRONİK AKTİF GASTRİT



# Skor 3

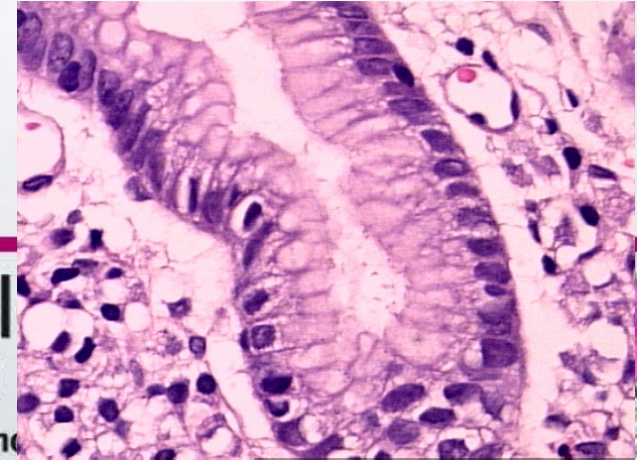
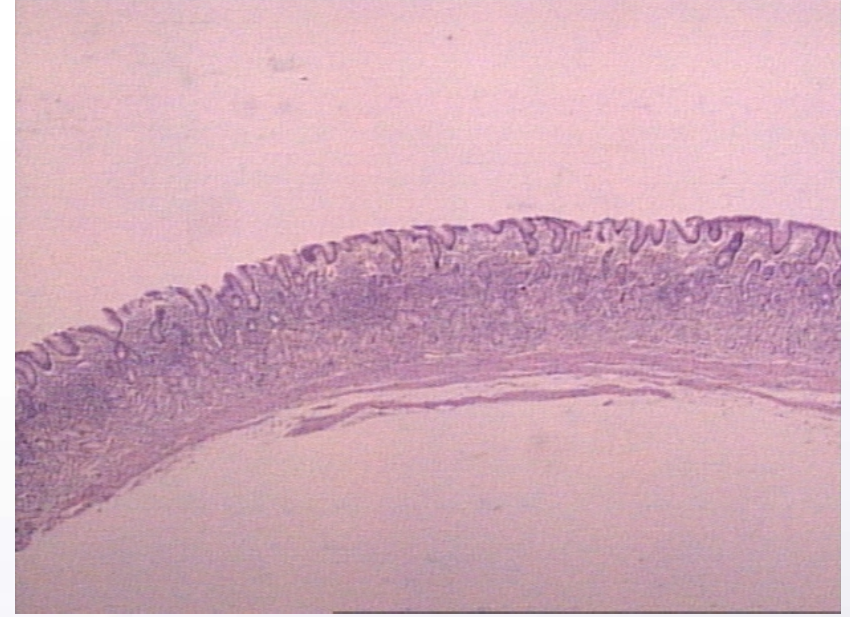
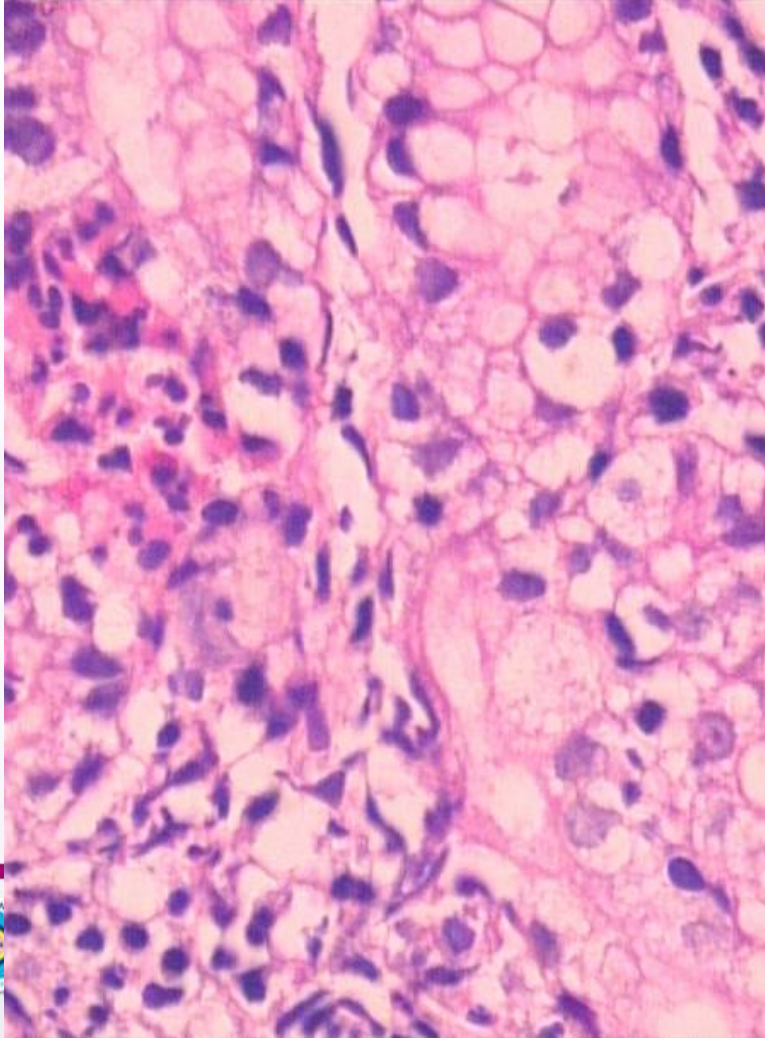
## REAKTİF OLASILIKLI ŞÜPHELİ LENFOİD PROLİFERASYON





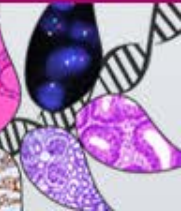
# Skor 3

## REAKTİF OLASILIKLI ŞÜPHELİ LENFOİD PROLİFERASYON



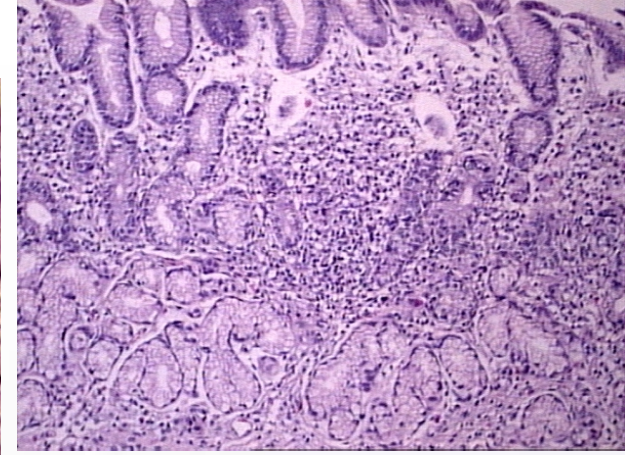
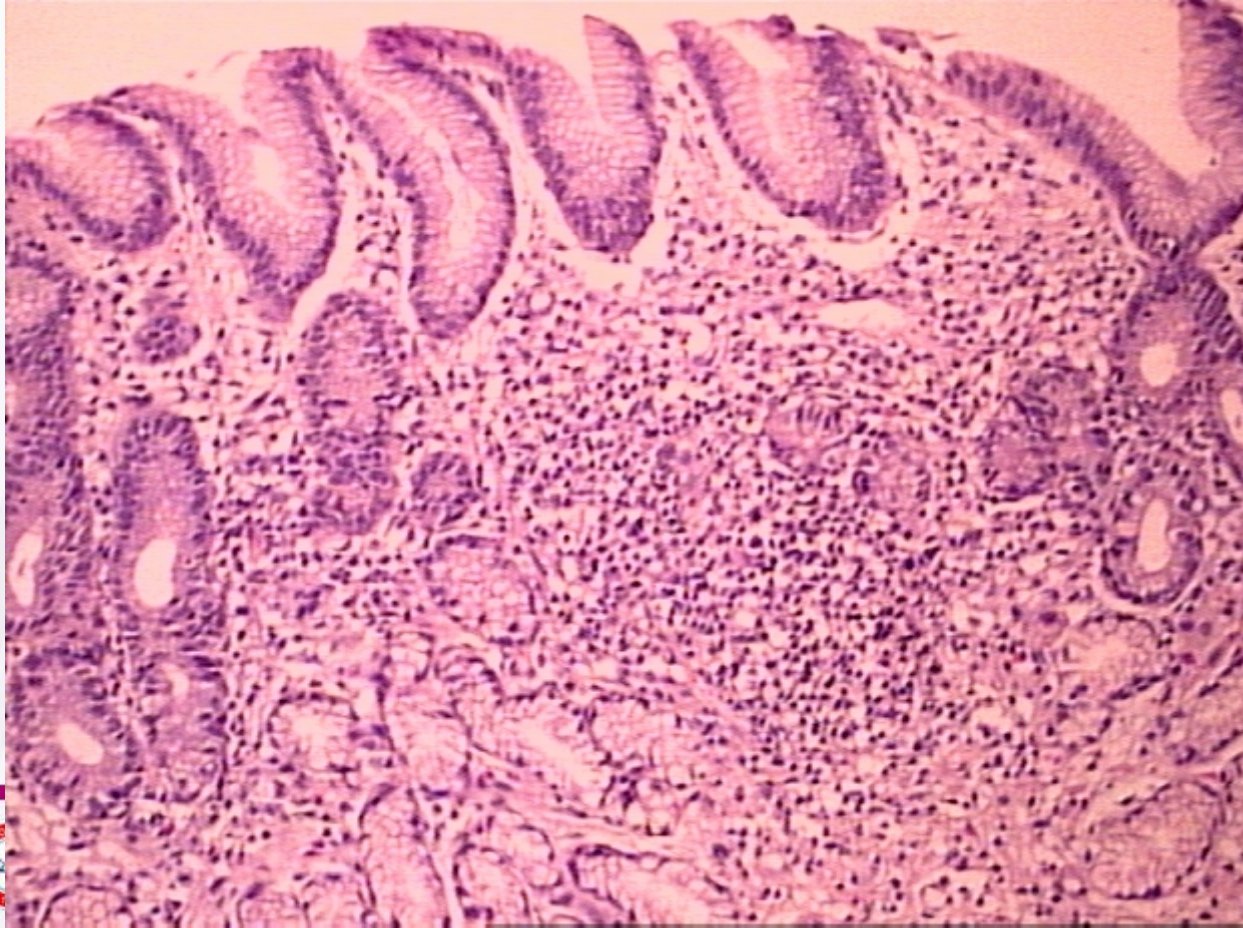
Patoloji  
Patoloji

14 - 17 Ekim 2015 / Merin



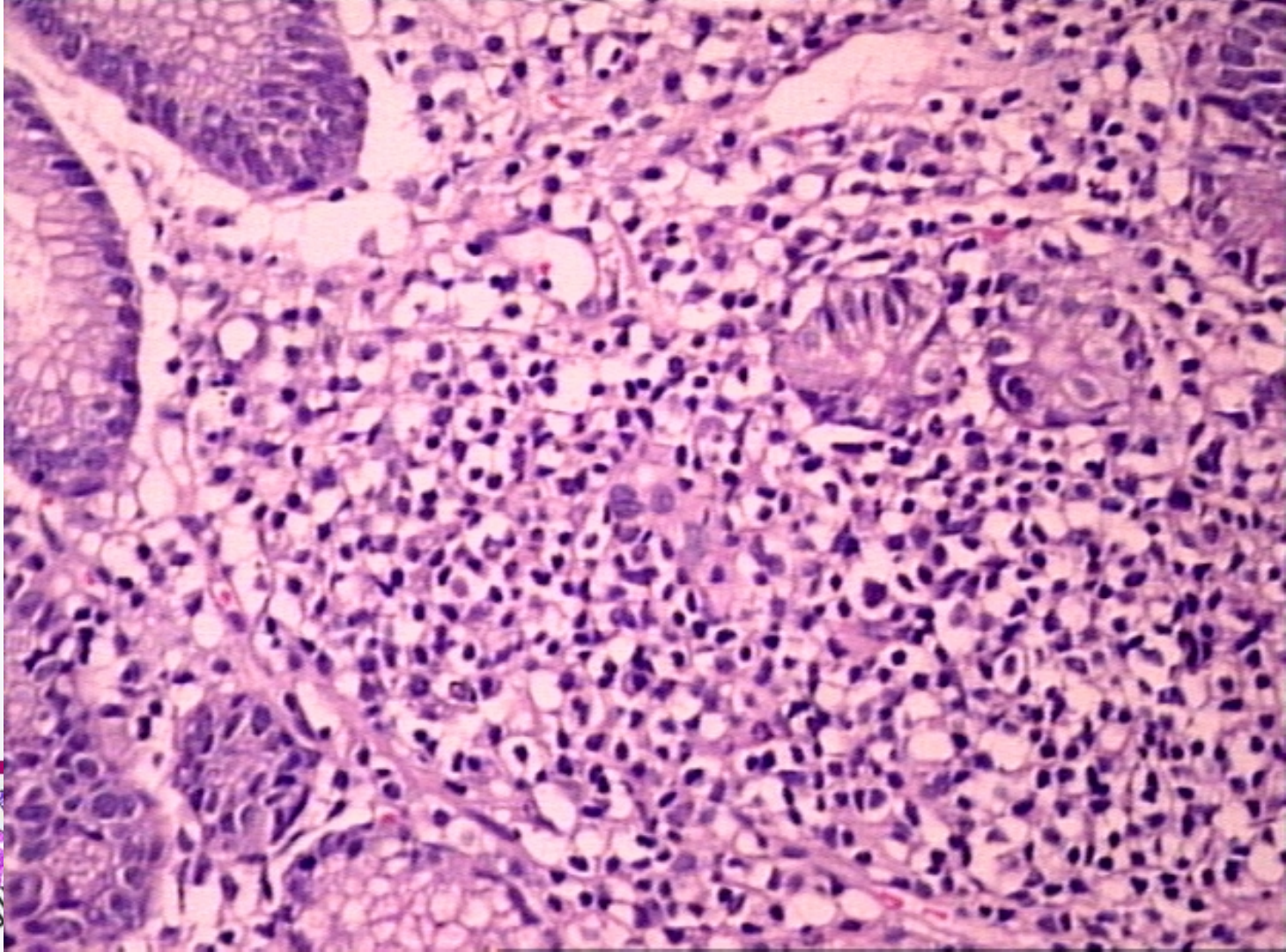
# Skor 3

## REAKTİF OLASILIKLI ŞÜPHELİ LENFOİD PROLİFERASYON



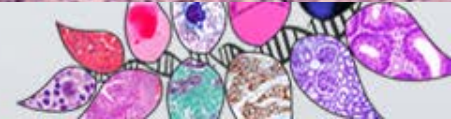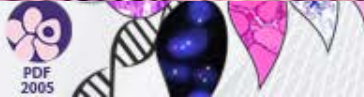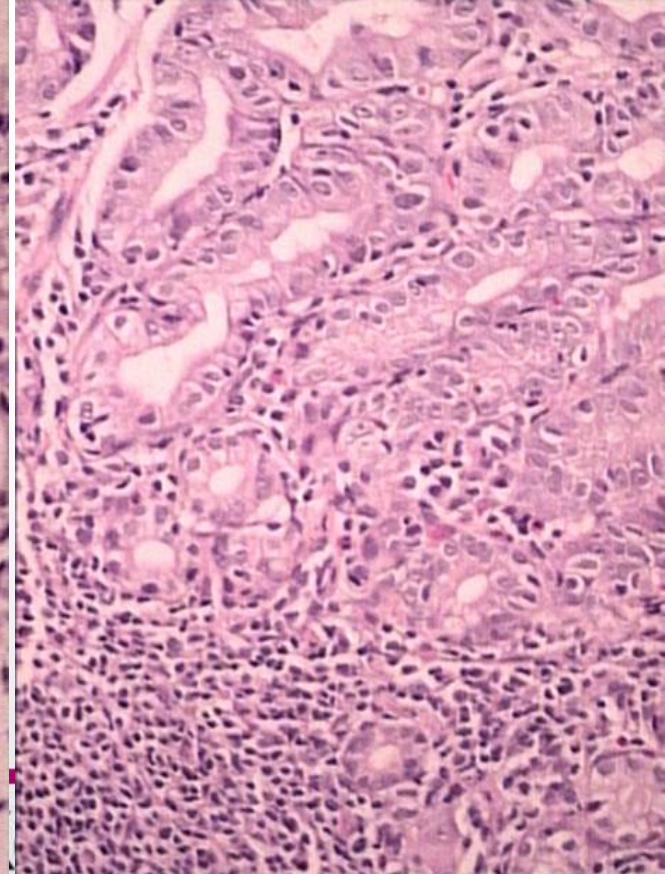
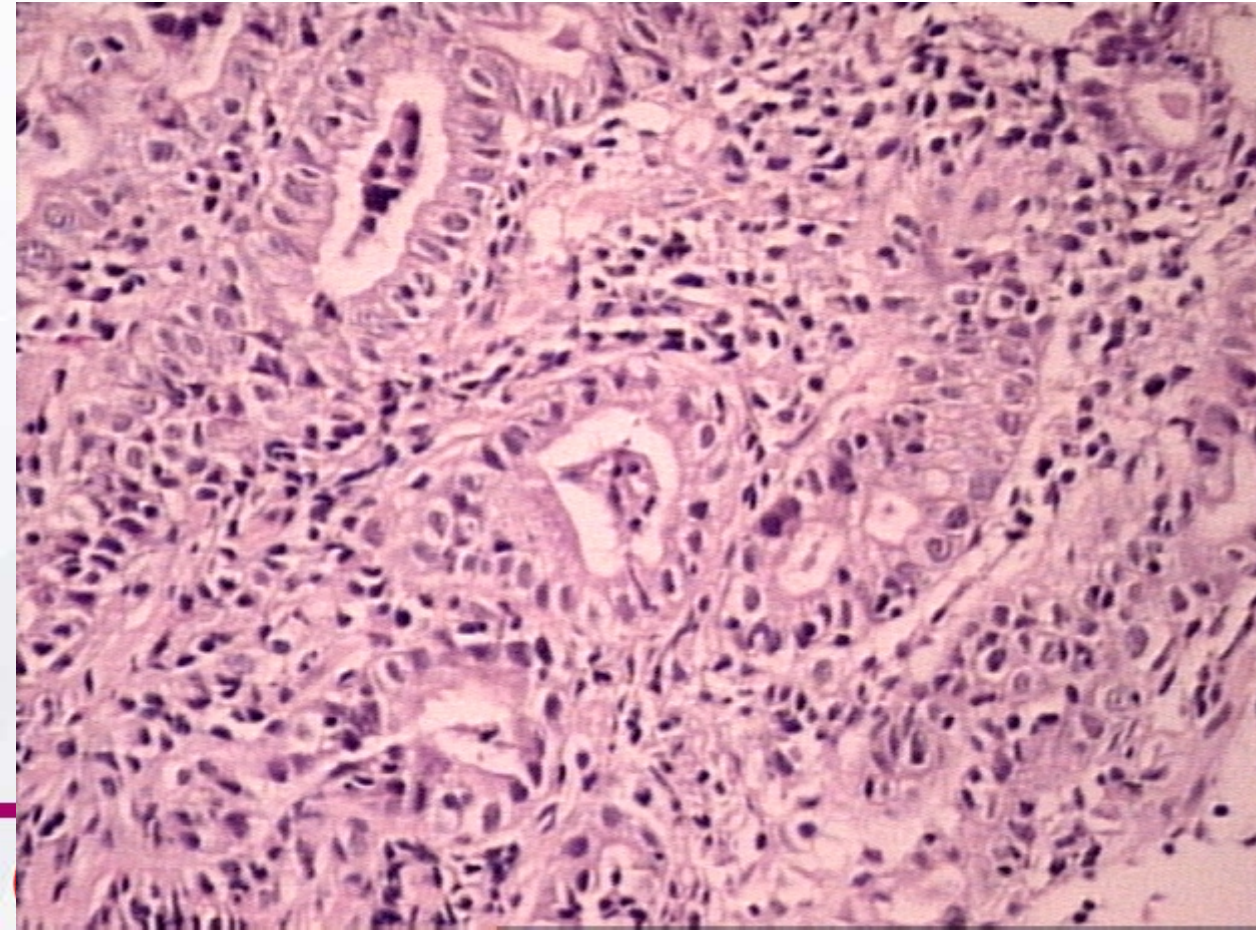
# Skor 3

## REAKTİF OLASILIKLI ŞÜPHELİ LENFOİD PROLİFERASYON



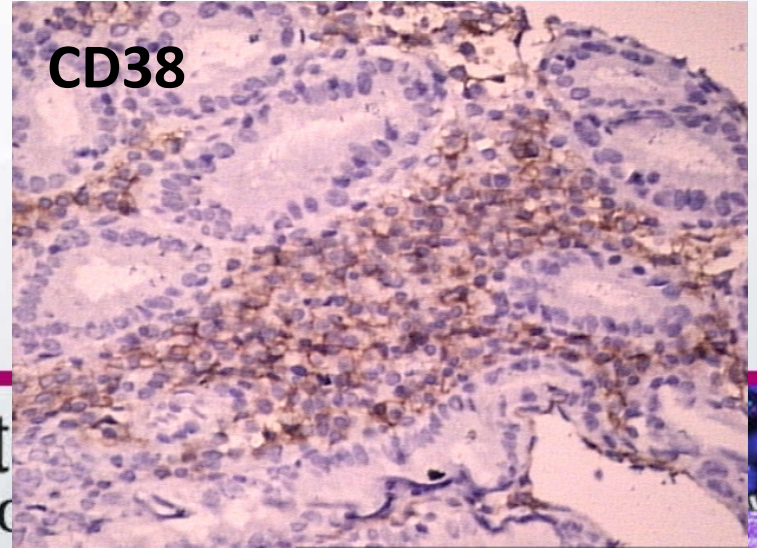
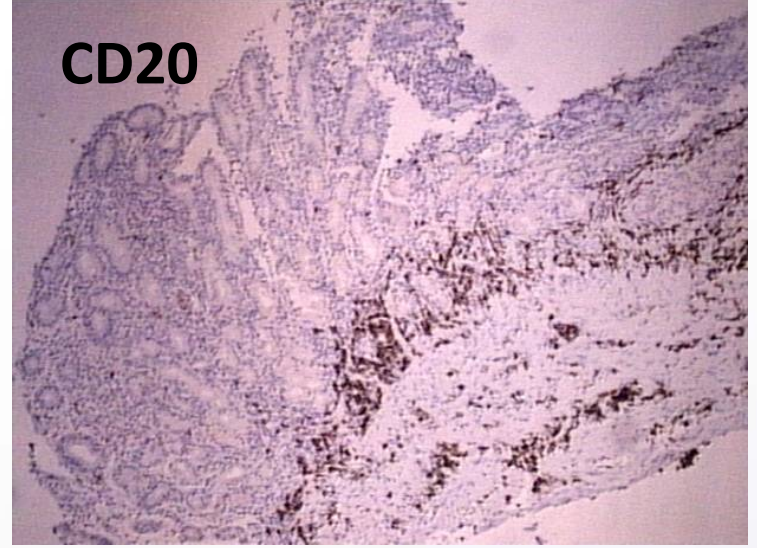
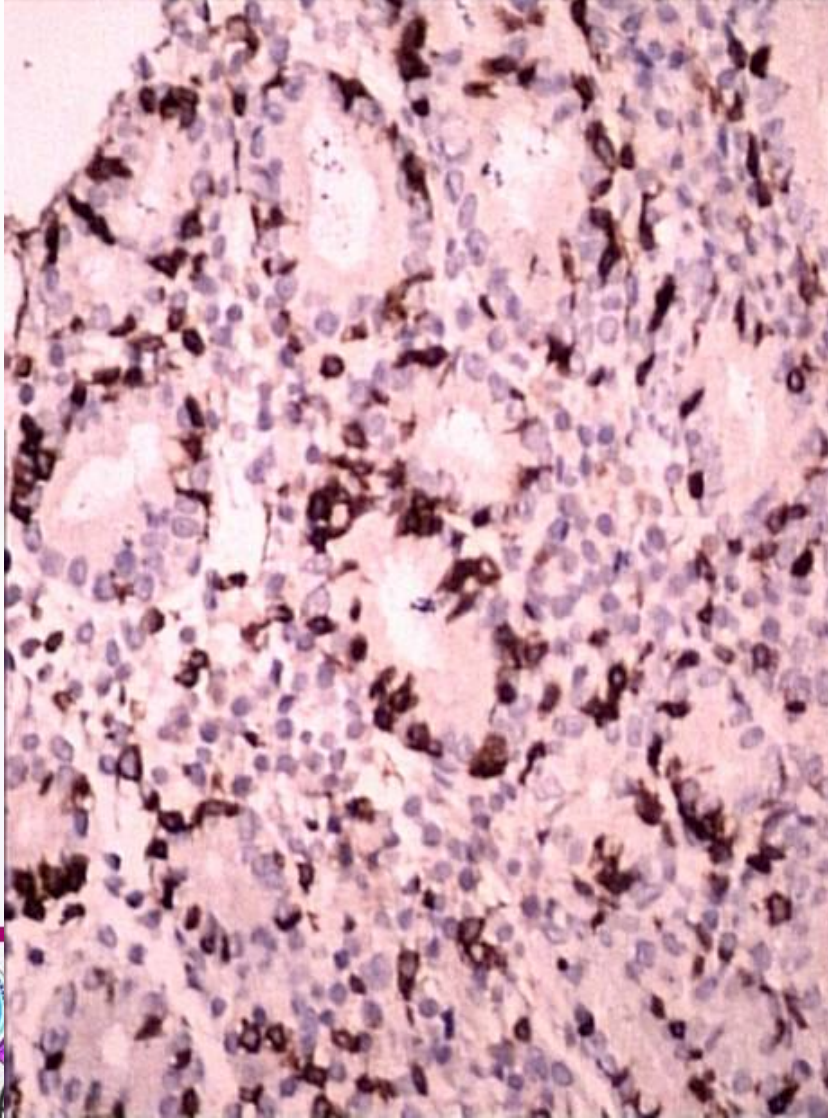
# Skor 3

## REAKTİF OLASILIKLI ŞÜPHELİ LENFOİD PROLİFERASYON



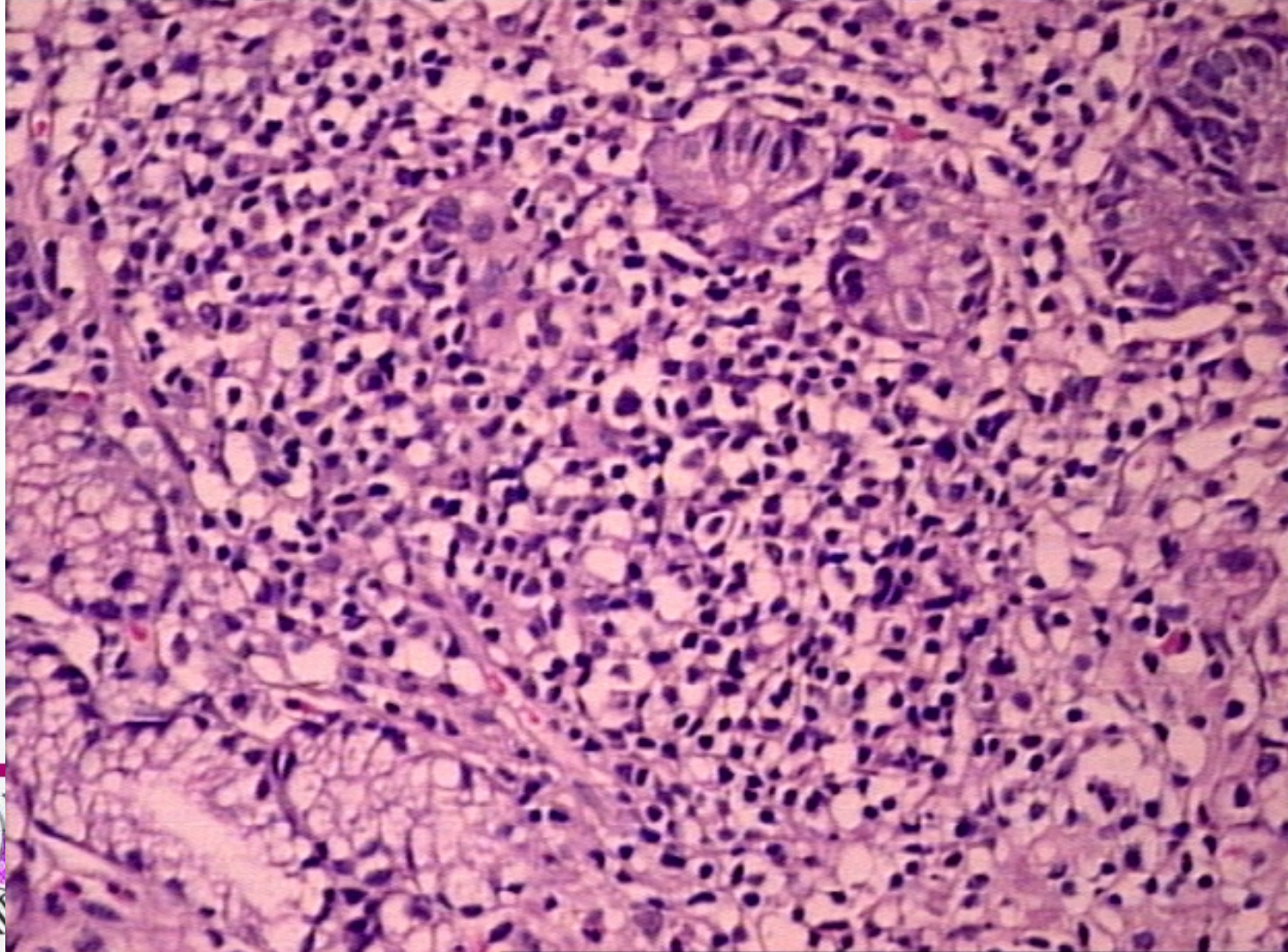
# Skor 3

## REAKTİF OLASILIKLI ŞÜPHELİ LENFOİD PROLİFERASYON



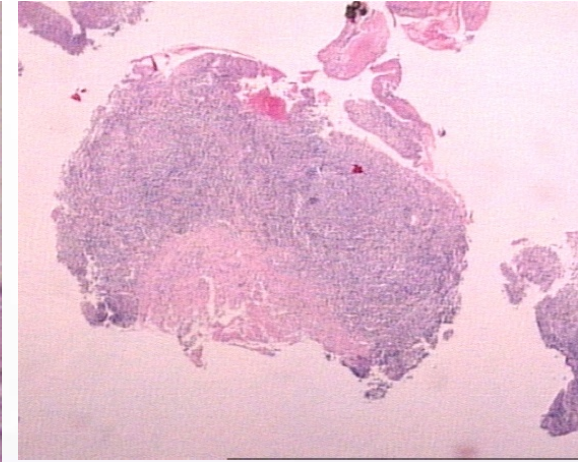
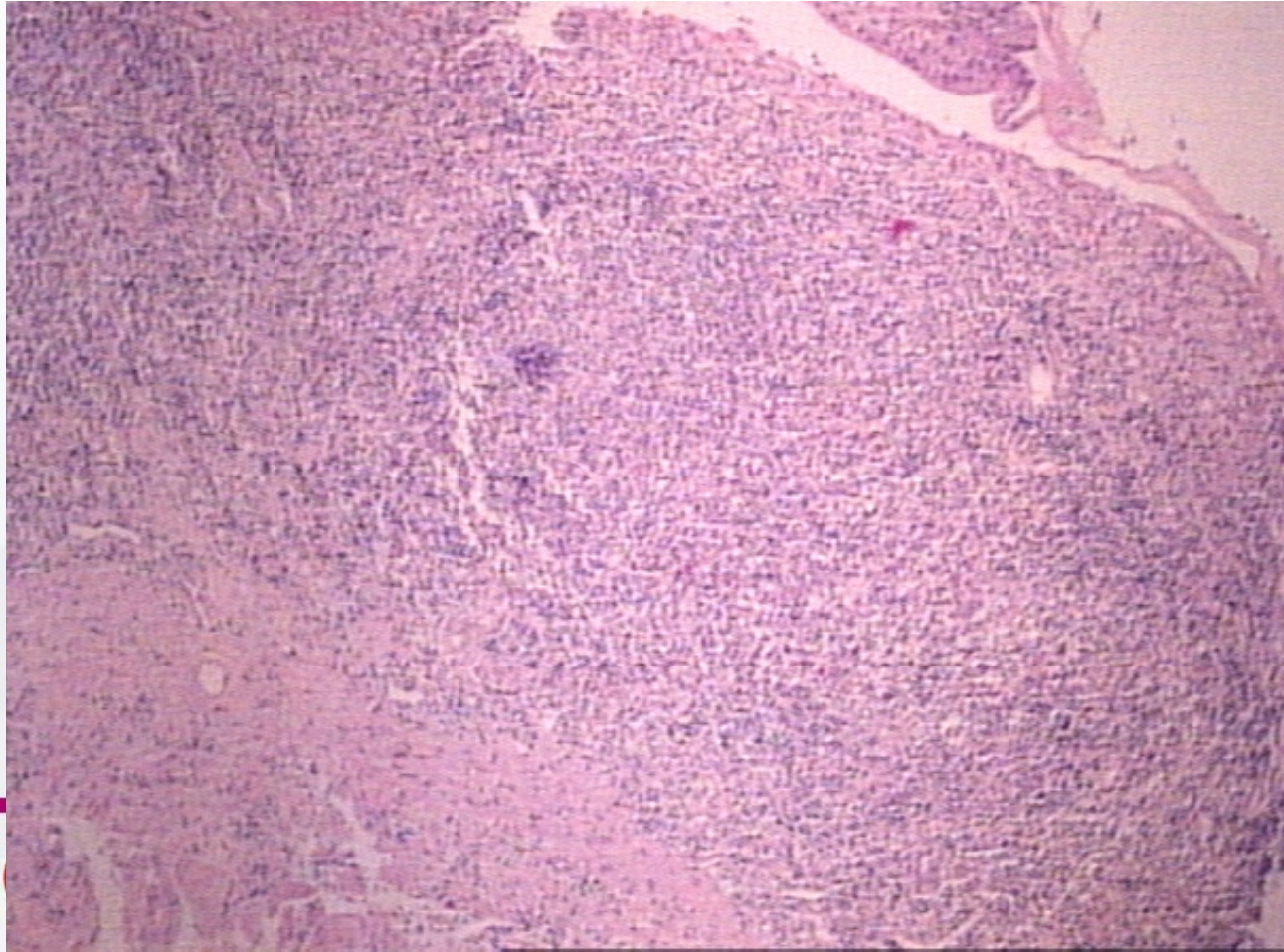
# Skor 3

## REAKTİF OLASILIKLI ŞÜPHELİ LENFOİD PROLİFERASYON



# Skor 4

## NEOPLASTİK OLASILIKLI ŞÜPHELİ LENFOİD PROLİFERASYON



ngresi

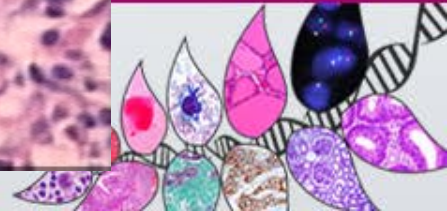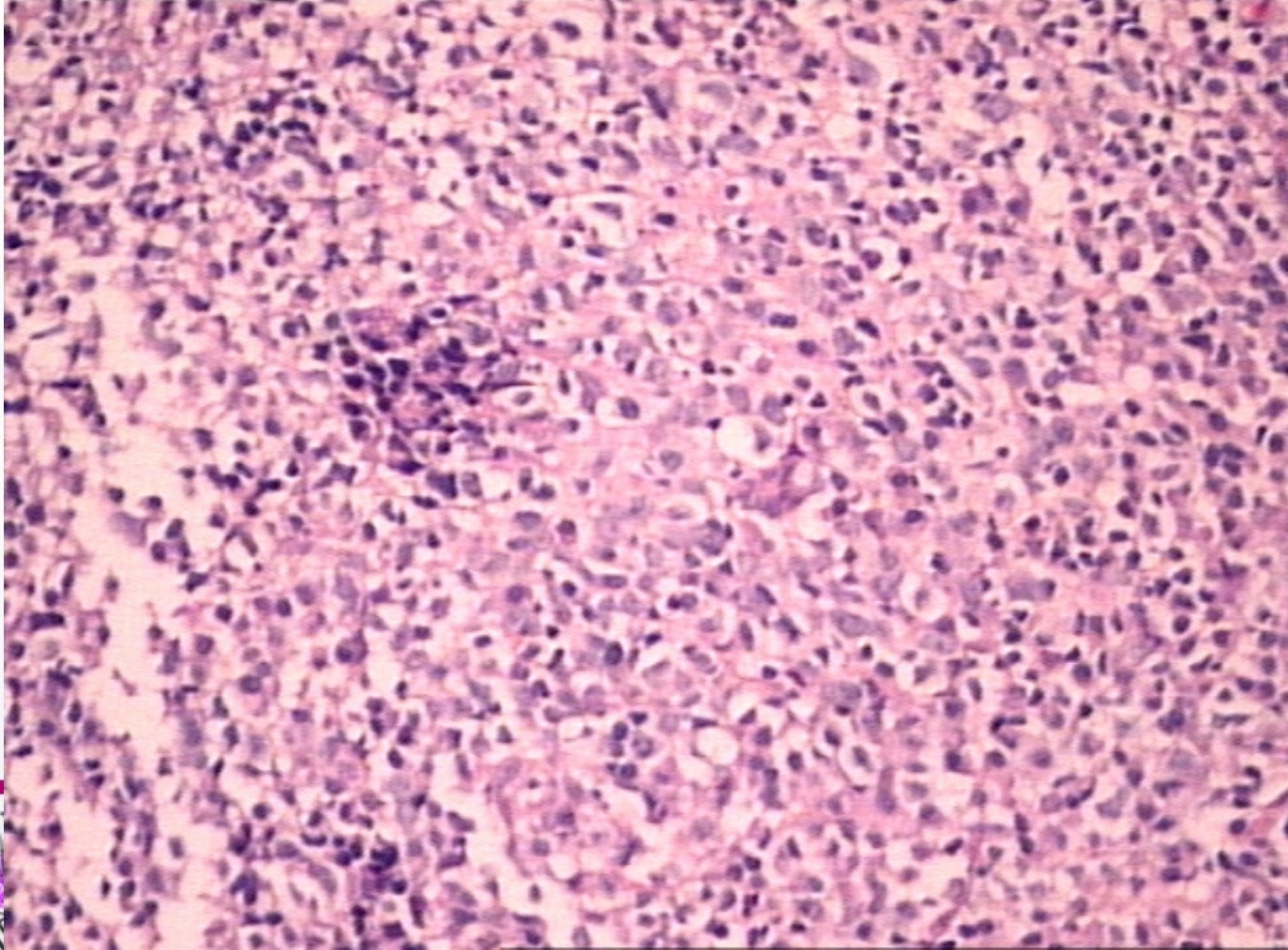
si

14 - 17 Ekim 2015 / Merinos AKKM - BURSA



# Skor 4

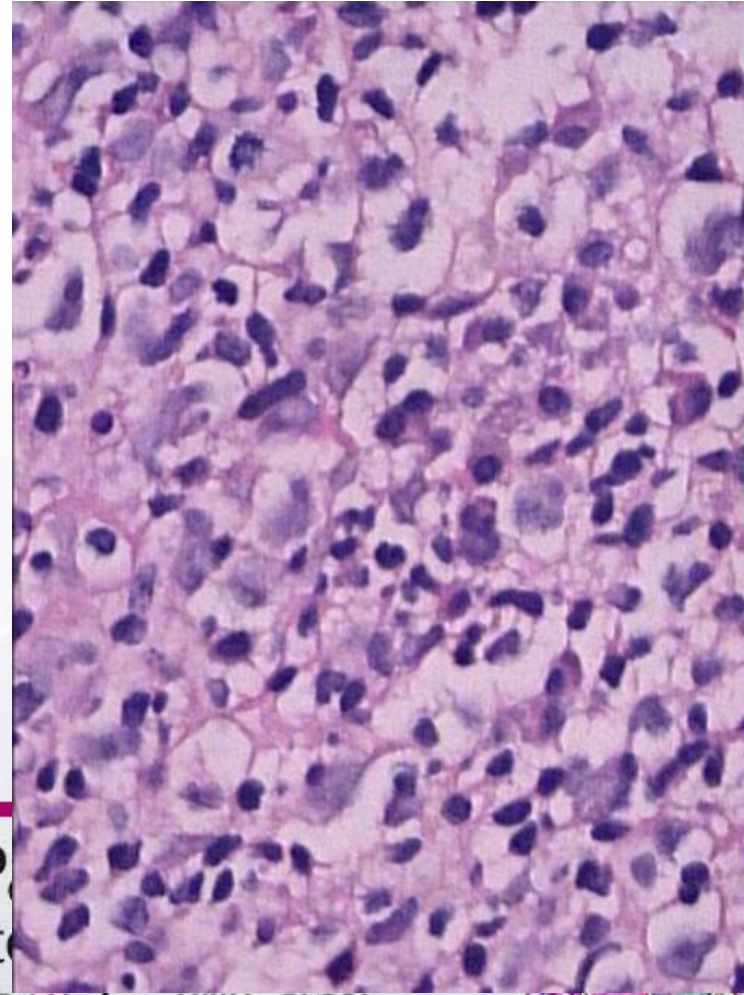
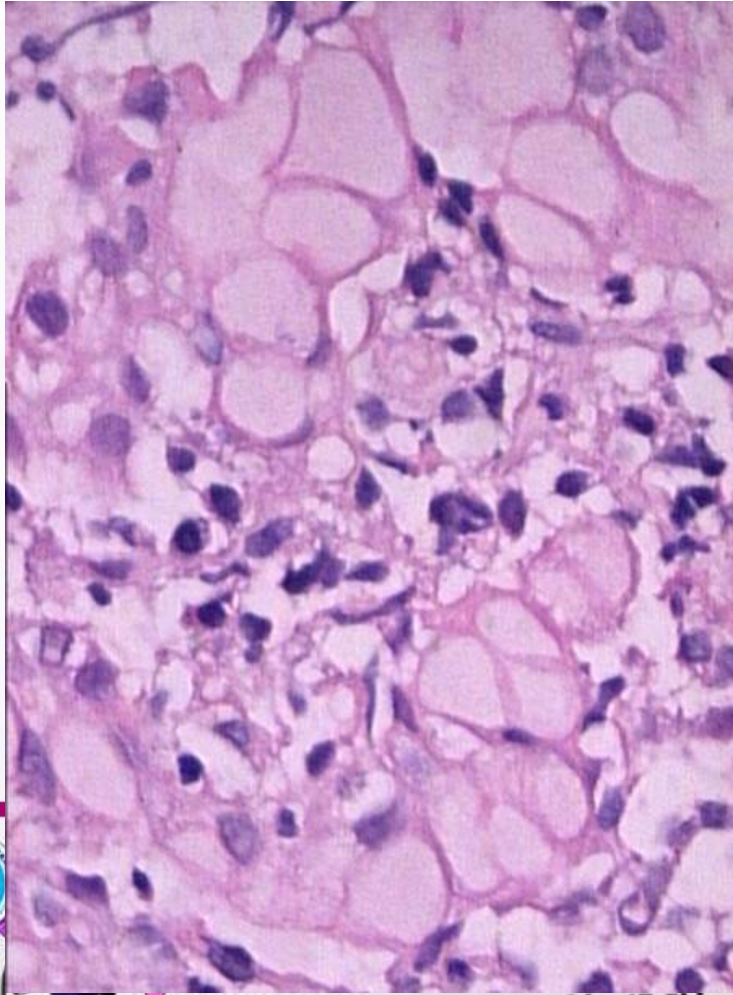
## NEOPLASTİK OLASILIKLI ŞÜPHELİ LENFOİD PROLİFERASYON



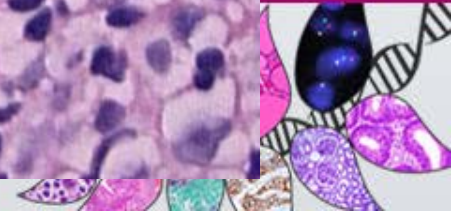


# Skor 4

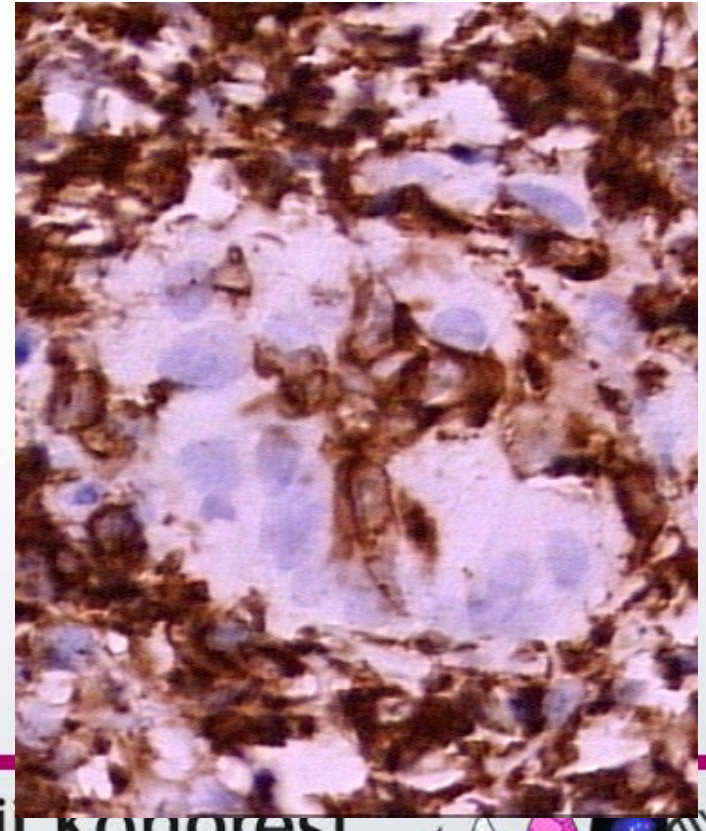
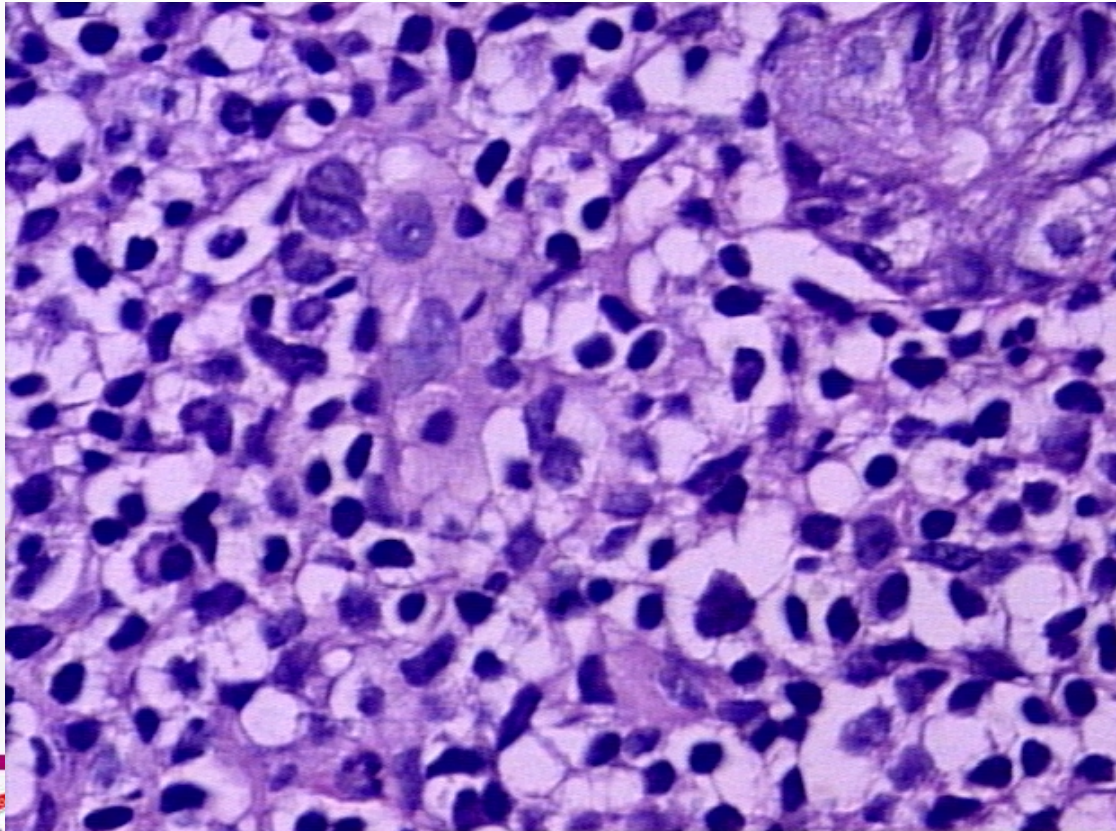
## NEOPLASTİK OLASILIKLI ŞÜPHELİ LENFOİD PROLİFERASYON



P  
at

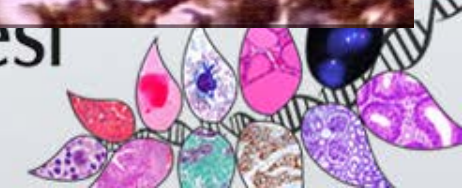
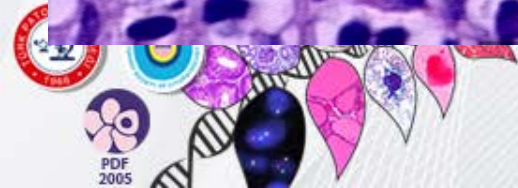
**LEL**



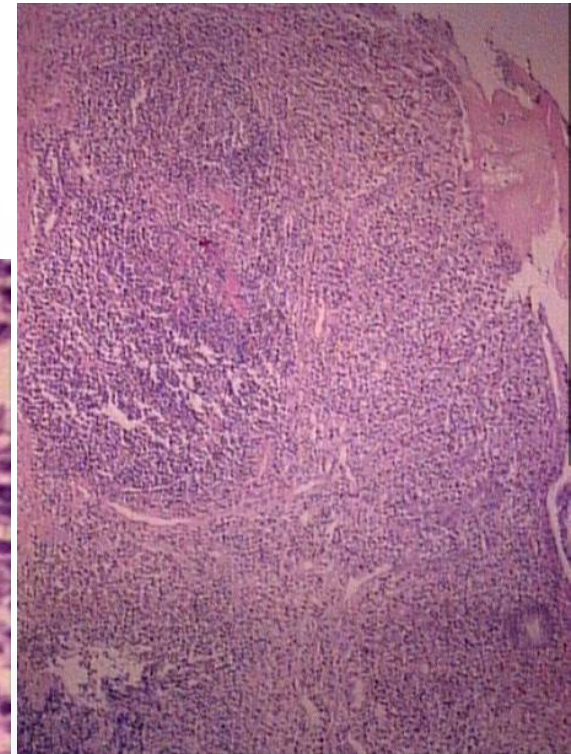
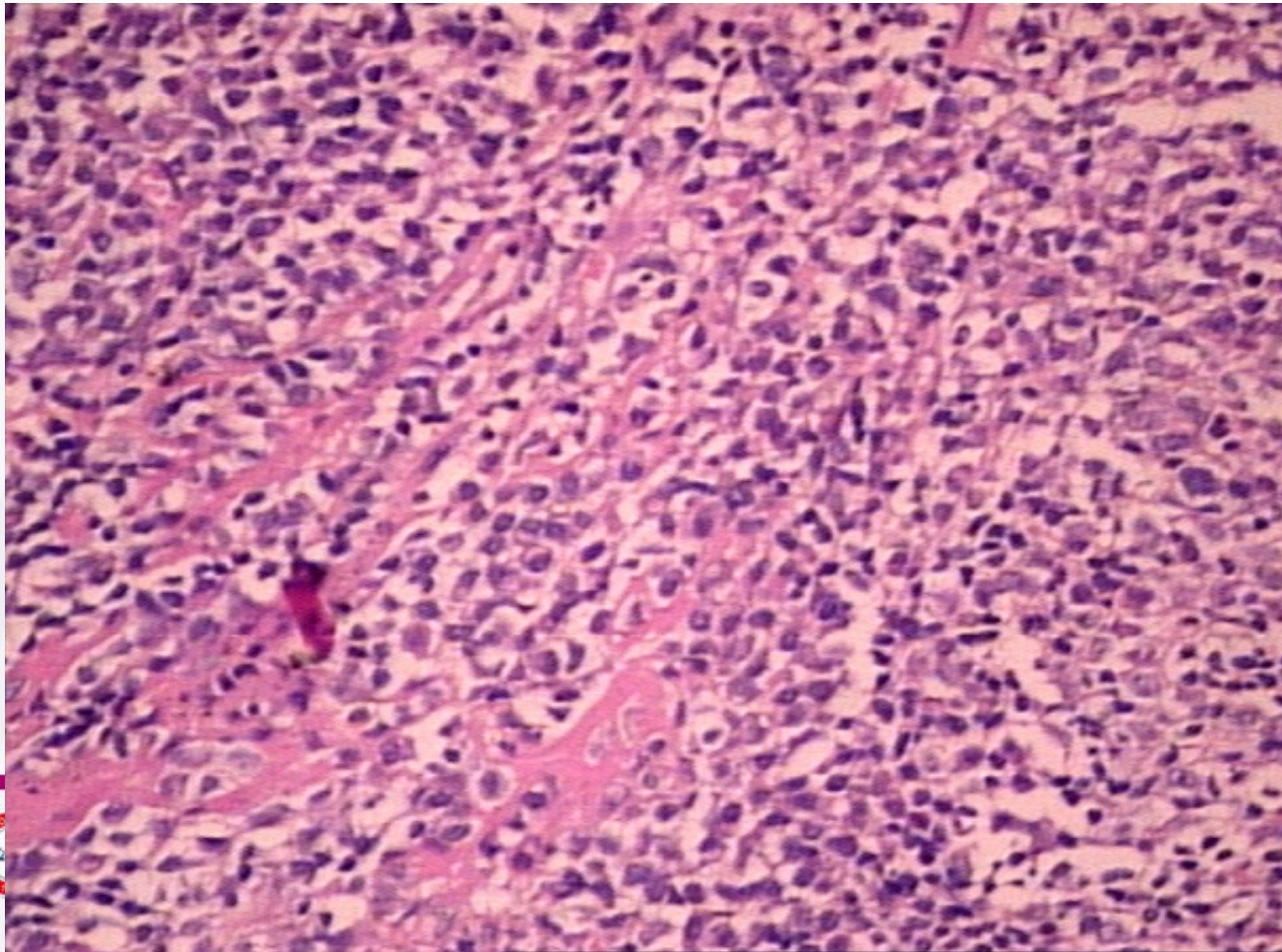
25. Ulusal Patoloji Kongresi  
6. Sitopatoloji Kongresi

14 - 17 Ekim 2015 / Merinos AKKM - BURSA

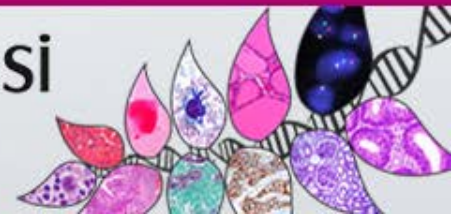

# Skor 5

## MALT LENFOMA

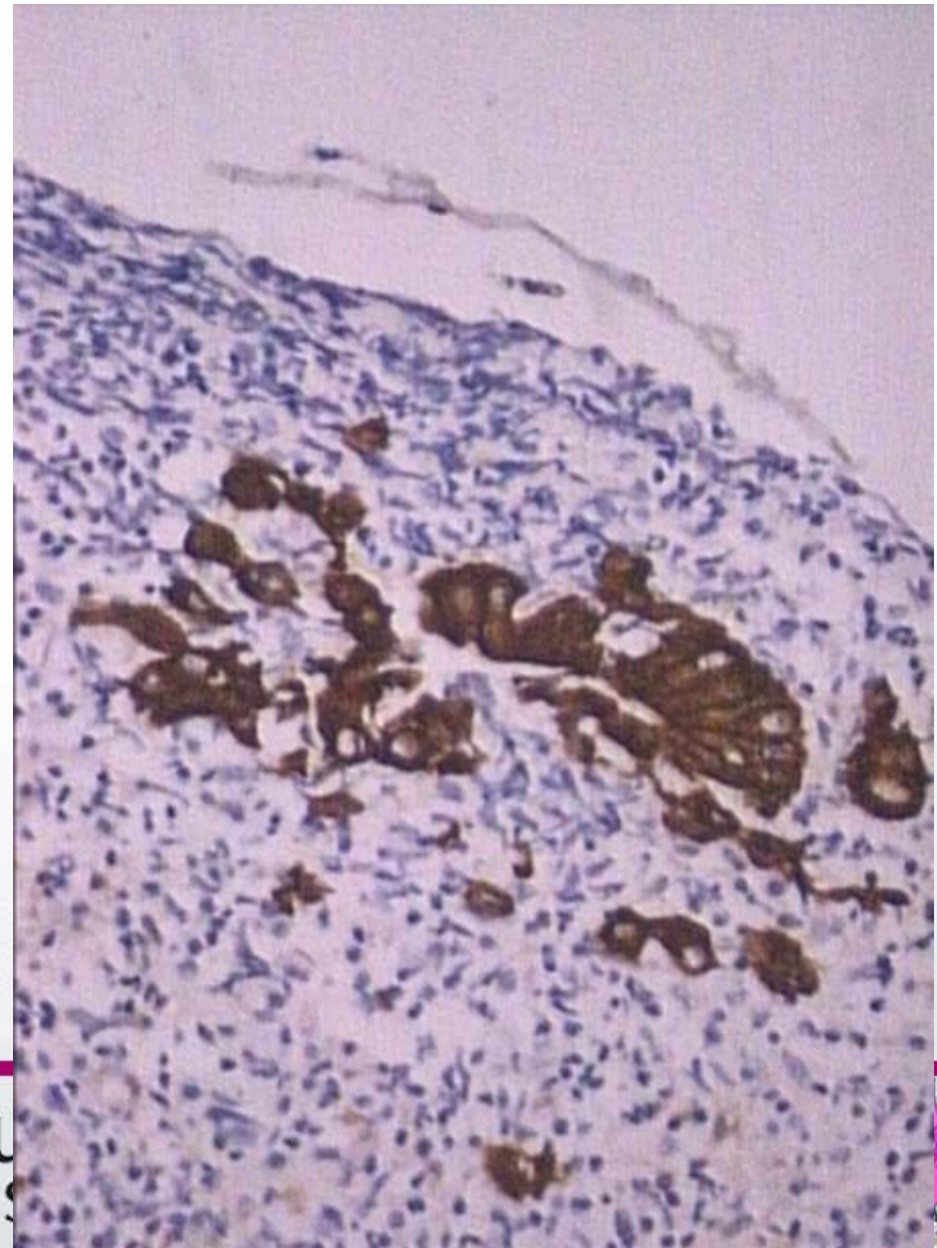
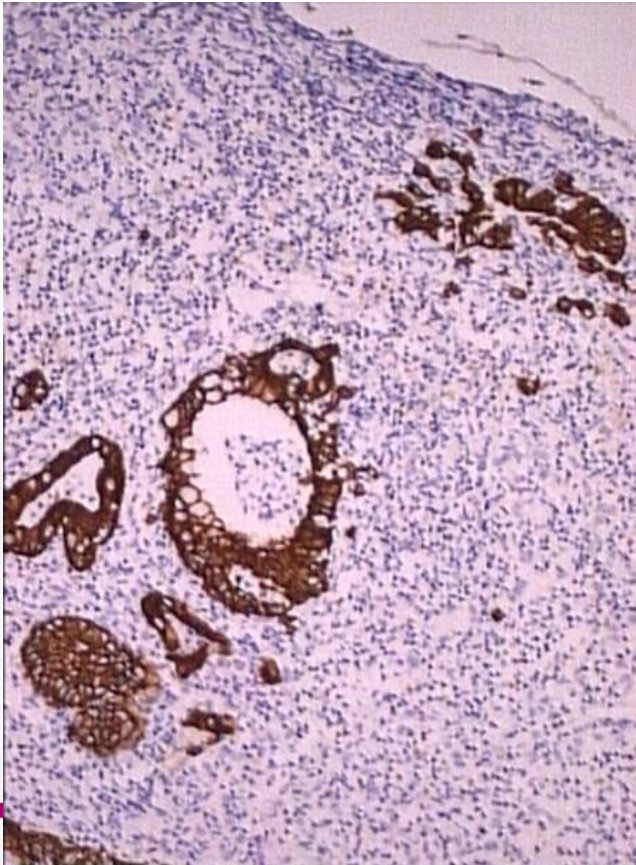


gresi

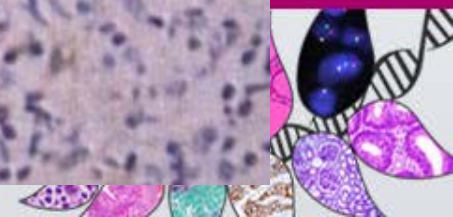


# Skor 5

## MALT LENFOMA



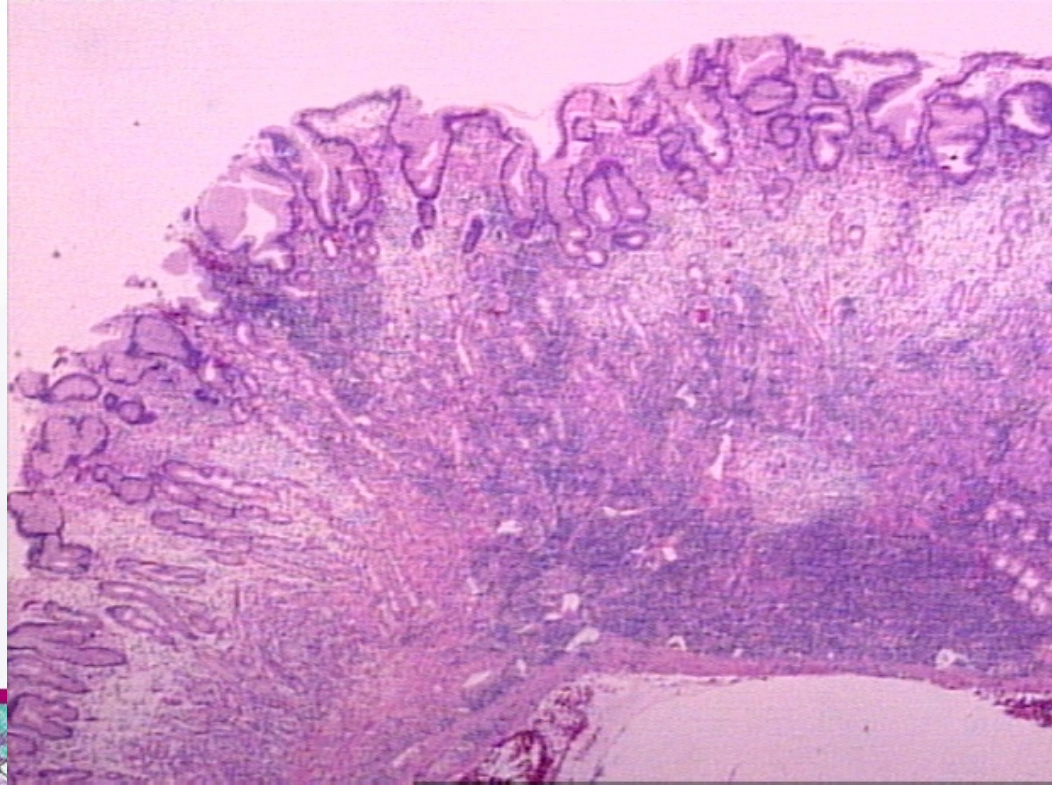
25. Ulu  
6. S



# MİDE MALT LENFOMALARINDA TANISAL YAKLAŞIMDA ALGORİTMA

LENFOİD  
İNİLTRASYON

Skor 3


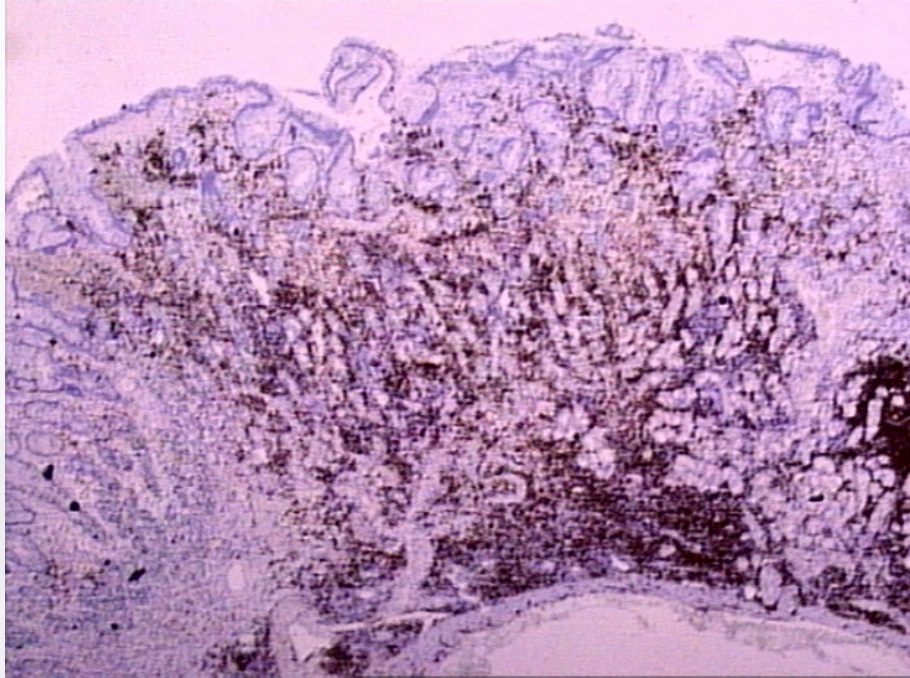
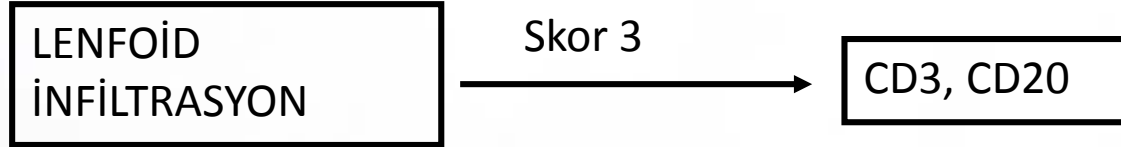


6. Sitopatoloji Kongresi

14 - 17 Ekim 2015 / Merinos AKKM - BURSA



# MİDE MALT LENFOMALARINDA TANISAL YAKLAŞIMDA ALGORİTMA

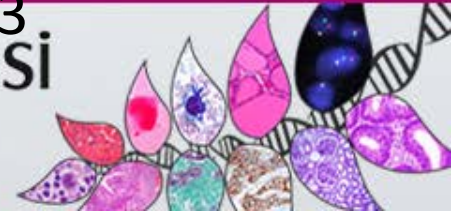

CD20

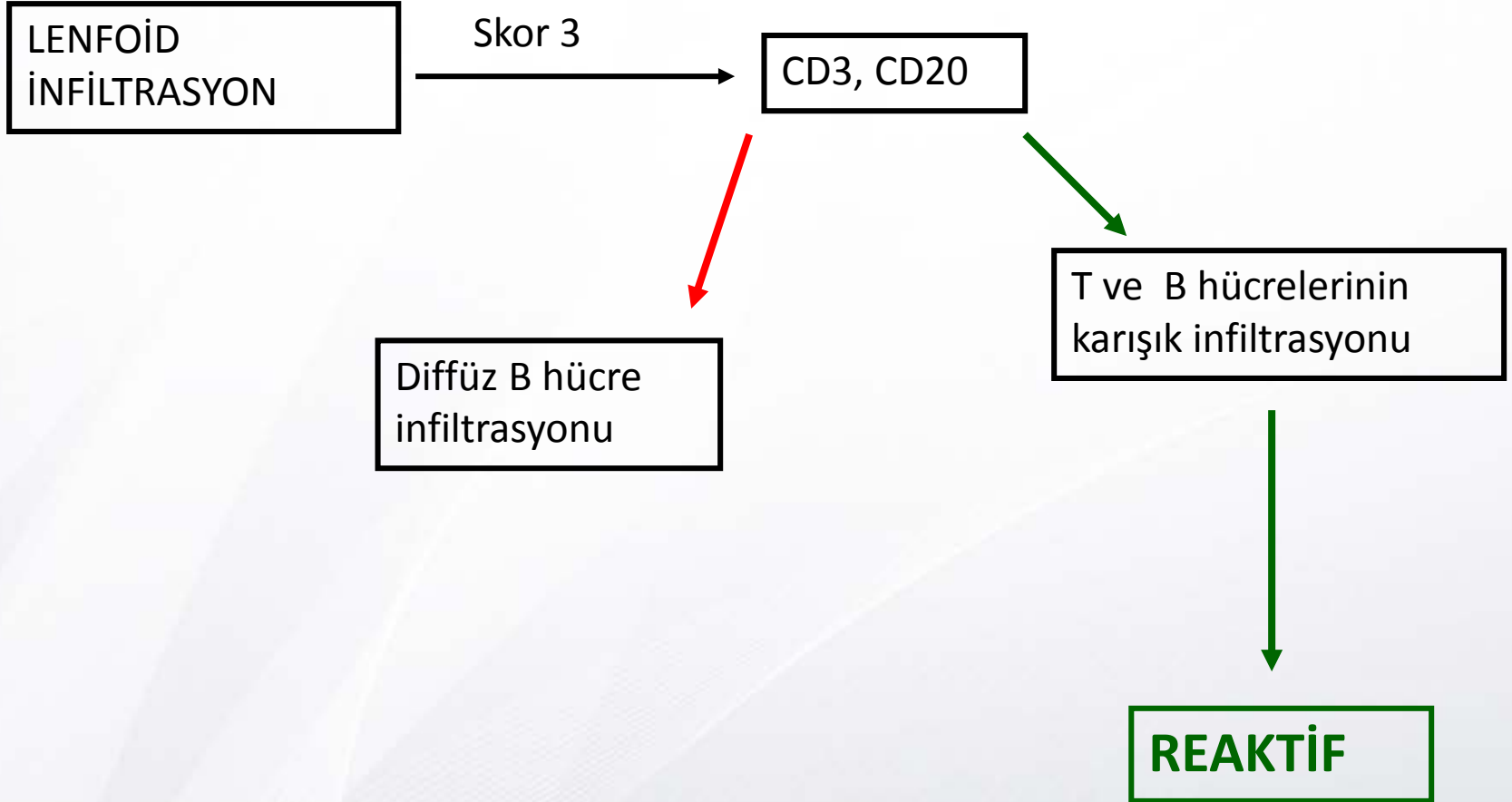
**25.** Ulusal Patoloji Kongresi  
**6.** Sitopatoloji Kongresi

14 - 17 Ekim 2015 / Merinos AKKM - BURSA

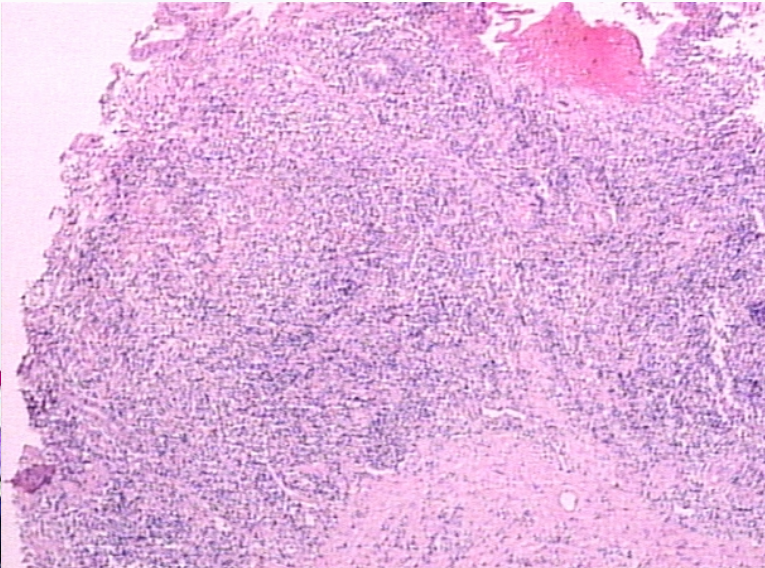
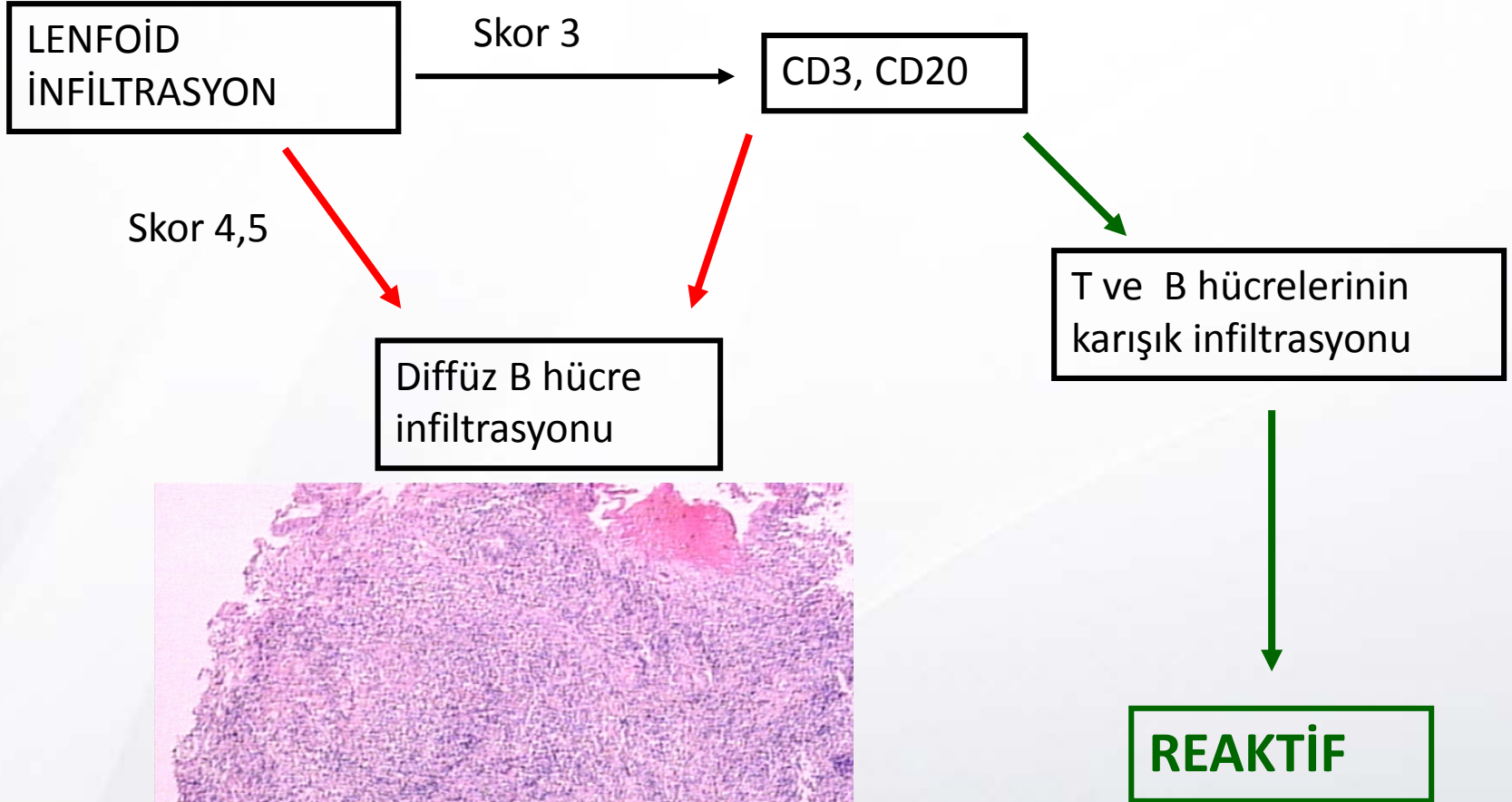
CD3



# MİDE MALT LENFOMALARINDA TANISAL YAKLAŞIMDA ALGORİTMA

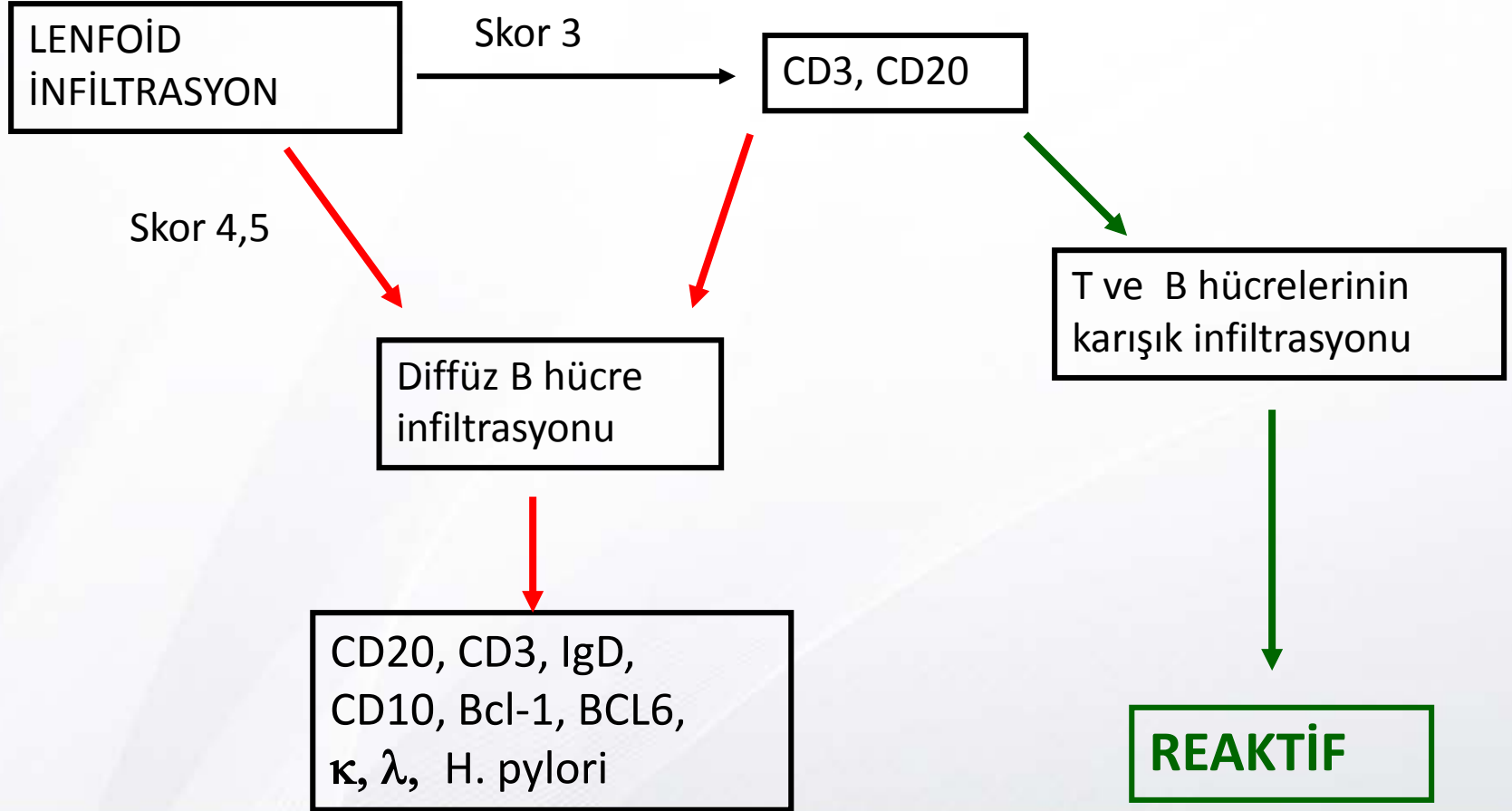


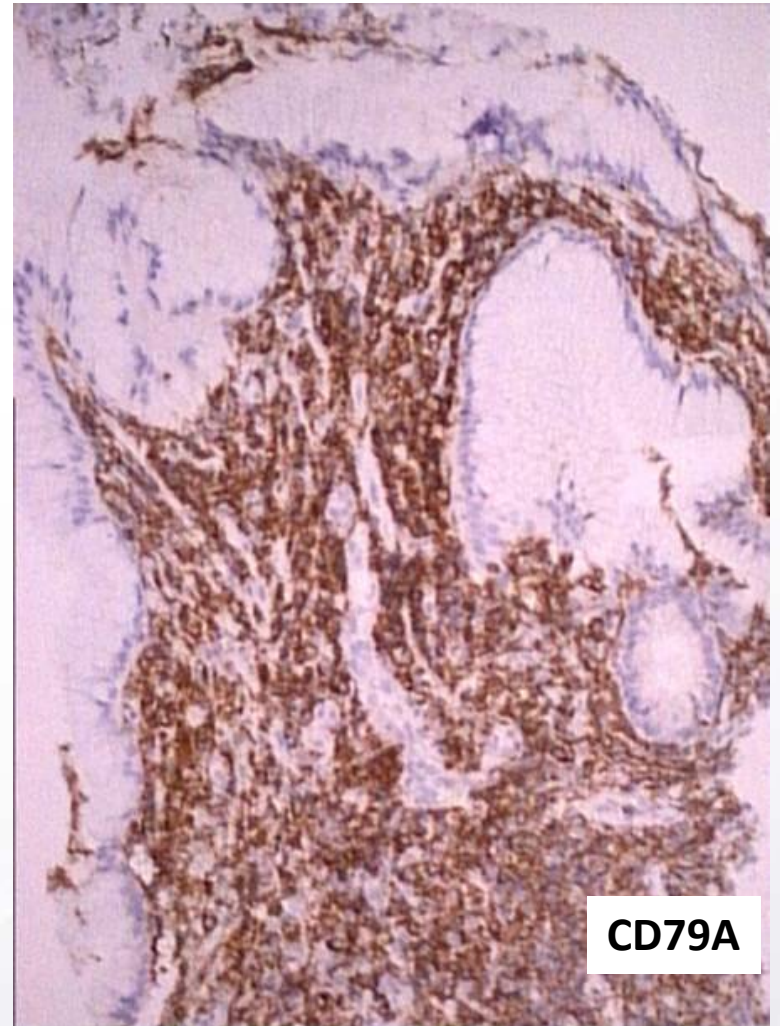
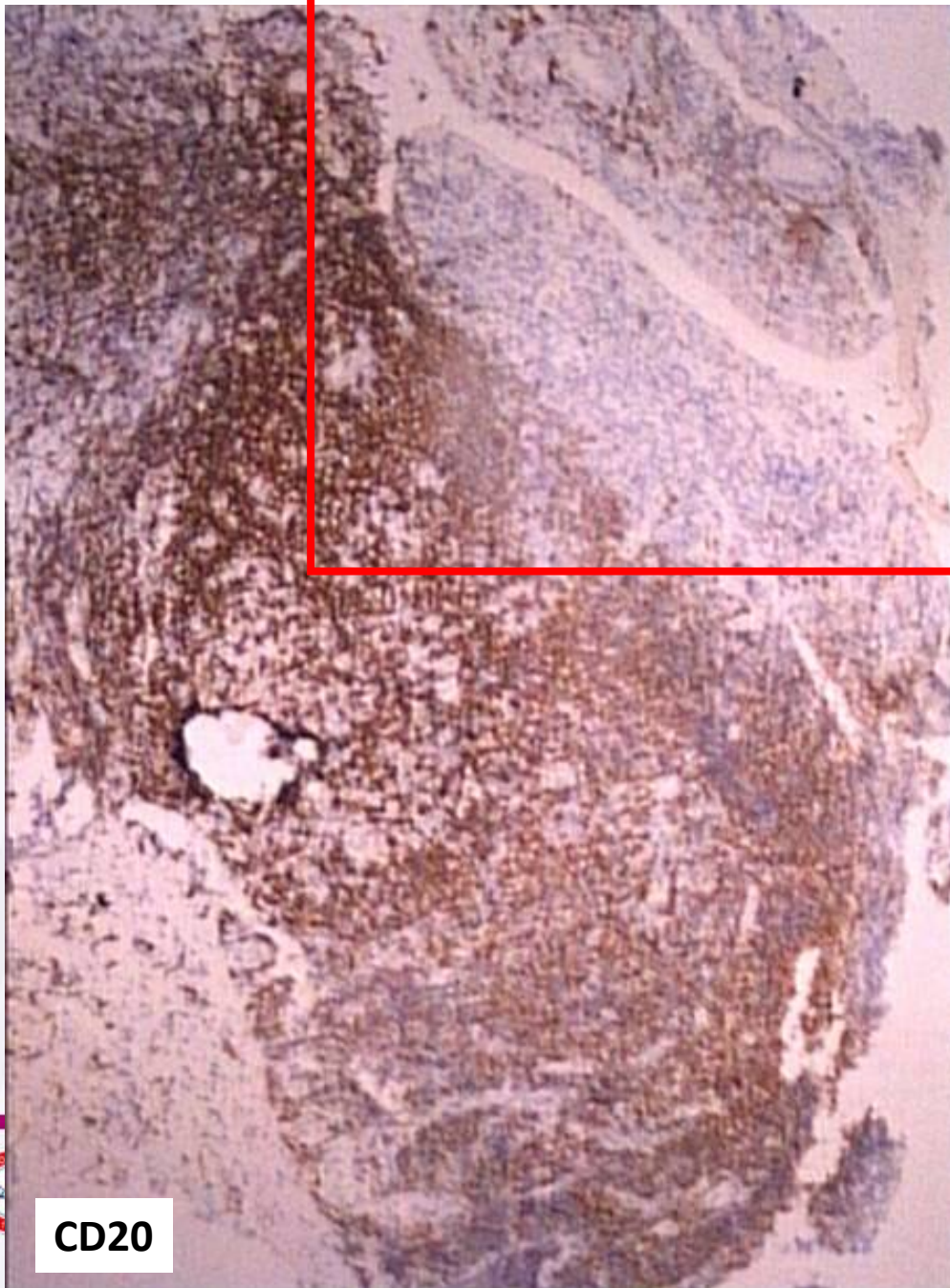
# MİDE MALT LENFOMALARINDA TANISAL YAKLAŞIMDA ALGORİTMA





# MİDE MALT LENFOMALARINDA TANISAL YAKLAŞIMDA ALGORİTMA

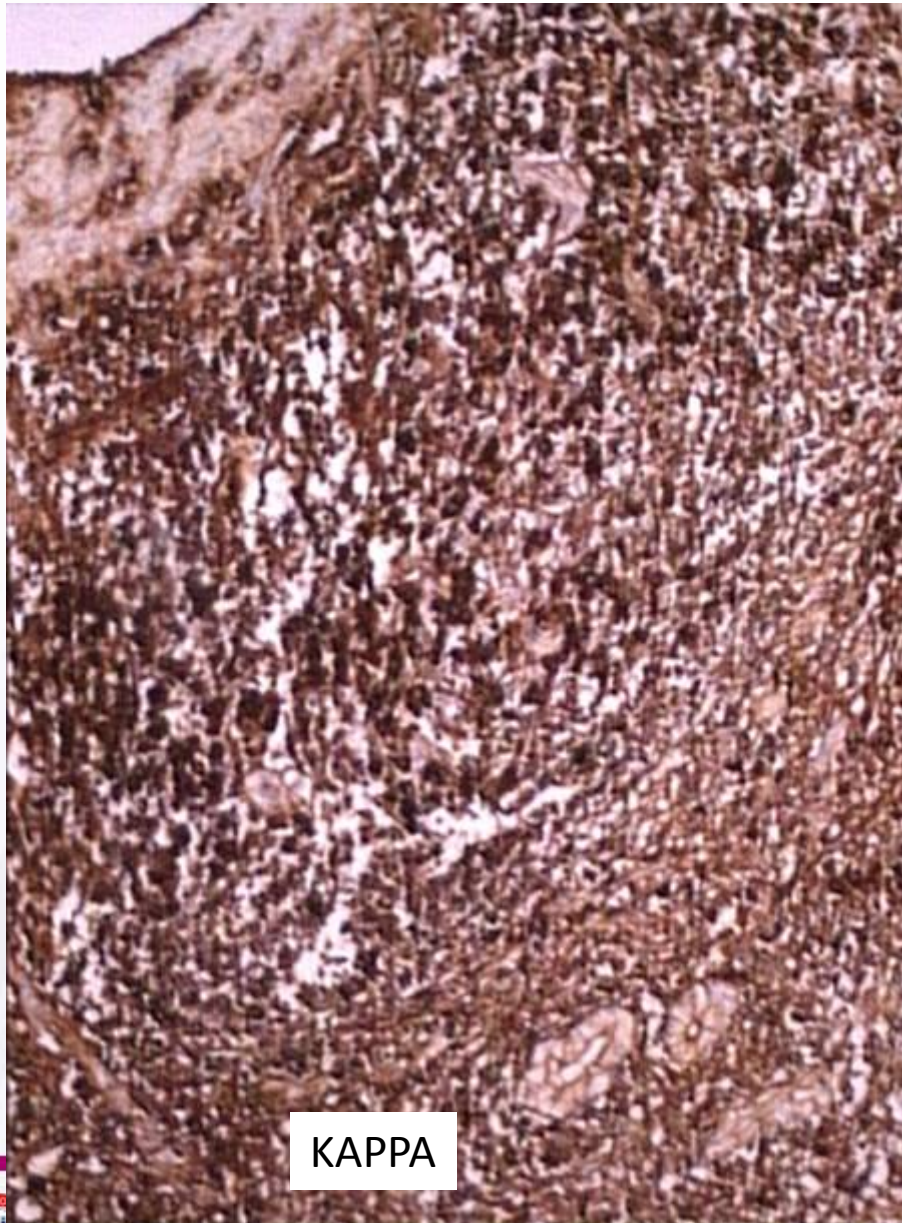




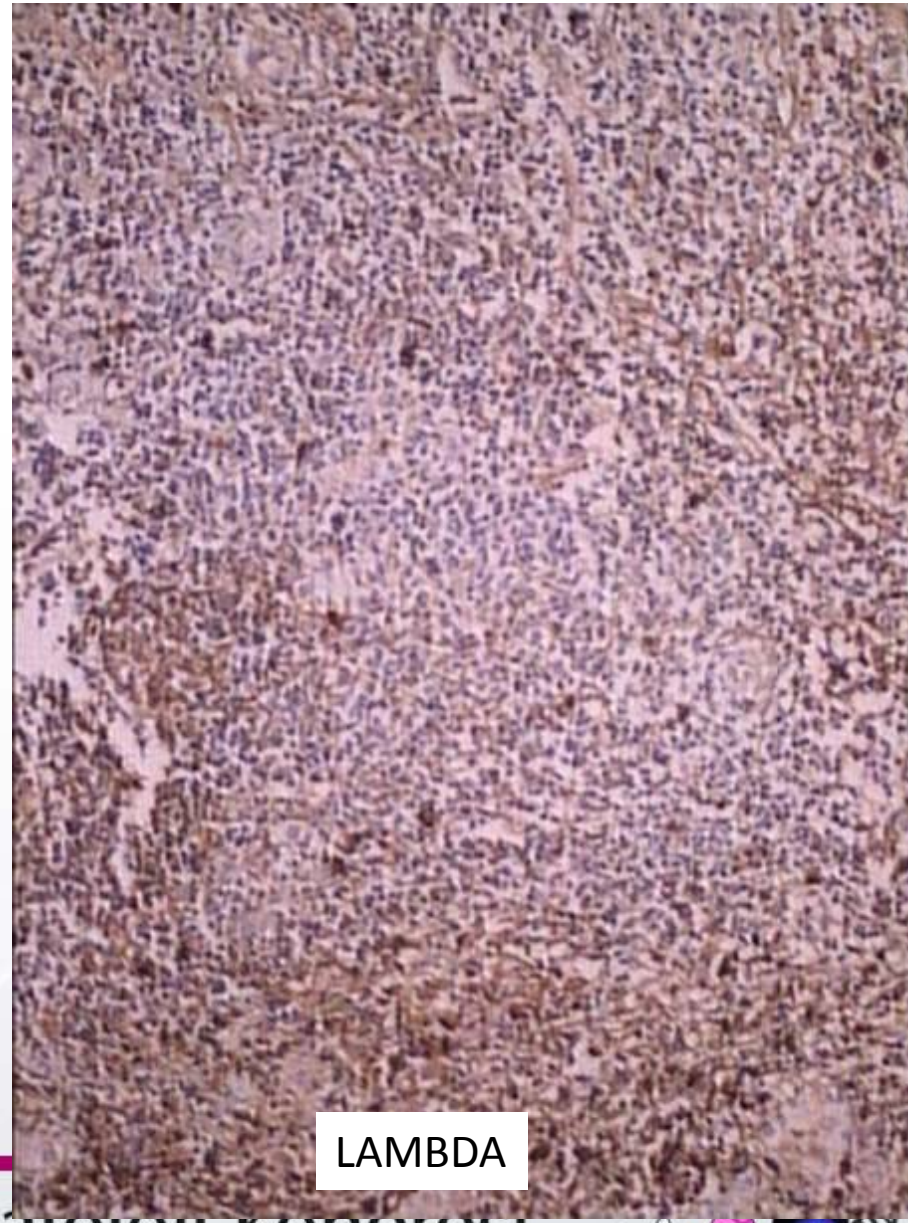
Patoloji Kongresi  
Onkoloji Kongresi

14 - 17 Ekim 2015 / Merinos AKKM - BURSA





KAPPA

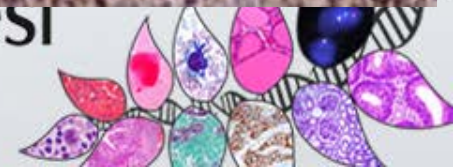

LAMBDA

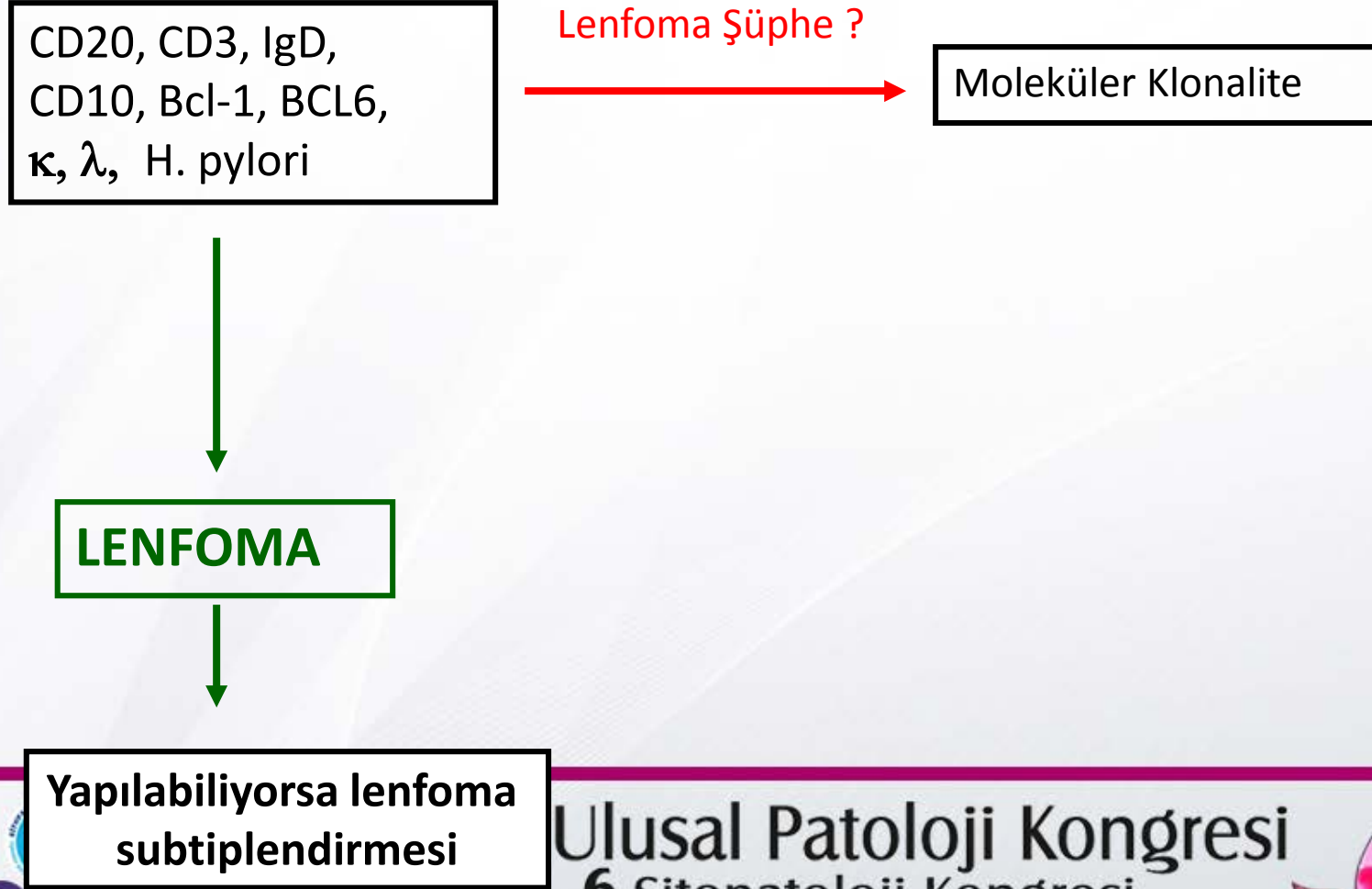


25 Bursa Patoloji Kongresi  
6. Sitopatoloji Kongresi

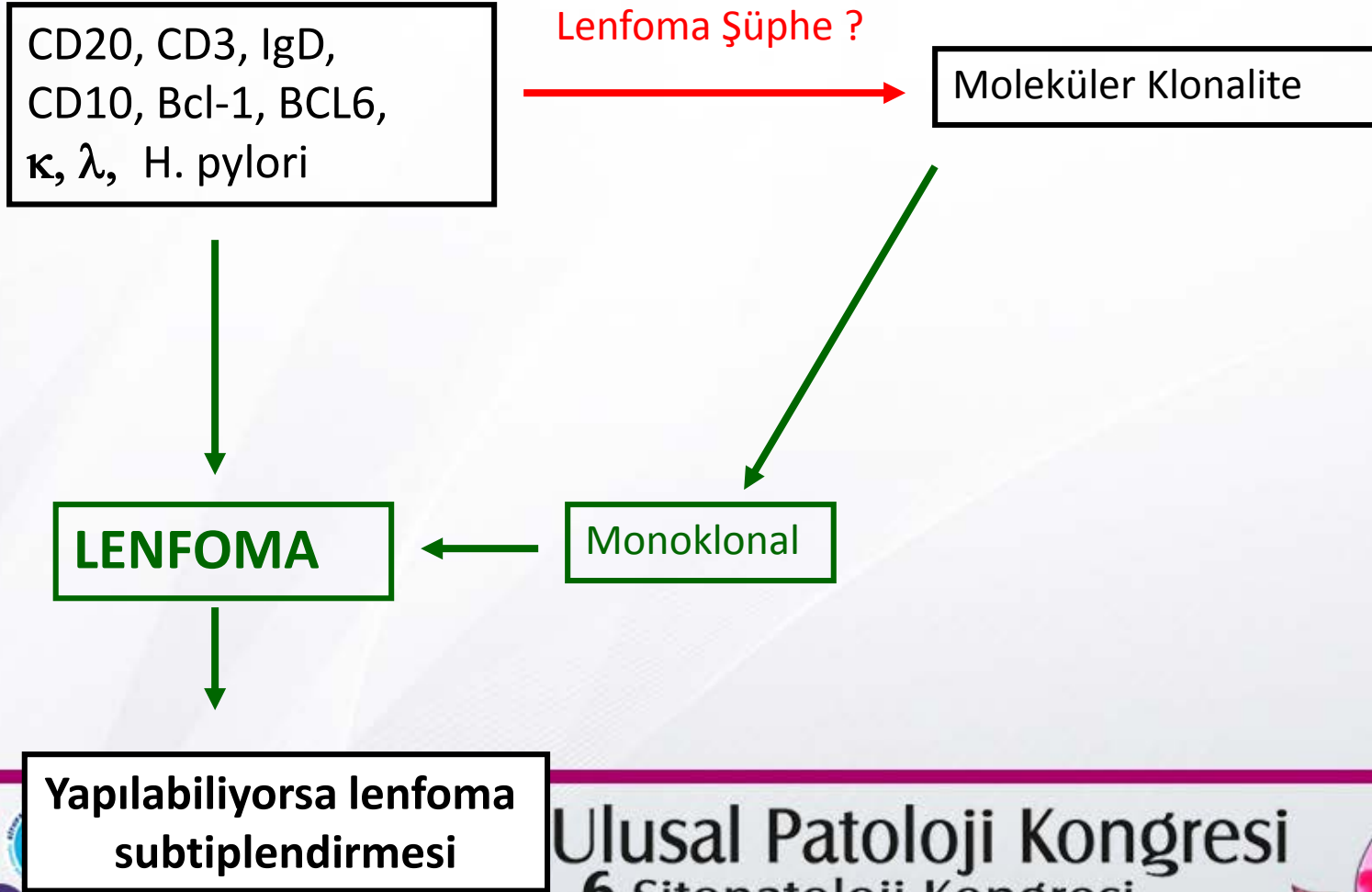
14 - 17 Ekim 2015 / Merinos AKKM - BURSA



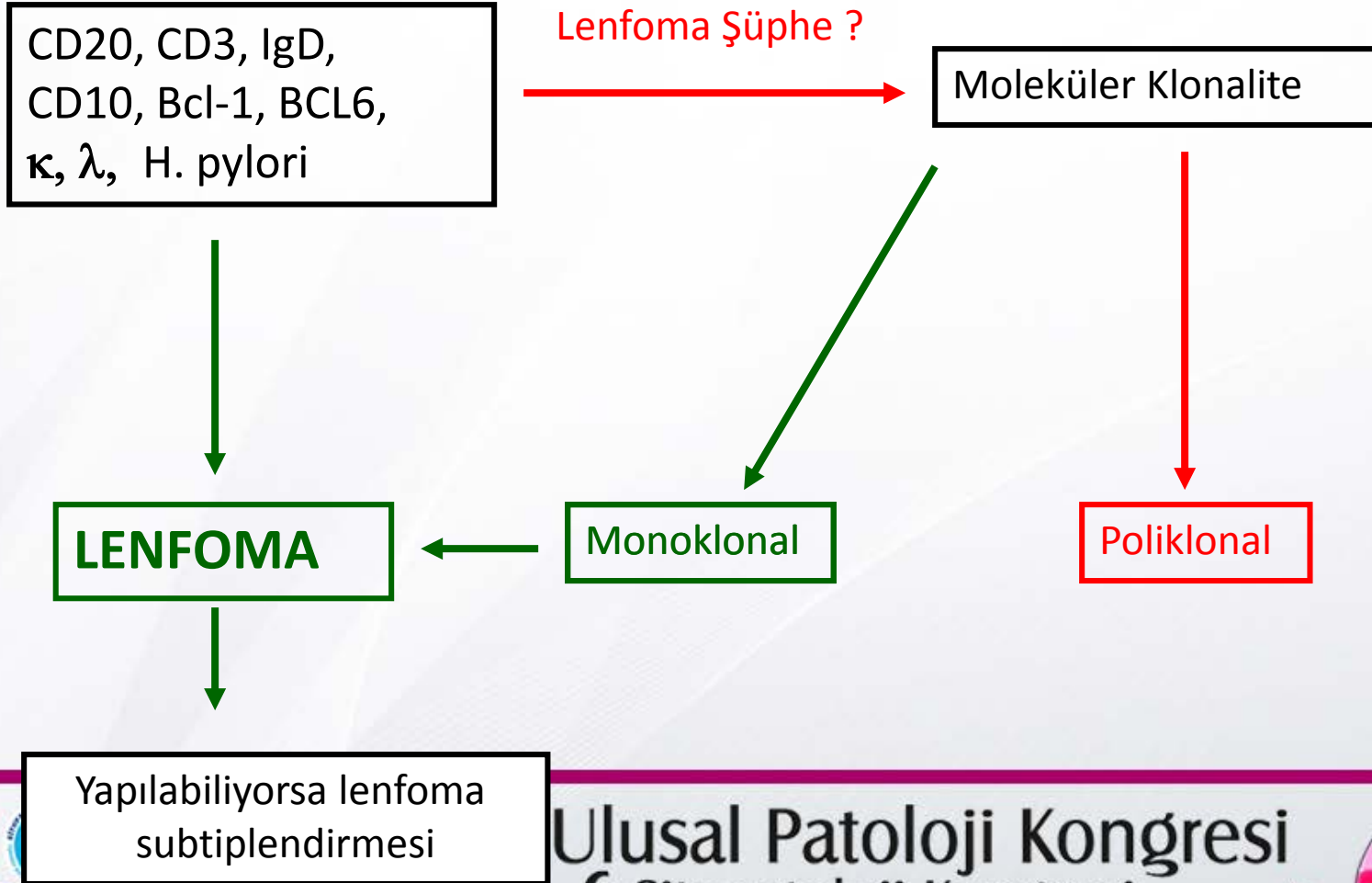
# MİDE MALT LENFOMALARINDA TANISAL YAKLAŞIMDA ALGORİTMA



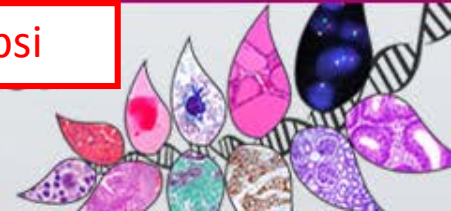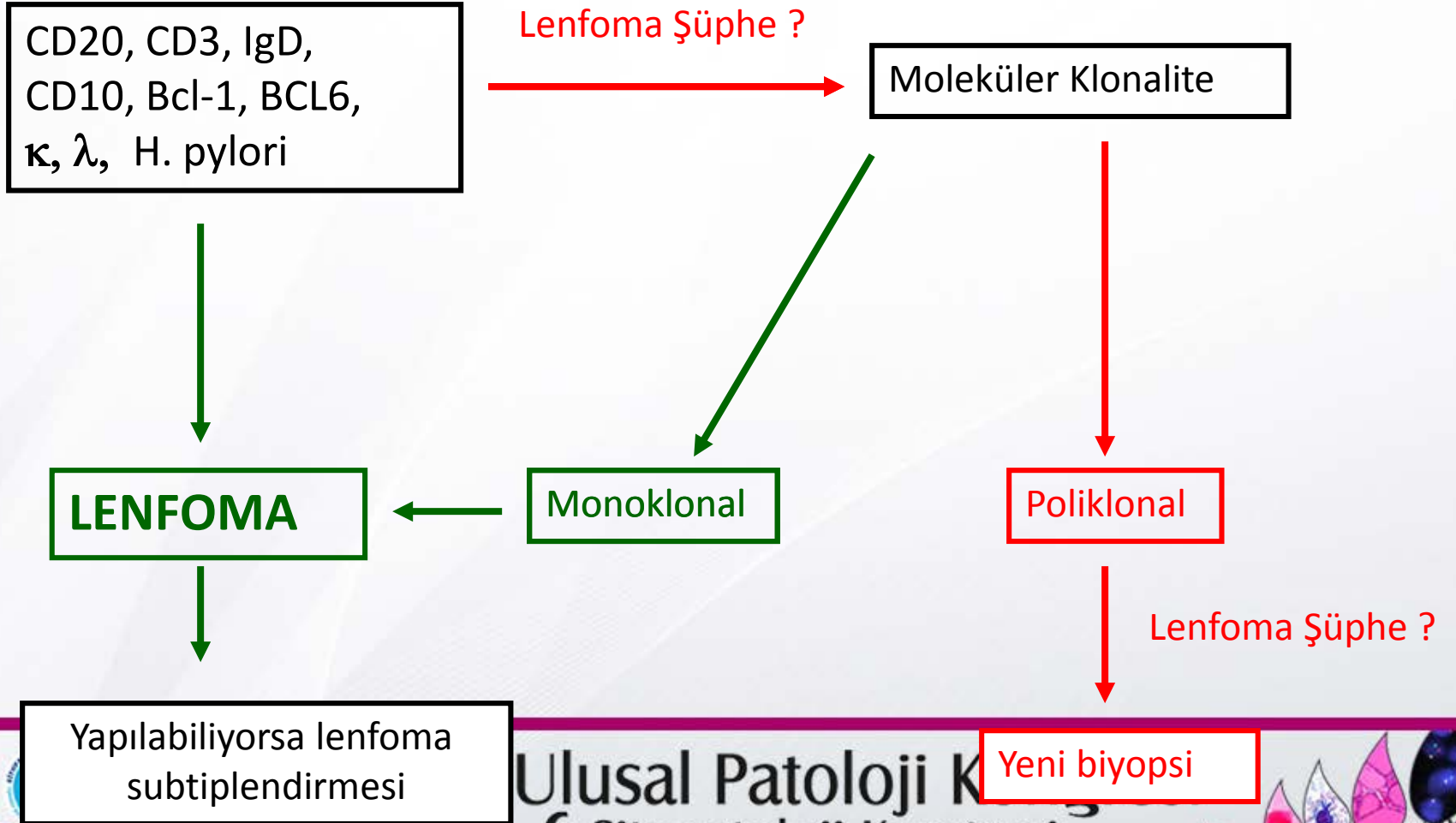
# MİDE MALT LENFOMALARINDA TANISAL YAKLAŞIMDA ALGORİTMA



# MİDE MALT LENFOMALARINDA TANISAL YAKLAŞIMDA ALGORİTMA



# MİDE MALT LENFOMALARINDA TANISAL YAKLAŞIMDA ALGORİTMA



**Table 1 Staging systems of gastric mucosa-associated lymphoid tissue lymphoma**

Lugano staging system for gastrointestinal lymphoma	TNM staging system modified for gastric lymphoma	Ann Arbor staging system modified by Musshoff	Tumor involvement
I = Confined to GI tract (single primary or multiple, noncontiguous)	T1 N0 M0 T2 N0 M0 T3 N0 M0	I <sub>E1</sub> I <sub>E2</sub>	Mucosa, submucosa Muscularis propria Serosa
II = Extending into abdomen			
II1 = Local nodal involvement	T1-3 N1 M0	II <sub>E1</sub>	Perigastric lymph nodes
II2 = Distant nodal involvement	T1-3 N2 M0	II <sub>E2</sub>	More distant regional lymph nodes
II E = Penetration of serosa to involve adjacent organs or tissues	T4 N0 M0	I <sub>E</sub>	Invasion of adjacent structures
IV = Disseminated extra-nodal involvement or concomitant supradiaphragmatic nodal involvement	T1-4 N3 M0 T1-4 N0-3 M1	III <sub>E</sub> IV <sub>E</sub>	Lymph nodes on both sides of the diaphragm Distant metastases (e.g., bone marrow or additional extranodal sites)

GI: Gastrointestinal; TNM: Tumor node metastasis.

Chun *World J Gastroenterol* 2014



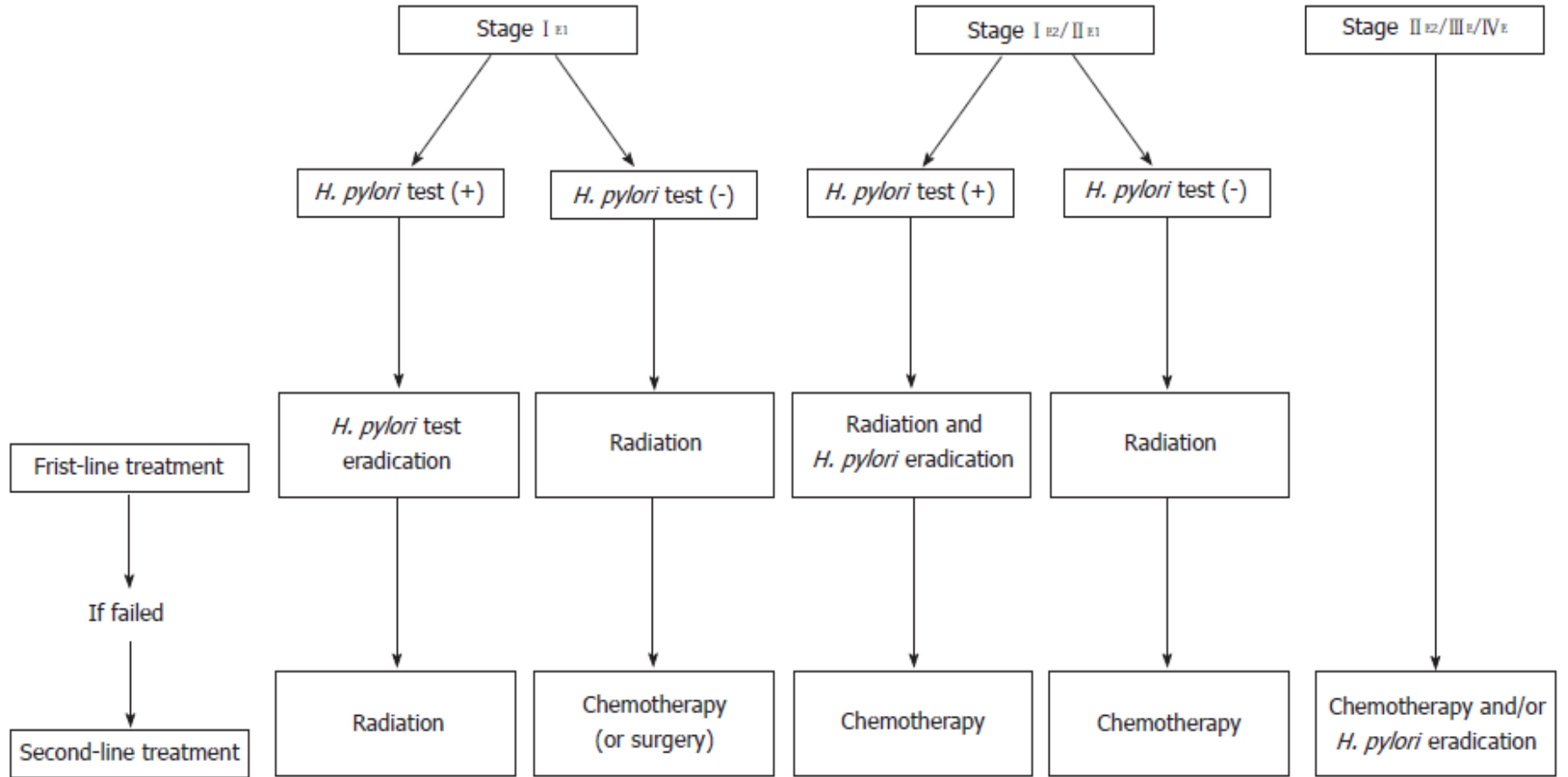
**25** Ulusal Patoloji Kongresi  
**6** Sitopatoloji Kongresi

14 - 17 Ekim 2015 / Merinos AKKM - BURSA





# TEDAVİ YAKLAŞIMI



Chun World J Gastroenterol 2014



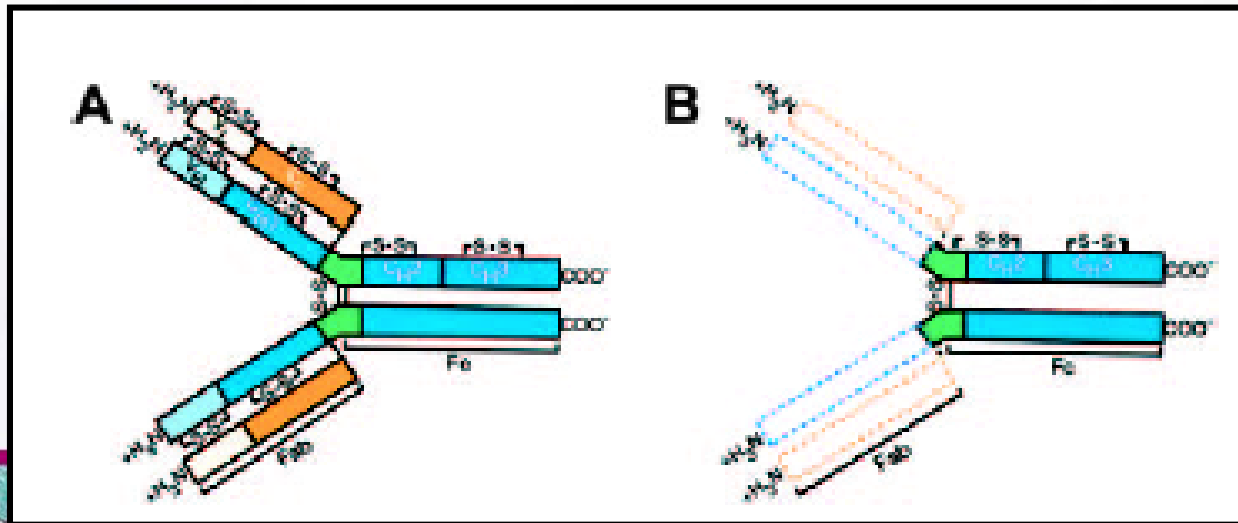
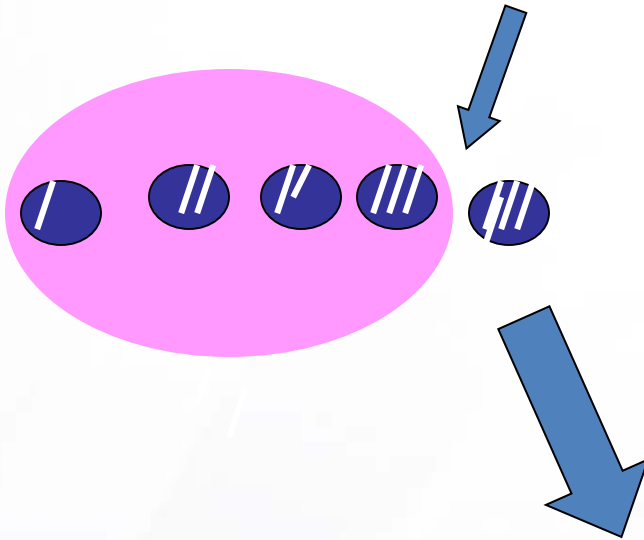
**25.** Ulusal Patoloji Kongresi  
**6.** Sitopatoloji Kongresi

14 - 17 Ekim 2015 / Merinos AKKM - BURSA



C jejuni

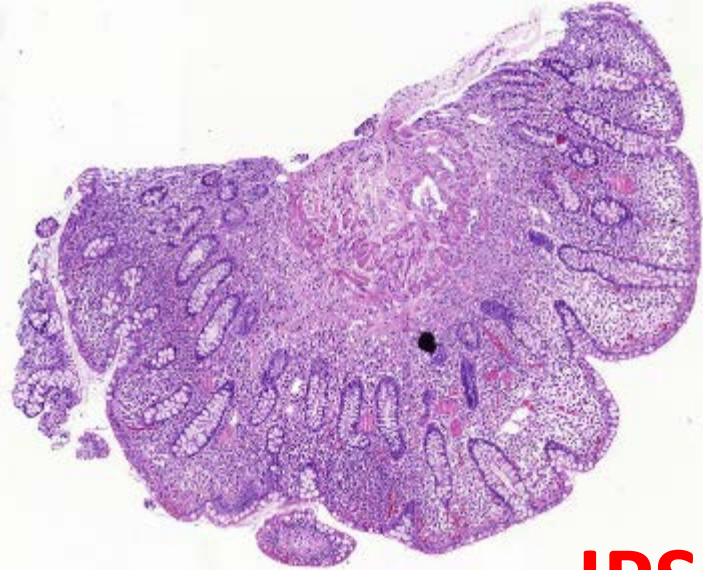
IPSID



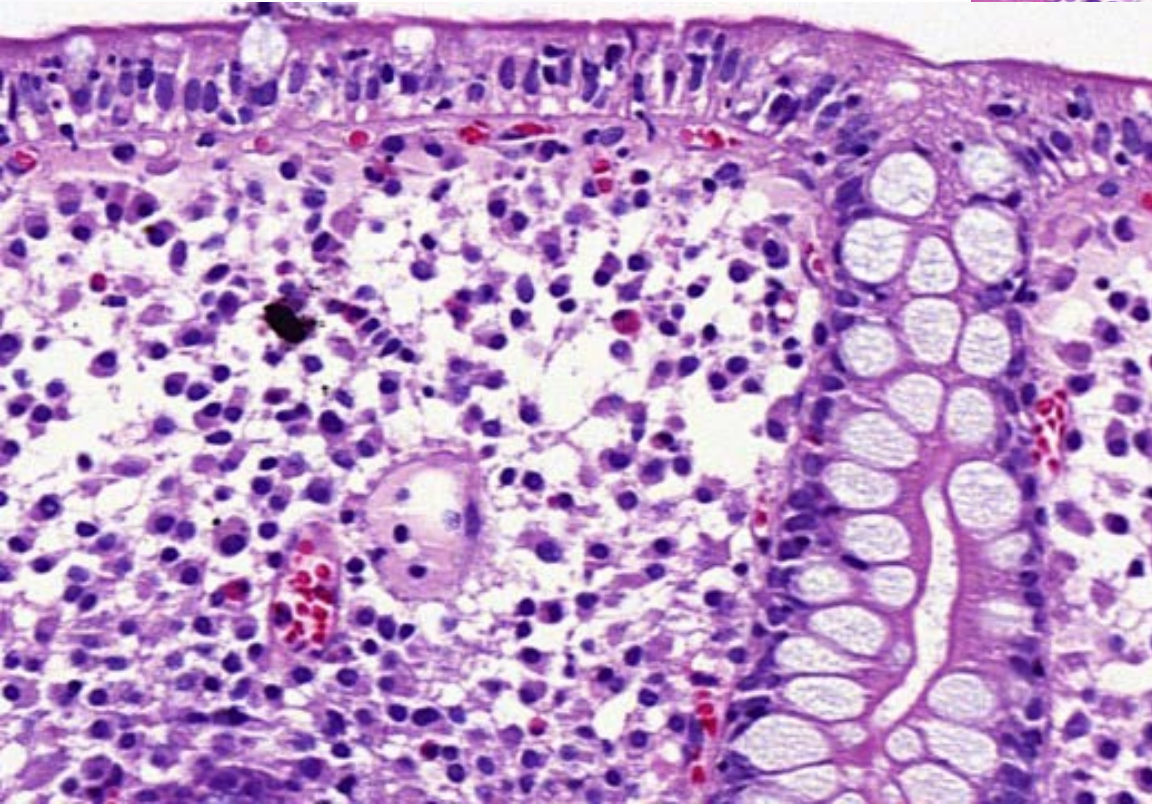
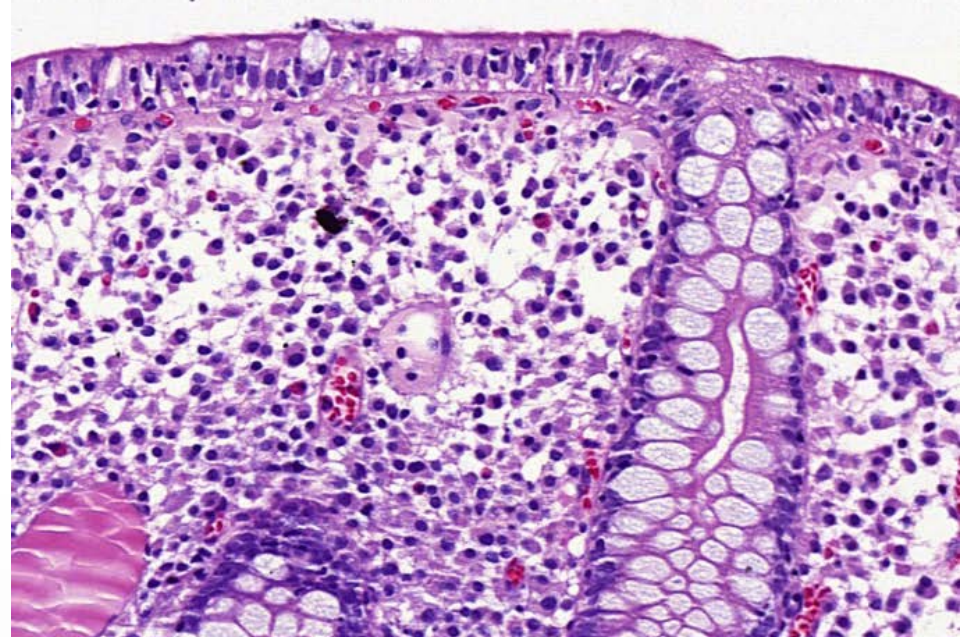25. Bursa Patoloji Kongresi  
6. Sitopatoloji Kongresi  
Blood 2005; 105; 2274-80

14 - 17 Ekim 2015 / Merinos AKKM - BURSA



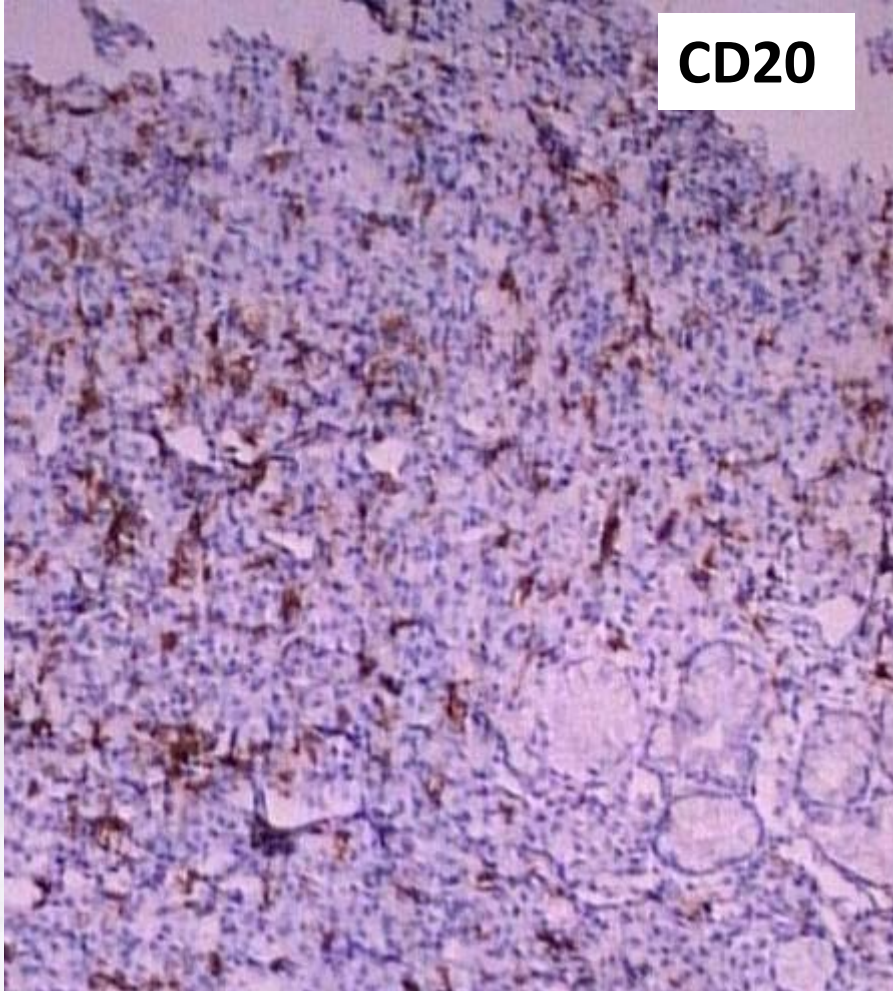


**IPSID**

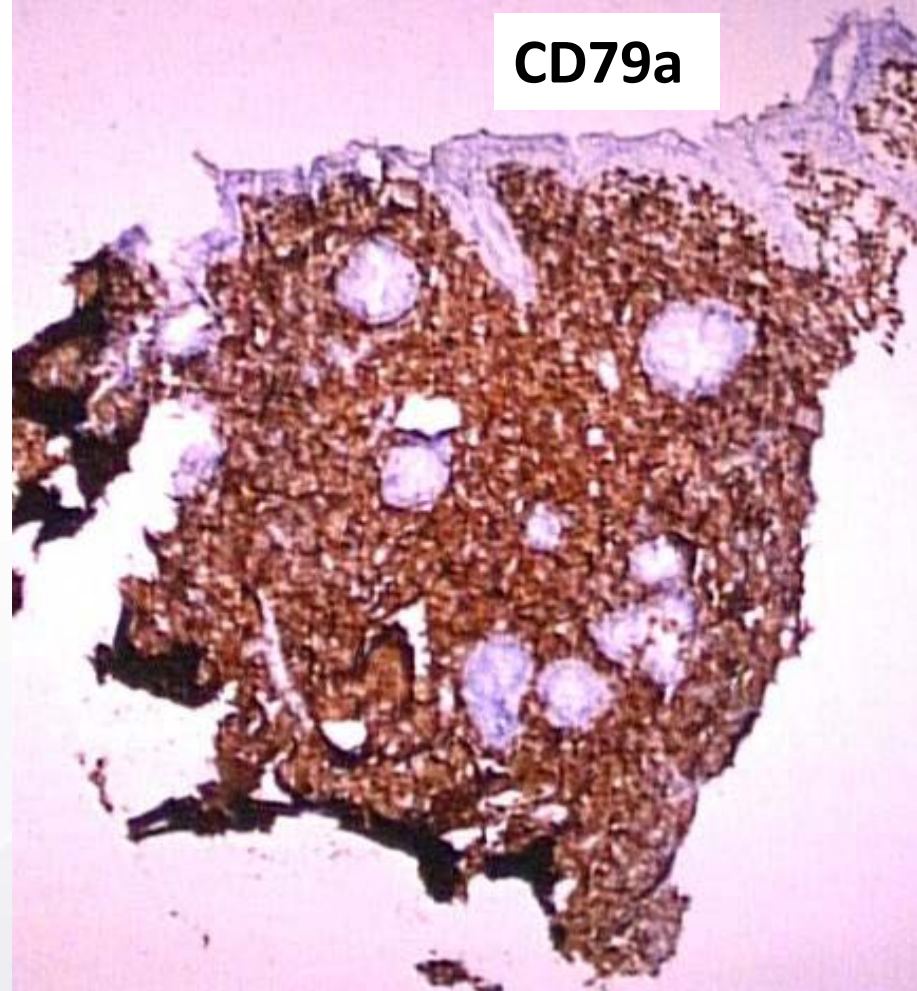


# IPSID

CD20



CD79a



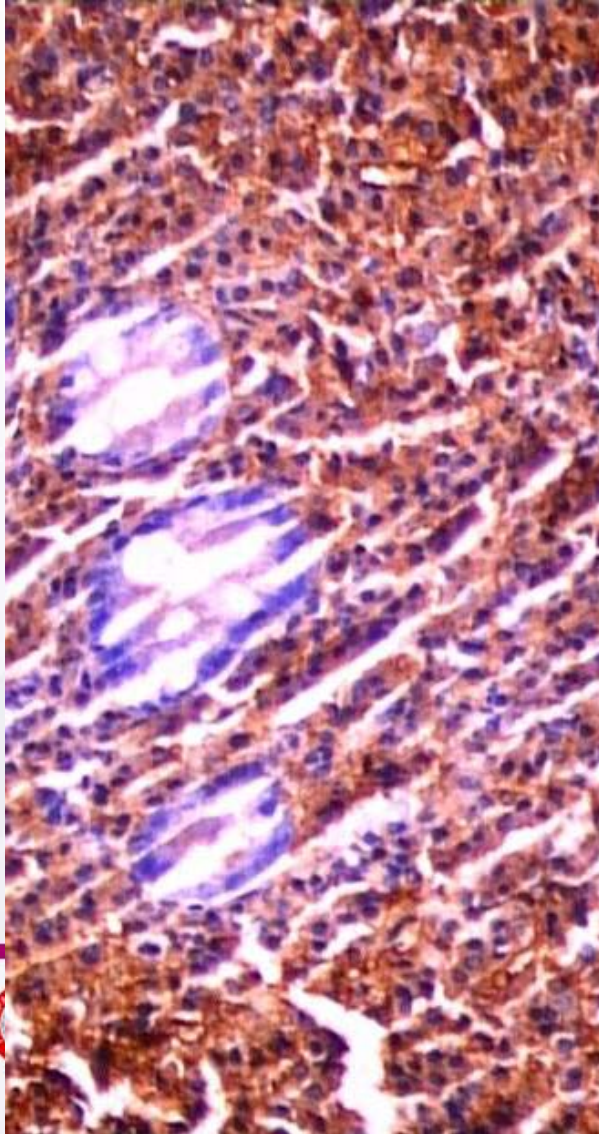
**25** Ulusal Patoloji Kongresi  
**6.** Sitopatoloji Kongresi

14 - 17 Ekim 2015 / Merinos AKKM - BURSA

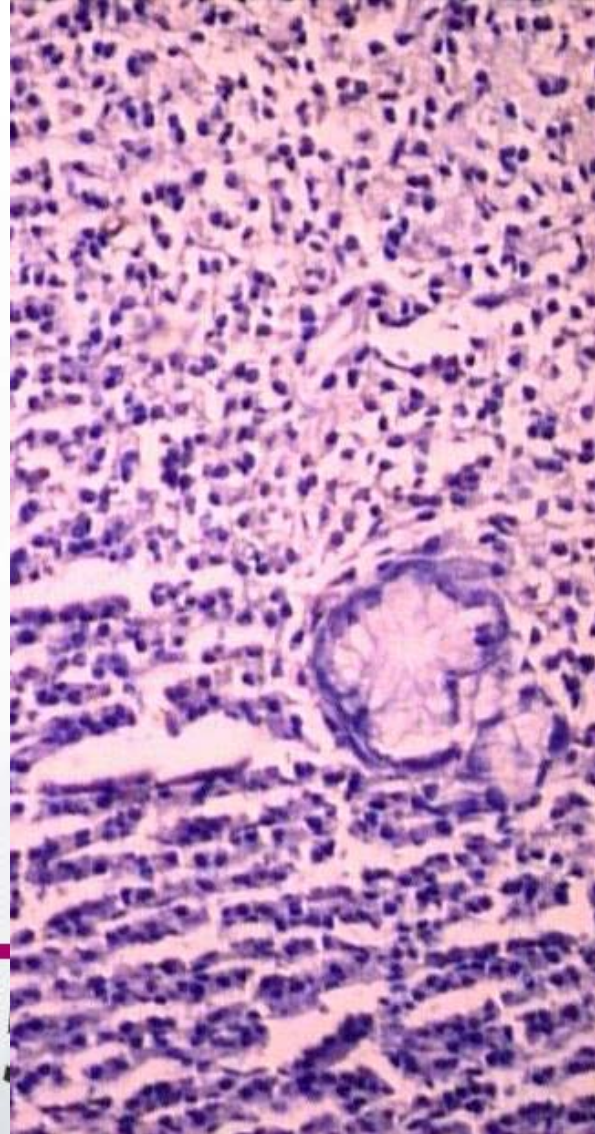


# IPSID

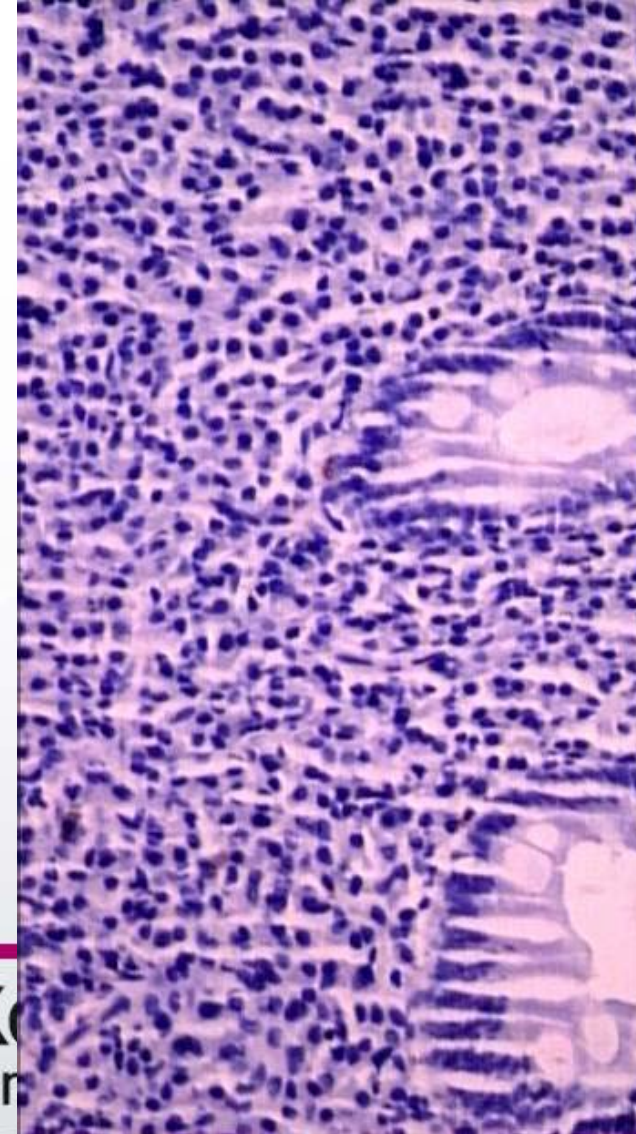
IgA



LAMBDA



KAPPA



# İMMUNFENOTİPİK AYIRICI TANI

- MALT LENFOMA (MALT)
- FOLLİKÜLER LENFOMA (FL)
- MANTLE CELL LENFOMA (MCL)
- DİFFÜZ BÜYÜK B HÜCRELİ LENFOMA (DLBCL)
- REAKTİF FOLLİKÜL (reaktif)



**25** Ulusal Patoloji Kongresi  
**6.** Sitopatoloji Kongresi

14 - 17 Ekim 2015 / Merinos AKKM - BURSA

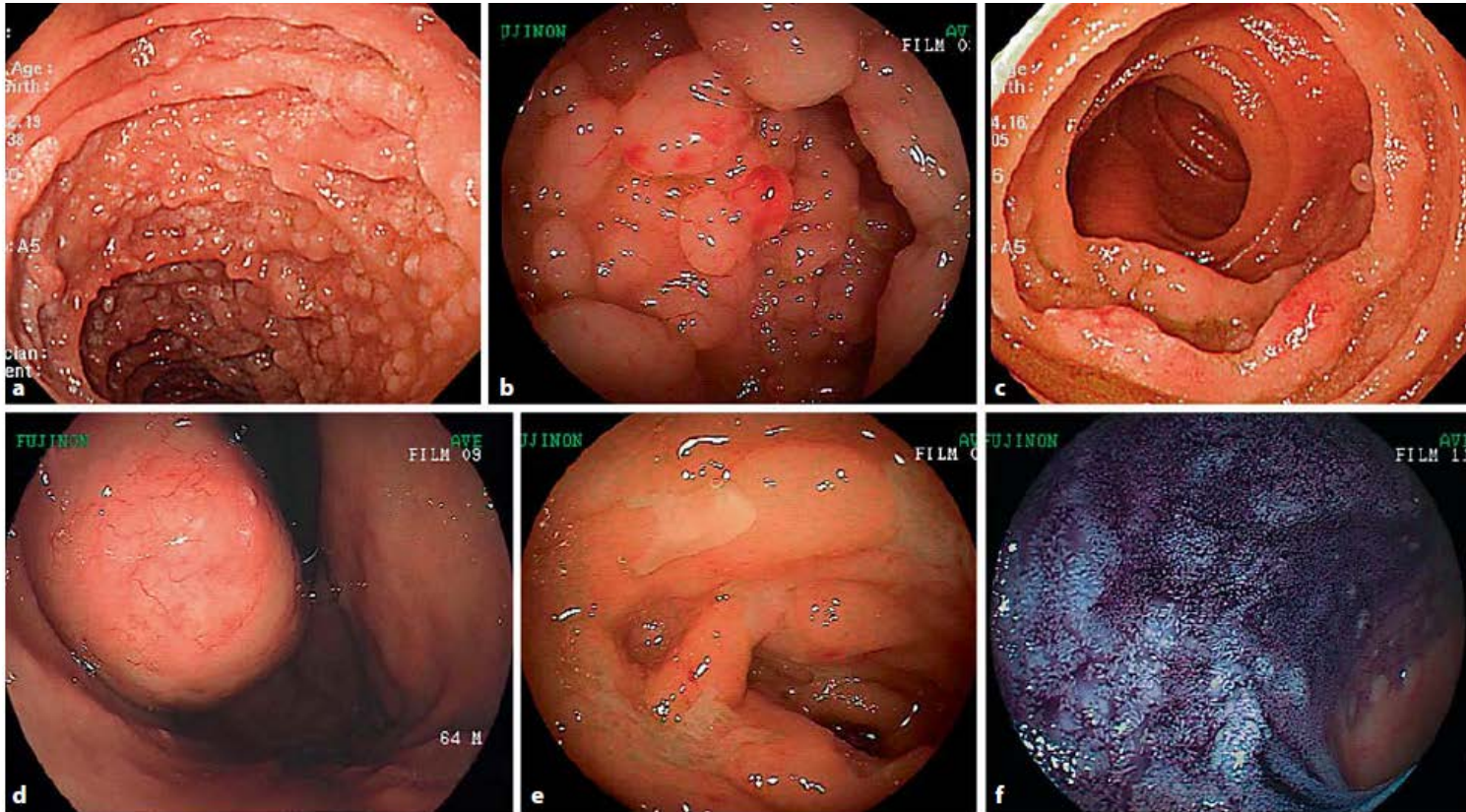


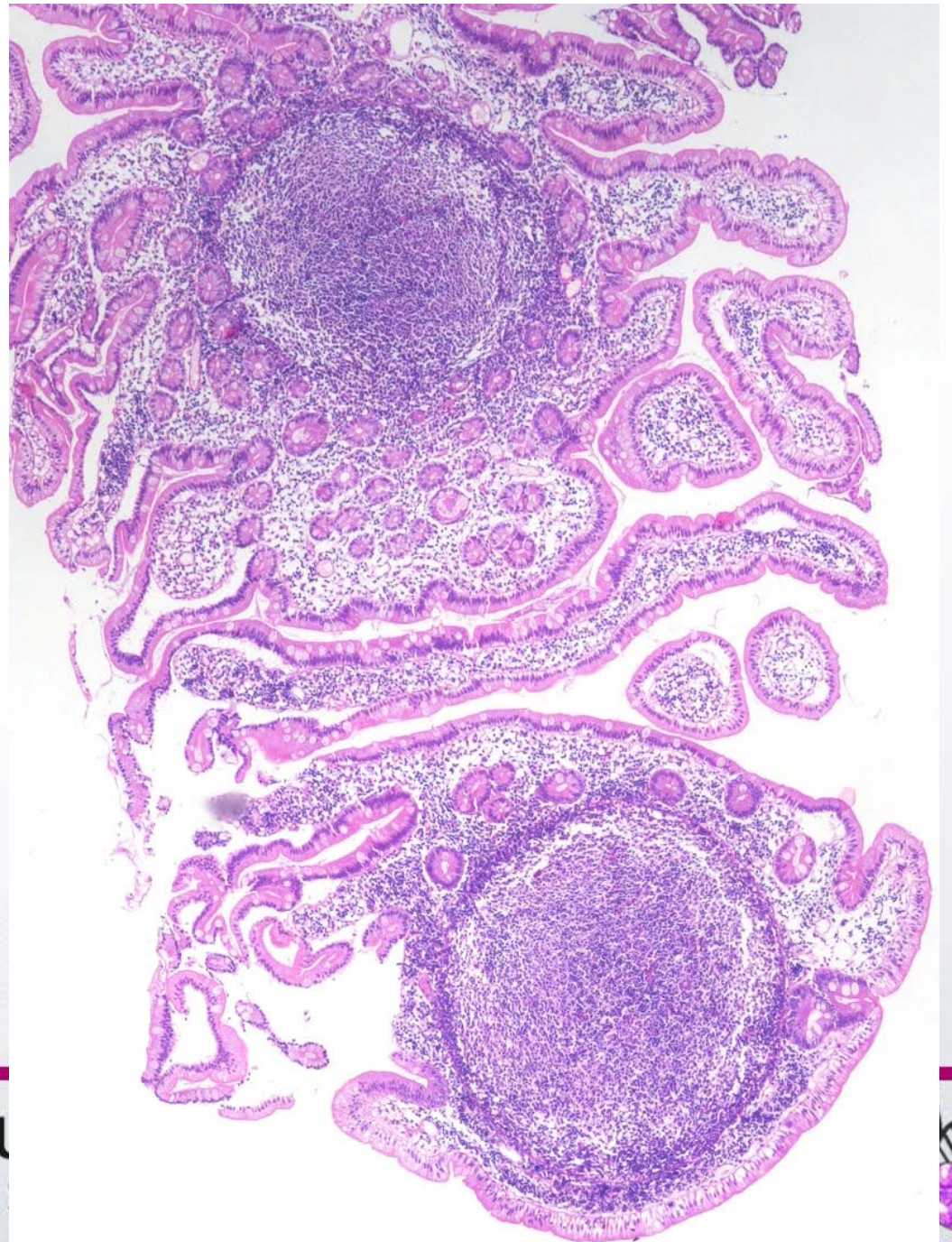
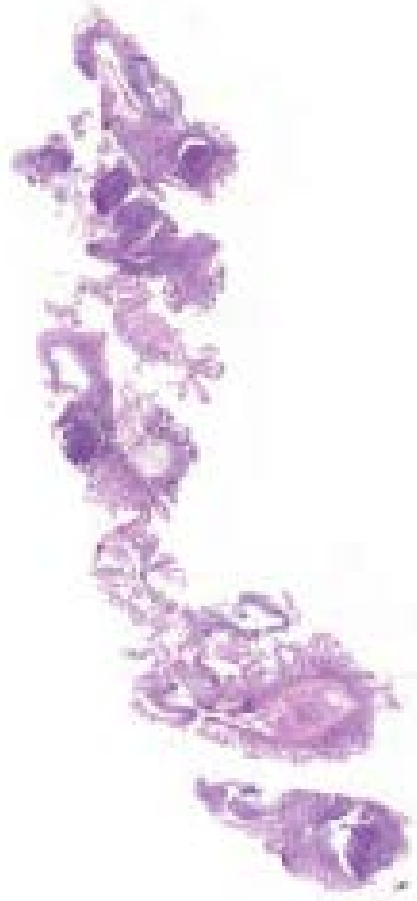# Birincil GIS Foliküler Lenfoma (FL)

GIS lenfomaları arasında 1–9% .

Uzak doğu- Japonya kaynaklı seriler.

Duodenum >İleum> Jejenum>Mide=Kolon=Rektum

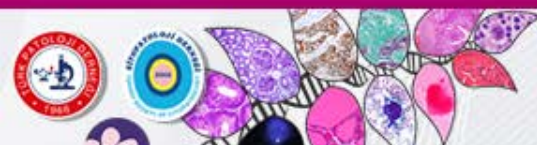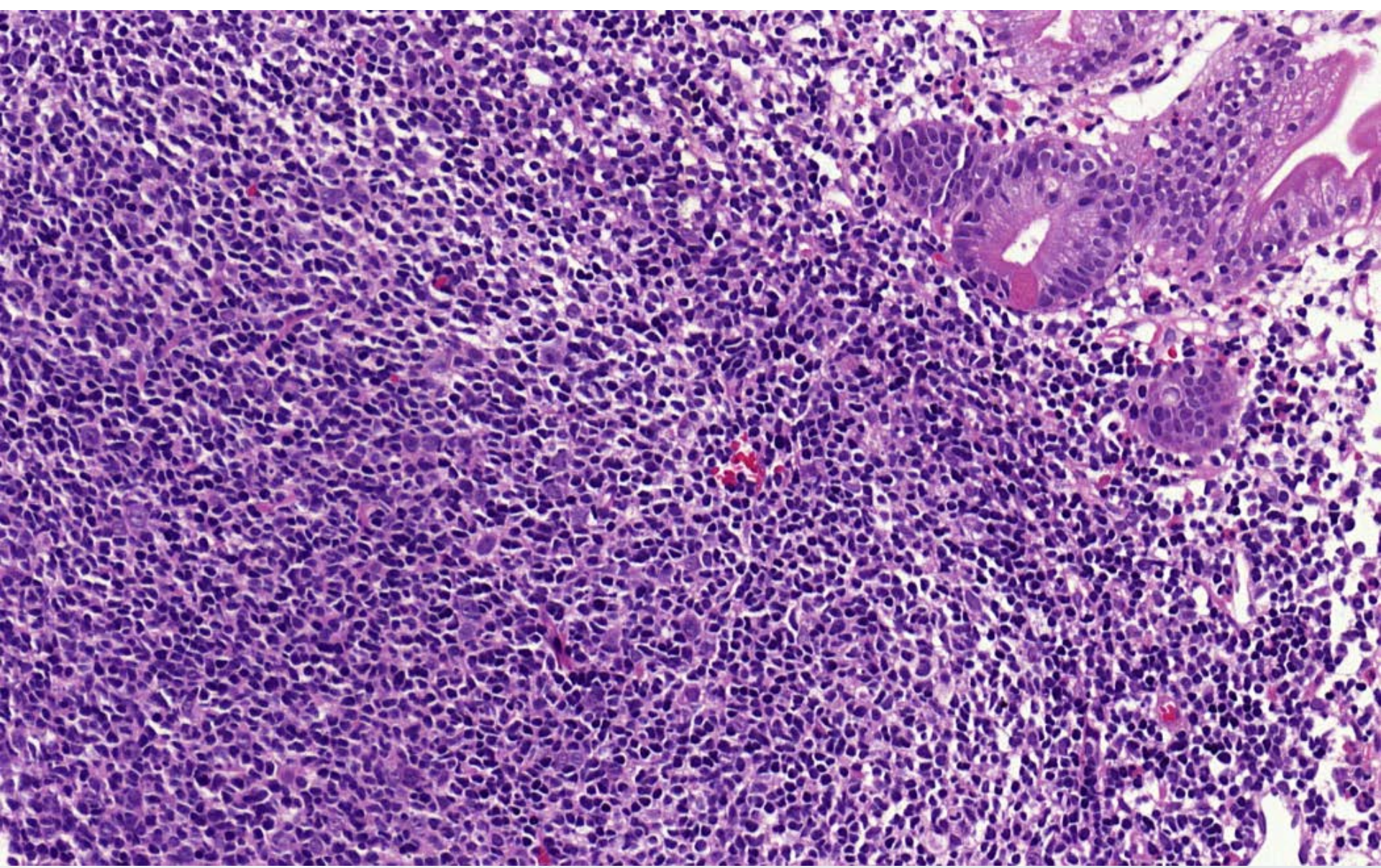




25. Ulu  
6.

14 - 17 EKİM 2015 / MERİTOS AKKM - BURSA

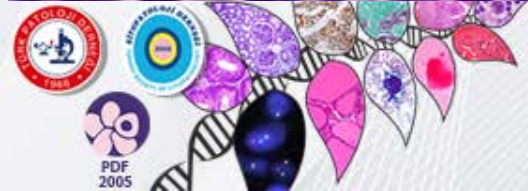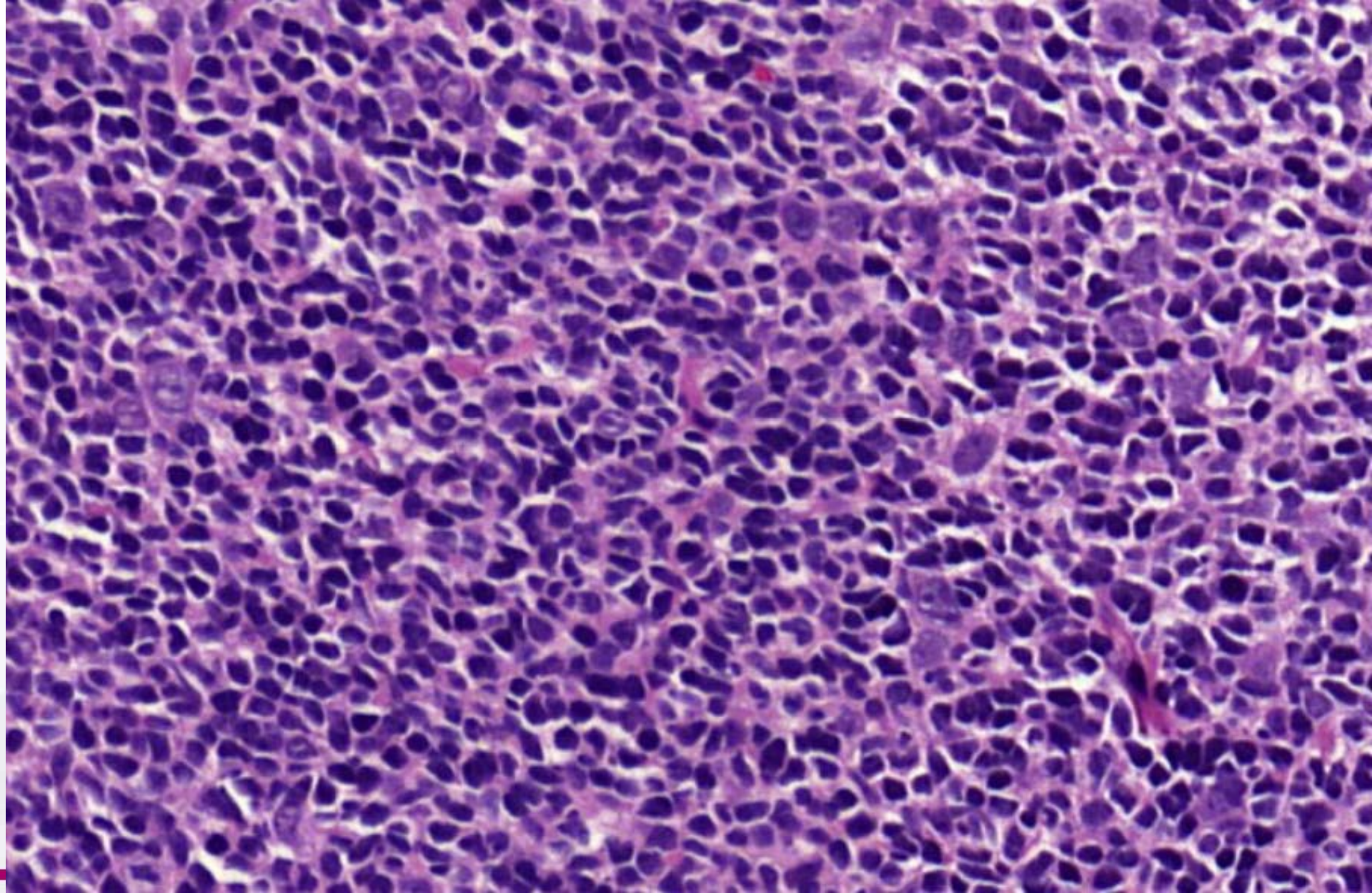




**25** Ulusal Patoloji Kongresi  
**6.** Sitopatoloji Kongresi

14 - 17 Ekim 2015 / Merinos AKKM - BURSA

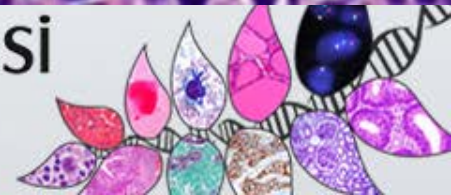



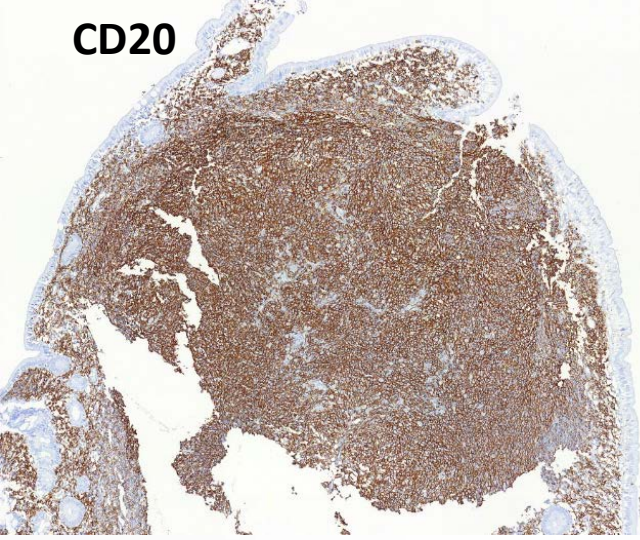
# 25. Ulusal Patoloji Kongresi

## 6. Sitopatoloji Kongresi

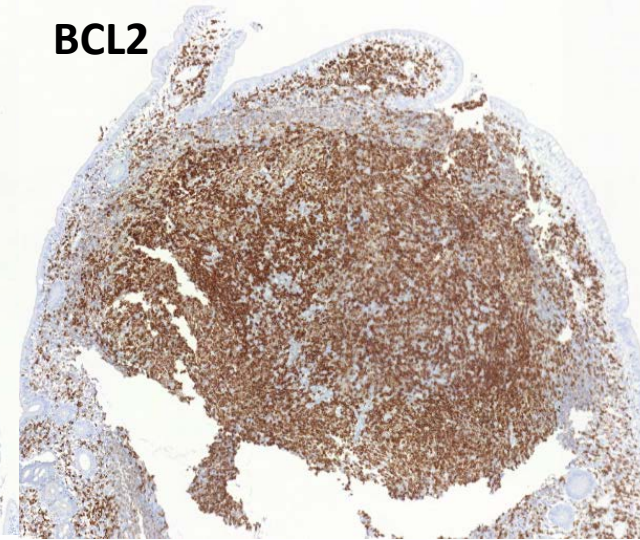
14 - 17 Ekim 2015 / Merinos AKKM - BURSA



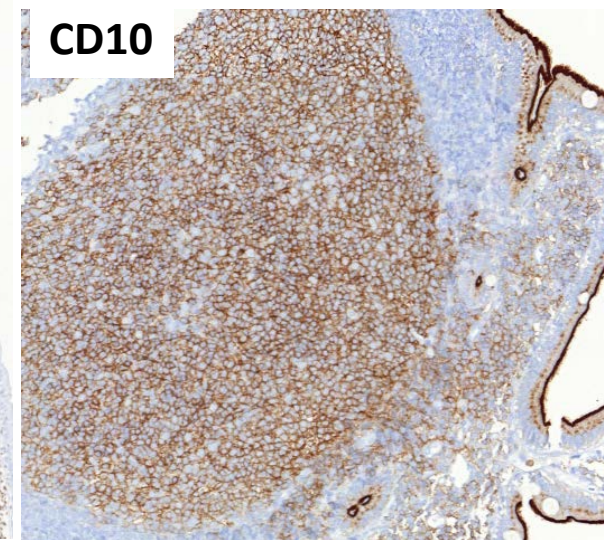
CD20



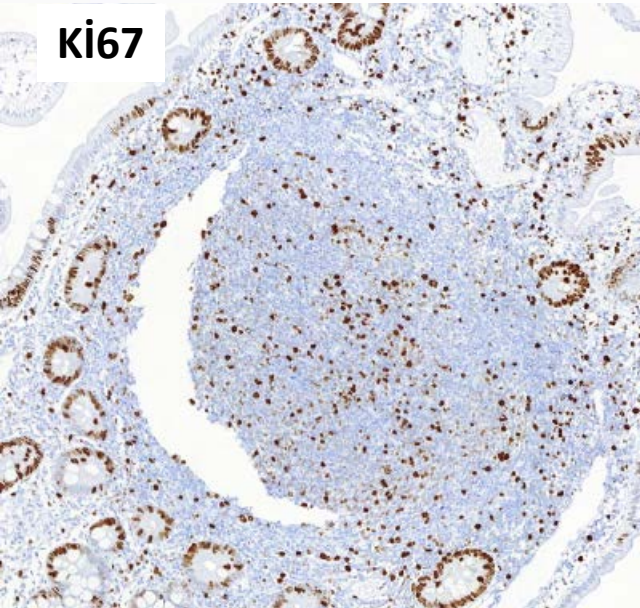
BCL2



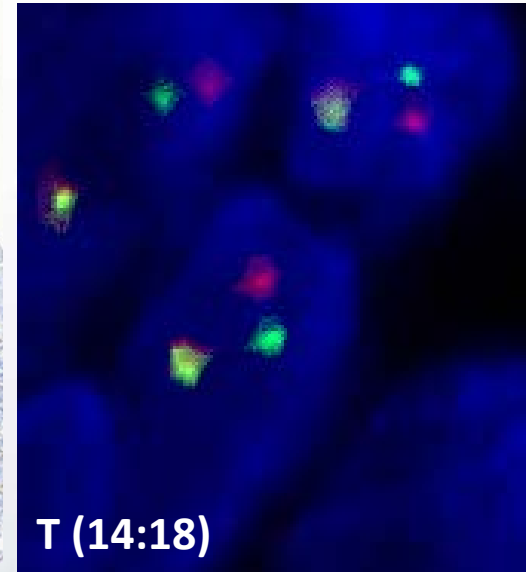
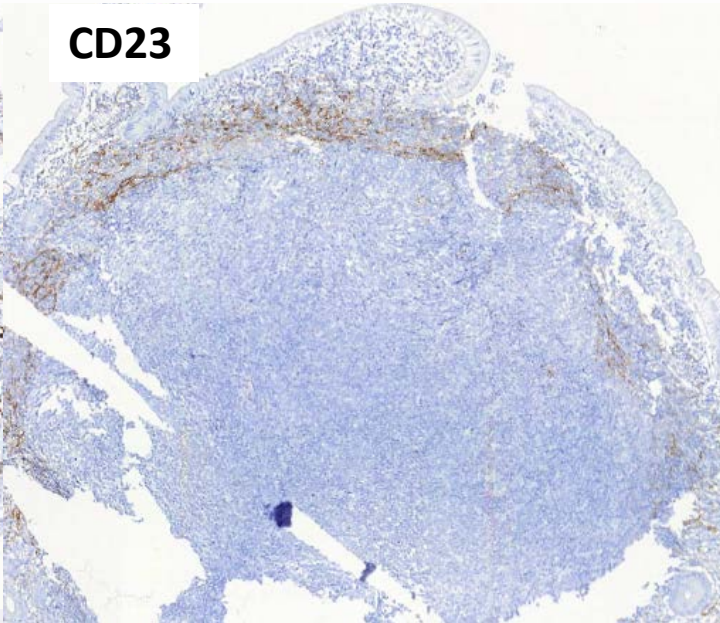
CD10



Ki67



CD23



T (14:18)



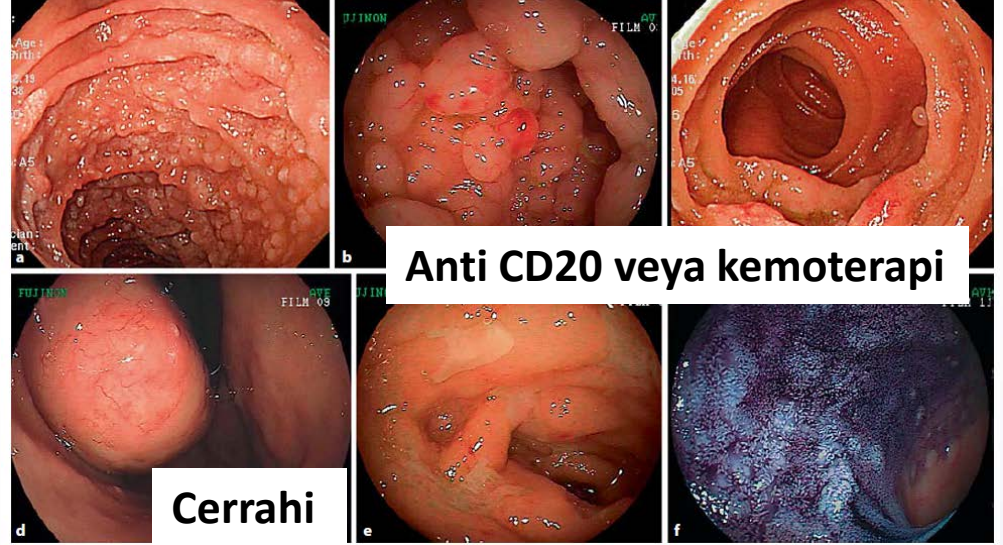
**25** Ulusal Patoloji Kongresi  
**6** Sitopatoloji Kongresi

14 - 17 Ekim 2015 / Merinos AKKM - BURSA



# Birincil GIS Folliküler Lenfoma (FL) Klinik

Genellikle Grd 1-2 ve lokalize kalma eğiliminde  
Sistemik yayılım yok

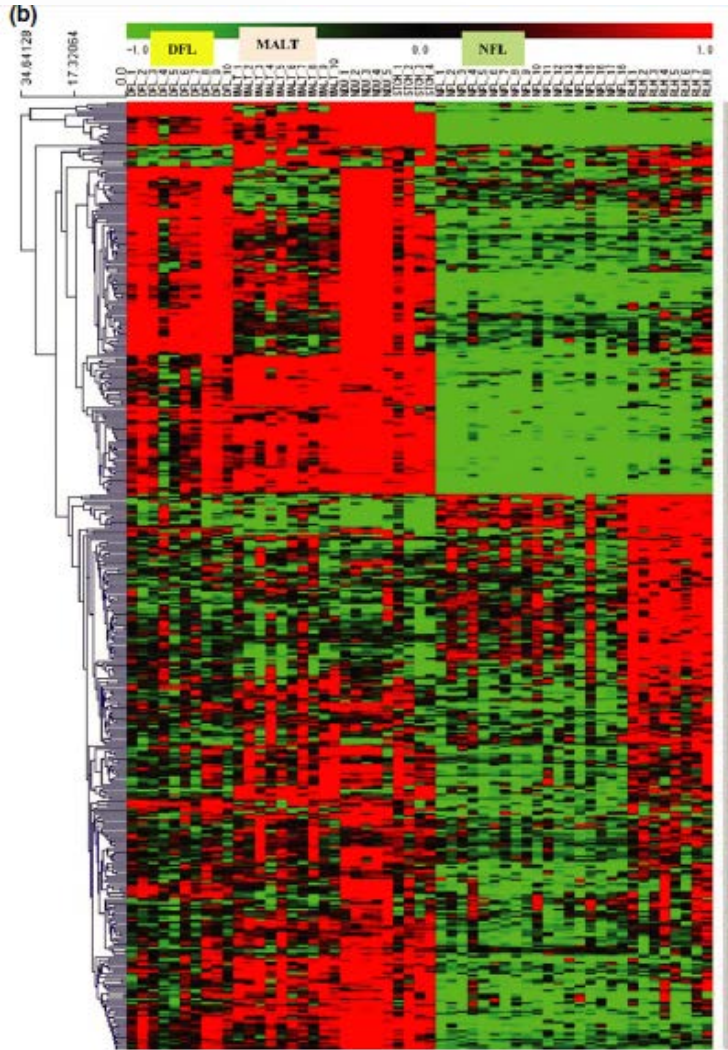


**25.** Ulusal Patoloji Kongres  
**6.** Sitopatoloji Kongresi

14 - 17 Ekim 2015 / Merinos AKKM - BURSA

Tari, Digestion 2011  
Foukas, Histopathology 2015  
Schmatz, JCO 2011  
Mori. Annals of Oncol 2009

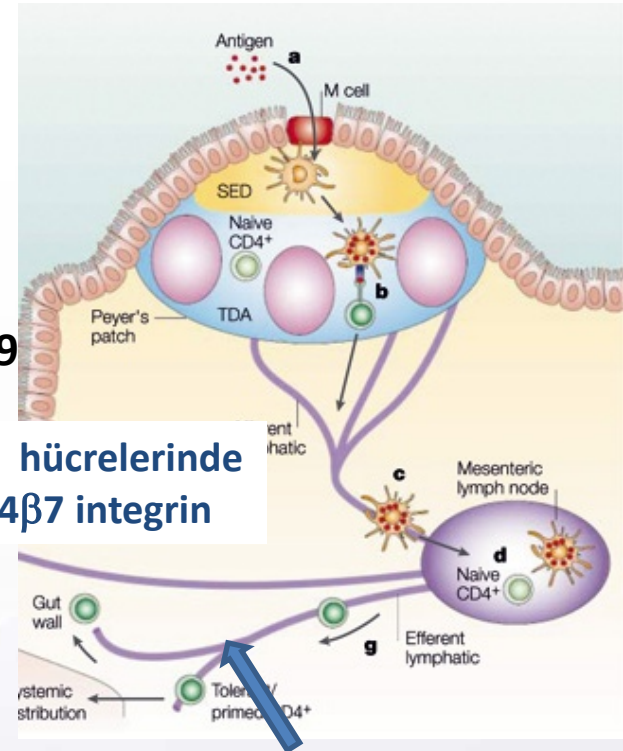
# Birincil GIS Folliküler Lenfoma (FL) Patogenez



Patogenez : Kronik antijenik uyarı

Gen ifade profili  
MALT lenfomaya benzer

IgA ifadesi +  
chemokine reseptör CCR9  
Ig genleri V 4, V5



FL hücrelerinde  
 $\alpha 4\beta 7$  integrin

GIS mukoza endotel de MADCAM-1

Takata. Cancer Science 2014  
Bende. Am J Pathol 2003



**25.** Ulusal Patoloji Kongresi  
**6.** Sitopatoloji Kongresi

14 - 17 Ekim 2015 / Merinos AKKM - BURSA



# Primer GIS FL Ayırıcı Tanı

- Reaktif folliküler hiperplazi
- İkincil FL tutulumları
- MCL
- MZL (Maltoma)



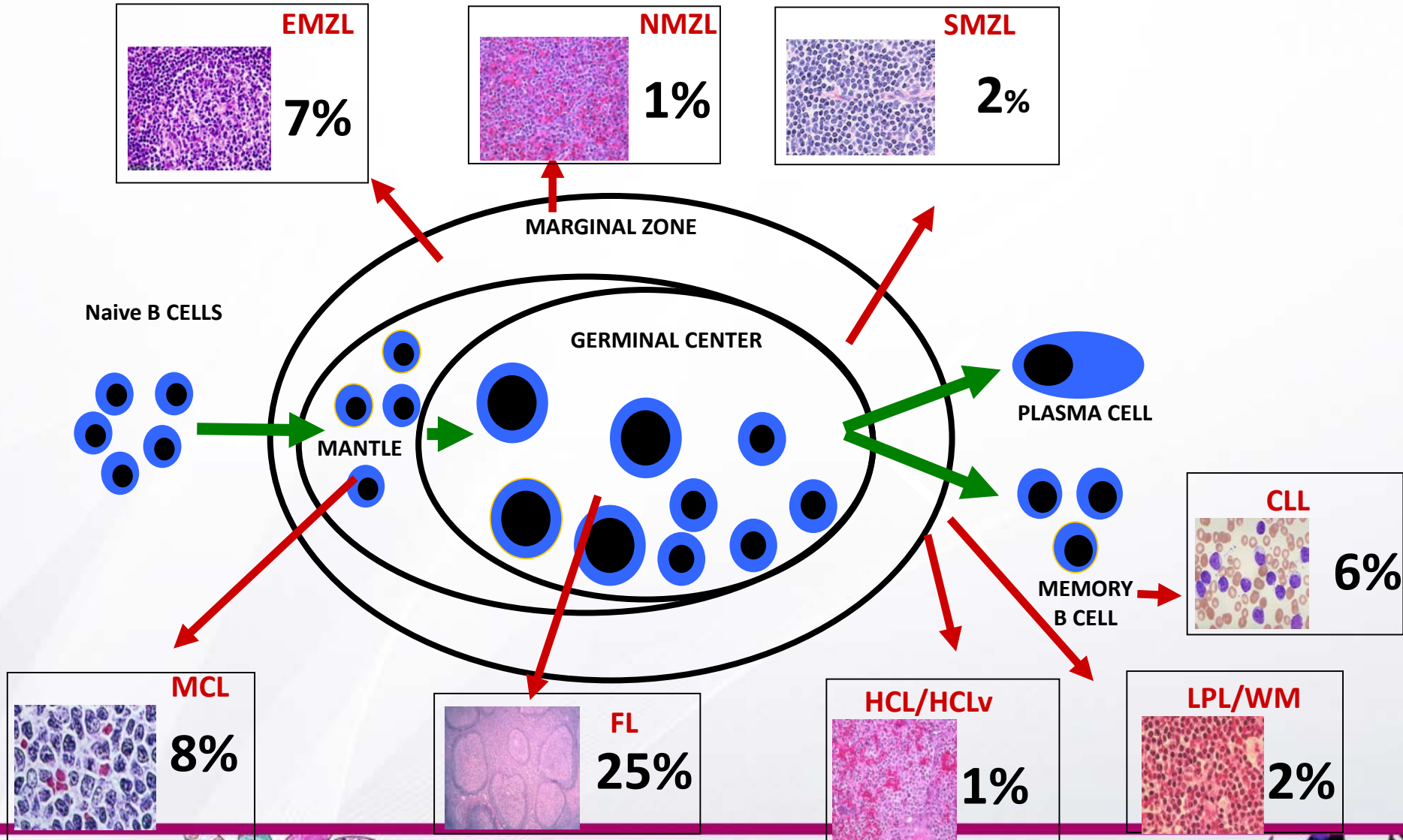
# GIS Birincil ve İkincil FL tutulumları ayırımı

**Table 2.** Key differences between primary intestinal (duodenal) and systemic (nodal) follicular lymphoma

	Duodenal FL	Nodal FL
Clinical presentation	Often localized disease (stages I, II). Commonly incidental finding in asymptomatic patients undergoing upper GI endoscopy for unrelated symptoms. Mucosal polyp (endoscopy) most commonly in the second portion of the duodenum; may also occur elsewhere in the small intestine	Often widespread disease (stages III, IV). Generalized lymphadenopathy, splenomegaly, bone marrow involvement (40–70%). B symptoms in about 1/3 of the cases
Morphology	Follicular pattern of growth Grades 1–2/3	Follicular, follicular and diffuse or less commonly diffuse pattern of growth Grades 1–2 or 3 (3A, 3B)
Immunophenotype	BCL2 <sup>+</sup> , BCL6 <sup>+</sup> , CD10 <sup>+</sup> $\alpha$ 4 $\beta$ 7 integrin <sup>+</sup> , IgA <sup>+</sup> , AID <sup>-</sup> , BACH <sup>+</sup> FDCs (CD21/CD23): often disrupted meshwork within neoplastic follicles, commonly with a hollow pattern	BCL2 <sup>+/-</sup> , BCL6 <sup>+</sup> , CD10 <sup>+/-</sup> $\alpha$ 4 $\beta$ 7 integrin <sup>-</sup> , IgM <sup>+</sup> , AID <sup>+</sup> FDCs (CD21/CD23): variable, usually dense meshwork throughout the follicles; commonly disrupted meshwork
Genetics	t(14;18)(q32;q21)/IGH-BCL2 in virtually all cases  Biased usage of the IGVH4 and IGVH5 gene types	t(14;18)(q32;q21)/IGH-BCL2 in the majority of cases (negative in about 15% of the cases, especially grade 3 cases) Frequent usage of the IGVH3 gene type
Clinical course	Very indolent, remains localized. Very low risk of progression/transformation to a high-grade lymphoma	Indolent. Higher risk of disease progression/transformation (25–35%)

FDCs, Follicular dendritic cells; AID, Activation-induced cytidine deaminase; Ig, Immunoglobulin; BCL, B cell lymphoma.

# Küçük B Hücreli Lenfomalar Görülme Sıklığı



**25.** Ulusal Patoloji Kongresi  
**6.** Sitopatoloji Kongresi

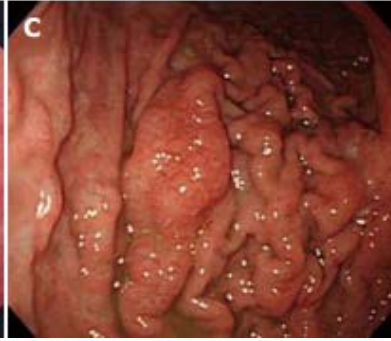
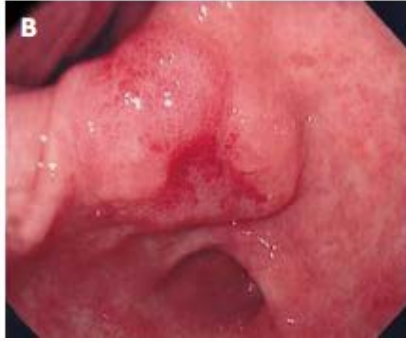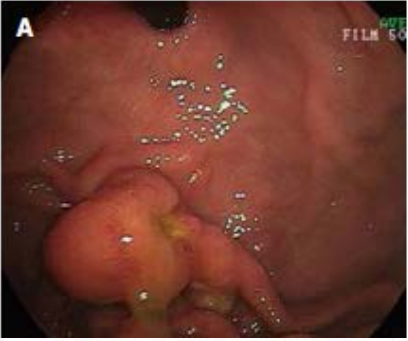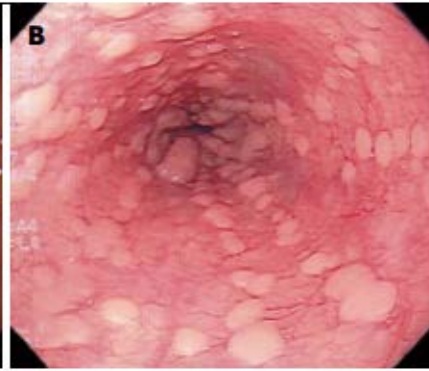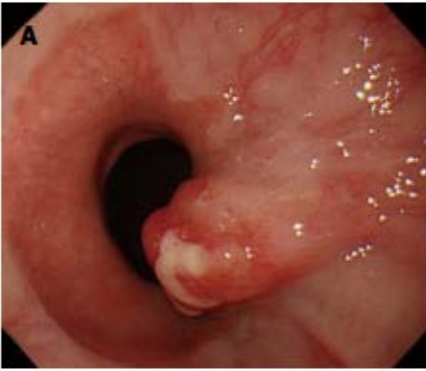
14 - 17 Ekim 2015 / Merinos AKKM - BURSA · Fitzgibbon 2014





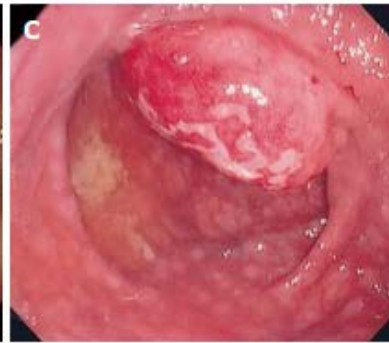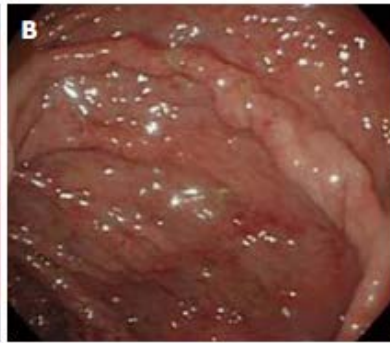
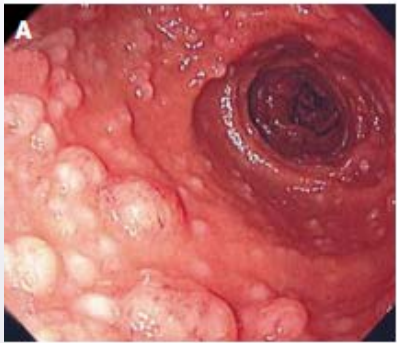
# MANTLE HÜCRELİ LENFOMA MCL

OZOFAGUS

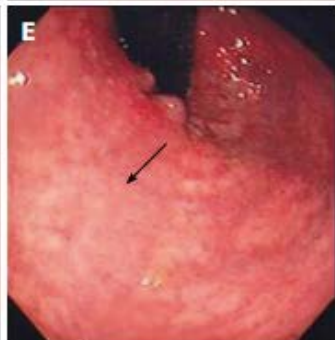
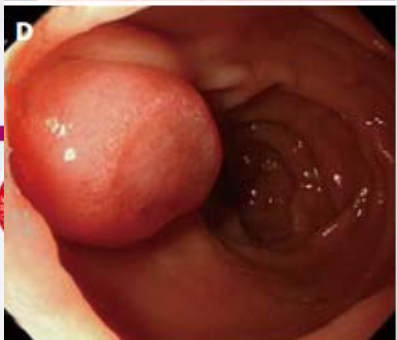

MİDE

MULTİPLE  
LENFOPMATÖZ  
POLİPOZİS



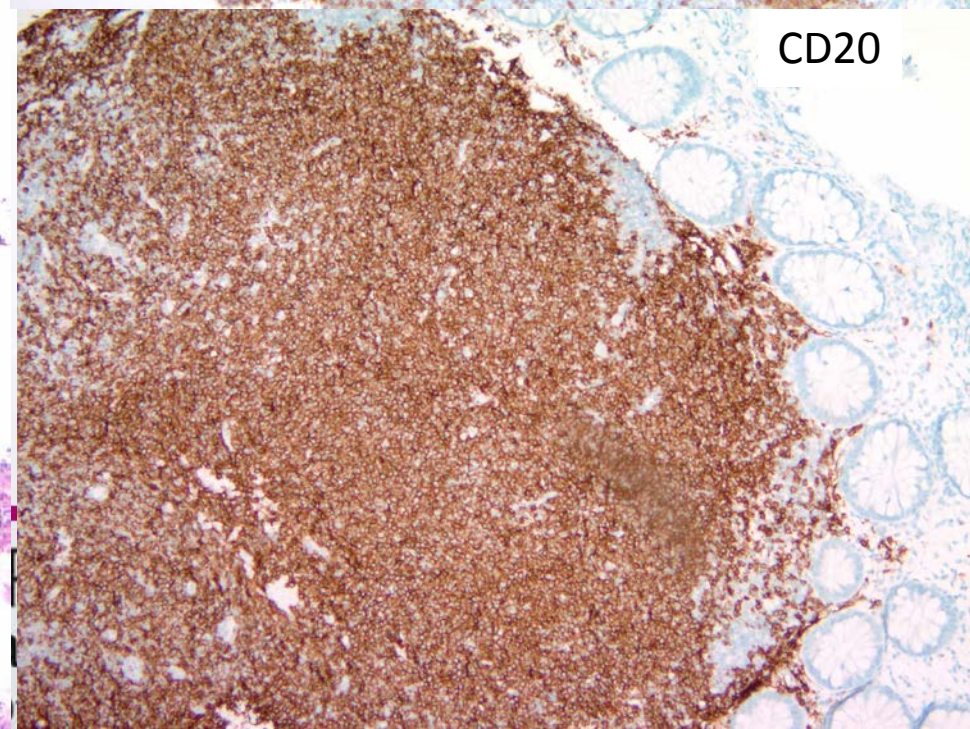
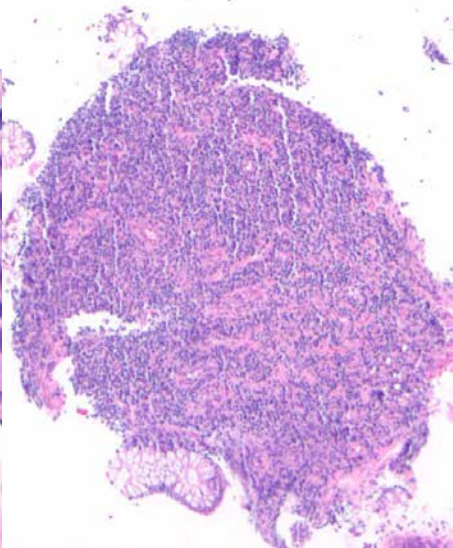
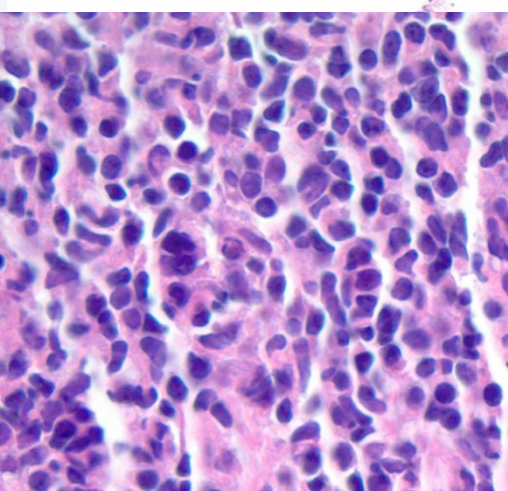
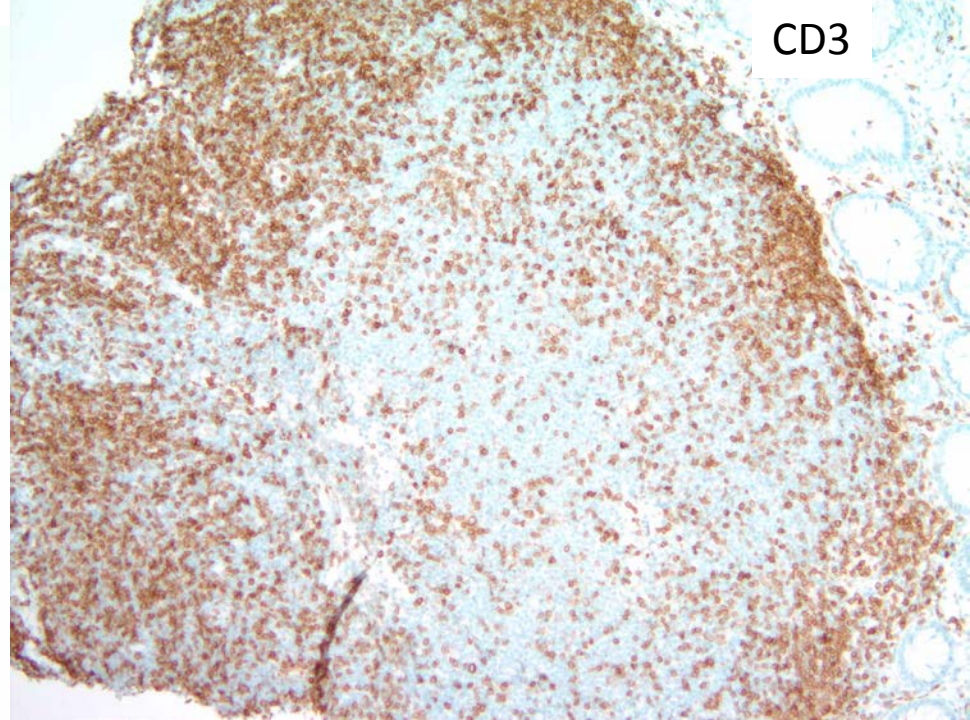
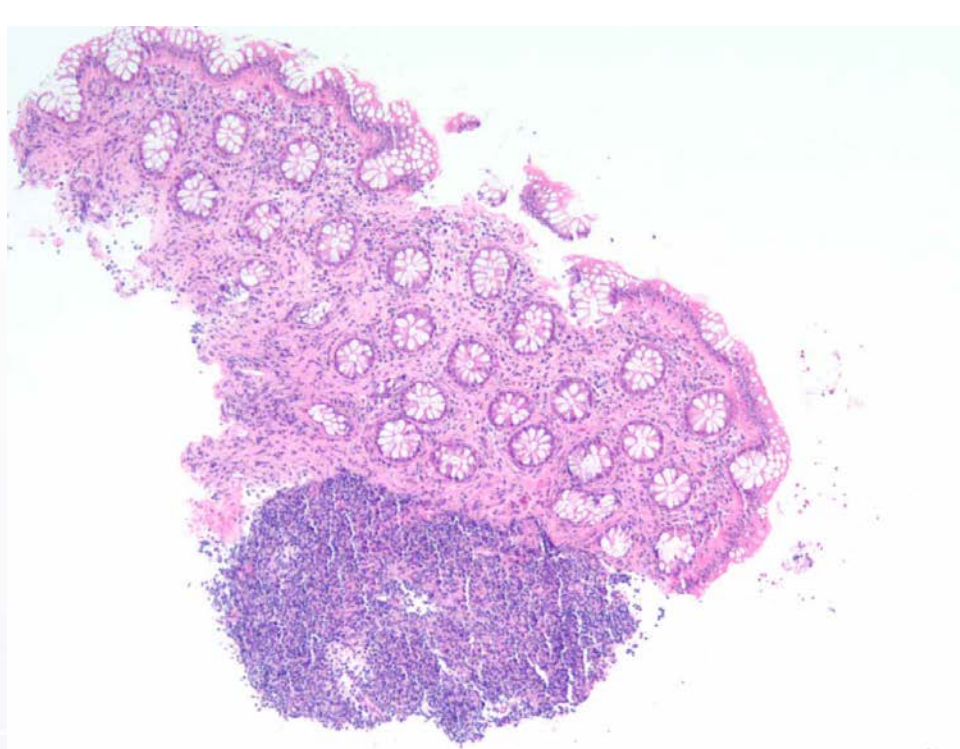
KOLON



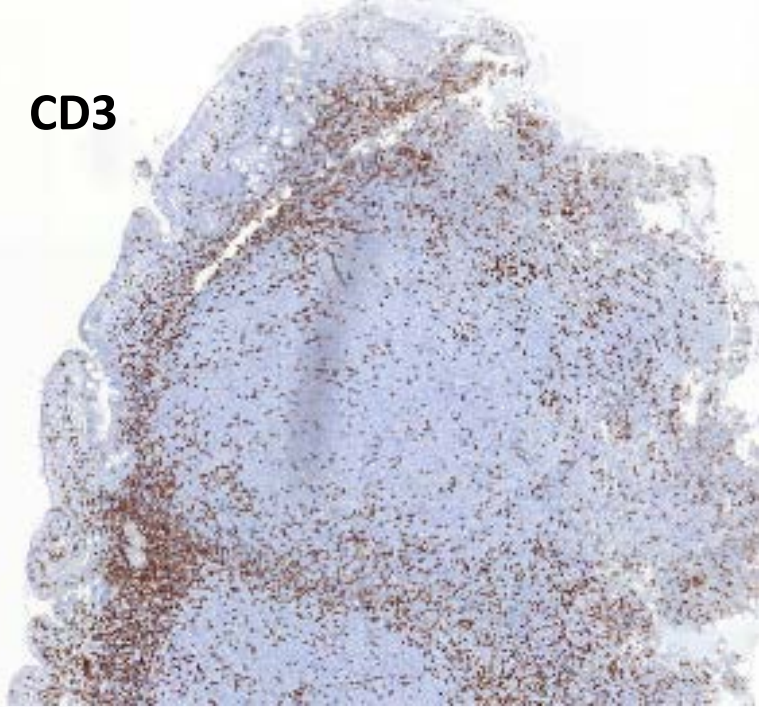
Iwamuro . World J Gastroenterol 2010

Kongresi  
gresi  
A - BURSA

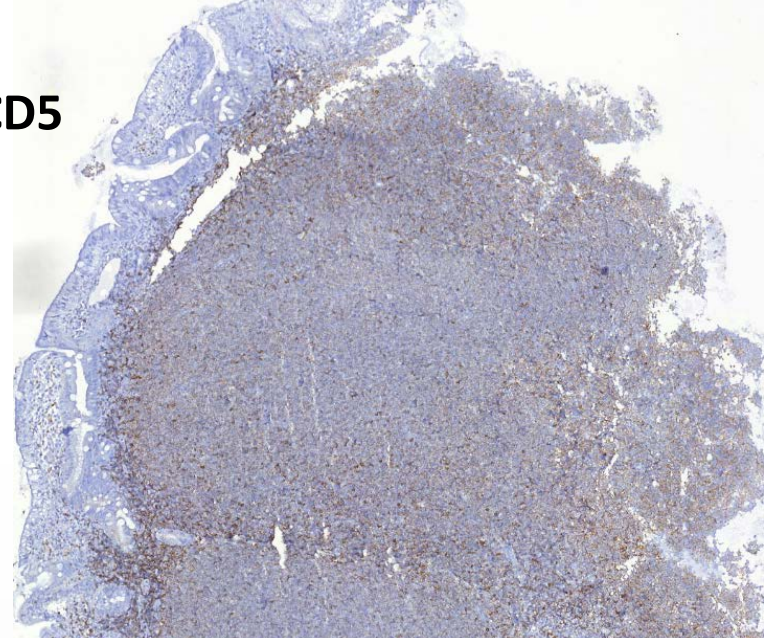




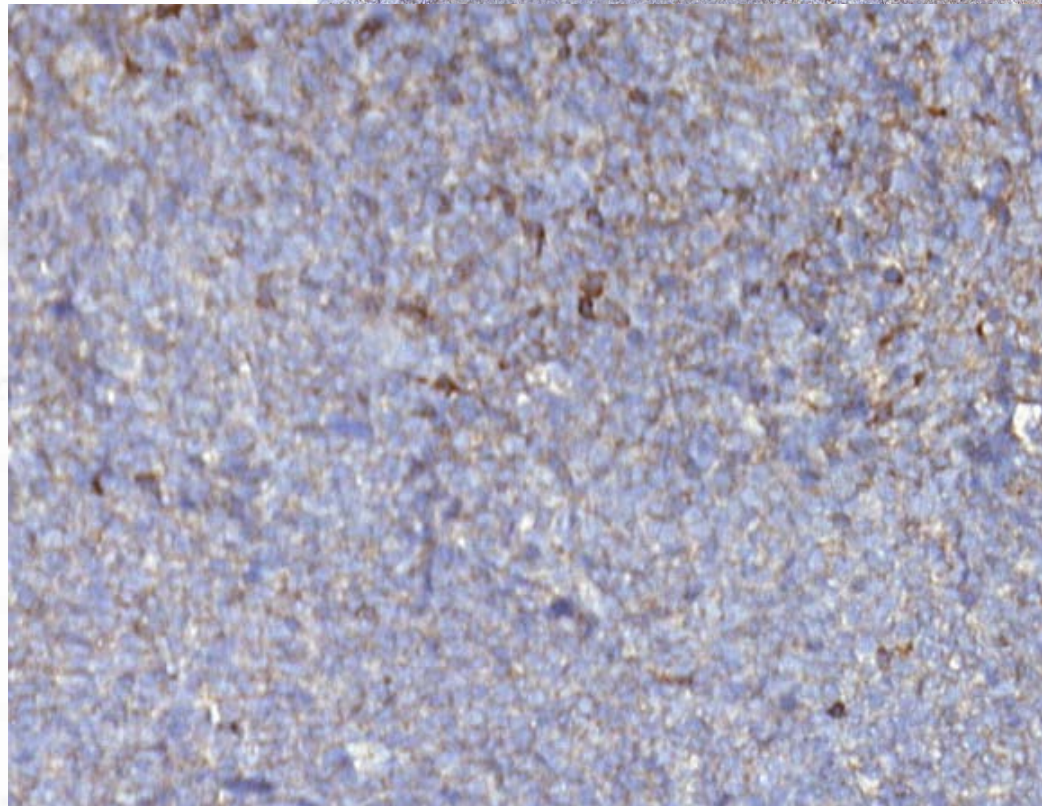
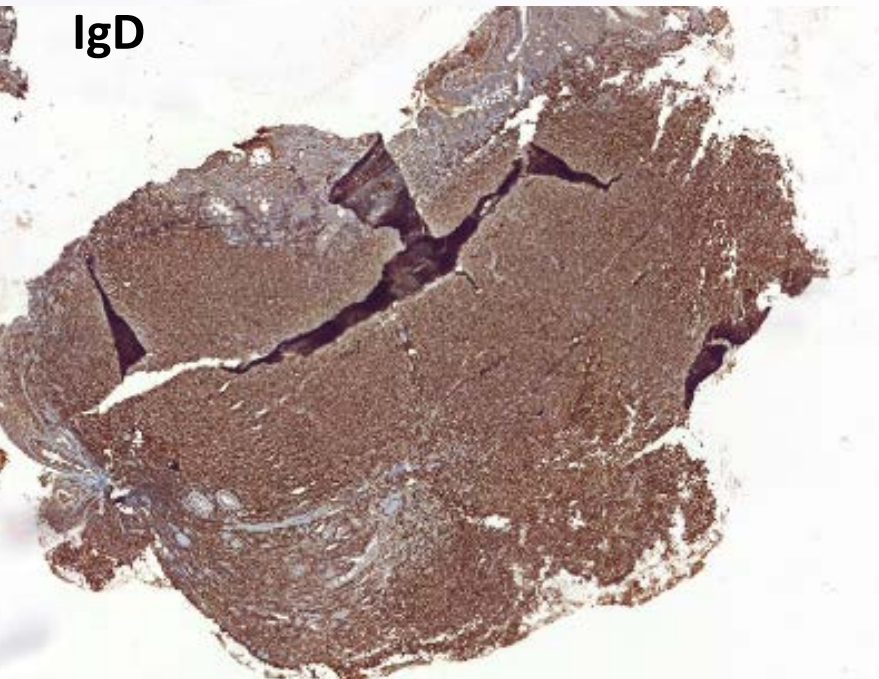**CD3**



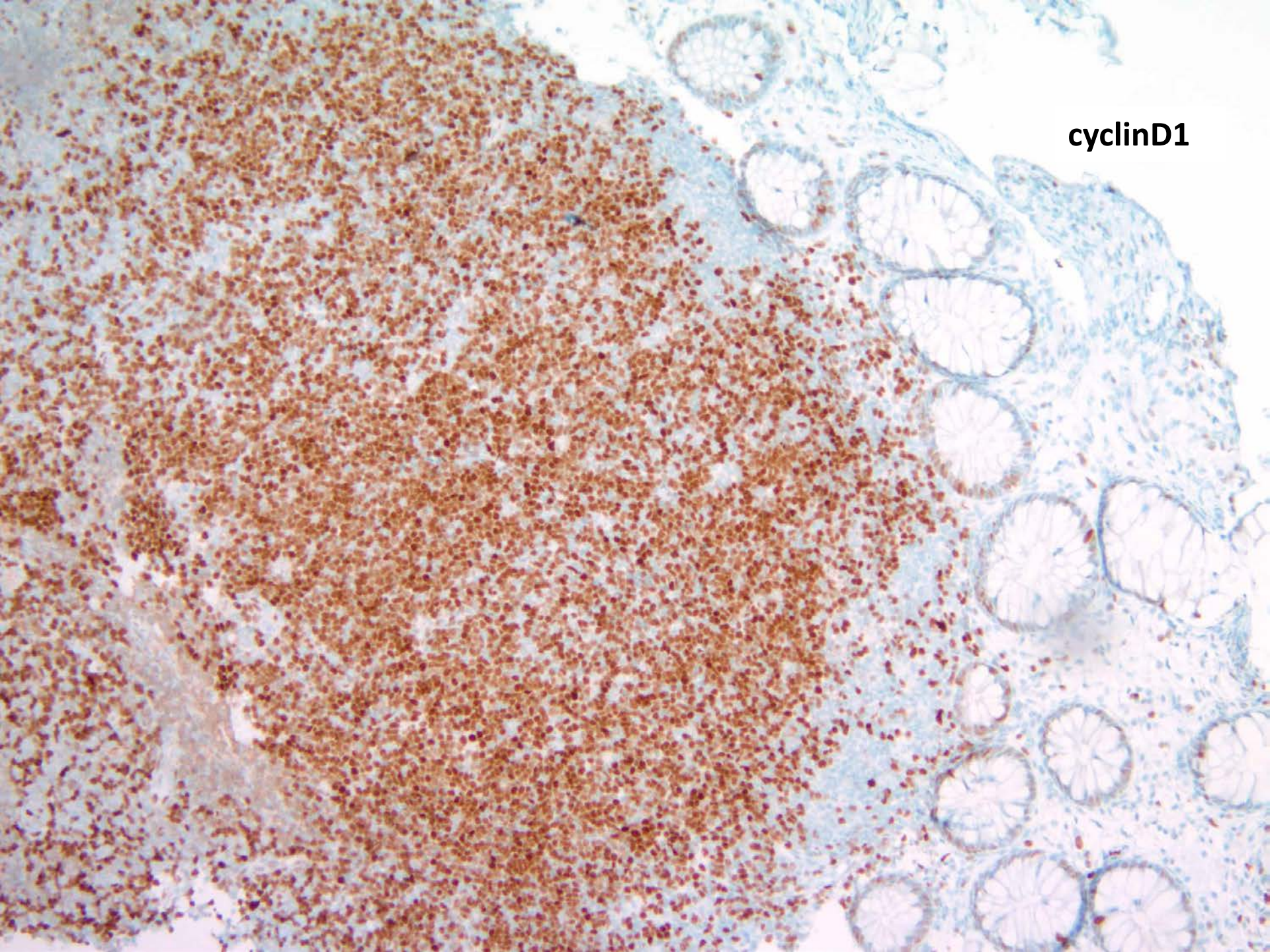
**CD5**



**IgD**



**cyclinD1**

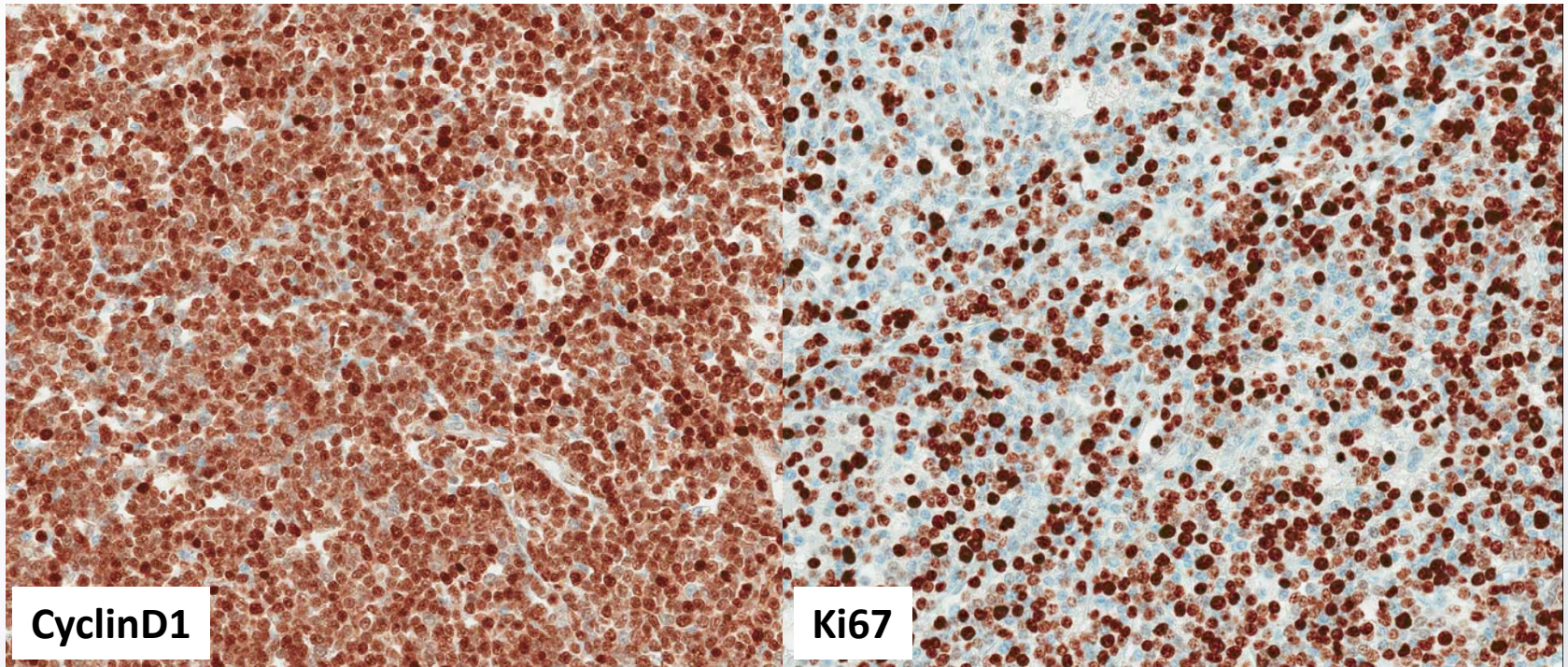


**SOX11**

**DIĐER CD5 + B HÜCRELİ LENFOMA İNFİLTRASYONU  
KLL /SLL AYIRICI TANIDA !!**

# MCL AGRESİF FORMLAR

Blastoid,  
Pleomorfik

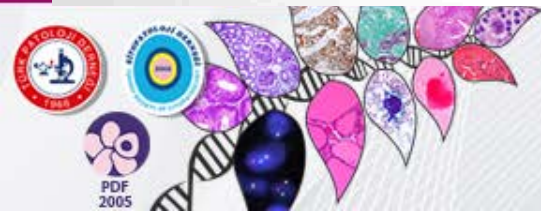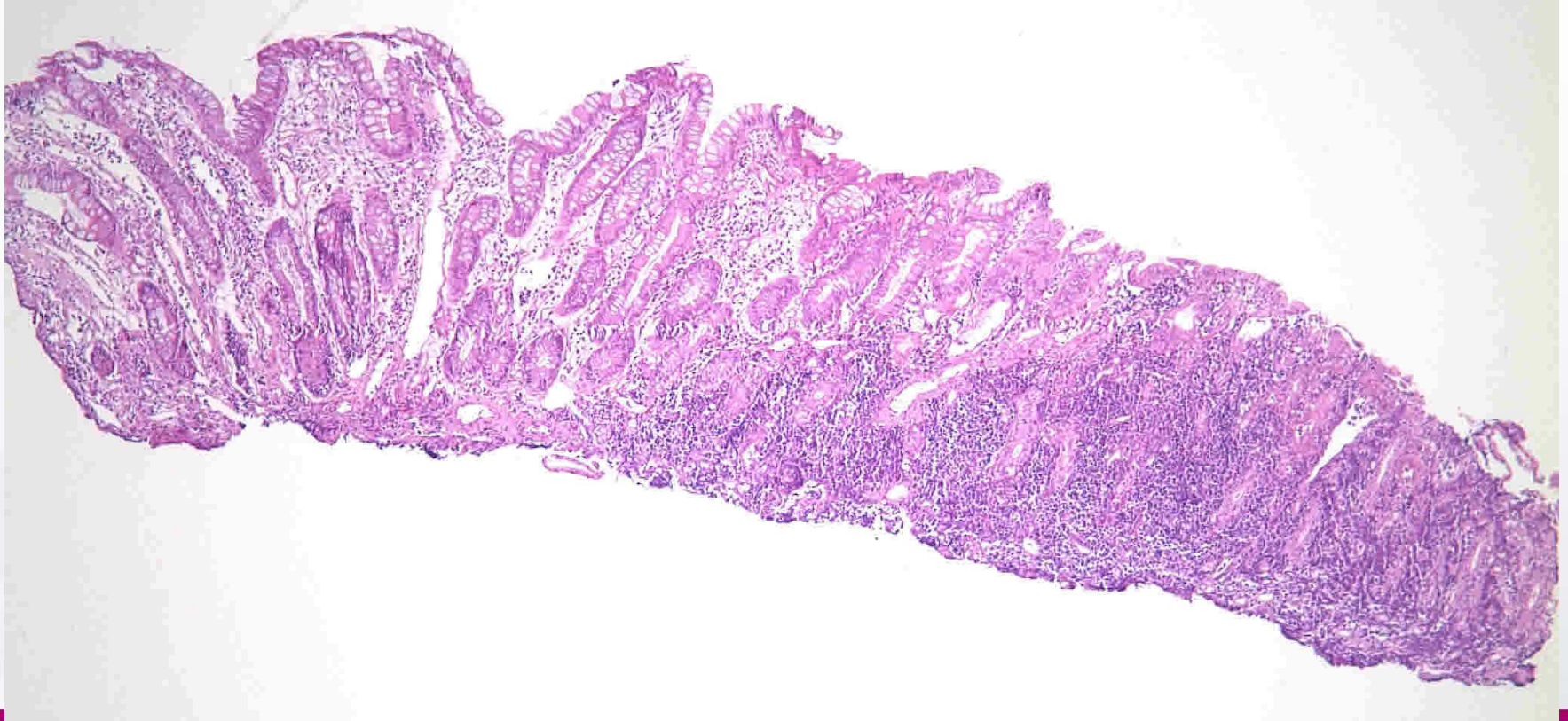


**25.** Ulusal Patoloji Kongresi  
**6.** Sitopatoloji Kongresi

14 - 17 Ekim 2015 / Merinos AKKM - BURSA

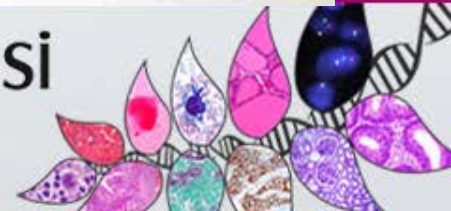

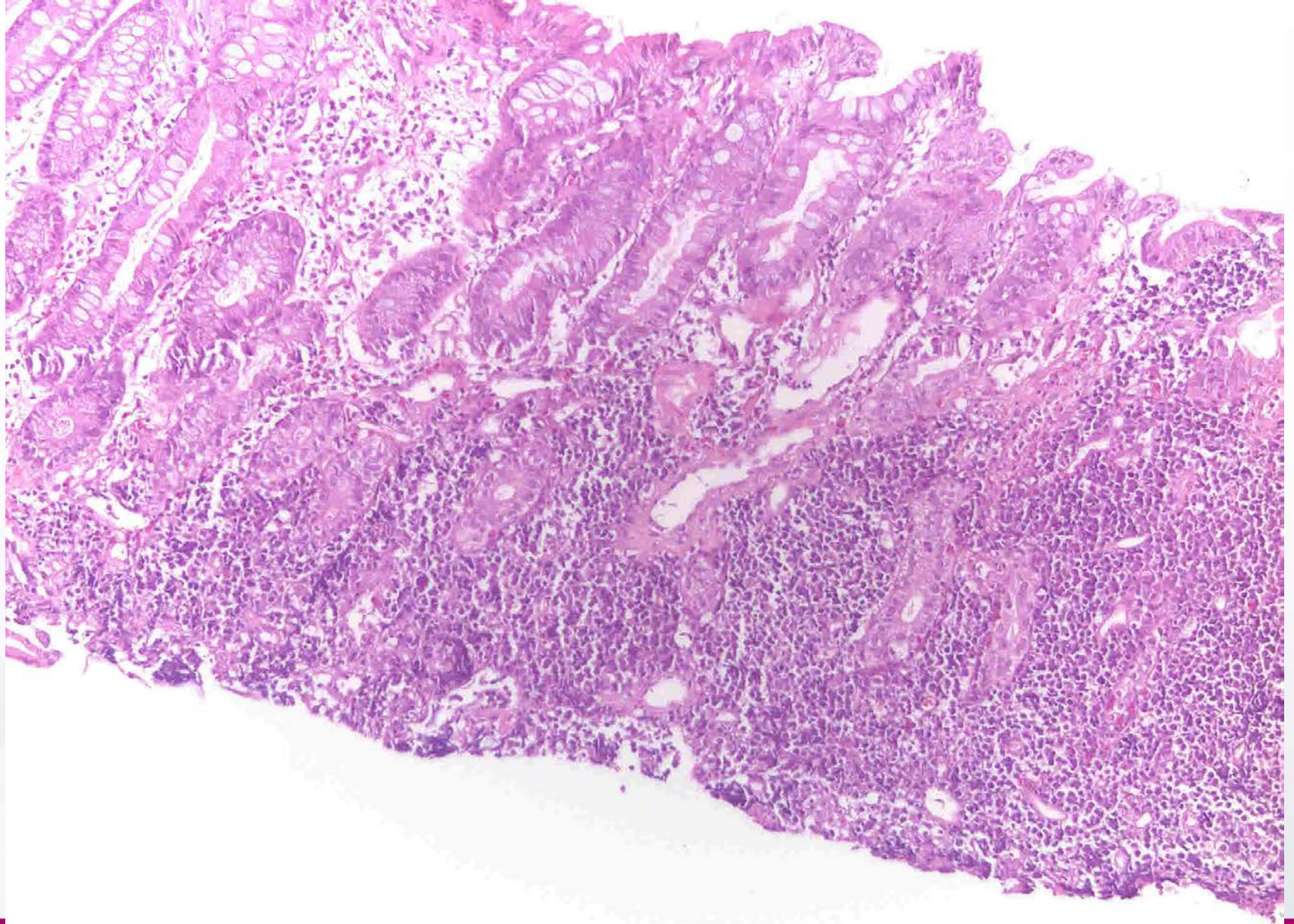
# BURKITT LENFOMA (BL)



**25** Ulusal Patoloji Kongresi  
**6.** Sitopatoloji Kongresi

14 - 17 Ekim 2015 / Merinos AKKM - BURSA



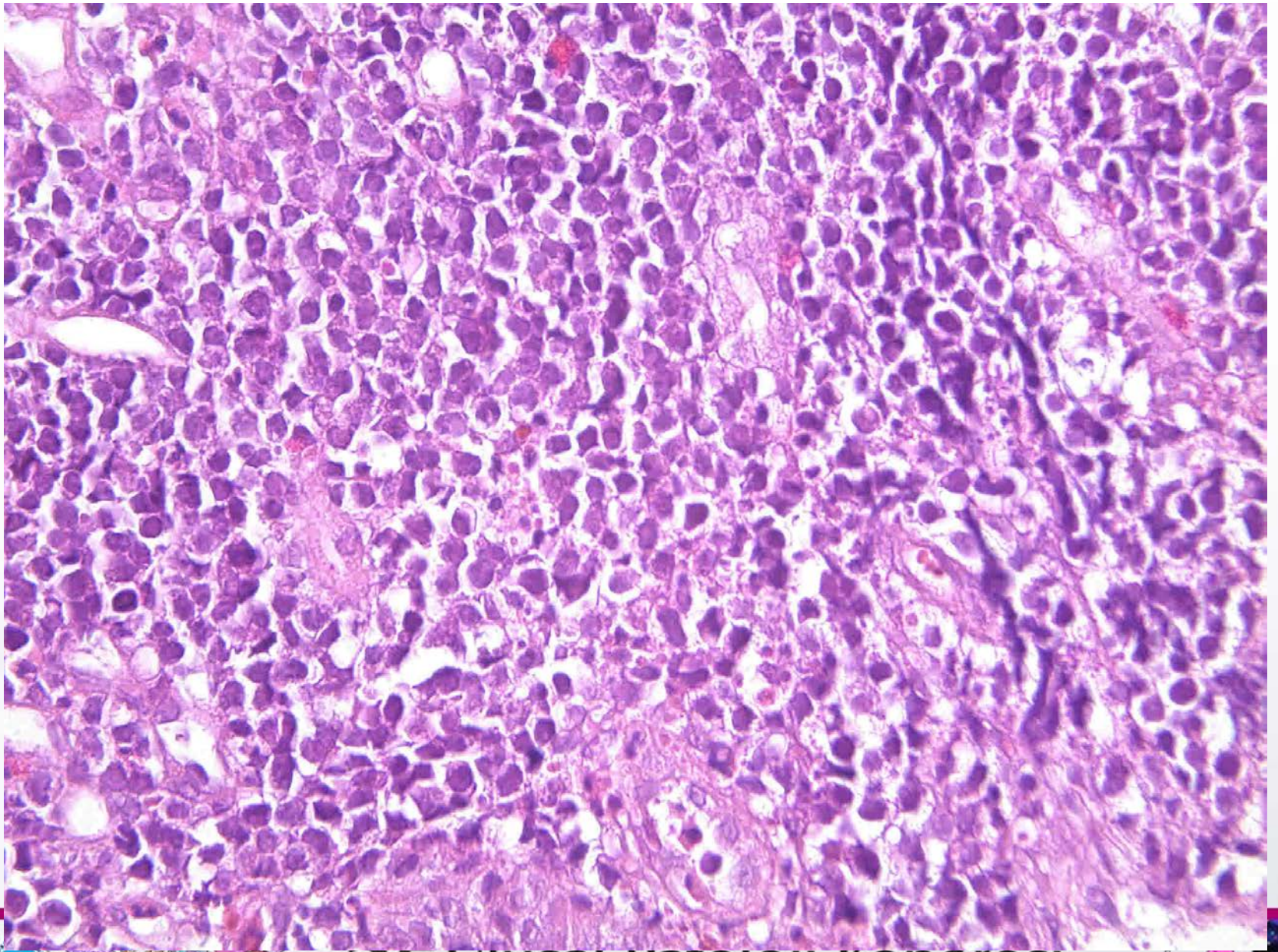


# 25. Ulusal Patoloji Kongresi

## 6. Sitopatoloji Kongresi

14 - 17 Ekim 2015 / Merinos AKKM - BURSA



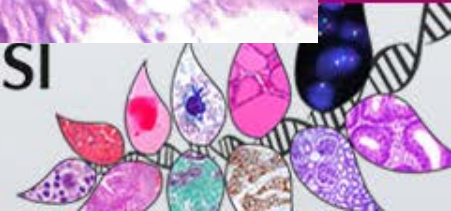


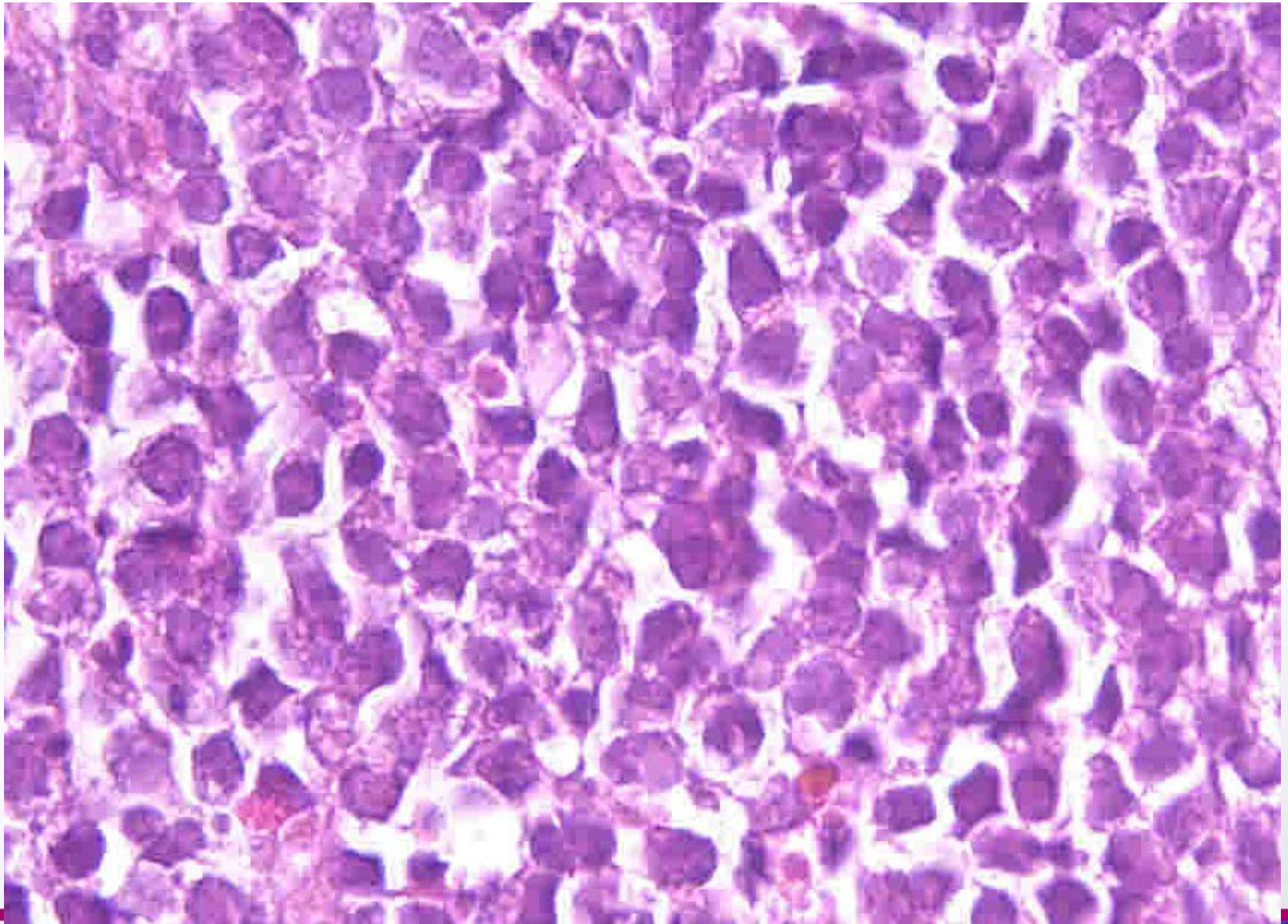
PDF  
2005

# 25. Ulusal Patoloji Kongresi

## 6. Sitopatoloji Kongresi

14 - 17 Ekim 2015 / Merinos AKKM - BURSA

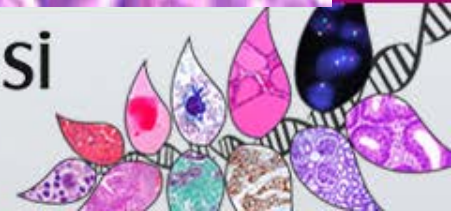



# 25. Ulusal Patoloji Kongresi

## 6. Sitopatoloji Kongresi

14 - 17 Ekim 2015 / Merinos AKKM - BURSA



# AYIRICI TANI

- DİFFÜZ BÜYÜK B HÜCRELİ LENFOMA (DBBHL)
- BURKİTT LENFOMA
- LENFOBLASTİK LENFOMA

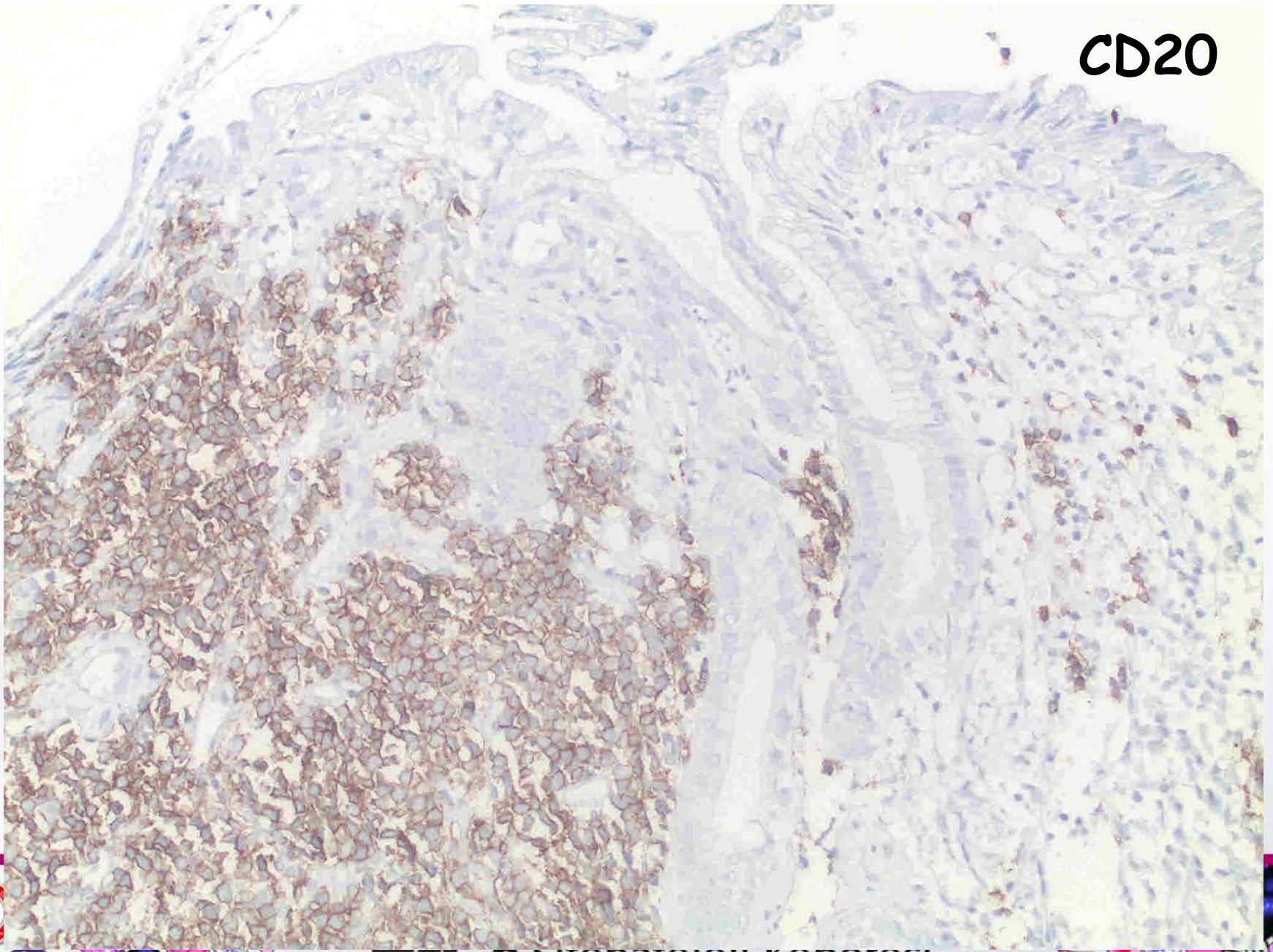


**25.** Ulusal Patoloji Kongresi  
**6.** Sitopatoloji Kongresi

14 - 17 Ekim 2015 / Merinos AKKM - BURSA



CD20

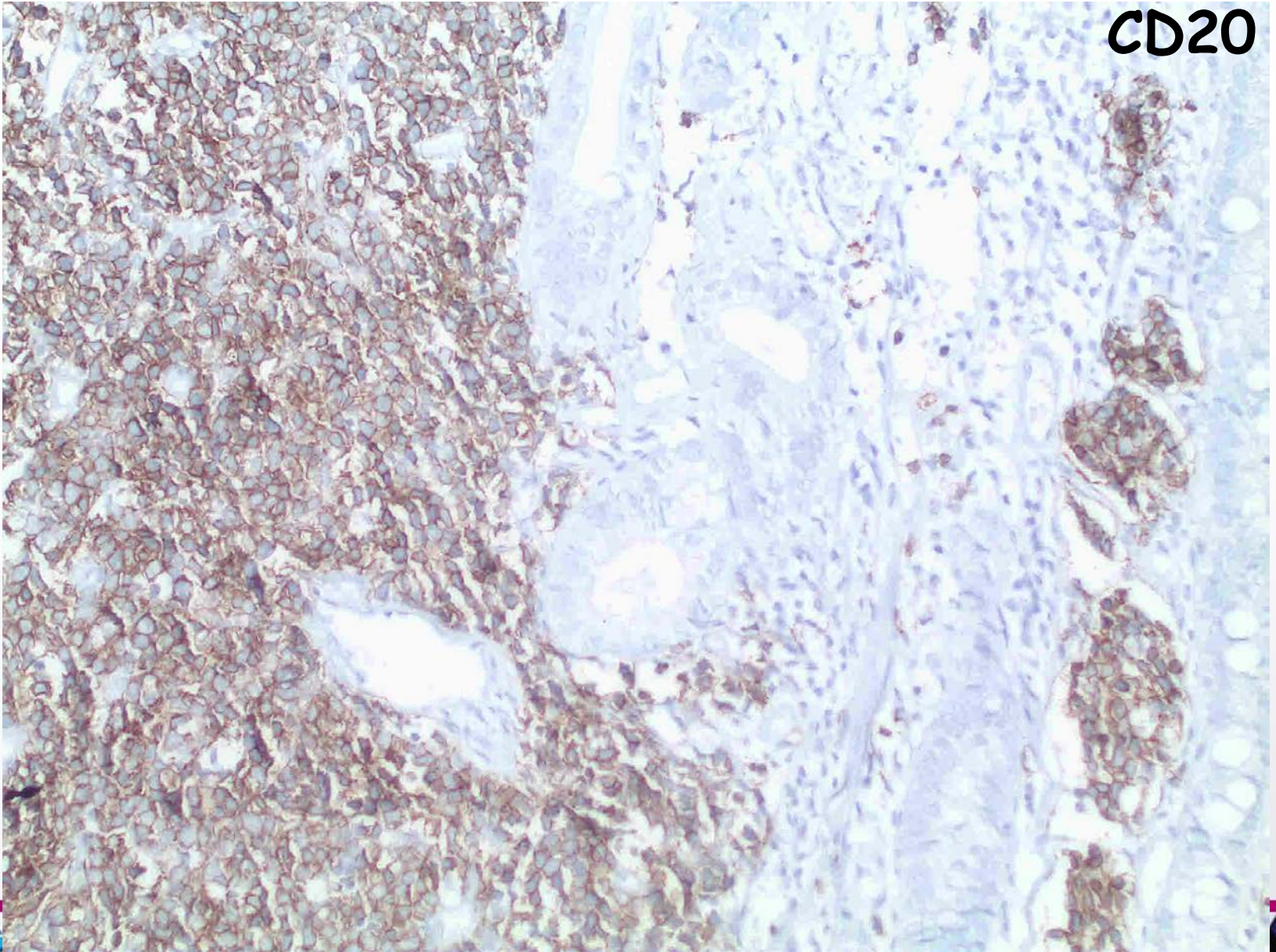


1. Sitopatoloji Kongresi

14 - 17 Ekim 2015 / Merinos AKKM - BURSA



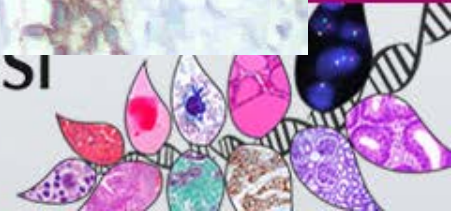
CD20



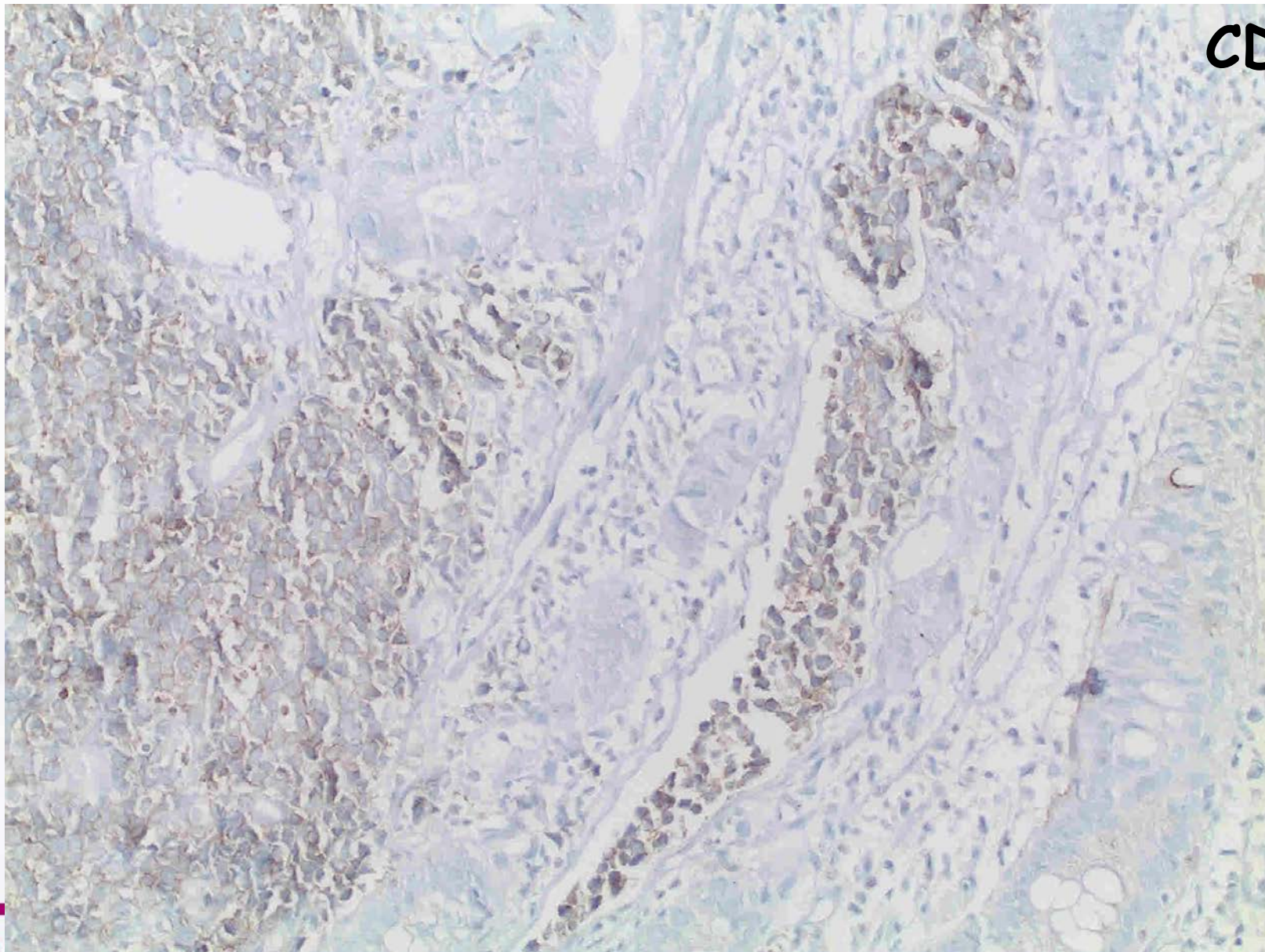
PDF  
2005

25. Ulusal Patoloji Kongresi  
6. Sitopatoloji Kongresi

14 - 17 Ekim 2015 / Merinos AKKM - BURSA



CD10

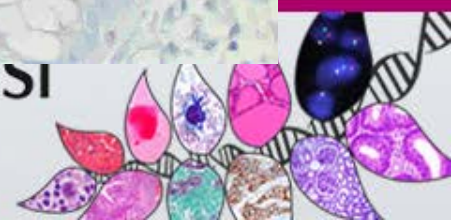


25. Ulusal Patoloji Kongresi  
6. Sitopatoloji Kongresi

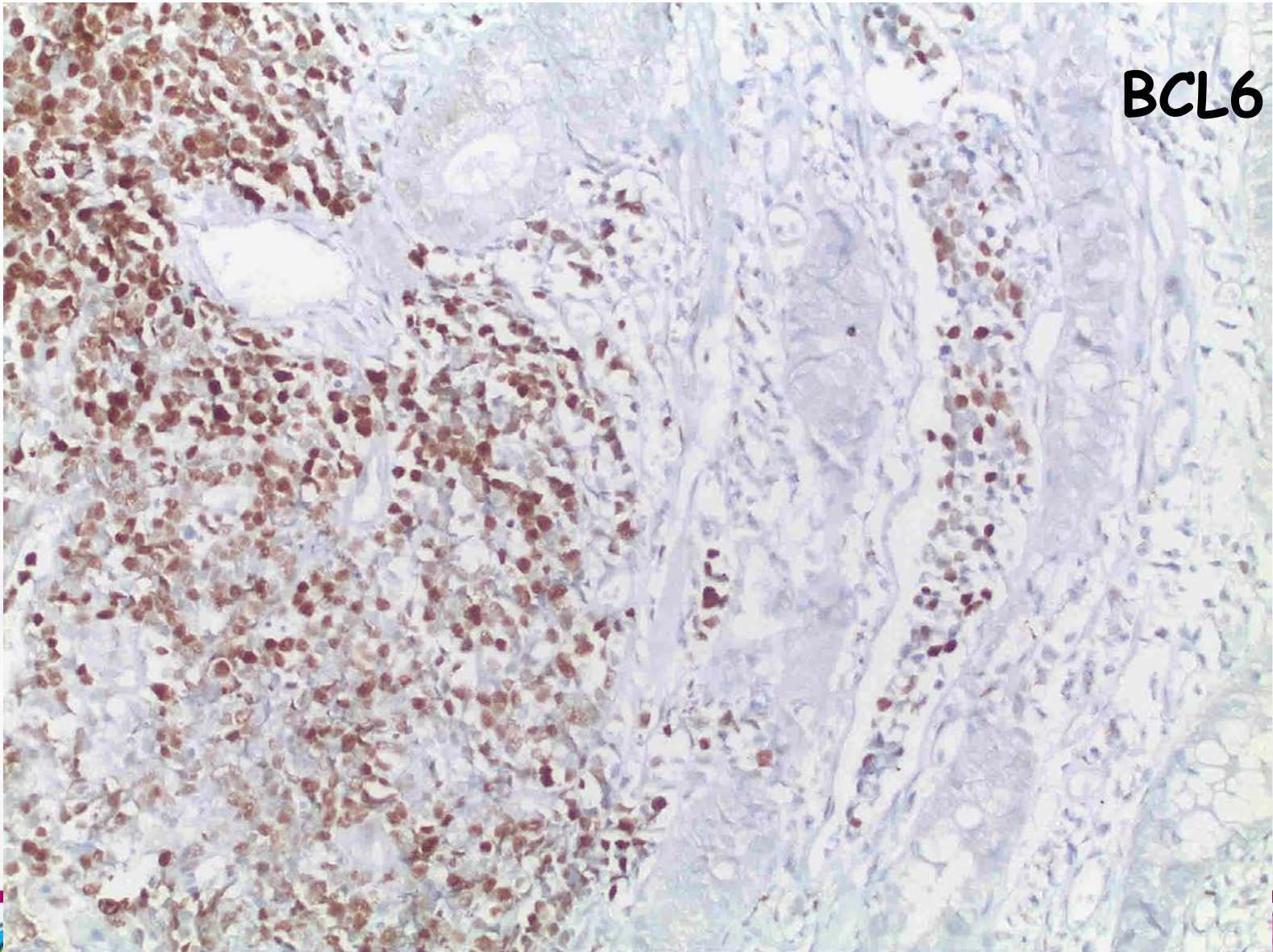
14 - 17 Ekim 2015 / Merinos AKKM - BURSA



PDF  
2005



**BCL6**

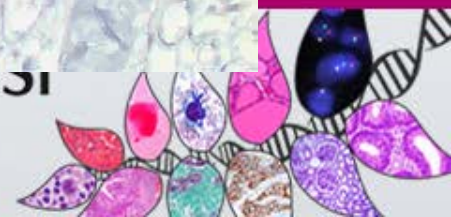


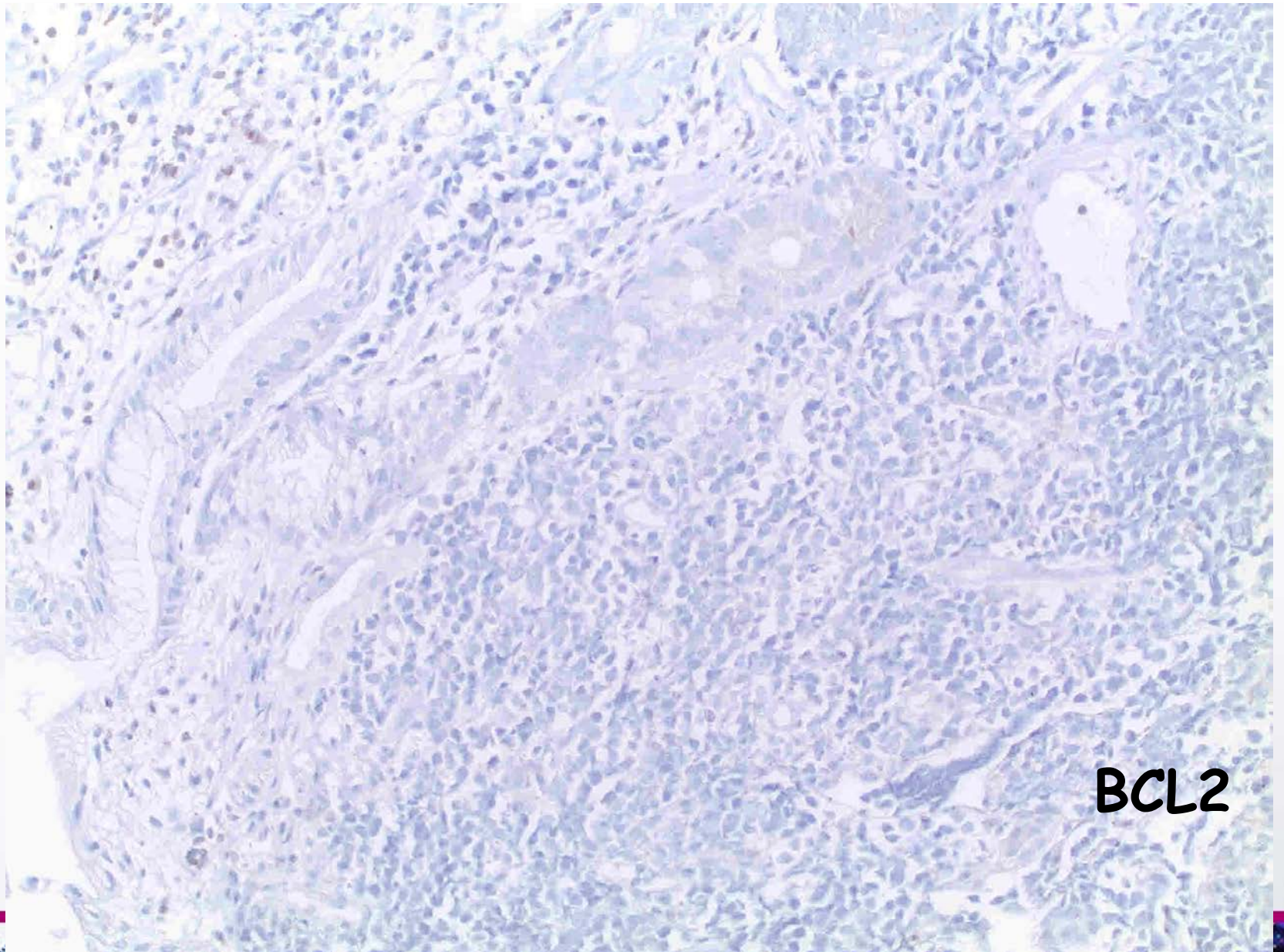
**25** Bursa Patoloji Kongresi  
**6. Sitopatoloji Kongresi**

14 - 17 Ekim 2015 / Merinos AKKM - BURSA



PDF  
2005





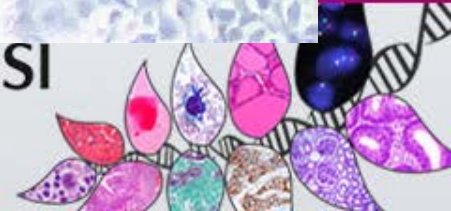
**BCL2**



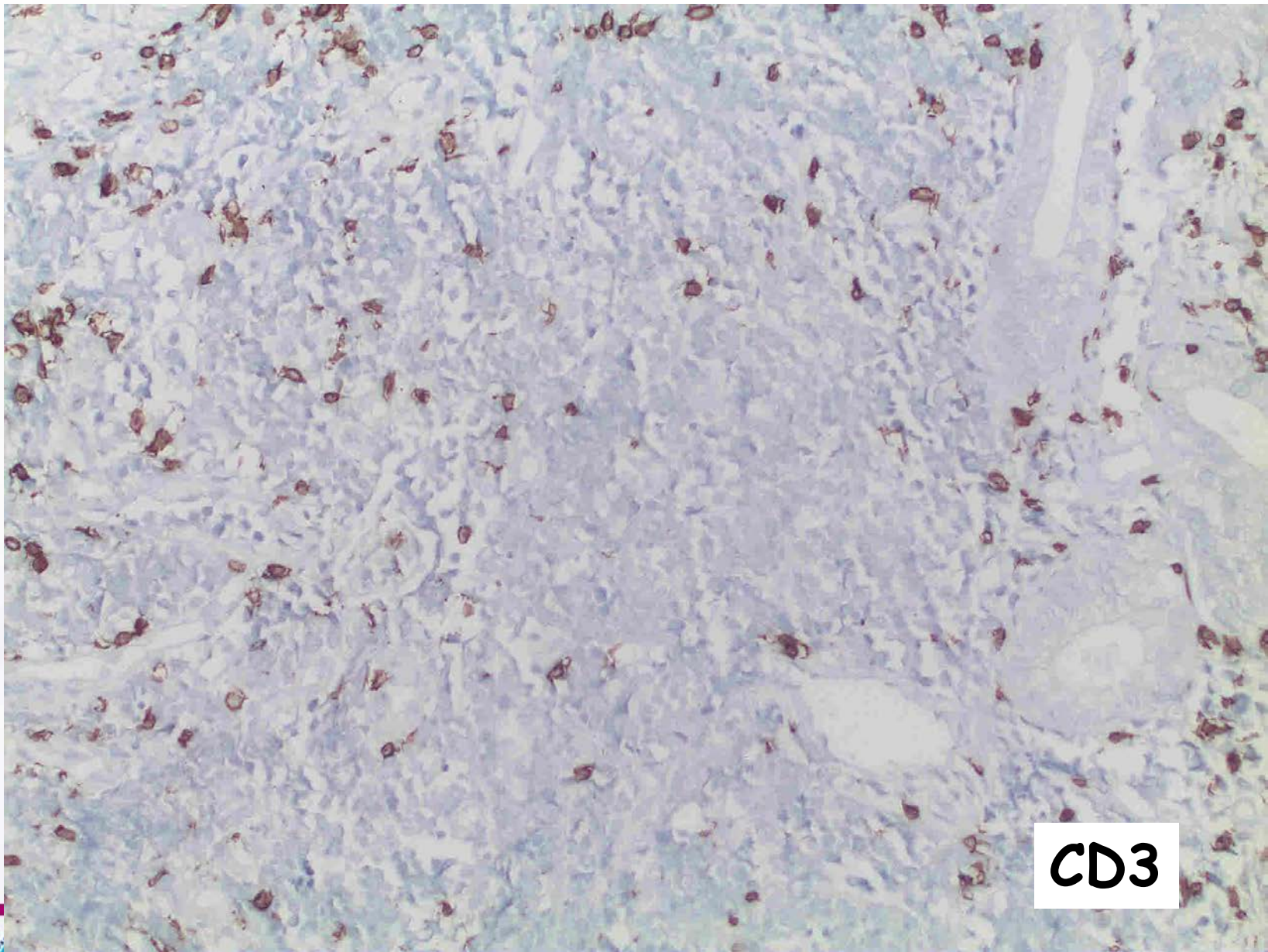
PDF  
2005

**25.** Ulusal Patoloji Kongresi  
**6.** Sitopatoloji Kongresi

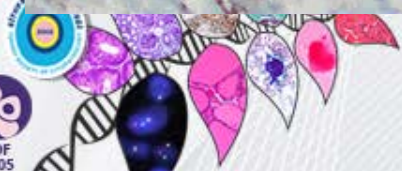
14 - 17 Ekim 2015 / Merinos AKK - BURSA







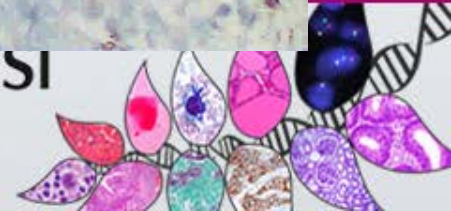
**CD3**



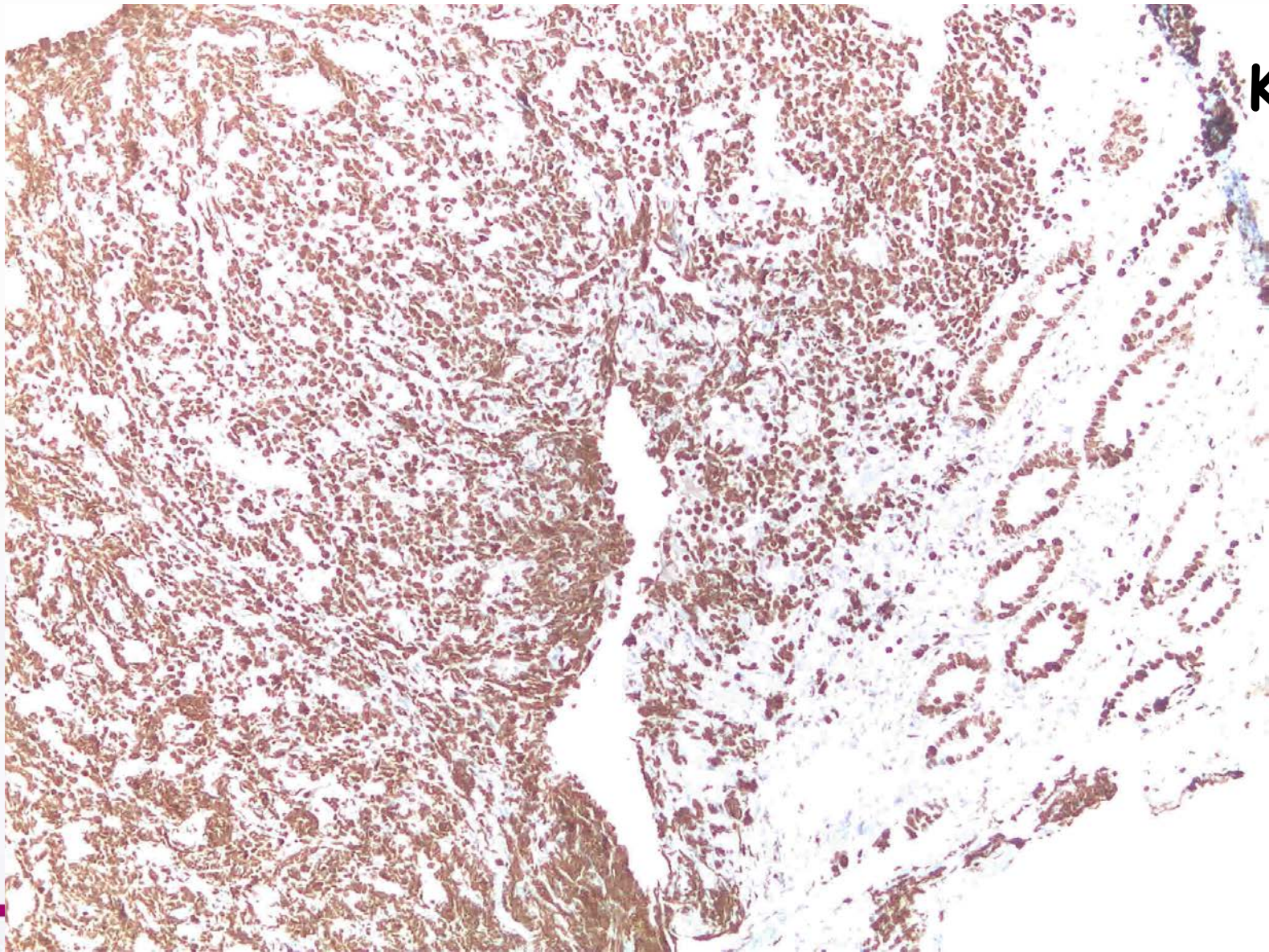
# 25. Bursa Patoloji Kongresi

## 6. Sitopatoloji Kongresi

14 - 17 Ekim 2015 / Merinos AKKM - BURSA

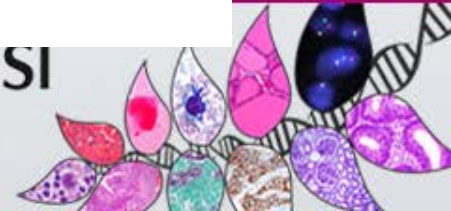

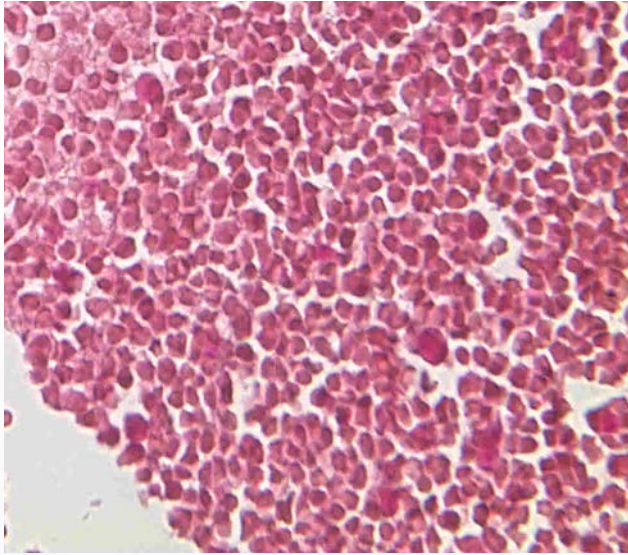
**Ki67**



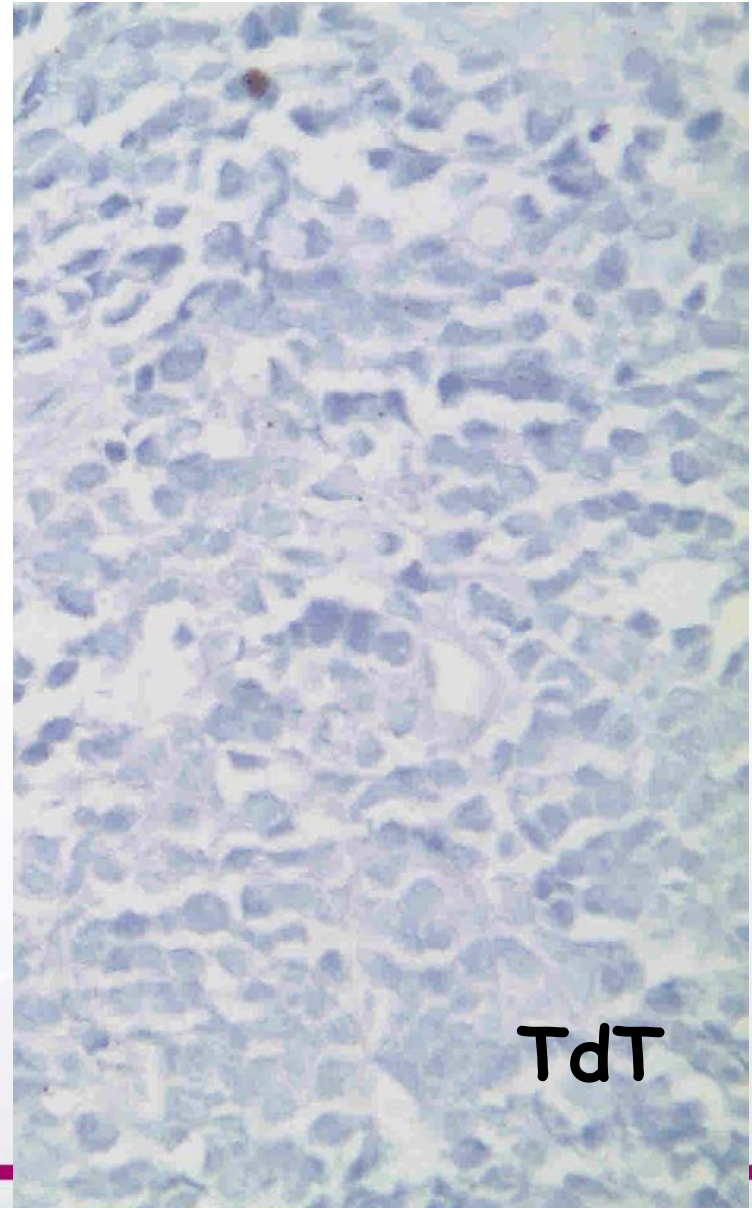
**25.** Ulusal Patoloji Kongresi  
**6.** Sitopatoloji Kongresi

14 - 17 Ekim 2015 / Merinos AKKM - BURSA





**EBER**

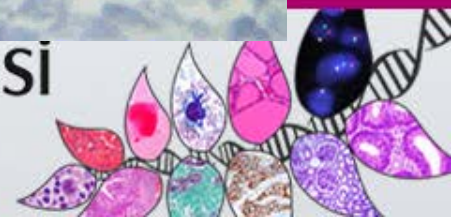


**TdT**

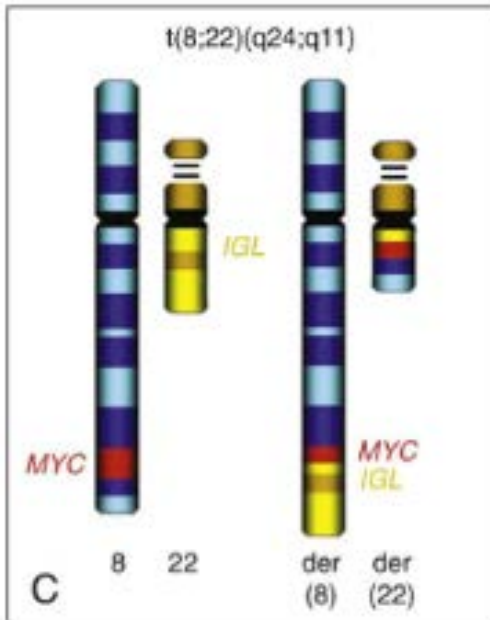
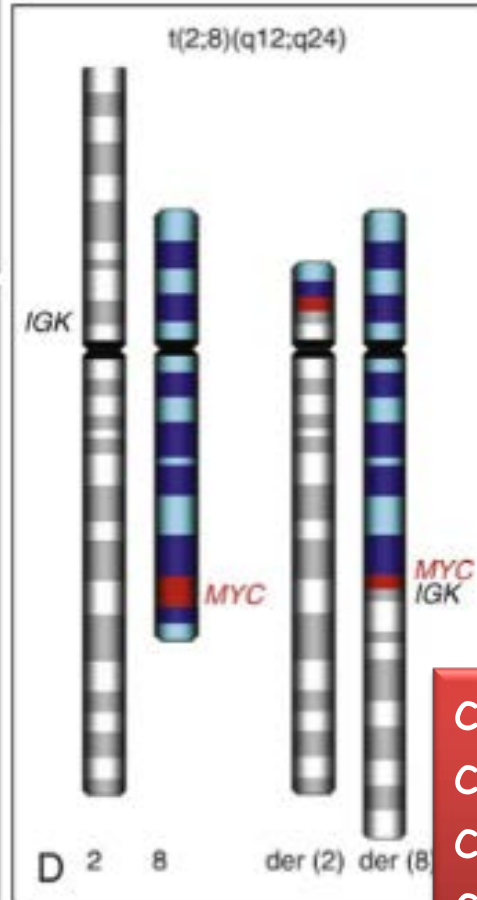
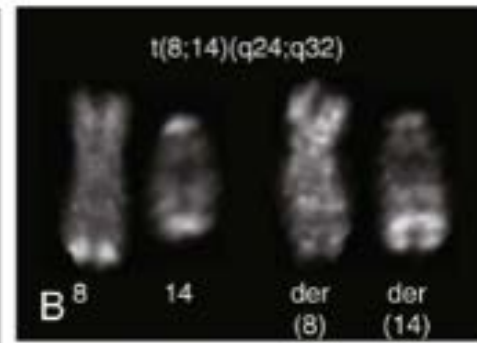
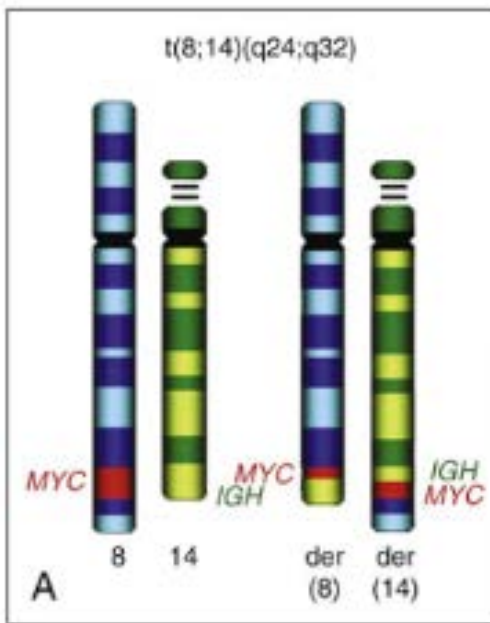


**25** Ulusal Patoloji Kongresi  
**6.** Sitopatoloji Kongresi

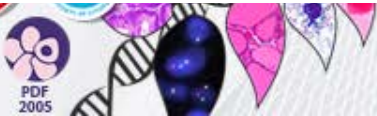14 - 17 Ekim 2015 / Merinos AKKM - BURSA

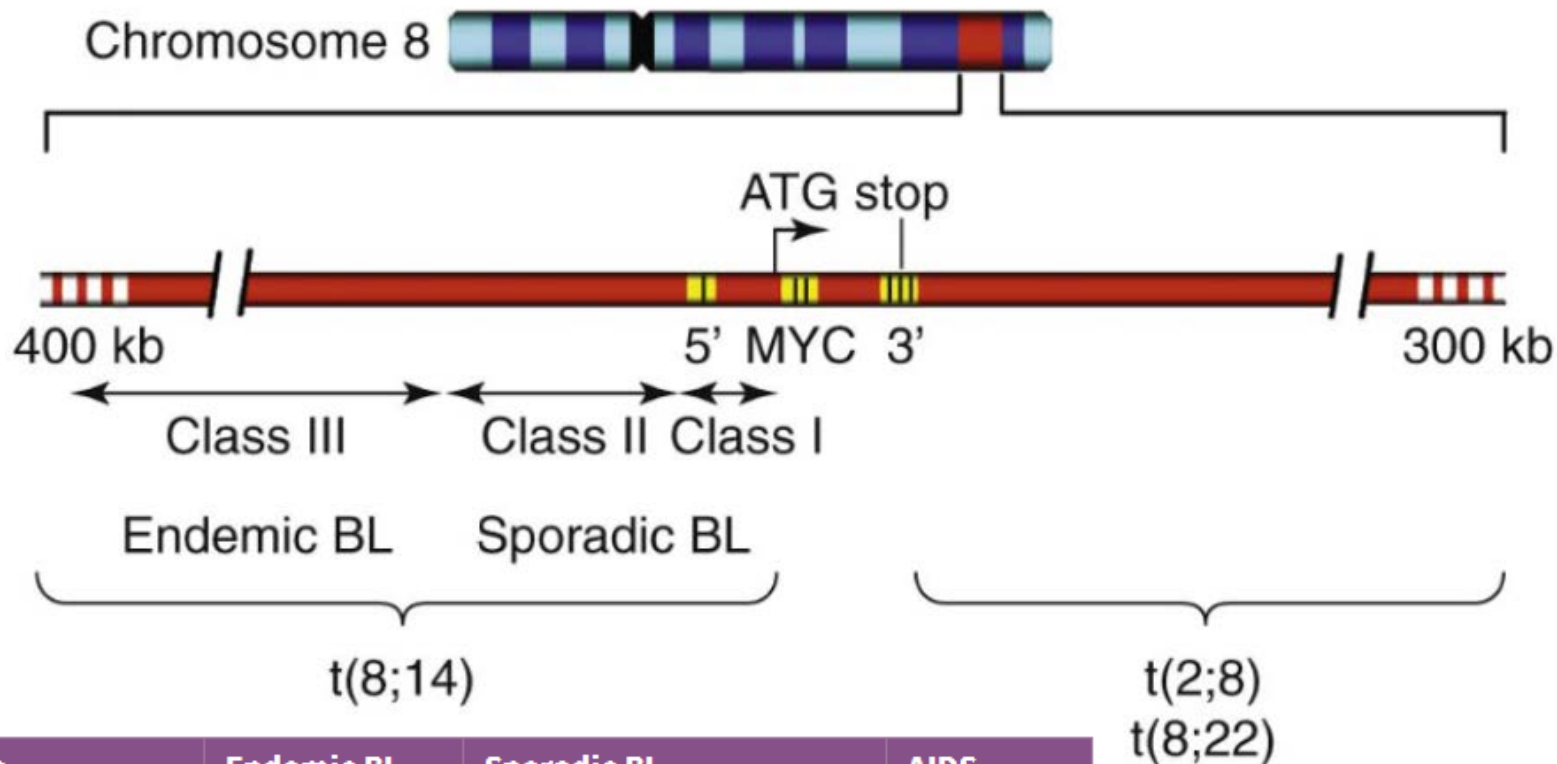


# Myc gen düzenlenmesi



c-myc; IgH	t(8;14)(q24;q32)
c-myc; Igk	t(2;8)(p12;q24)
c-myc; Igl	t(8;22)(q24;q11)
c-myc; TCR- $\alpha$	t(8;14)(q24;q11)





Feature	Endemic BL	Sporadic BL	AIDS-Associated BL
Predominant MYC breakpoint in t(8;14) (q24;q32)	Far 5' (centromeric) of MYC (class III)	Exon and intron 1 (class I) and 5' (centromeric) of MYC (class II)	Exon and intron 1 (class I)
Predominant IGH@ breakpoint in t(8;14) (q24;q32)	VDJ region	Switch region	Switch region
Somatic IGH@ mutations	Yes	Yes	Yes
EBV positivity	>90%	5%-30%	25%-40%

ongresi  
esi

TÜRK HEMATOLOJİ OKULU  
8. Klinik Patoloji Ortak Lenfoma Kursu  
26-27 Nisan 2014 Ankara

14 - 17 Ekim 2015 / Merinos Akademi

R Gascoyne, R Siebert, J Conors, 2011



# Ayırıcı Tanı

- **LENFOBLASTİK LENFOMA**

Tdt+, CD34+, CD10+, Bcl6-,

- **MİYEÖİD SARKOM**

CD34+, Myeloid antijenler, TdT+/-

- **MANTLE HÜCRELİ LENFOMA (Blastoid tip)**

cyclin D1+, CD5+, CD10-,

- **AGRESSİF T HÜCRELİ LENFOMALARIN BİR KISMI**

B hücre antijenleri negatif

- **DİFFÜZ BÜYÜK B HÜCRELİ LENFOMA**

## Borderline cases

WHO 2008

B-cell lymphoma, unclassifiable, with features intermediate between diffuse large B-cell lymphoma and Burkitt lymphoma

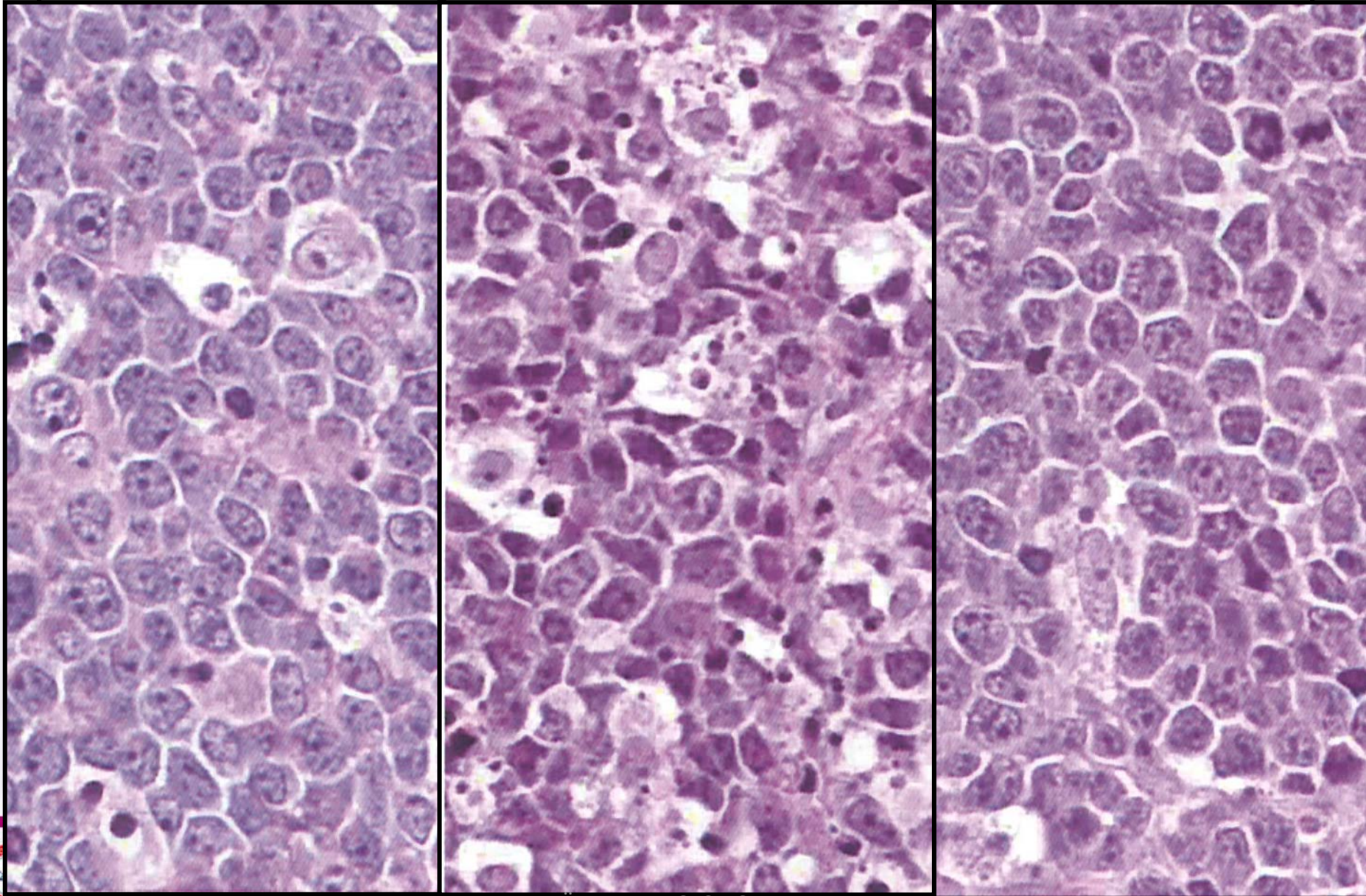
B-cell lymphoma, unclassifiable, with features intermediate between diffuse large B-cell lymphoma and classical Hodgkin lymphoma



**25. Ulusal Patoloji Kongresi**  
TÜRK HEMATOLOJİ OKULU  
**6. Sitopatoloji Kongresi**  
8. Klinik Patoloji Ortak Lenfoma Kursu

14 - 17 Ekim 2015 / Merinos AKKM - BURSA





25. **6. Sitopatoloji Kongresi**

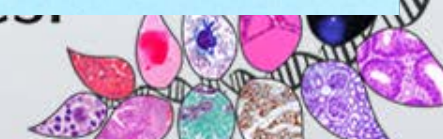8. Klinik Patoloji Ortak Lenfoma Kursu

14 - 17 Ekim 2015 / Melinos AKKM - BURSA



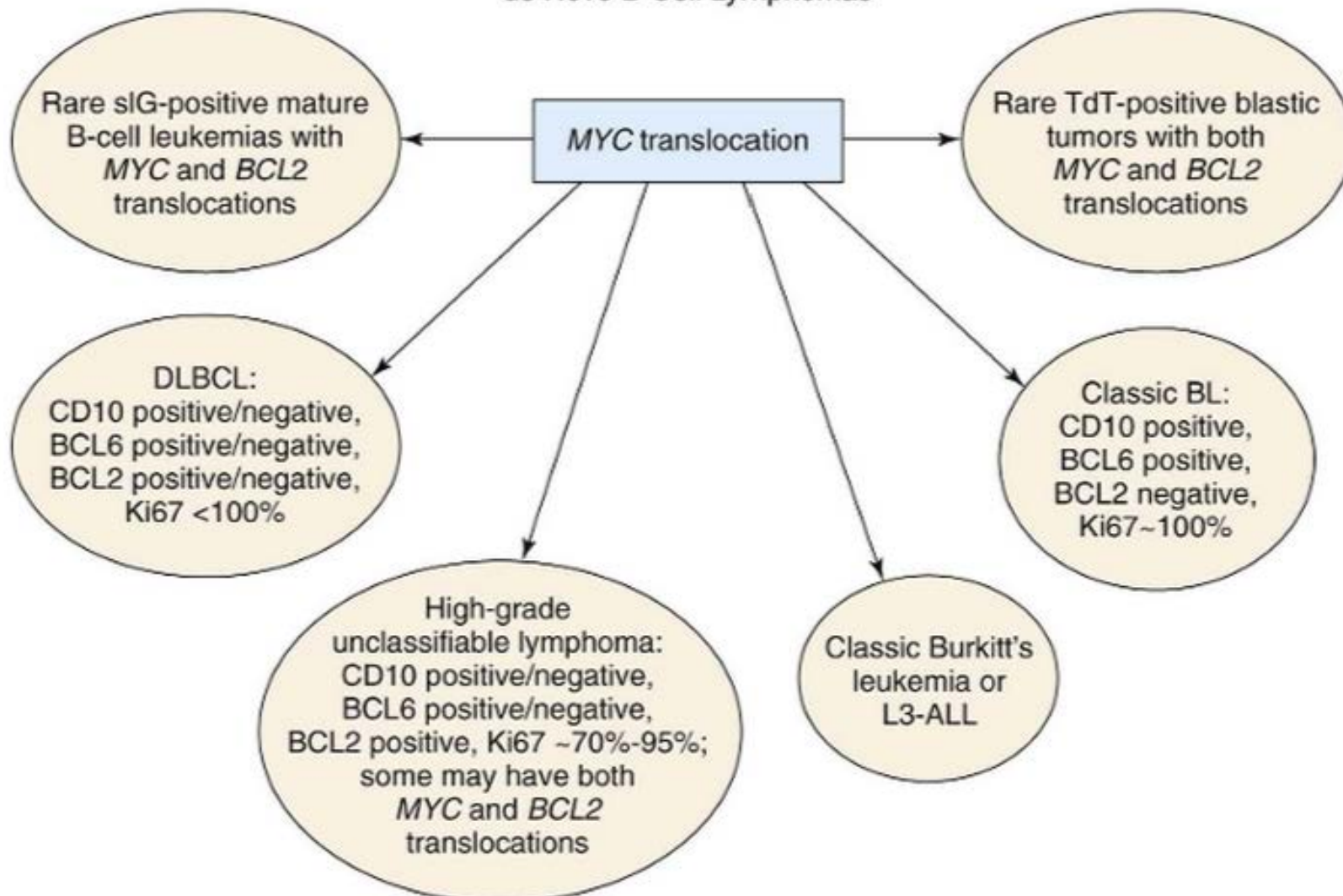


Characteristic	BL	Intermediate BL/DLBCL	DLBCL
<b>Morphology</b>			
Only small/medium-size cells	Yes	Common	No
Only large cells	No	No	Common
Mixture	No	Sometimes	Rare
<b>Proliferation (Ki67/MIB1)</b>			
>90% and homogeneous	Yes	Common	Rare
<90% or heterogeneous	No	Sometimes	Common
<b>BCL2 expression</b>			
Negative / weak	Yes	Sometimes	Sometimes
Strong	No	Sometimes	Sometimes
<b>Genetic features</b>			
<i>MYC</i> rearrangement	Yes*	Common	Rare
<i>IG-MYC</i> **	Yes	Sometimes	Rare
Non <i>IG-MYC</i> **	No	Sometimes	Rare
<i>BCL2</i> but no <i>MYC</i> rearrangement	No	Rare	Sometimes
<i>BCL6</i> but no <i>MYC</i> rearrangement	No	Rare	Sometimes
Double hit#	No	Sometimes	Rare
<i>MYC</i> -Simple karyotype***	Yes	Rare	Rare
<i>MYC</i> -Complex karyotype***	Rare	Common	Rare



# Myc translokasyonu Burkitt lenfomaya özgü müdür?

The Involvement of *MYC* in de Novo B-Cell Lymphomas



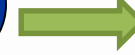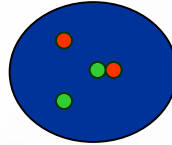
Klasik morfoloji Pediatrik Hasta  
CD20+, CD10+, Bcl-6+, Ki67(>%95), Bcl2-



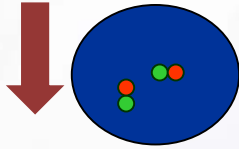
BL

Atipik morfoloji /immunfenotip Pediatrik Hasta  
Erişkin morfoloji /immunfenotip BL benzer  
CD20 +, CD10+, Bcl6+

Myc ayrılma probe FISH



Pediatric vakalar = BL



Erişkin  
İmmunfenotip  
Bcl2, Ki67 >%95  
Moleküler :FISH  
Bcl2, Bcl6

IHK: Bcl2 ++, Ki67 <%95,  
FISH: Bcl2 ve/veya Bcl6+

Morfolojiye dayalı olarak  
BL DBBHL arasında  
sınıflandırılmayan BHL

IHK: Bcl2 -/+ , Ki67 >%95,  
FISH: Bcl2 ve Bcl6 -

BL kabul et

25. Ulusal Hematoloji Kongresi  
6. Sitopatoloji Kongresi  
TÜRK HEMATOLOJİ OKULU  
8. Klinikyen Patoloji Ortak Lenfoma Kursu  
26-27 Nisan 2014 Ankara

14 - 17 Ekim 2015 / Mehmet AKK - BURSA

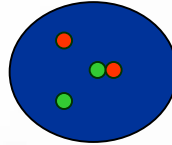


Klasik morfoloji Pediatrik Hasta  
CD20+, CD10+, Bcl-6+, Ki67(>%95), Bcl2-

BL

Atipik morfoloji /immunfenotip Pediatrik Hasta  
Erişkin morfoloji /immunfenotip BL benzer  
CD20 +, CD10+, Bcl6+

Myc ayrılma probe FISH



Pediatric vakalar = BL

**Erişkin  
İmmunfenotip**  
Bcl2, Ki67 >%95  
**Moleküler :FISH**  
Bcl2, Bcl6

IHK: Bcl2 ++, Ki67 <%95,  
FISH: Bcl2 ve/veya Bcl6+

Morfolojiye dayalı olarak  
BL DBBHL arasında  
sınıflandırılmayan BHL

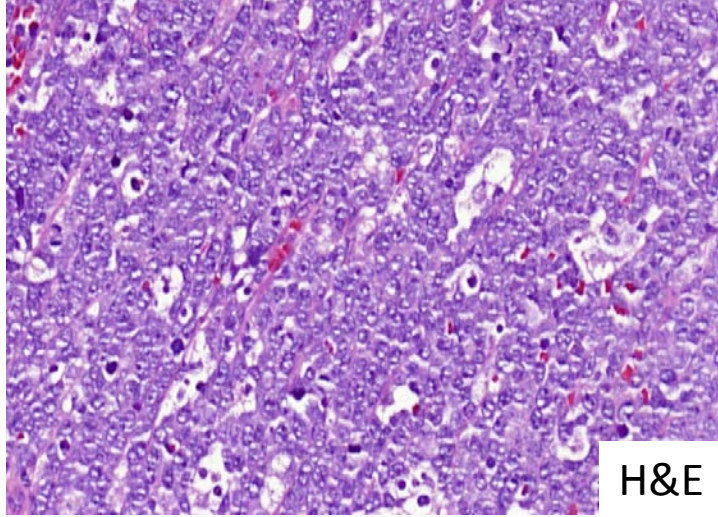
**IHK: Bcl2-/+ , Ki67 >%95,  
FISH: Bcl2 ve Bcl6 -**

BL

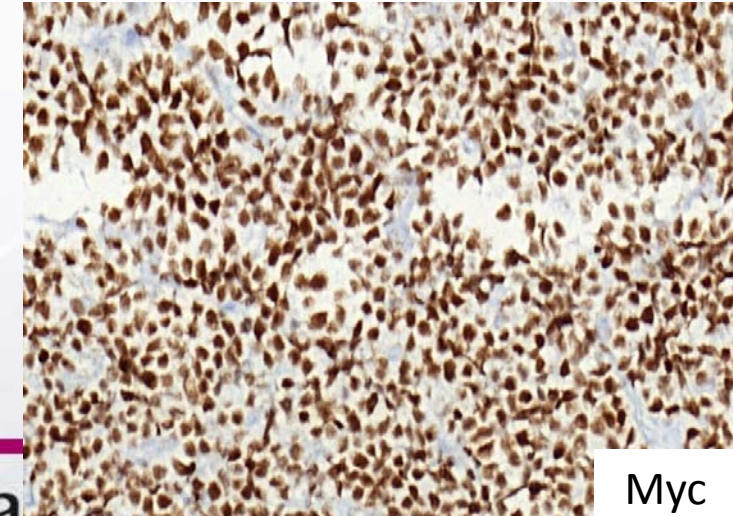
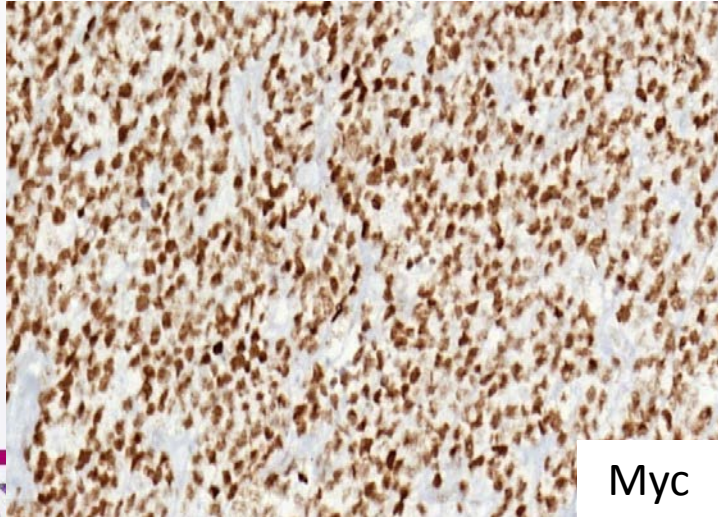
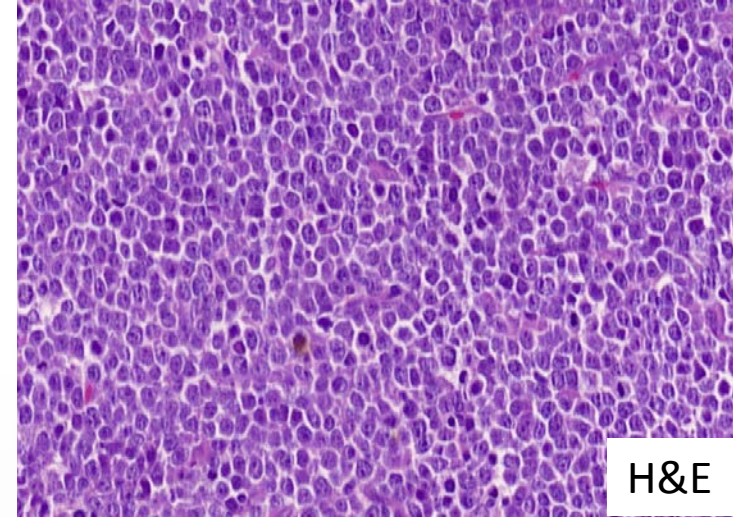
25. Ulusal Hematoloji ve Onkoloji Kongresi  
TÜRK HEMATOLOJİ OKULU  
8. Klinik Patoloji Ortak Lenfoma Kursu  
6. Sitopatoloji Kongresi

14 - 17 Ekim 2015 / Mehmet AKKÖK - BURSA

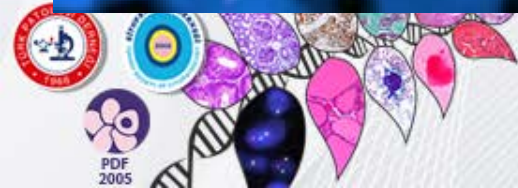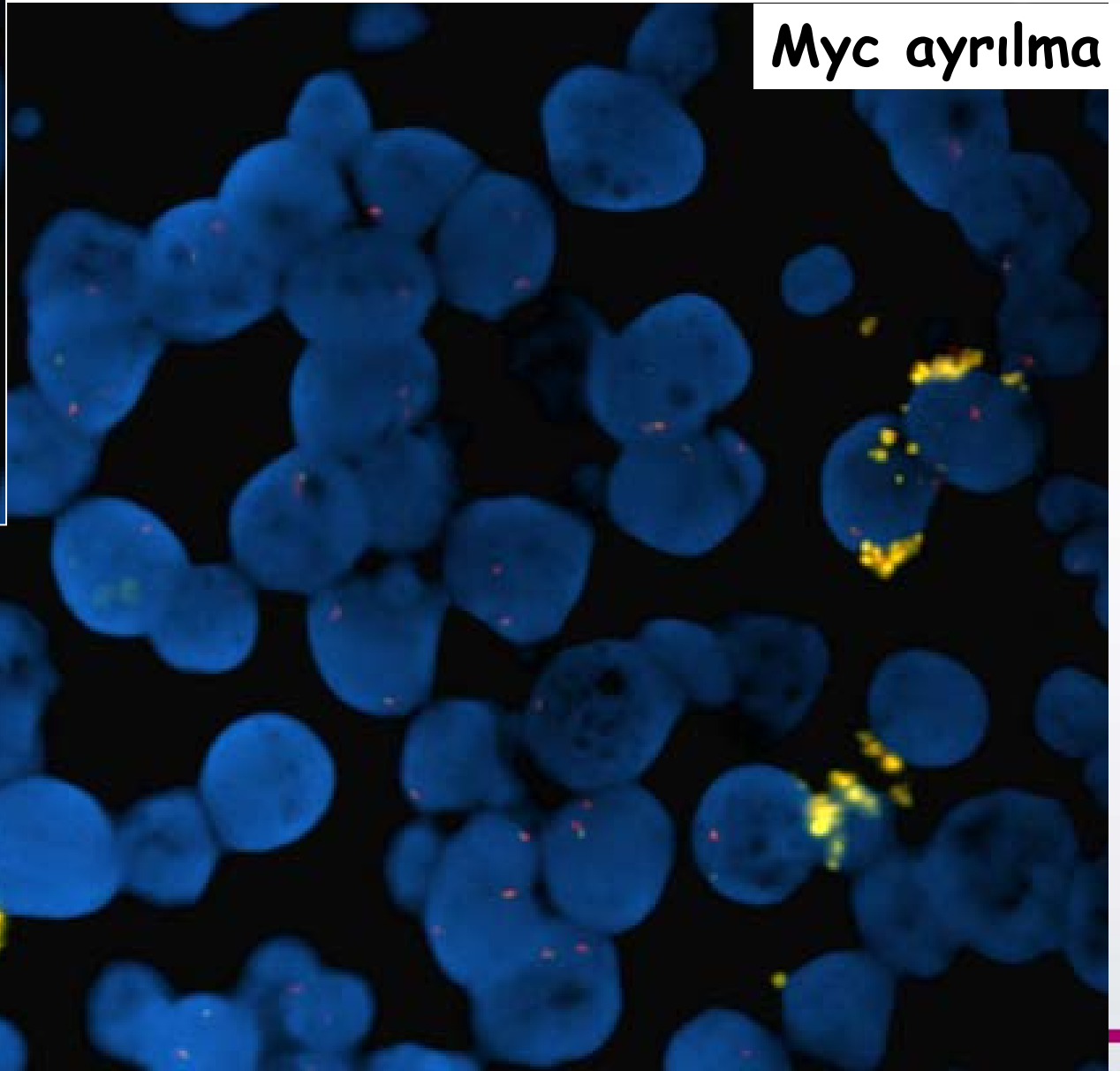
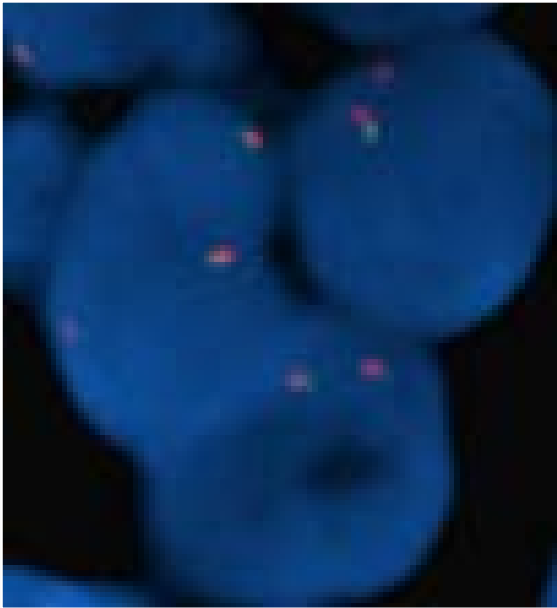
## Burkitt Lenfoma



## Diffüz Büyük B Hücreli Lenfoma



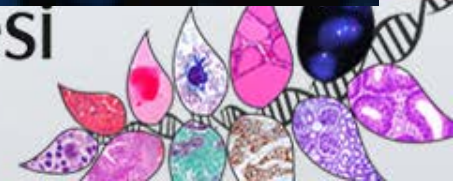Myc ayrılma



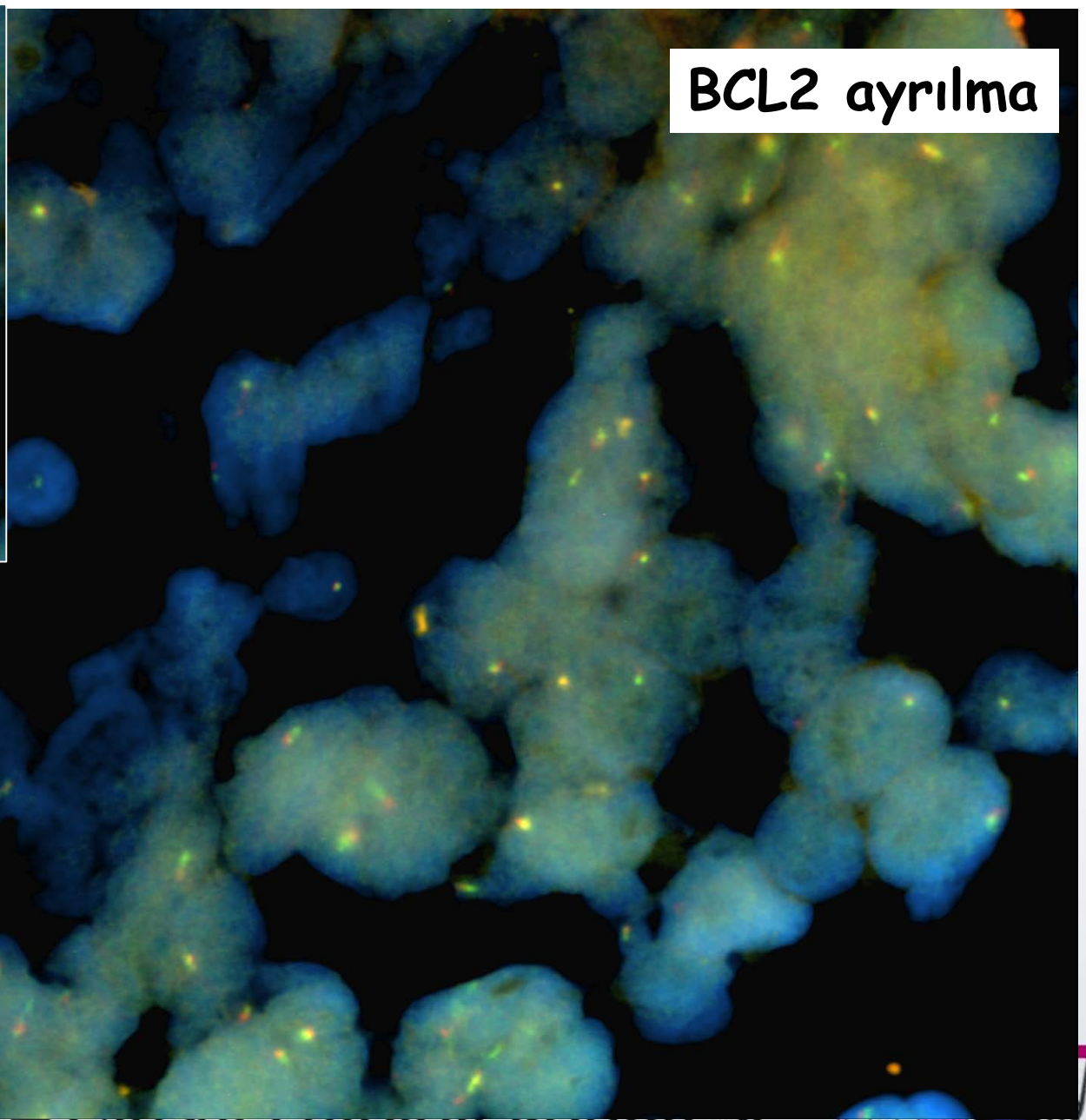
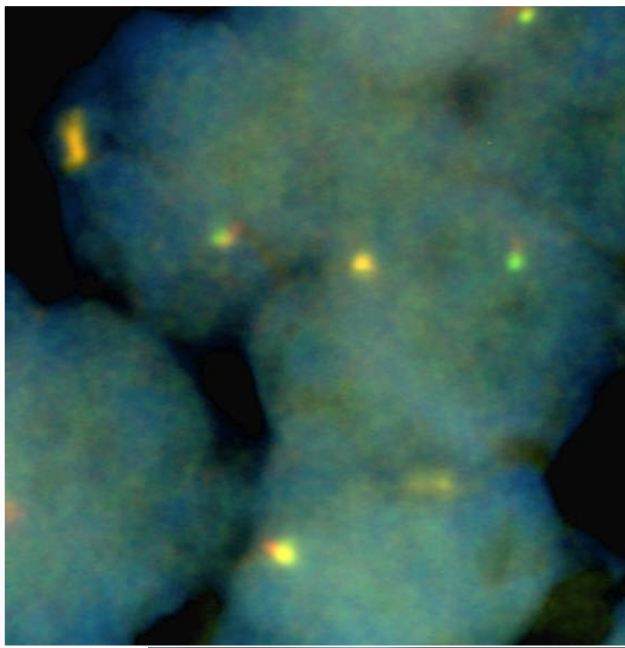
25. Ulusal Patoloji Kongresi  
TÜRK HEMATOLOJİ OKULU  
6. Sitopatoloji Kongresi

8. Klinikyen Patoloji Ortak Perfora Kursu

14 - 17 Ekim 2015 / Melihos AKKM - BURSA

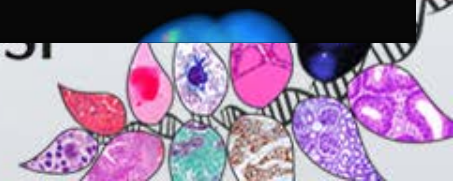


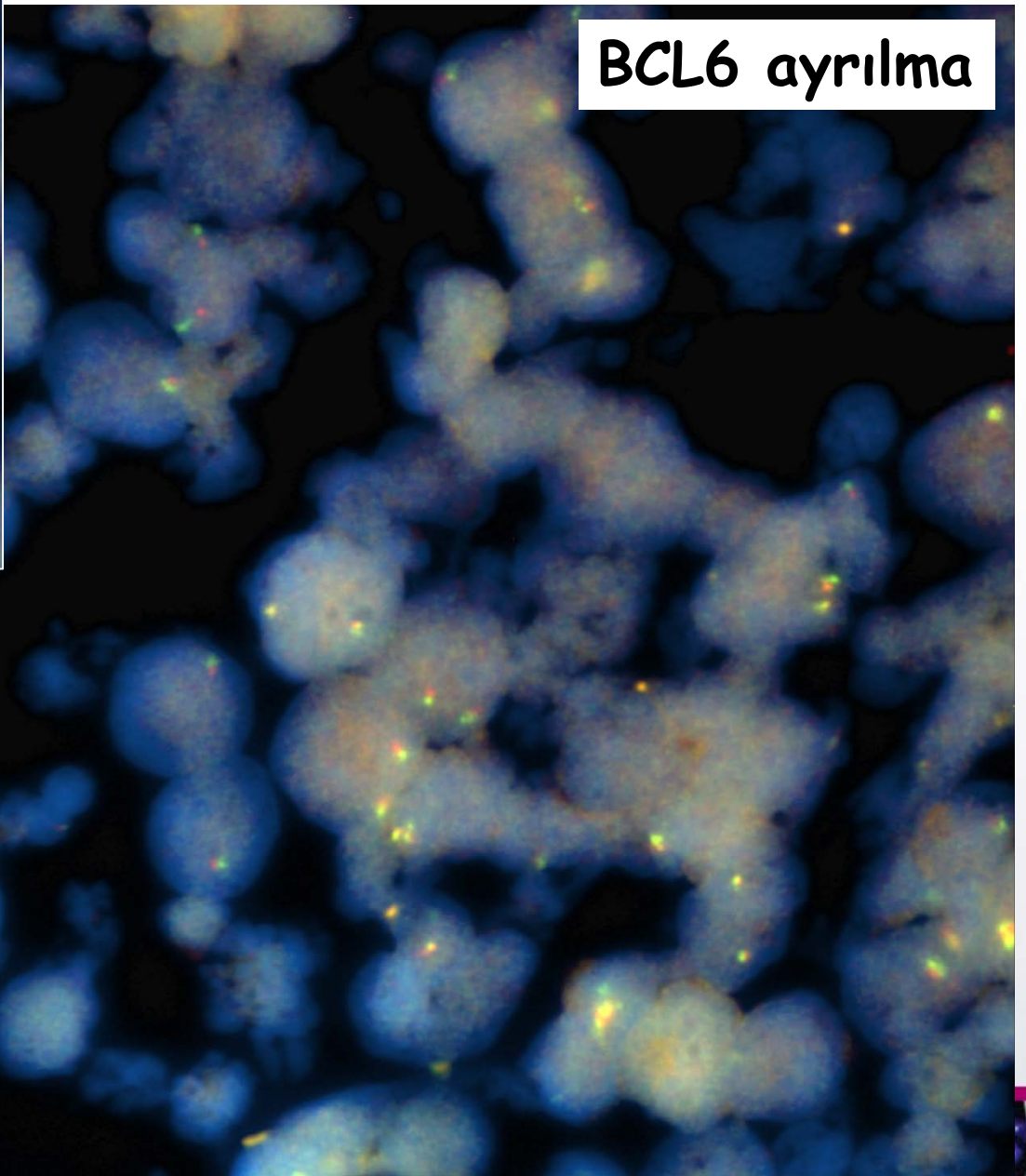
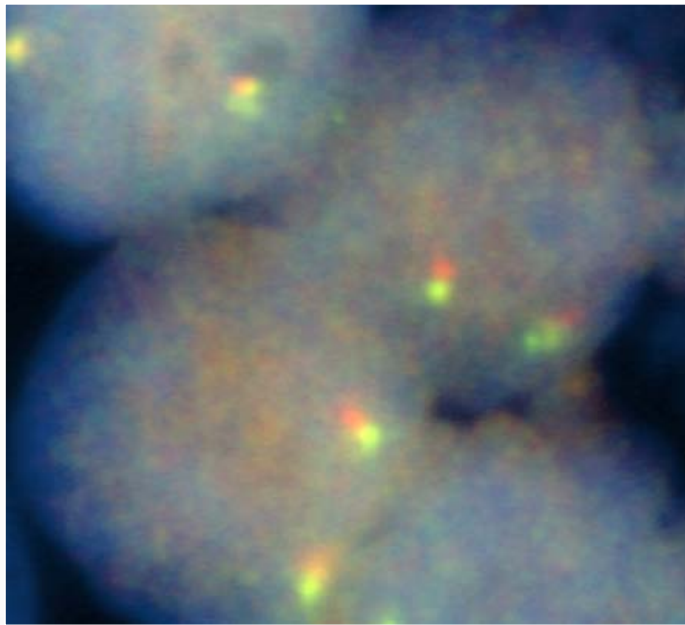
BCL2 ayrılma



25. Bursa Patoloji Kongresi  
6. Sitopatoloji Kongresi

14 - 17 Ekim 2015 / Merinos AKKM - BURSA



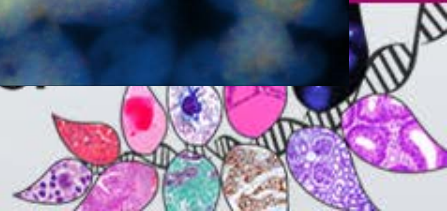


BCL6 ayrılma



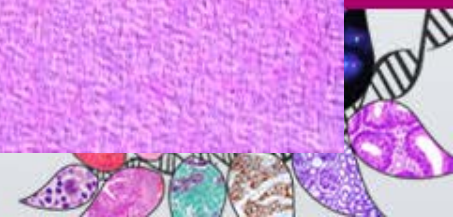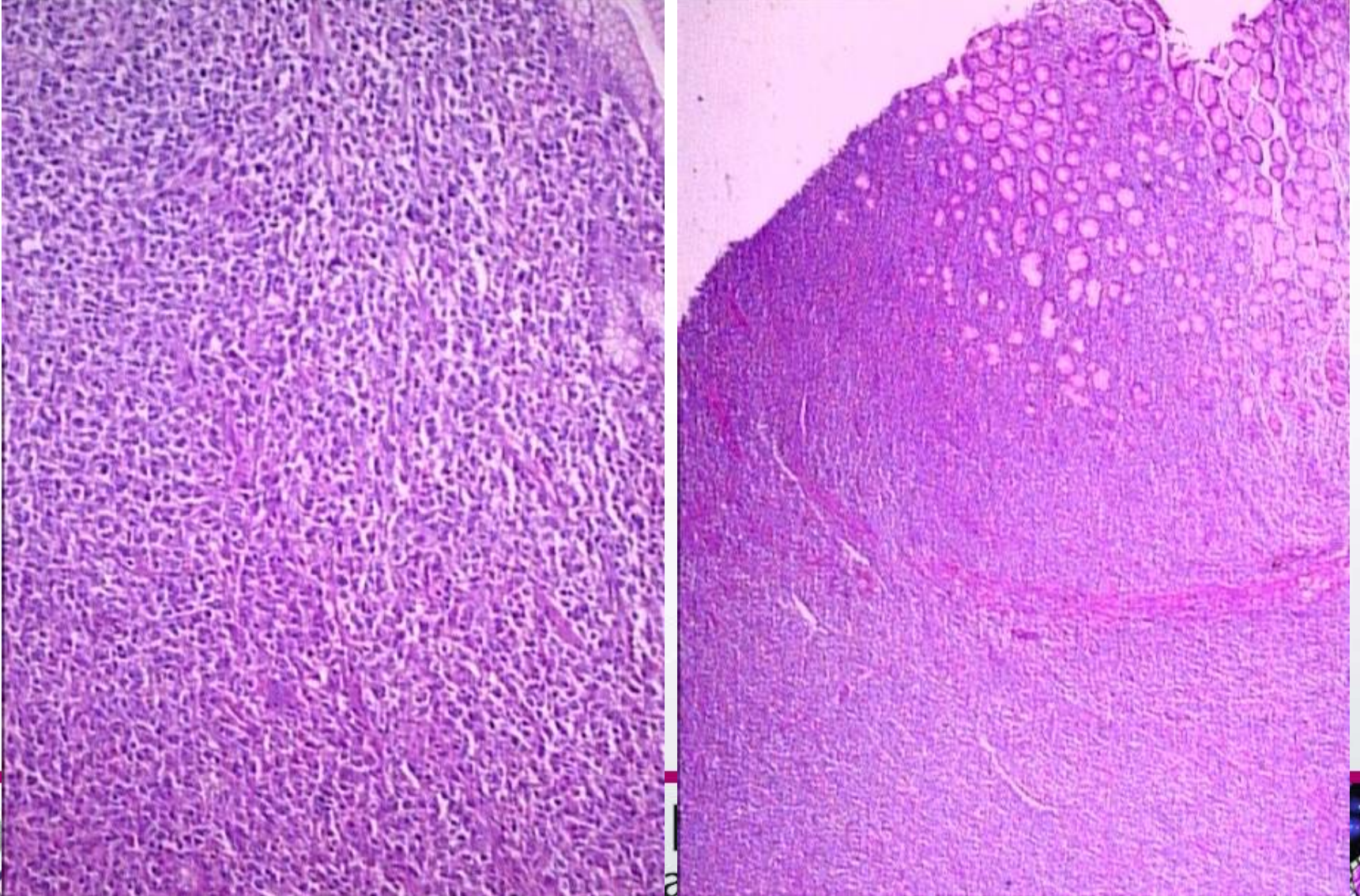
## 6. Sitopatoloji Kongresi

14 - 17 Ekim 2015 / Merinos AKKM - BURSA

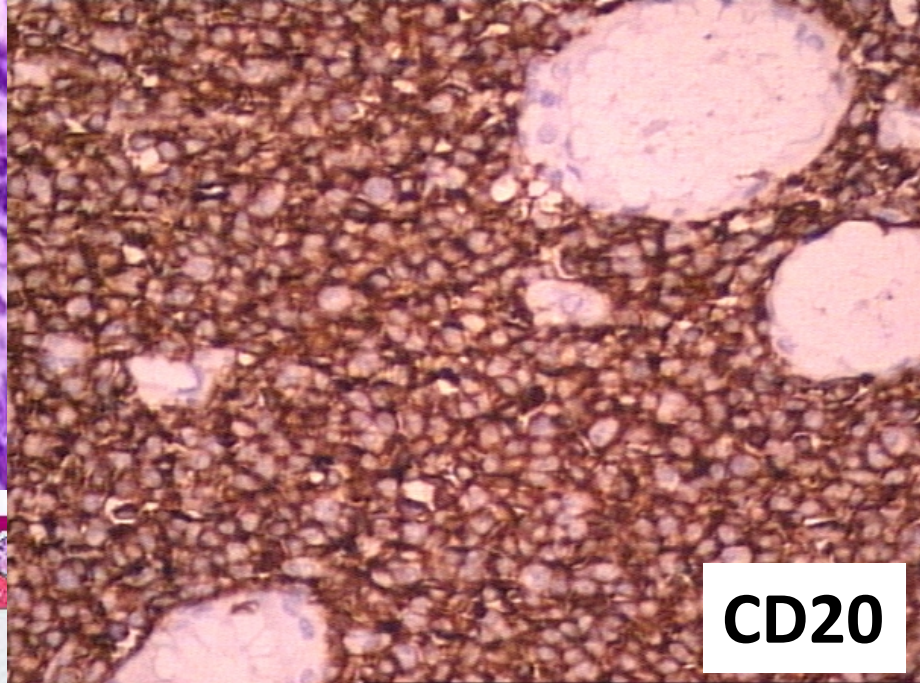
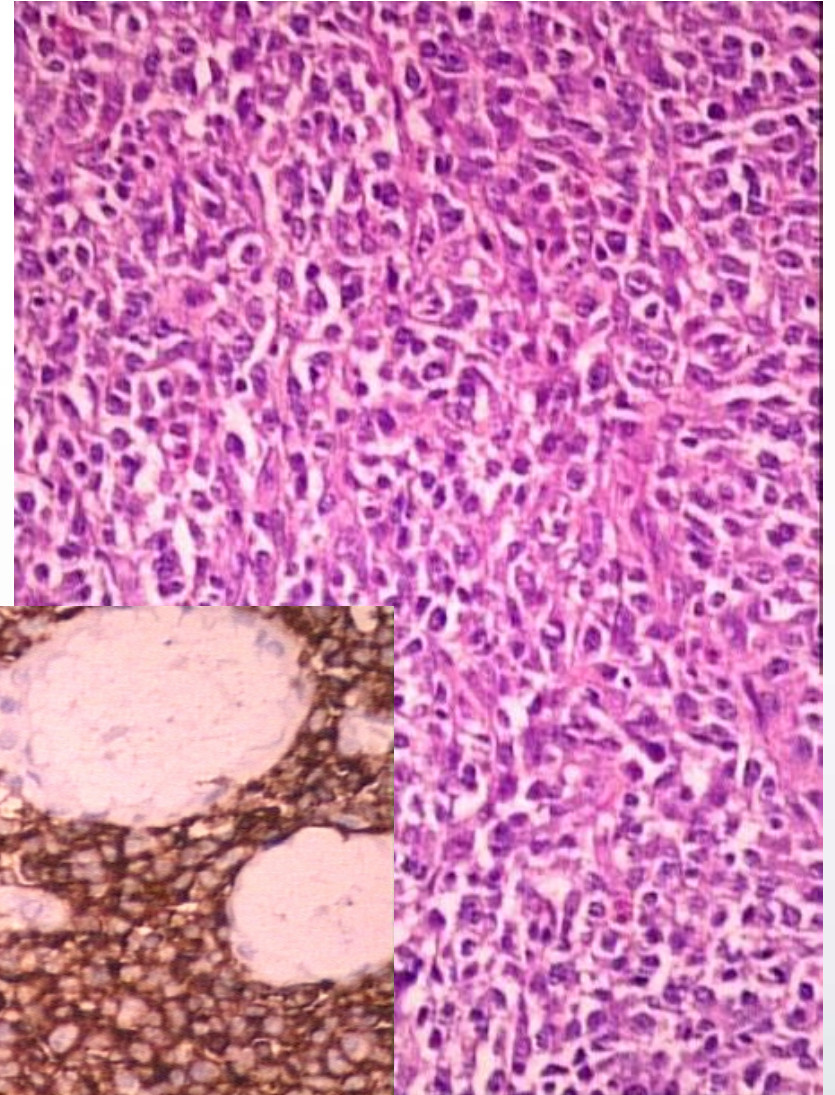
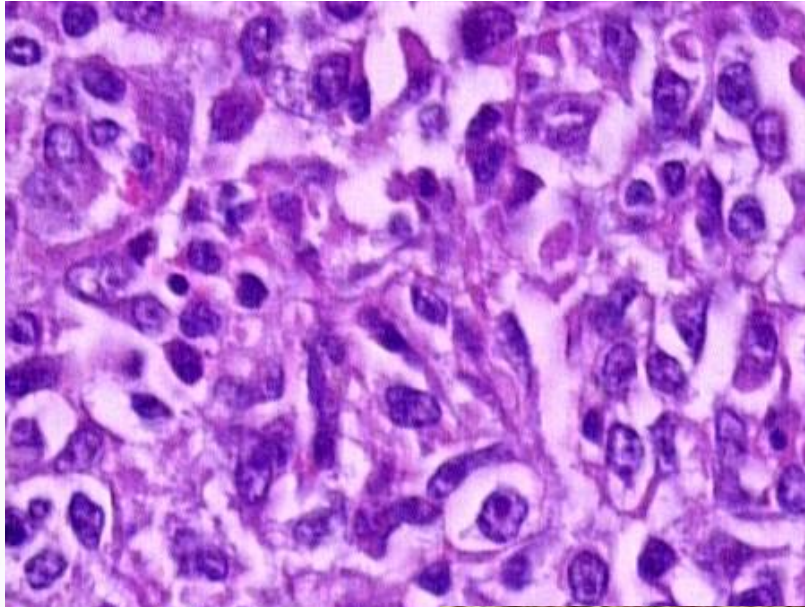




# Diffüz Büyük B Hücreli Lenfoma DLBCL

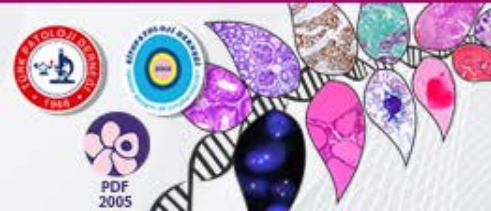

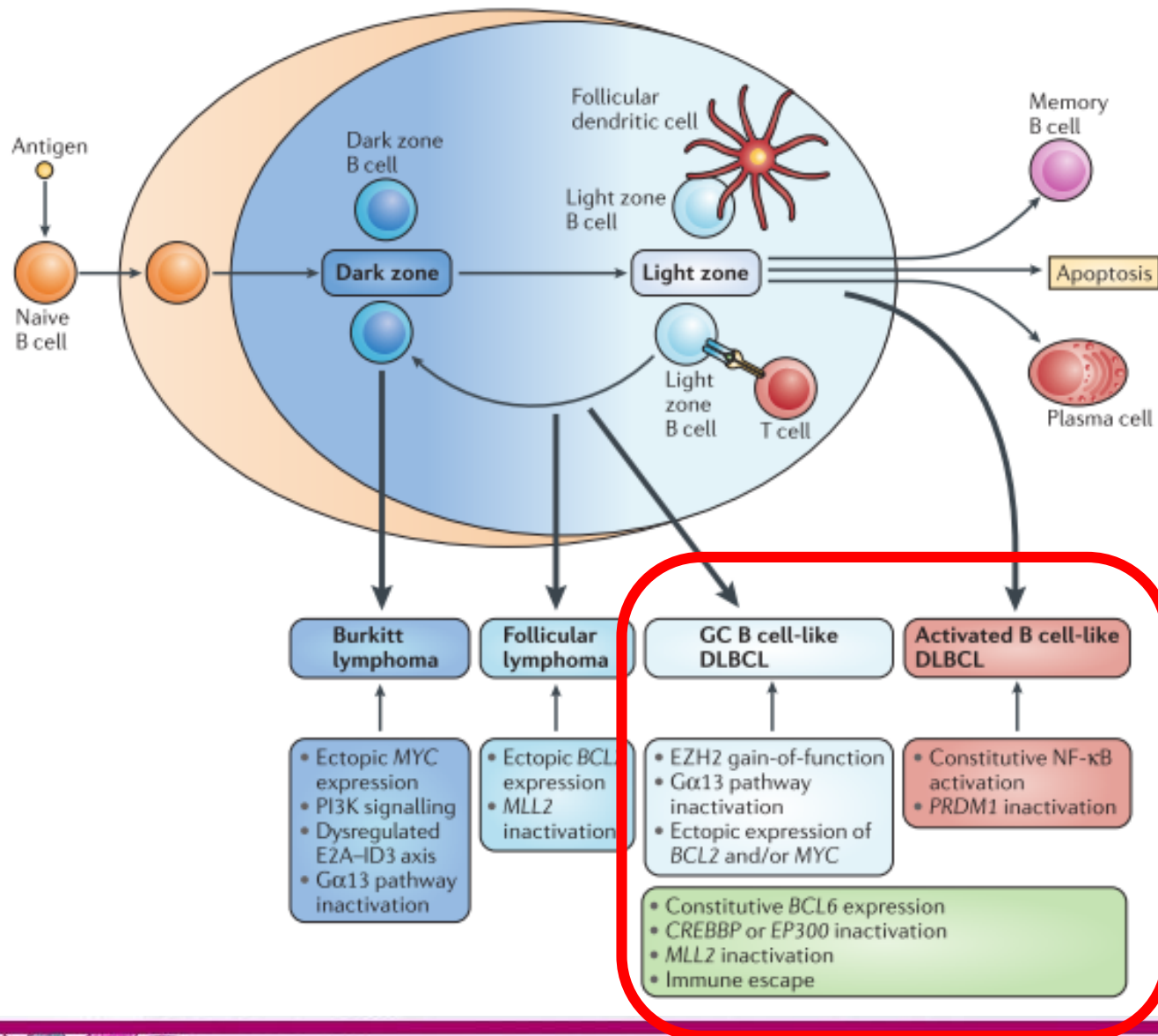
# Diffüz Büyük B Hücreli Lenfoma (DLBCL)



**CD20**

esi





# 25. Ulusal Patoloji Kongresi

## 6. Sitopatoloji Kongresi

14 - 17 Ekim 2015 / Merinos AKKM - BURSA



# CD20 NEGATİF AGRESSİF B HÜCRELİ LENFOMALAR

PLAZMABLASTİK LENFOMA  
PRİMER EFFÜZYON LENFOMASI  
YAŞLIŞARIN EBVE İLİŞKİLİ DBBHL

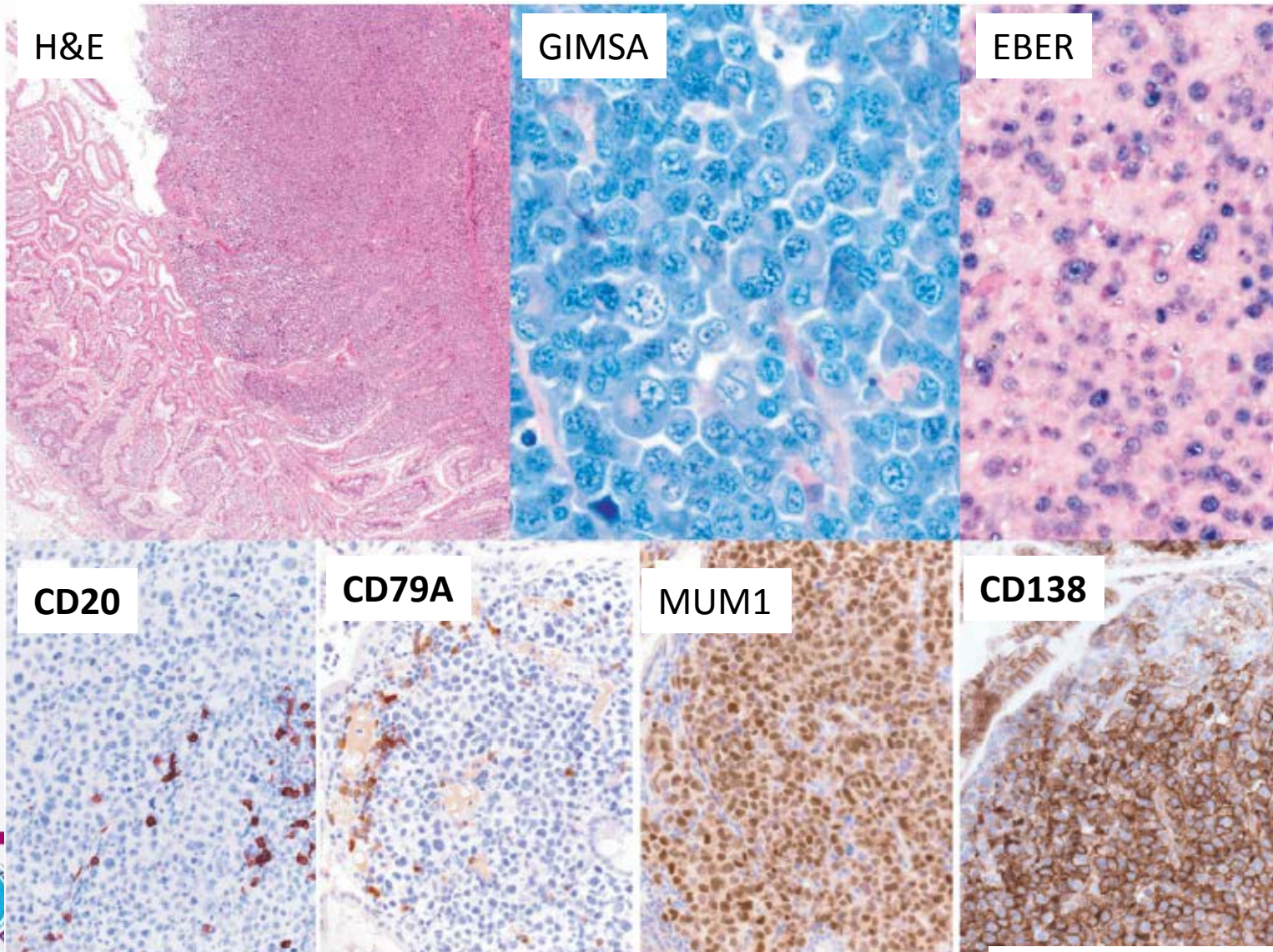


**25.** Ulusal Patoloji Kongresi  
**6.** Sitopatoloji Kongresi

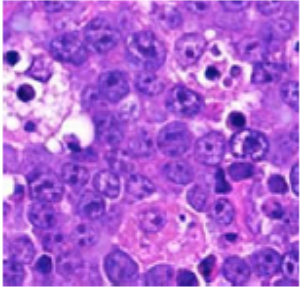
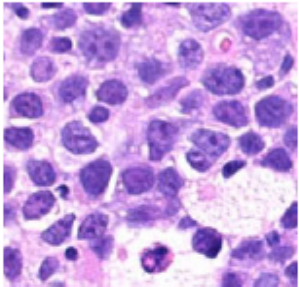
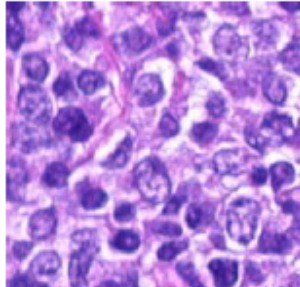
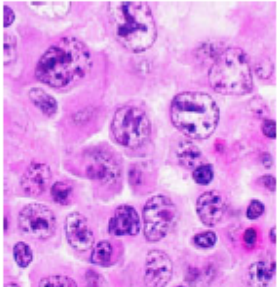
14 - 17 Ekim 2015 / Merinos AKKM - BURSA



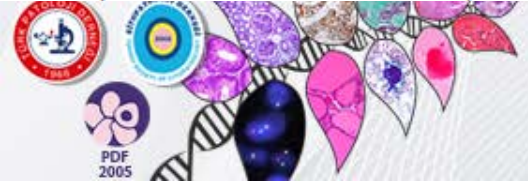# PLAZMABLASTİK LENFOMA



**Table 3.** Key points in comparison between Burkitt lymphoma (BL), B-cell lymphoma unclassifiable with features intermediate between diffuse large B-cell lymphoma (DLBCL) and BL (BCL-U-DLBCL/BL), DLBCL and plasmablastic lymphoma (PBL)

	BL	BCL-U-DLBCL/BL	DLBCL	PBL
Epidemiology	Adolescents or adults, male predominance, HIV	Adults, rare in the intestines	Any age, more common in older adults	HIV or immunocompromised adults
Morphology				
Immunophenotype	CD20 <sup>+</sup> PAX5 <sup>+</sup> CD79a <sup>+</sup> MUM1 <sup>-</sup> CD138 <sup>-</sup> BCL2 <sup>-</sup> CD10 <sup>+</sup> BCL6 <sup>+</sup> Ki67 100%	CD20 <sup>+</sup> PAX5 <sup>+</sup> CD79a <sup>+</sup> MUM1 <sup>-/+</sup> CD138 <sup>-</sup> BCL2 variable CD10 <sup>+/-</sup> BCL6 <sup>+/-</sup> Ki67 >90% homogeneous	CD20 <sup>+</sup> PAX5 <sup>+</sup> CD79a <sup>+</sup> MUM1 <sup>+/-</sup> CD138 <sup>-</sup> BCL2 <sup>+/-</sup> CD10 <sup>-/+</sup> BCL6 <sup>+/-</sup> Ki67 <90% heterogeneous	CD20 <sup>-</sup> PAX5 <sup>-</sup> CD79a <sup>-/+</sup> MUM1 <sup>+</sup> CD138 <sup>+</sup> BCL2 <sup>+/-</sup> CD10 <sup>-</sup> BCL6 <sup>-</sup> Ki67 >90%
Genetics	<i>MYC</i> rearrangement constant, simple karyotype	<i>MYC</i> rearrangement frequent, <sup>+/-</sup> <i>BCL2</i> and/or <i>BCL6</i> rearrangement	<i>BCL6</i> or <i>MYC</i> rearrangement in a subset of cases	<i>MYC</i> rearrangement frequent
EBV status	Subset of cases EBV-positive	EBV-negative	Rare cases EBV-positive	Most cases EBV-positive

EBV, Epstein-Barr virus; MUM1, Multiple myeloma oncogene 1; BCL, B cell lymphoma; PAX, Paired box.



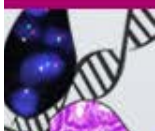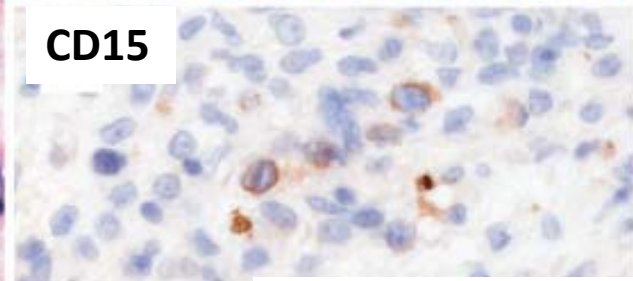
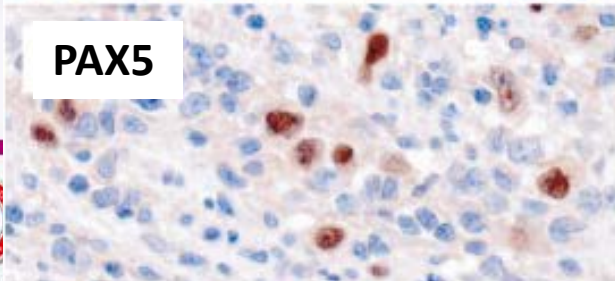
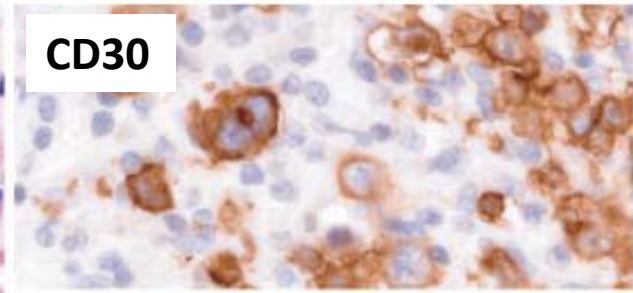
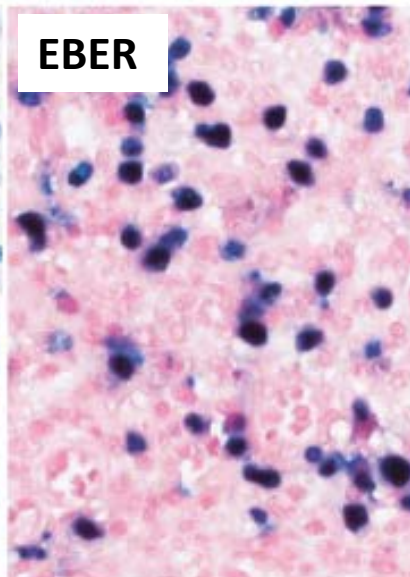
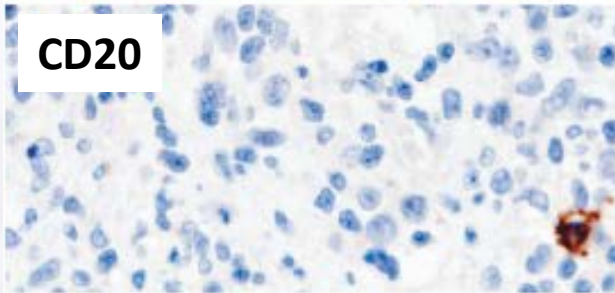
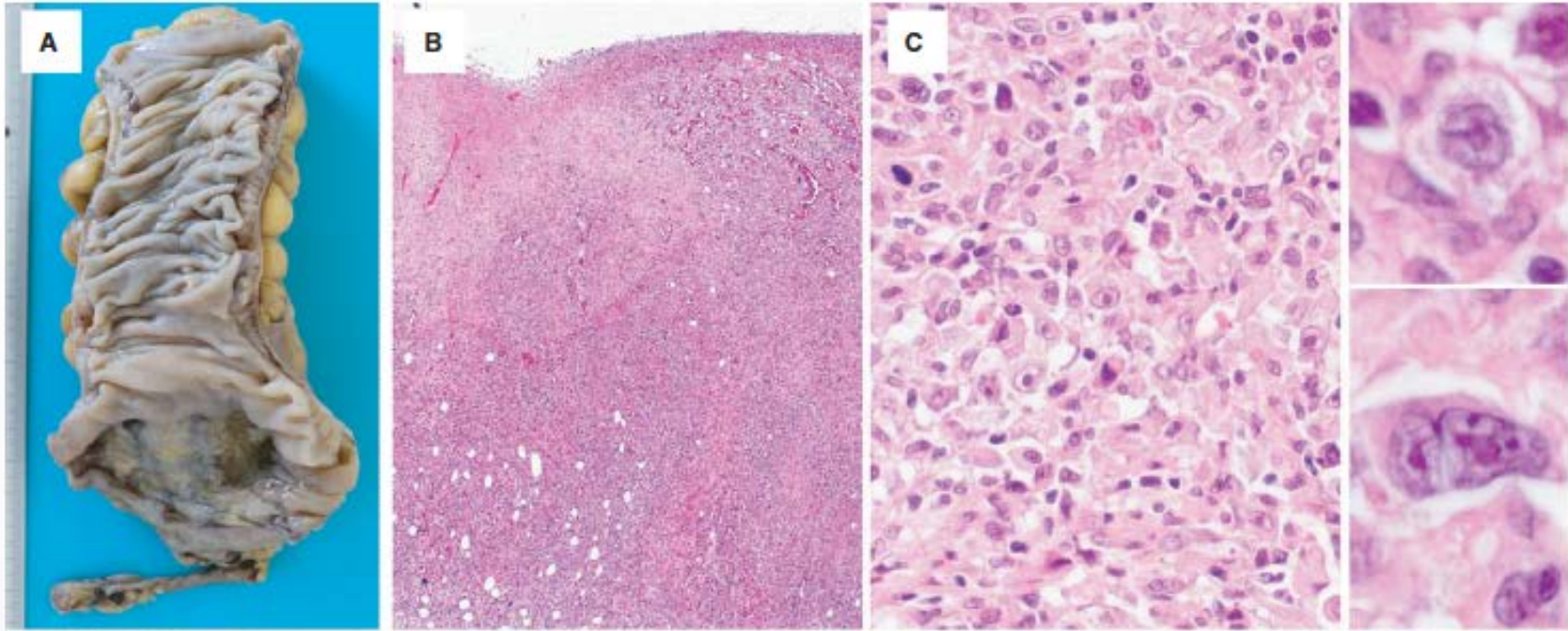
**25** Ulusal Patoloji Kongresi  
**6.** Sitopatoloji Kongresi

14 - 17 Ekim 2015 / Merinos AKKM - BURSA

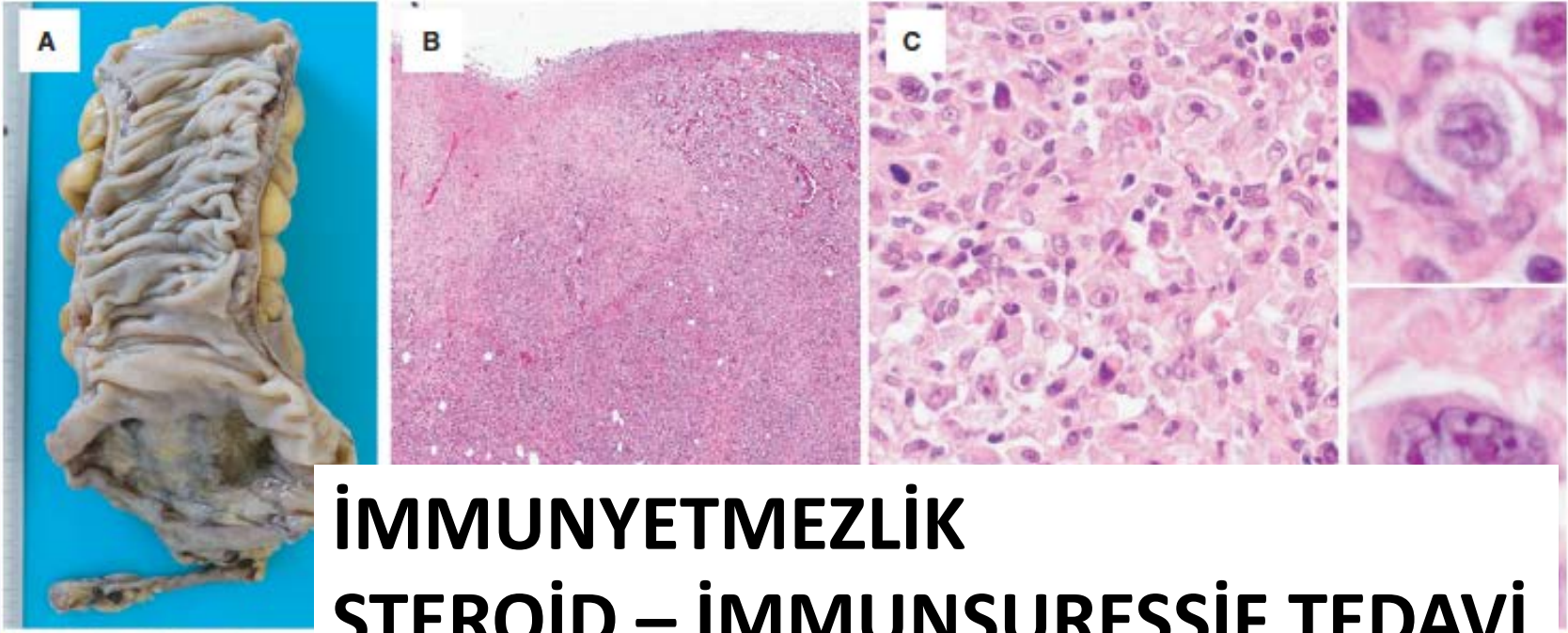**Foukas Histopath 2015**



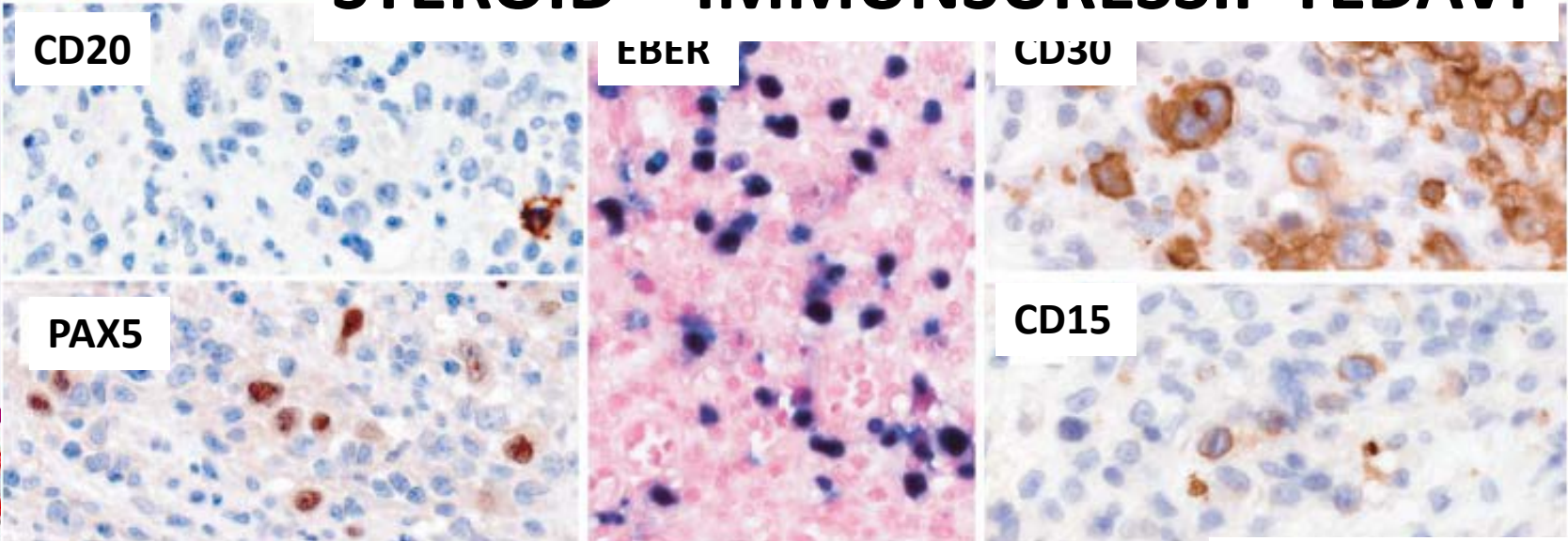
# EBV POZİTİF MUKOKUTANÖZ ÜLSER



# EBV POZİTİF MUKOKUTANÖZ ÜLSER



## İMMUNYETMEZLİK STEROİD – İMMUNSÜRESSİF TEDAVİ





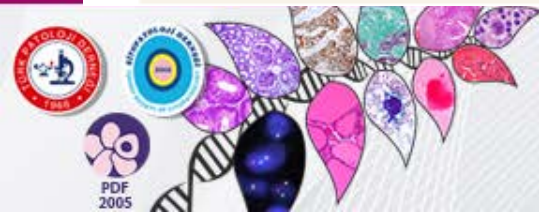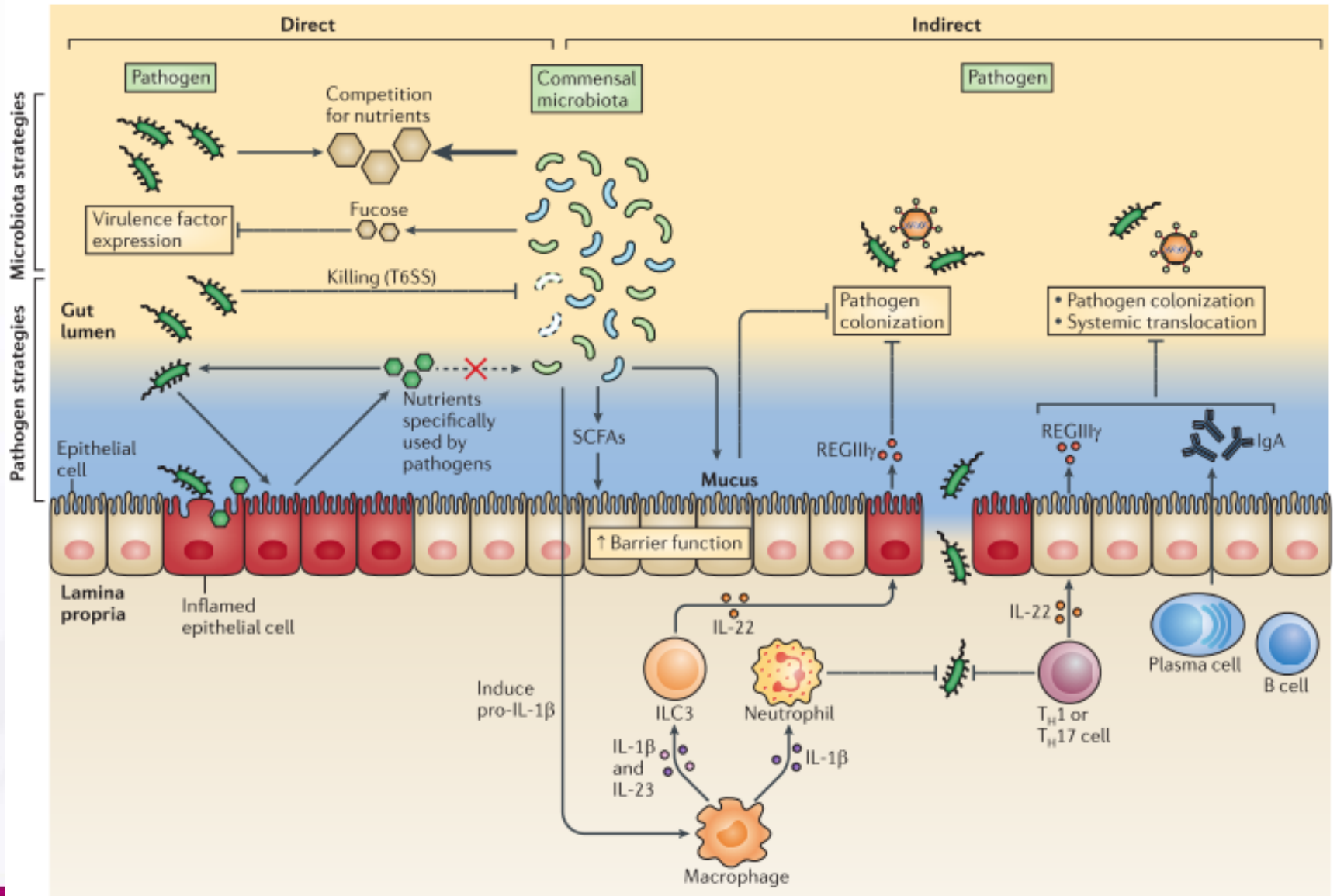
# T HÜCRELİ LENFOMALAR



**25.** Ulusal Patoloji Kongresi  
**6.** Sitopatoloji Kongresi

14 - 17 Ekim 2015 / Merinos AKKM - BURSA

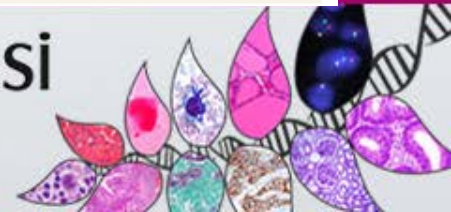



# 25. Ulusal Patoloji Kongresi

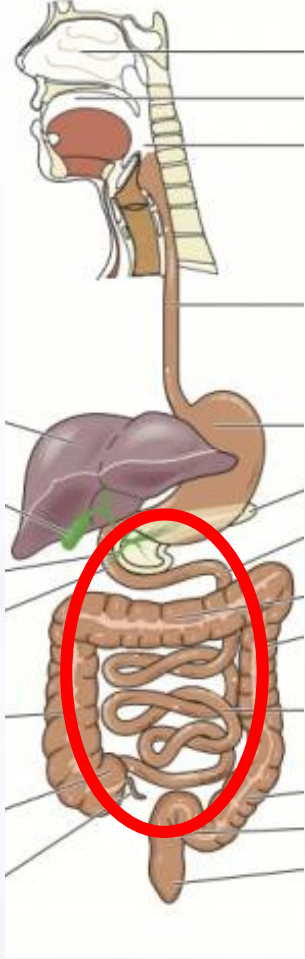
## 6. Sitopatoloji Kongresi

14 - 17 Ekim 2015 / Merinos AKKM - BURSA



# SİNDİRİM KANALI

## T HÜCRELİ LENFOMALAR



**25.** Ulusal Patoloji Kongresi  
**6.** Sitopatoloji Kongresi

14 - 17 Ekim 2015 / Merinos AKKM - BURSA



# ENTEROPATİ TİPİ T HÜCRELİ LENFOMA

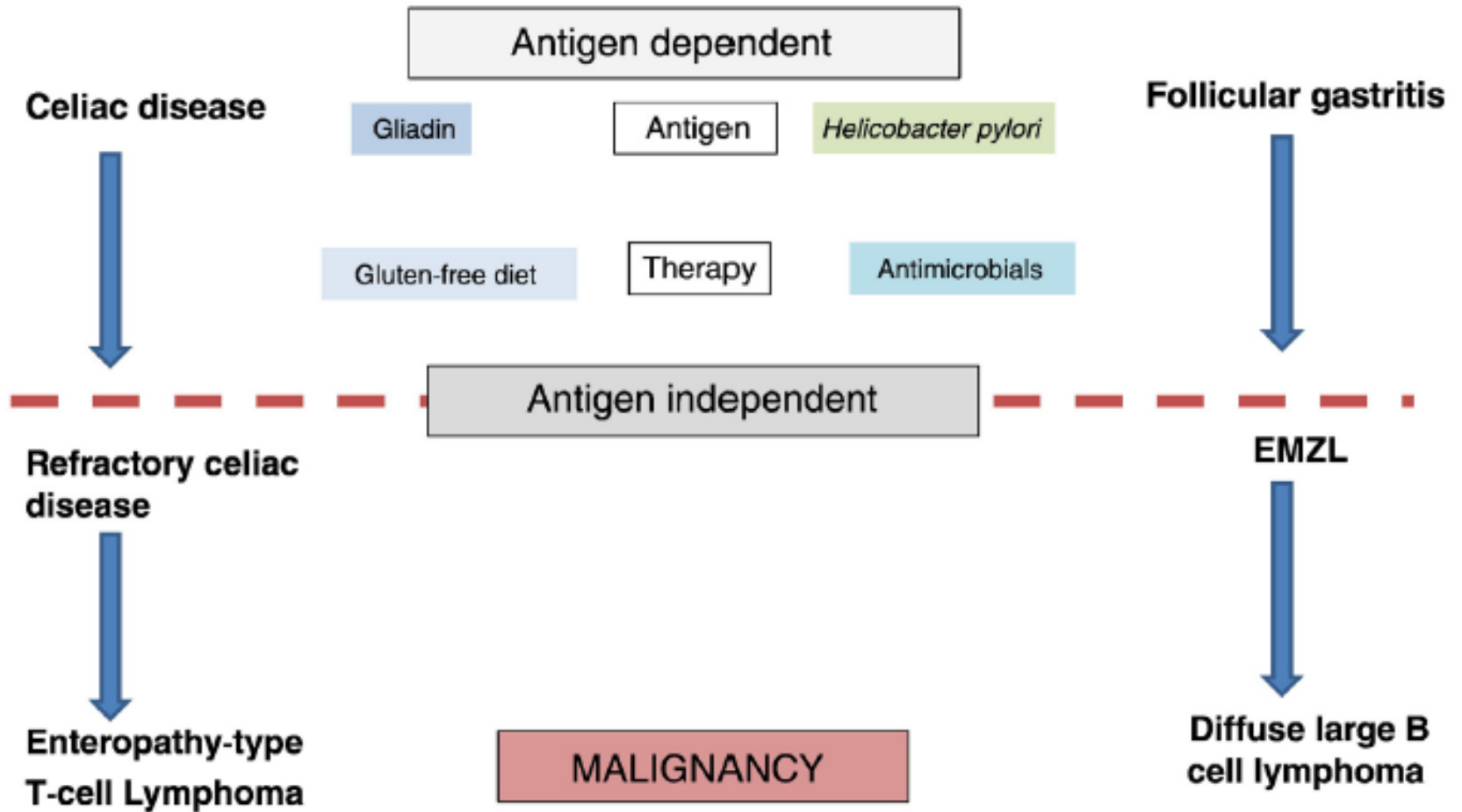
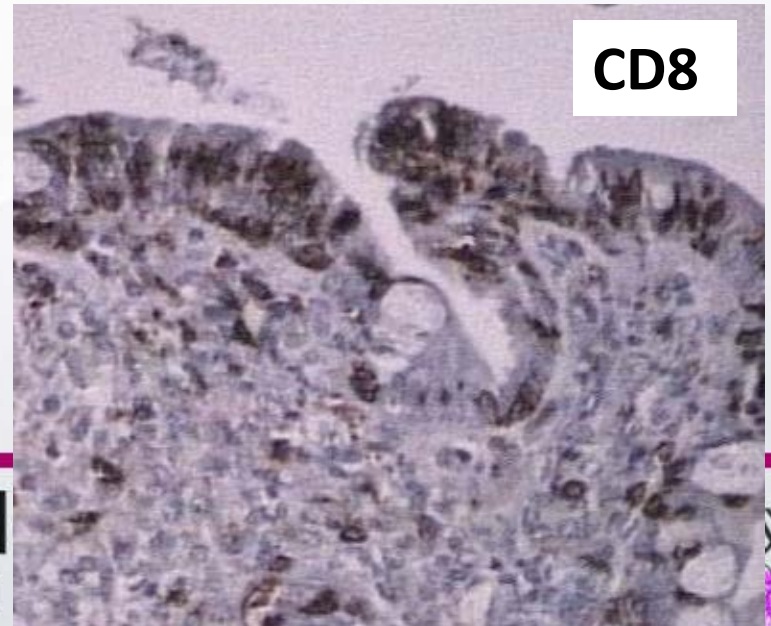
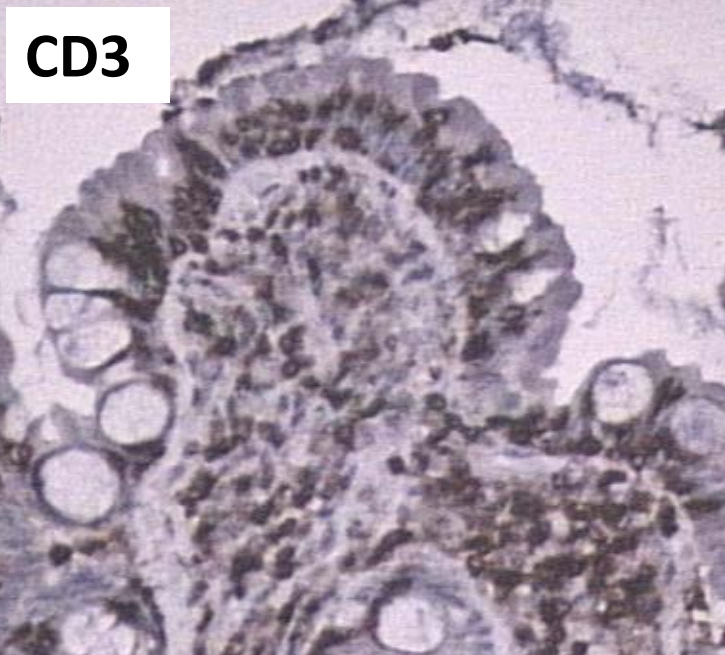

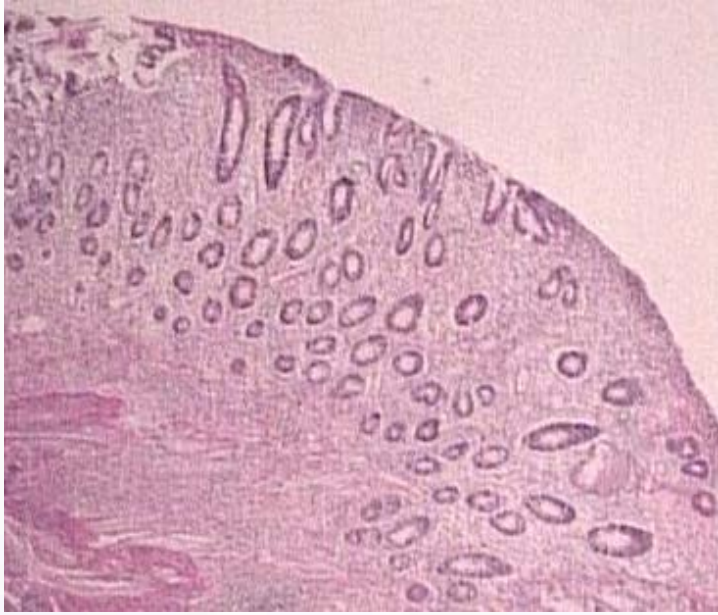


Fig. 9 Comparison of enteropathy-associated T cell lymphoma to extranodal marginal zone lymphoma.



# GLUTEN ENTEROPATİSİ

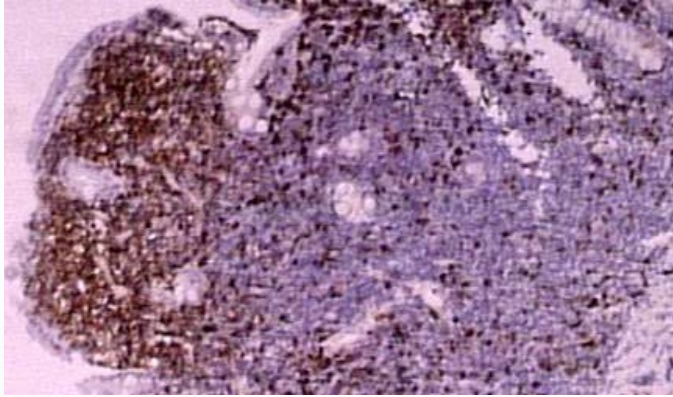


İnsanal Patoloji  
5. Sitopatoloji

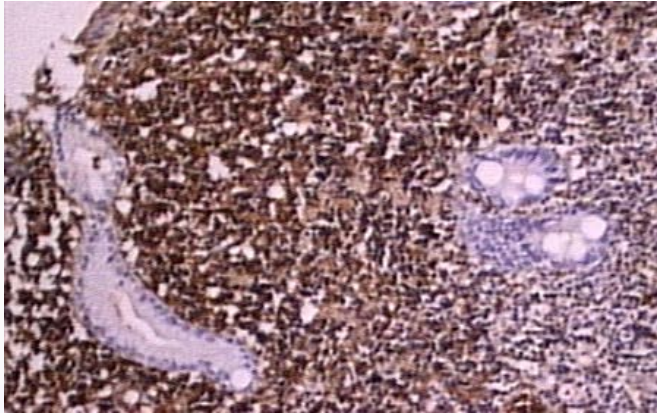


# REFRAKTER SPRUE

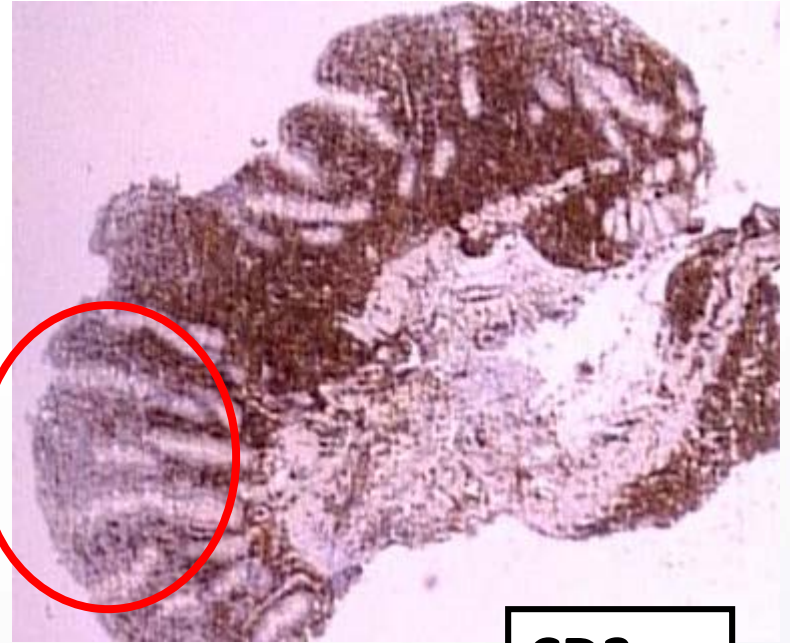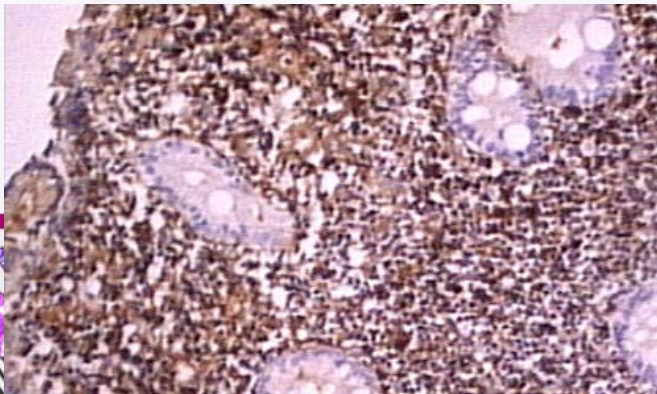
CD79a



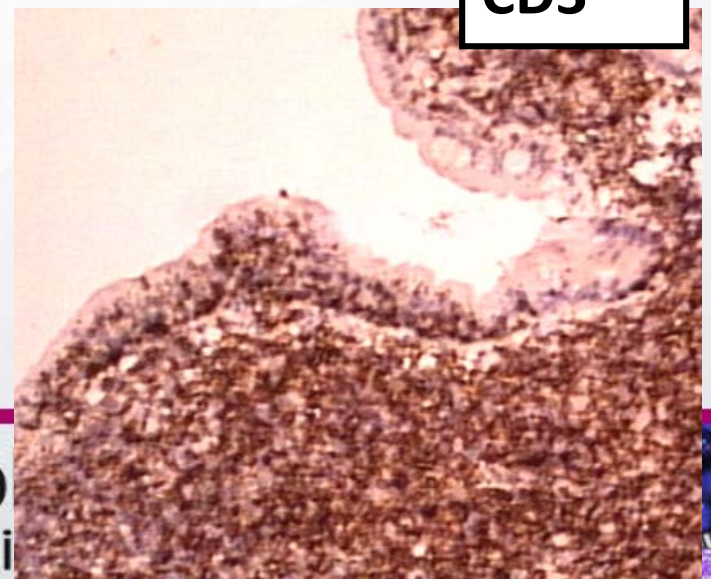
KAPPA



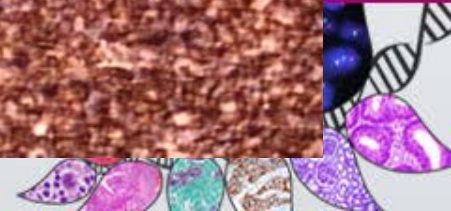
LAMBDA



CD3

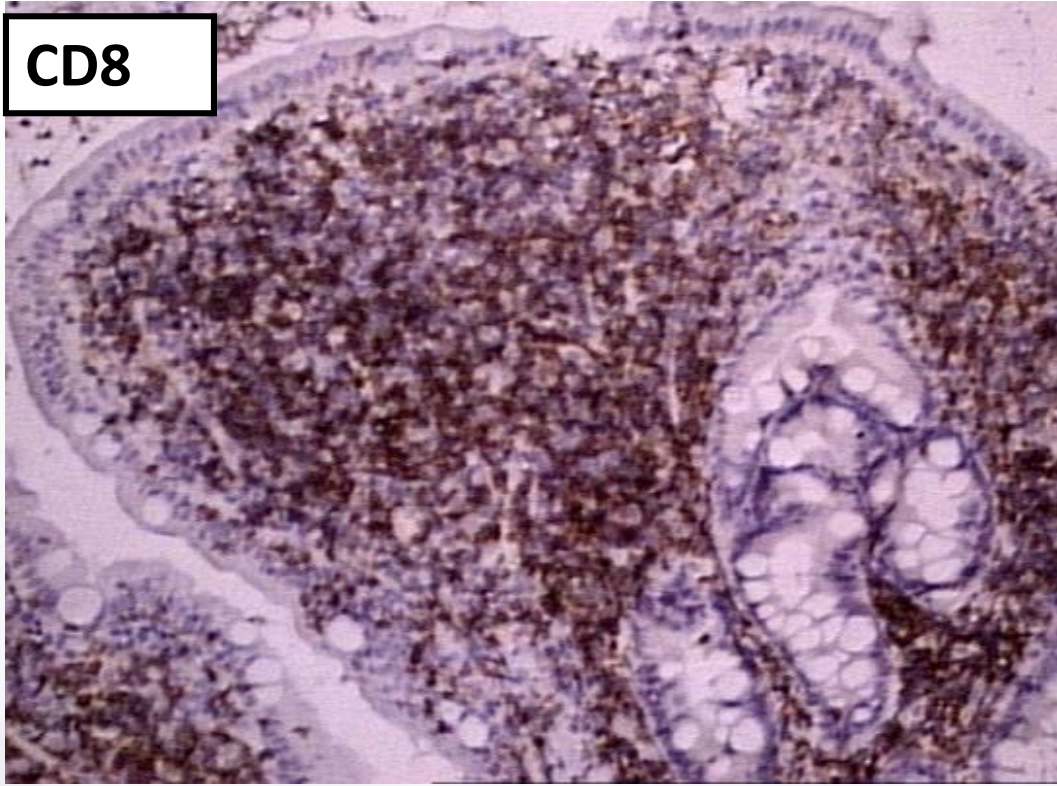


al Pato  
opatoloji

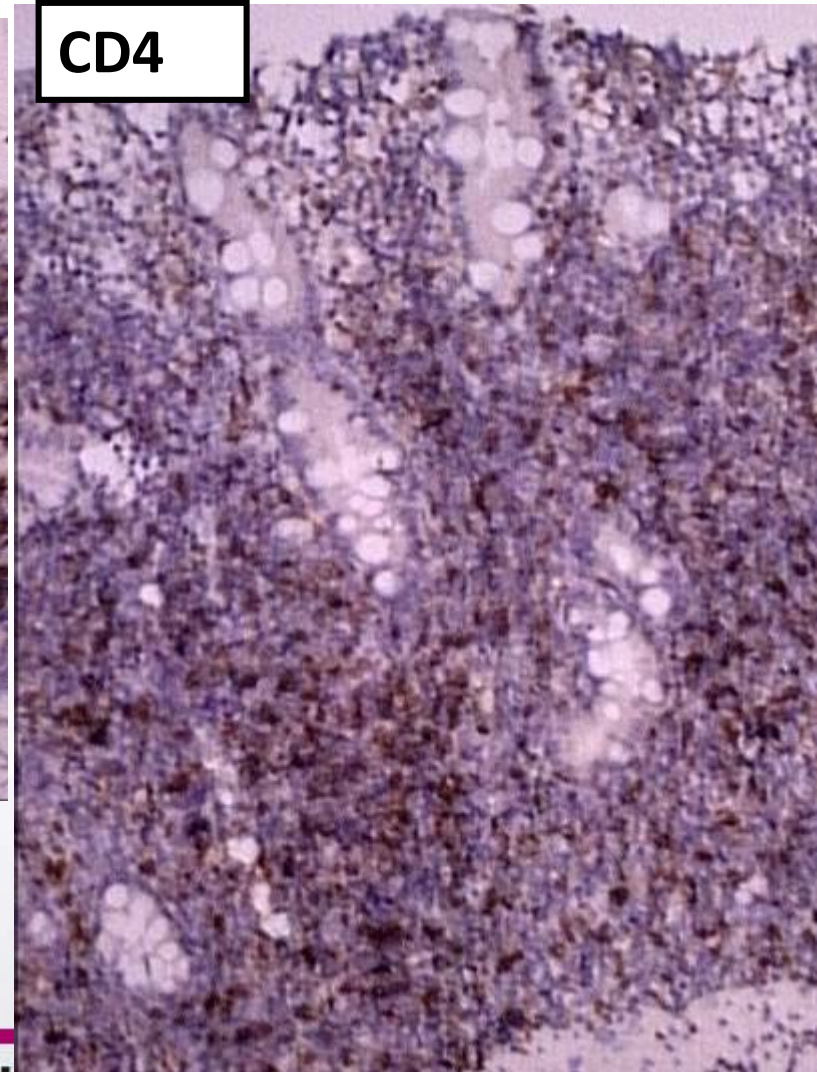


# REFRAKTER SPRUE

CD8



CD4



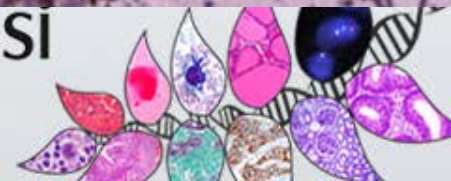LOW GRADE EATCL ?

PCR

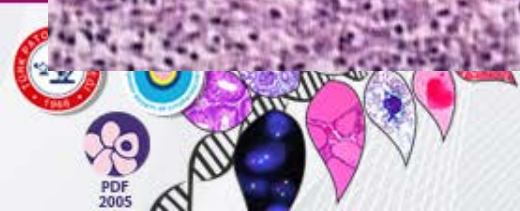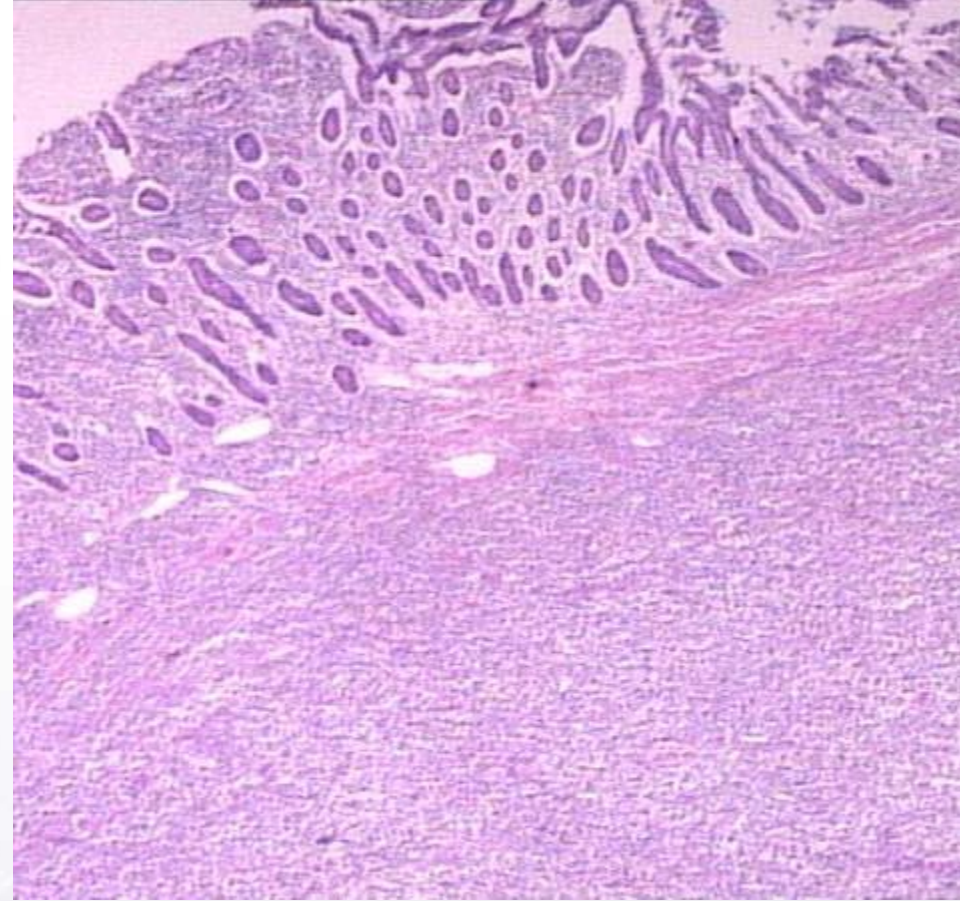
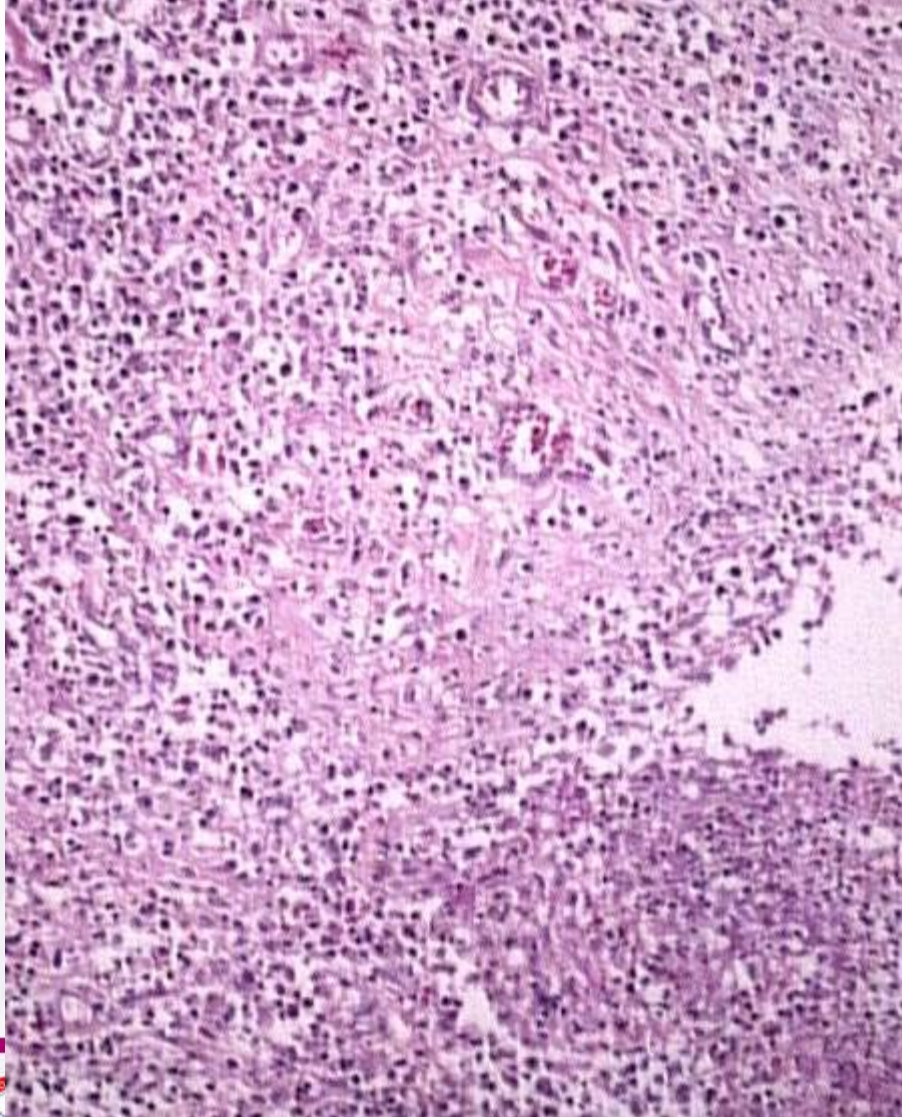
25. Ulusal Patoloji Kongresi

6. Sitopatoloji Kongresi

14 - 17 Ekim 2015 / Merinos AKKM - BURSA



# ENTEROPATİ TİPİ T HÜCRELİ LENFOMA (EATCL)



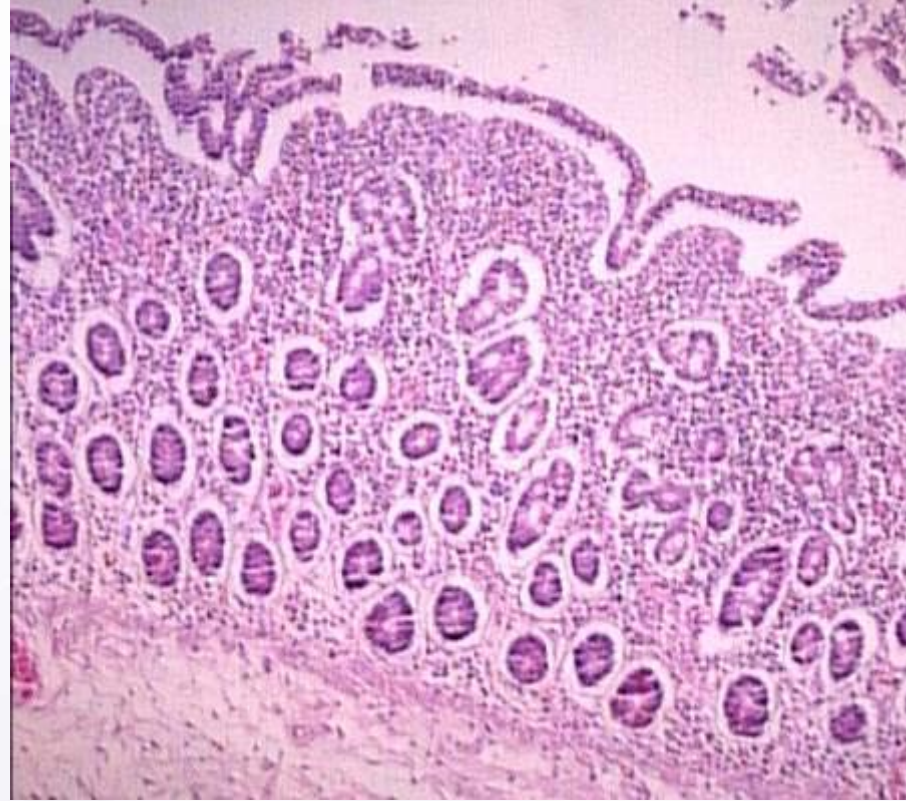25. Bursa Patoloji Kongresi  
6. Sitopatoloji Kongresi

14 - 17 Ekim 2015 / Merinos AKKM - BURSA

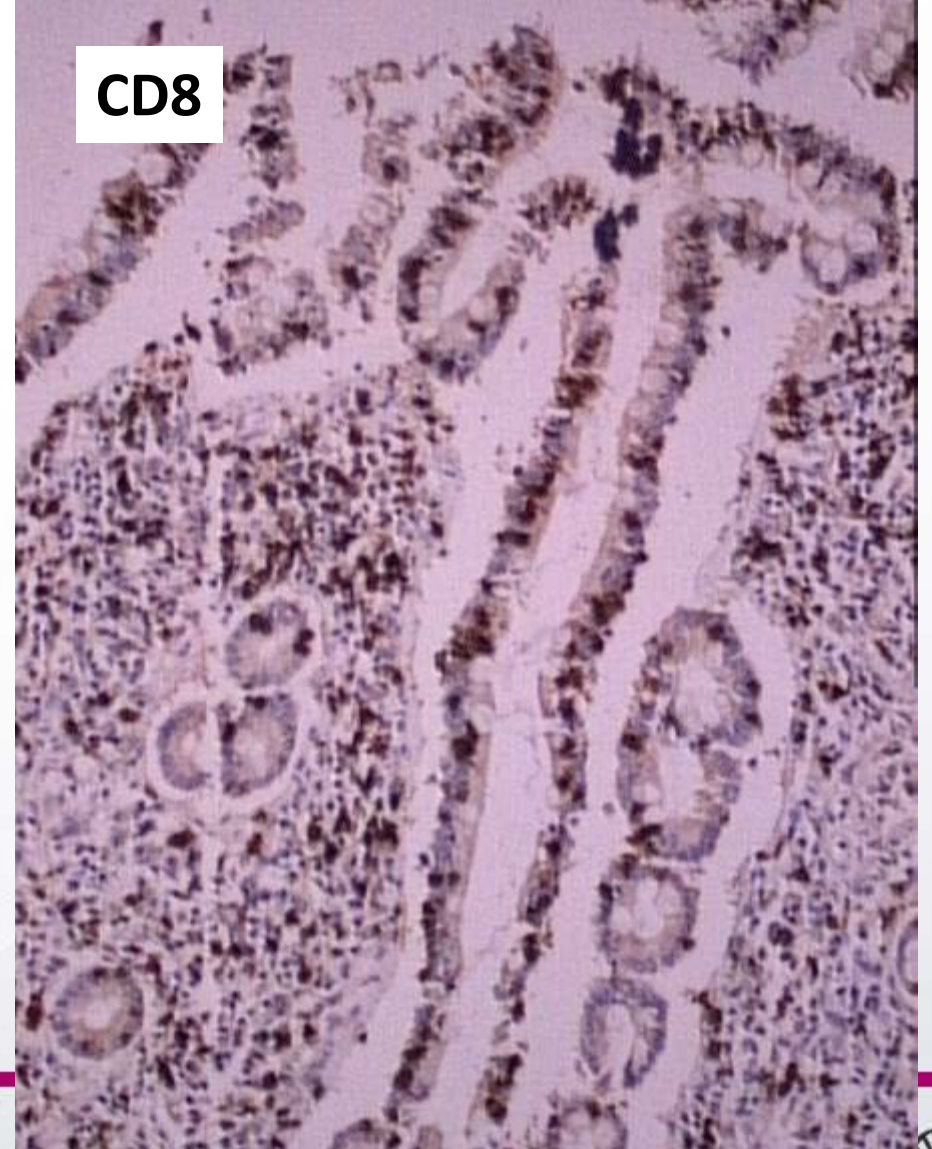




# ENTEROPATİ TİPİ T HÜCRELİ LENFOMA (EATCL)



TÜMÖR DIŞI MUKOZA

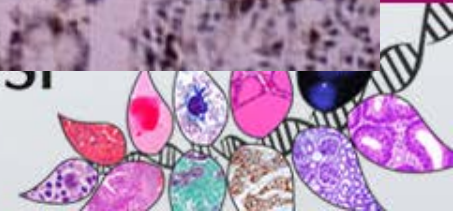


CD8



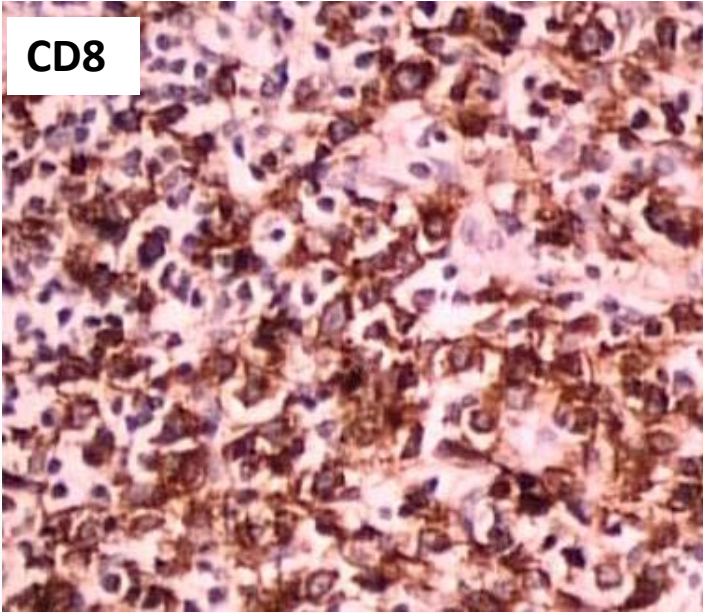
25. Ulusal Patoloji Kongresi  
6. Sitopatoloji Kongresi

14 - 17 Ekim 2015 / Merinos AKKM - BURSA

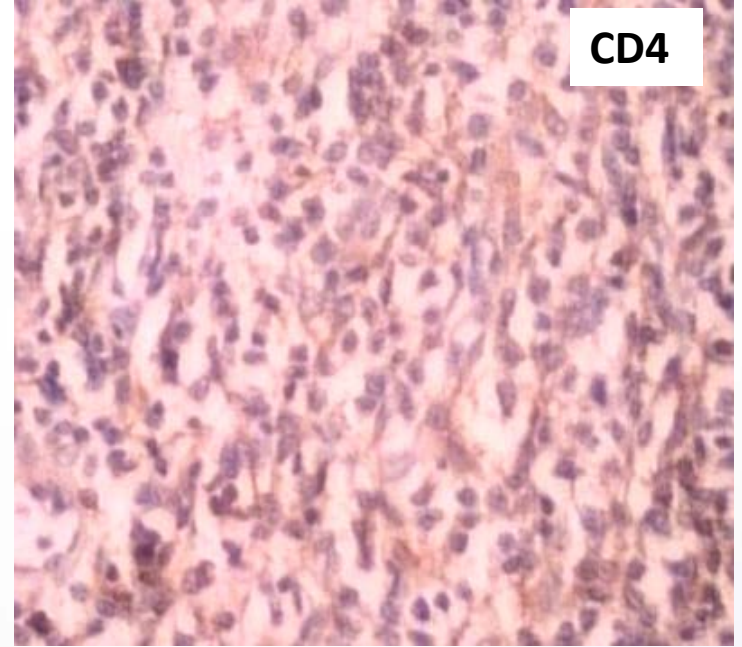


# ENTEROPATİ TİPİ T HÜCRELİ LENFOMA (EATCL)

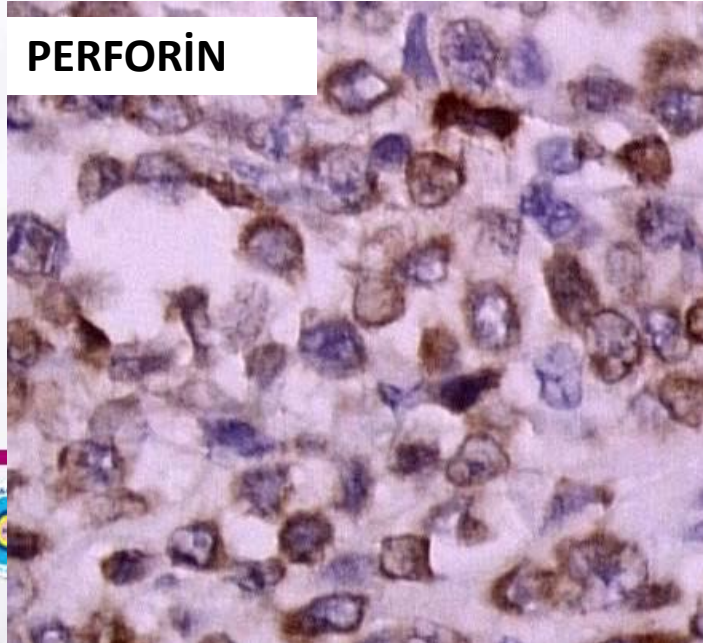
CD8



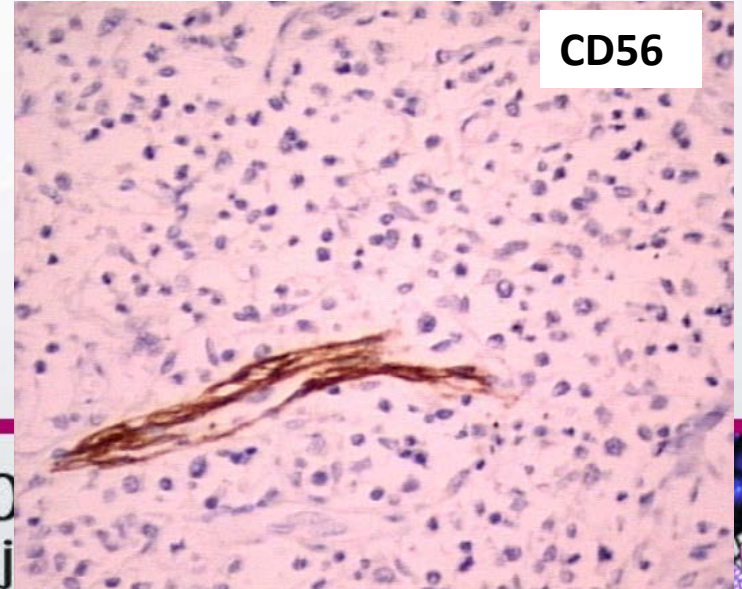CD4



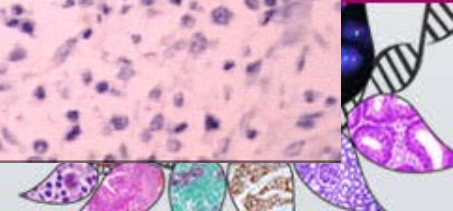
PERFORİN



CD56



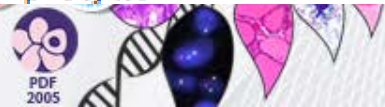al Patolo  
opatoloj



**Table 5.** Key points in comparison between CD, RCD (types I and II) and EATL type I

	CD	RCD-I	RCD-II	EATL type I
Disease type	Autoinflammatory immune response, triggered by gluten	Aberrant autoinflammatory immune response, gluten independent	Intraepithelial ( <i>in situ</i> ) lymphoma, low-grade	High-grade lymphoma
Clinical features	Diarrhoea, abdominal pain, weight loss, anaemia Villous atrophy	CD symptoms unresponsive to gluten-free diet Ulcerative jejunitis (<30%), small ulcerations (<1 cm)	Protein-losing enteropathy Ulcerative jejunitis (>70%), large ulcerations (>1 cm)	Fever, weight loss Tumour mass with obstruction or perforation
Lymphocytes	Increased IEL: sCD3 <sup>+</sup> , cCD3 <sup>+</sup> , CD5 <sup>-</sup> , CD8 <sup>+</sup> , CD103 <sup>+</sup>	Increased IEL: sCD3 <sup>+</sup> , cCD3 <sup>+</sup> , CD5 <sup>-</sup> , CD8 <sup>+</sup> , CD103 <sup>+</sup>	Increased IEL: sCD3 <sup>-</sup> , cCD3 <sup>+</sup> , CD5 <sup>-</sup> , CD8 <sup>-</sup> , CD103 <sup>+</sup> , CD30 <sup>-</sup>	Atypical infiltrating lymphoid cells: CD3 <sup>+</sup> , CD8 <sup>-</sup> , Ki67 <sup>+</sup> , p53 <sup>+</sup> , CD30 <sup>+</sup>
Genetics	Polyclonal <i>TCR</i>	Polyclonal <i>TCR</i>	Monoclonal <i>TCR</i> Partial trisomy of 1q	Monoclonal <i>TCR</i> Additional chromosomal gains and loss (see Table 4 for details)
Clinical course	Indolent	Rather indolent 5-years survival: ~90% (80-96%)	Aggressive 5-year survival: ~50% (44-58%)	Highly aggressive 5-year survival: ~20%
Likelihood of progression to EATL	0.7% in 5 years	14% in 5 years	33-52% in 5 years	

CD, Coeliac disease; RCD, Refractory coeliac disease; EATL, Enteropathy-associated T cell lymphoma; IELs, Intraepithelial lymphocytes.

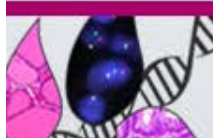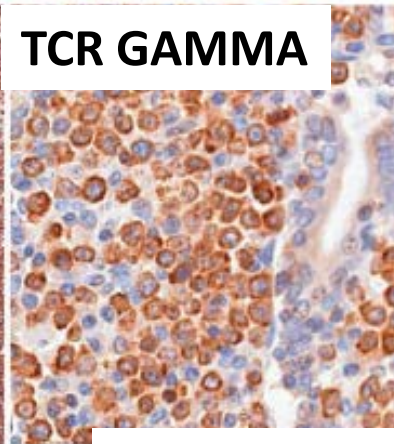
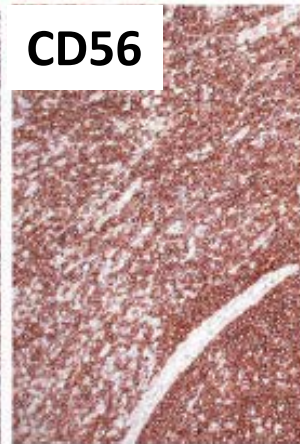
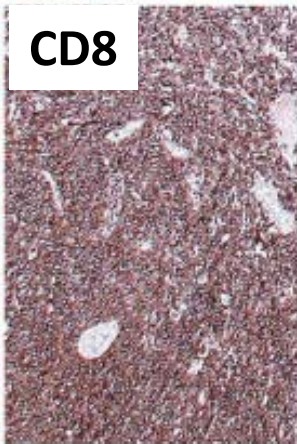
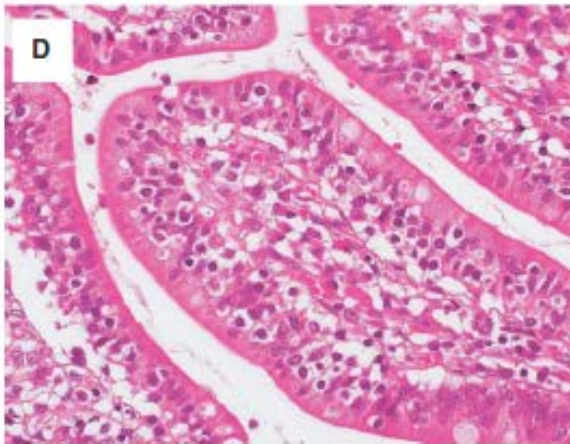
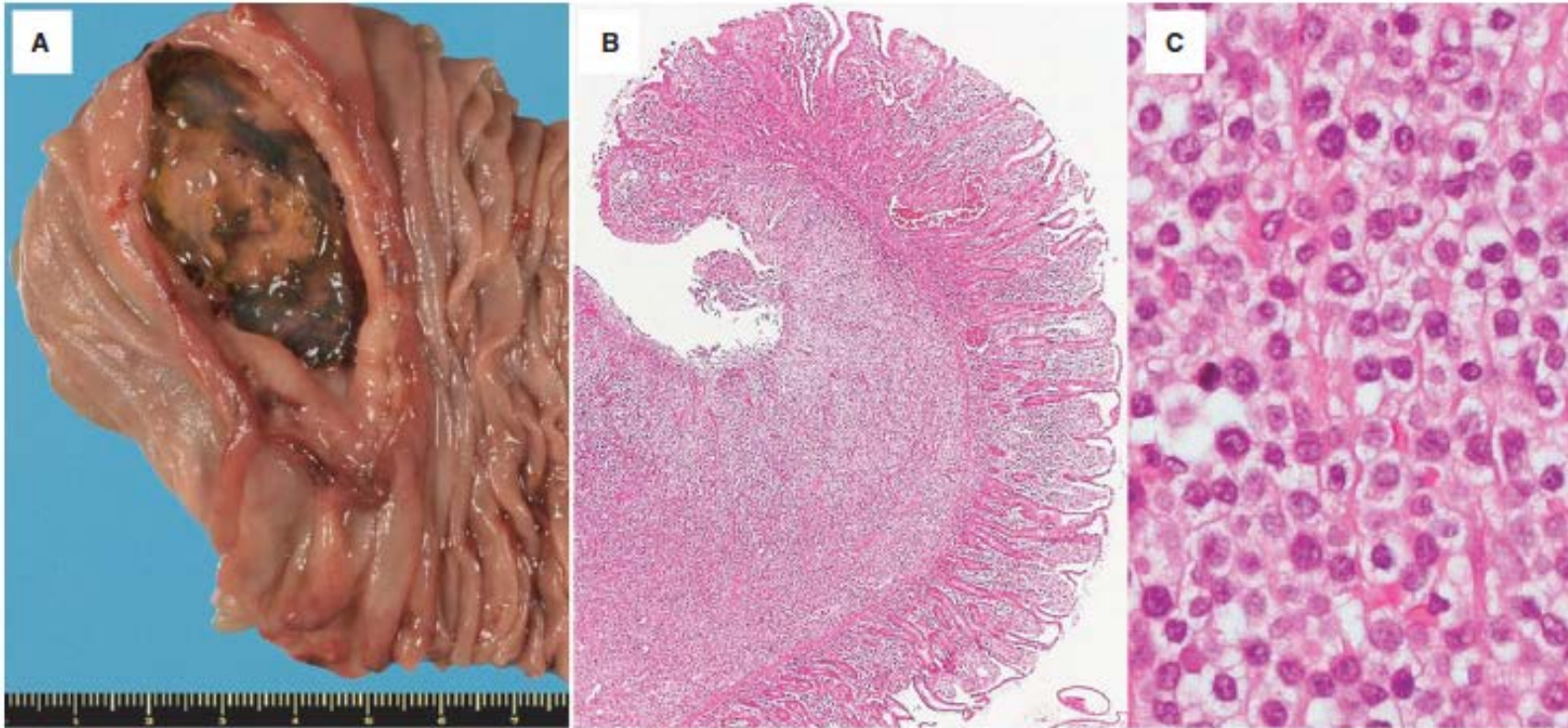


**Table 4.** Overview of enteropathy-associated T-cell lymphoma (EATL), types I and II

	EATL type I	EATL type II
Frequency	80–90%	10–20%
Epidemiology	Most common in northern Europe Strong association with coeliac disease HLA-DQ2/-DQ8: >90%	The most common subtype in Asia Coeliac disease uncommon HLA-DQ2/-DQ8: normal frequency
Tumour cells	Pleomorphic, medium- to large-sized, some cases anaplastic	Monomorphic, small- to medium-sized Epitheliotropic
Reactive inflammatory infiltrate	Often present (eosinophilis and histiocytes)	Uncommon
Necrosis	Common	Uncommon
Distant mucosa	Enteropathy: increased IEL, villous atrophy, crypt hyperplasia	Increased IEL, no villous atrophy
Immunophenotype	CD3 <sup>+</sup> , CD5 <sup>-</sup> , CD8 <sup>-/+</sup> , CD56 <sup>-</sup> , frequently CD30 <sup>+</sup> Cytotoxic/activation markers: TIA1 <sup>+/+</sup> granzyme B <sup>+</sup> , perforin <sup>+/+</sup> MATK <sup>+</sup> <40% of tumour cells	CD3 <sup>+</sup> , CD5 <sup>-</sup> , CD8 <sup>+/+</sup> , CD56 <sup>+/+</sup> , CD30 <sup>-</sup> Cytotoxic/activation markers: TIA1 <sup>+/+</sup> granzyme B <sup>+</sup> , perforin <sup>+/+</sup> MATK <sup>+</sup> >80% tumour cells
TCR expression	Usually αβTCR	γδTCR > αβTCR
<b>Genetics</b>		
1q32.2-q41 gain	Frequent	Rare
5q34-q35.2 gain	Frequent	Rare
8q24 ( <i>MYC</i> ) gain	Rare	Frequent
9q gain	Frequent	Frequent
16q21.1 loss	Frequent	Frequent

IEL, Intraepithelial lymphocytes; MATK, Megakaryocyte-associated tyrosine kinase; TCR, T-cell

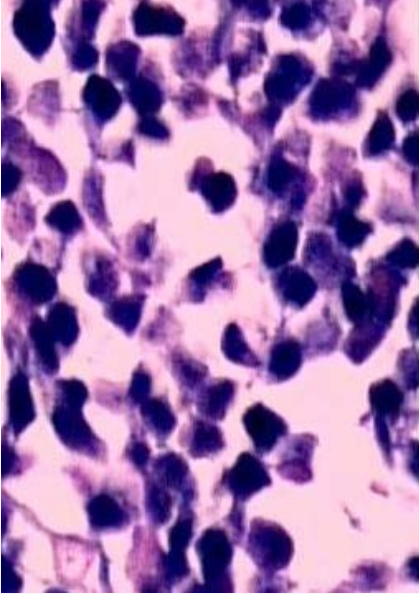
# ENTEROPATİ TİPİ T HÜCRELİ LENFOMA (EATCL) TİP II



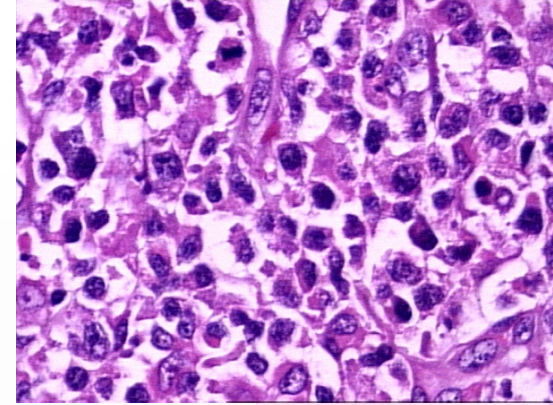
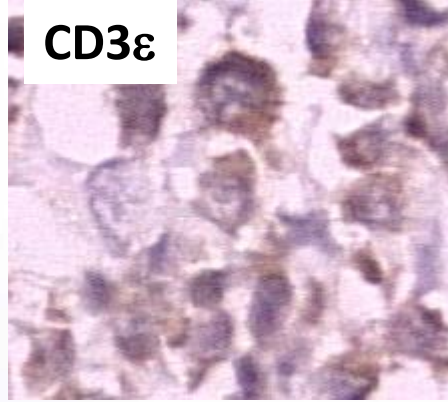
# AYIRICI TANI

## EKSTRANODAL NK/T HÜCRELİ LENFOMA NAZAL TİP

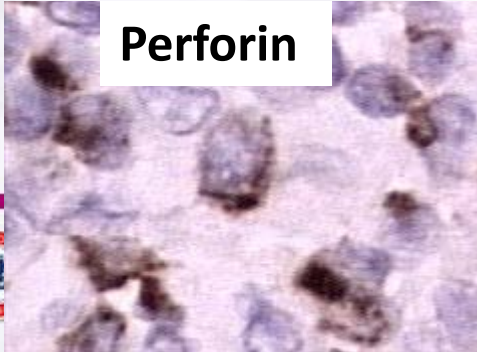
EBER +



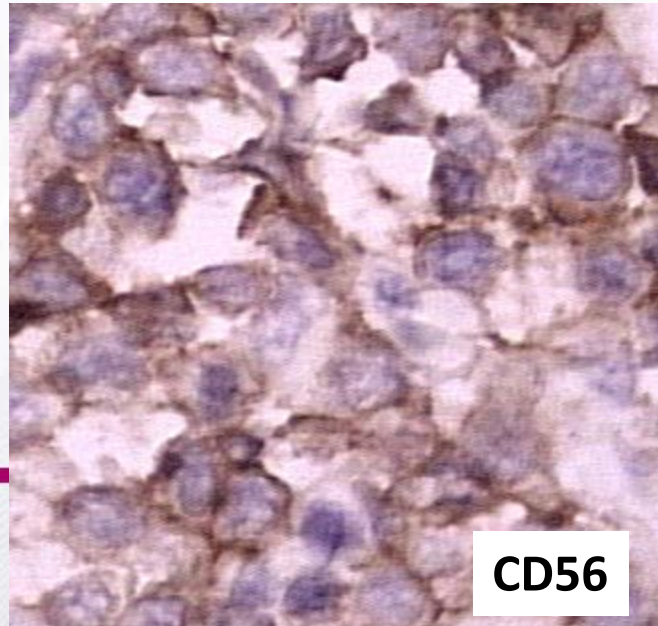
CD3ε



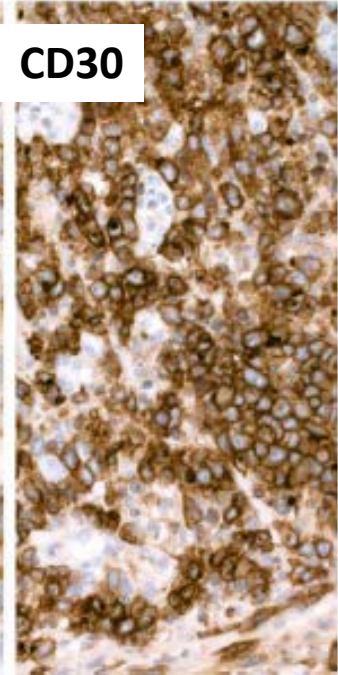
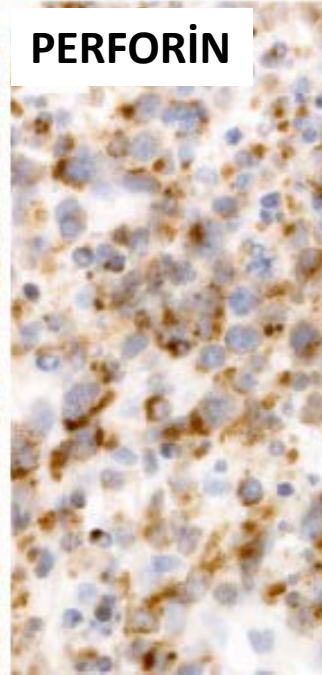
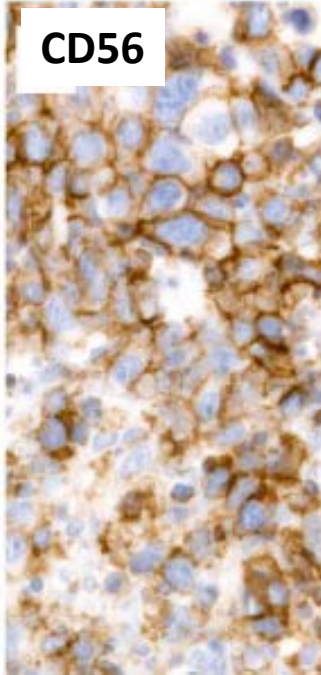
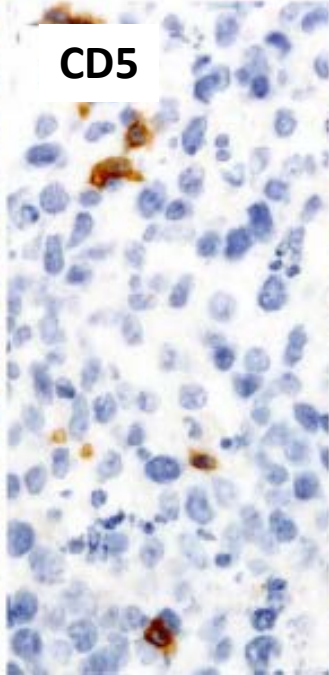
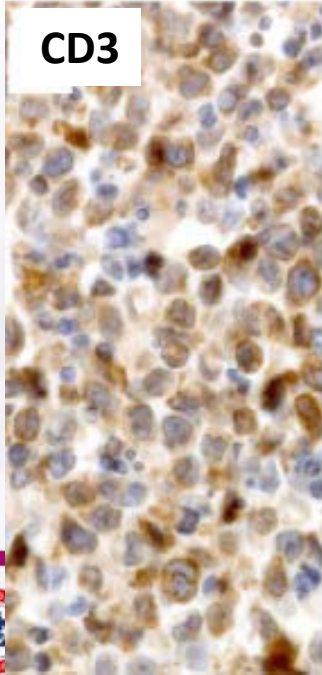
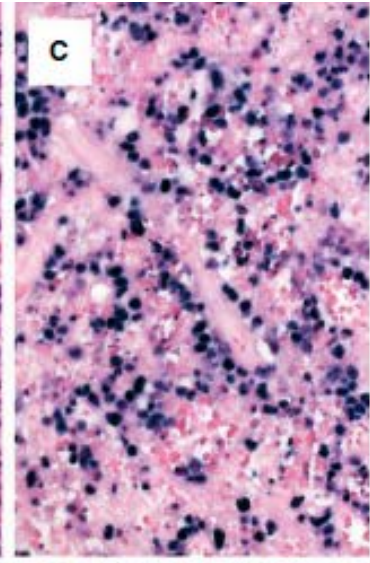
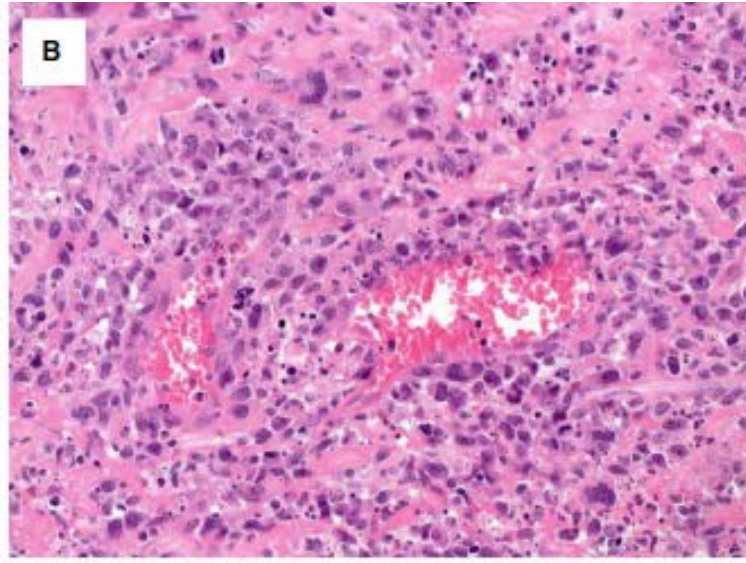
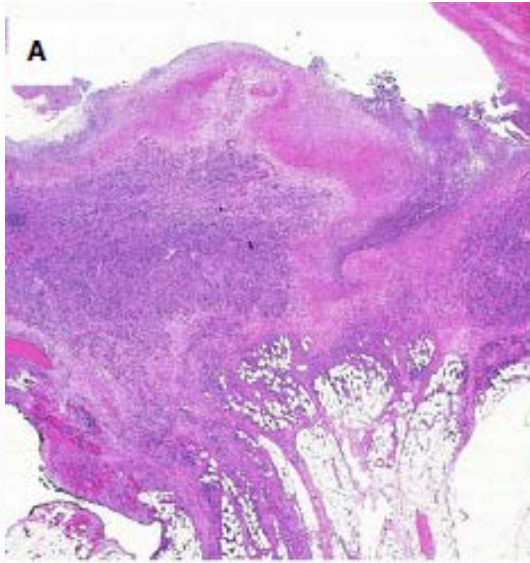
Perforin



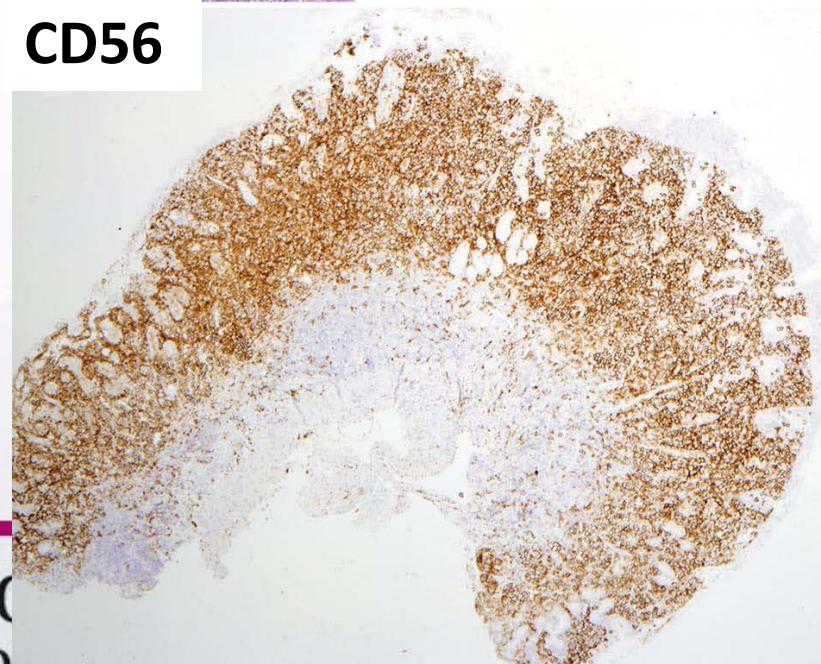
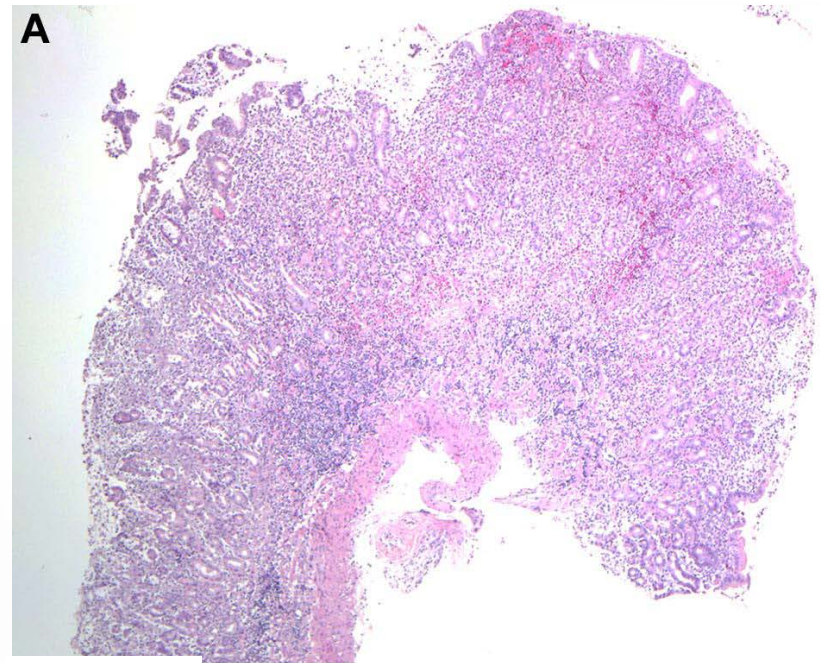
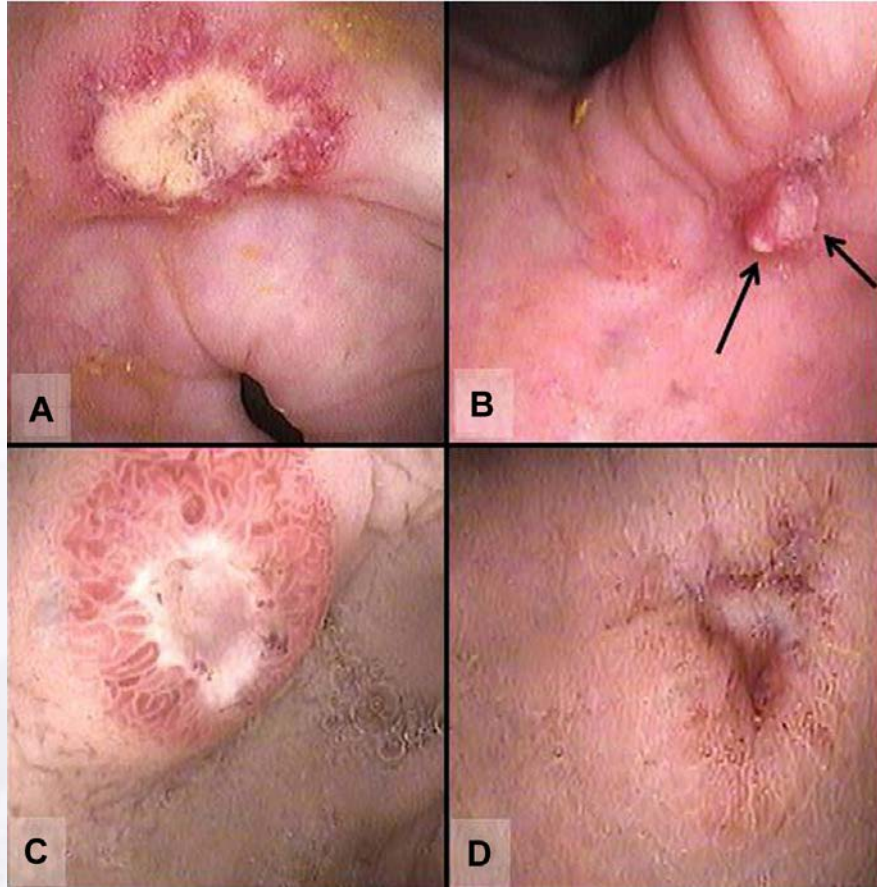
CD56



# EKSTRANODAL NK/T HÜCRELİ LENFOMA NAZAL TİP



# NK HÜCTRELİ ENTEROPATİ



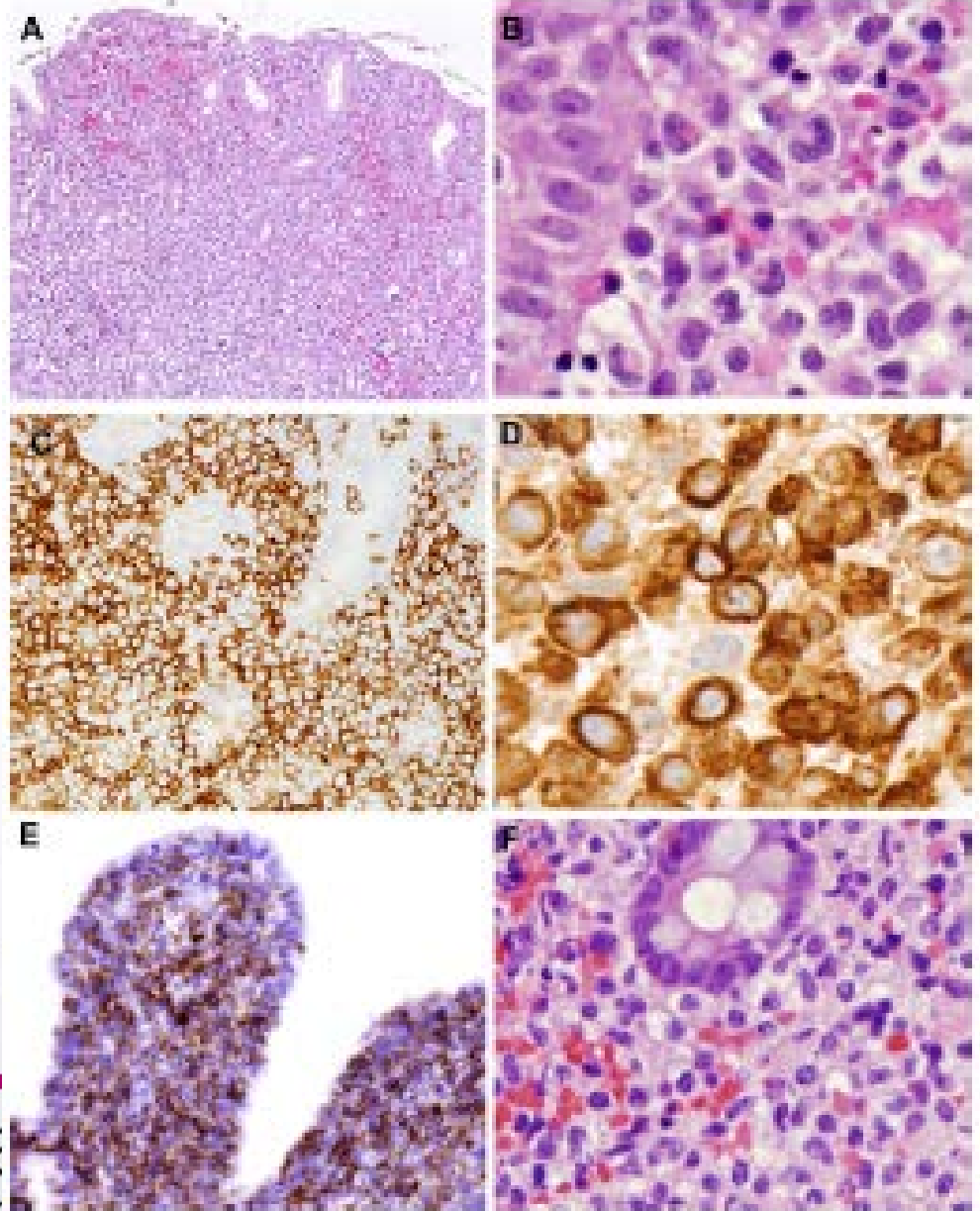
Mansoor 2011 BLOOD





# NK HÜCTRELİ ENTEROPATİ

MULTİPLE BÖLGE TUTULUMU



# NK HÜCTRELİ ENTEROPATİ

Table 2. Immunophenotypic and molecular studies

Patient no.	cCD3	CD56	TIA/GRZB	CD7	CD5	CD4/CD8	CD20	CD43	EBER	TCR
1	+	+	+	+	-	-	-	+	-	Polyclonal
2	+	+	NA	+	-	-	-	+	-	Polyclonal
3	+	+	+	+	-	-	-	+	-	Polyclonal
4	+	+	+	+	-	-	-	+	-	Polyclonal
5	+	+	+	+	-	-	-	NA	-	Polyclonal
6	+	+	+	+	-	-	-	+	-	Polyclonal
7	+	+	+	+	-	-	-	+	-	Oligoclonal
8	+	+	+	NA	-	-	-	+	-	Polyclonal

POLİKLONAL  
CD3

T VE B HÜCRELERİNDEN BAĞIMSIZ HAPTEN  
İLİŞKİLİ NK HÜCRELERİNİN OLUŞTURDUĞU  
DOGAL İMUN YANIT



KONTAKT HİPERSENSİTİVİTE



# 25. Ulusal Patoloji Kongresi

## 6. Sitopatoloji Kongresi

14 - 17 Ekim 2015 / Merinos AKKM - BURSA

