



Olgu sunumu

Dr. Gülfiliz GÖNLÜŞEN
Çukurova Üniversitesi Tıp Fakültesi
Patoloji Anabilim Dalı
ADANA

Olgu-Hikaye

- 69 yaşında ♂ hasta
- Bacaklarında ve testislerinde şişlik şikayeti ile başvuruyor
- 10 yıldır HT ve gut hastalığı öyküsü var
- 2012 yılında gut hastalığı nedeniyle ayak başparmağından opere olmuş.
- Gut nedeni ile ilaç kullanmamış, sadece diyet verilmiş.
- Yine HT için zaman zaman ilaç kullanmış, ancak bu ilaçların adını bilmiyor

Olgu-Fizik Muayene

- Genel durum iyi
- Şuur açık, koopere
- TA: 132/82
- KVS muayenesi: normal
- Solunum sistemi muayenesi: normal
- Batın rahat, defans yok
- Pretibial Ödem: +++
- Skrotal ödem:++

Olgu-Labaratuvar Bulgulari

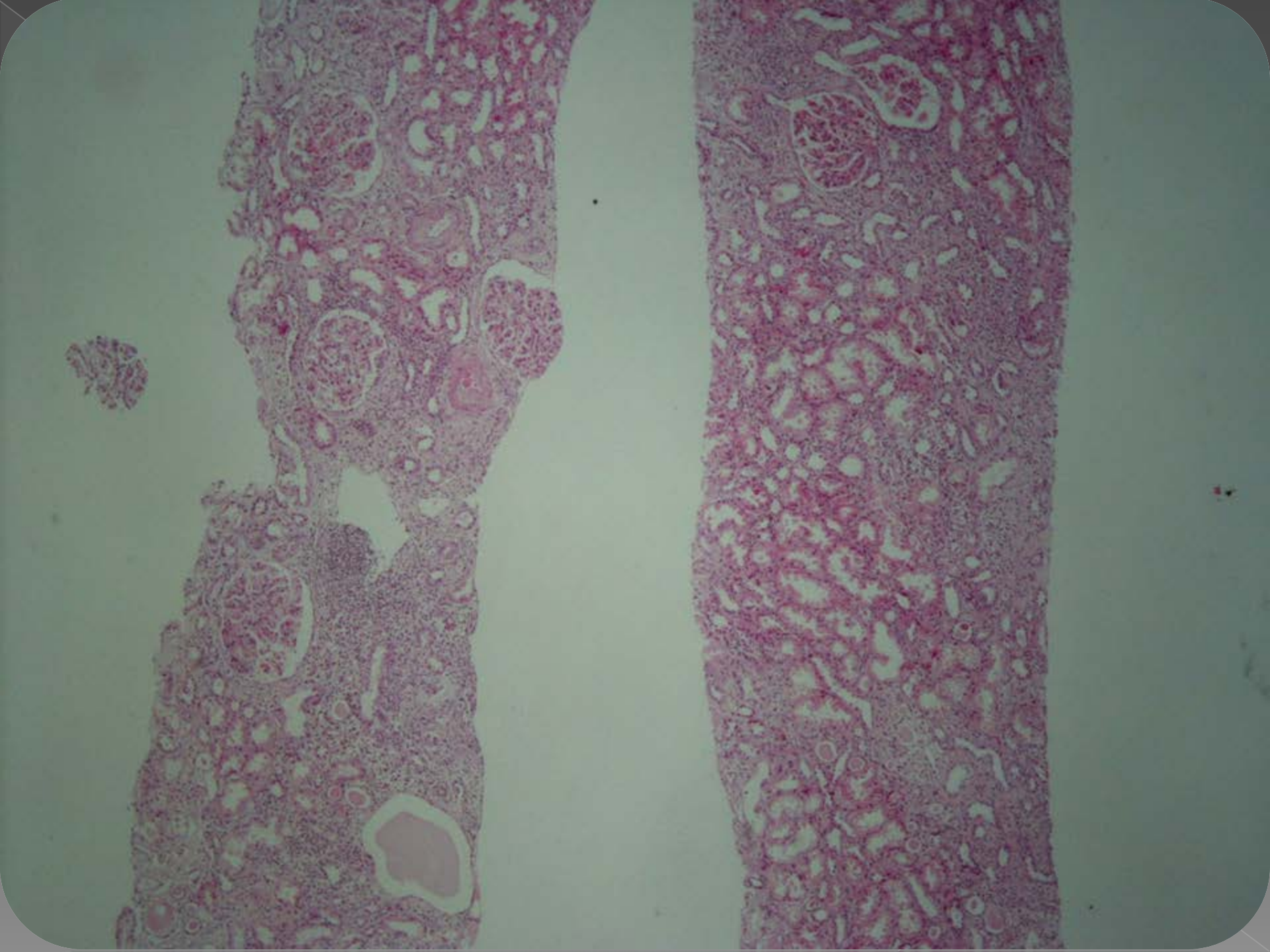
Kan Tahlili	
Glukoz	77
BUN	17
Kreatinin	1.03
AST/ALT	14/12
Na/K	142/4.4
WBC	8800
Total protein	4
Albumin	1.7
ESR	35
Ürik asit	6.6
LDH	153
Total kollesterol	338
LDL	277
Trigliserid	98

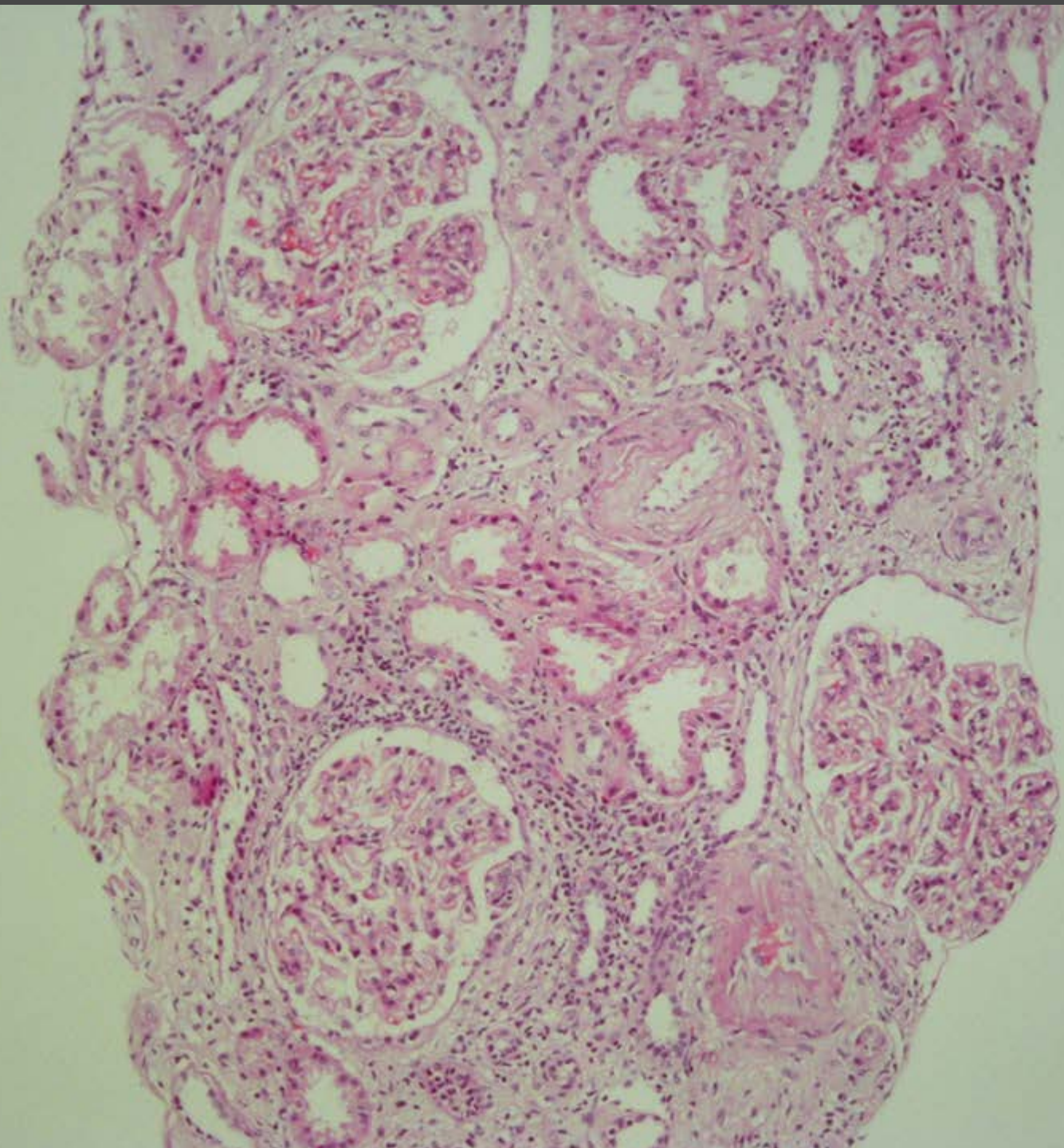
Olgu-Labaratuvar Bulgulari

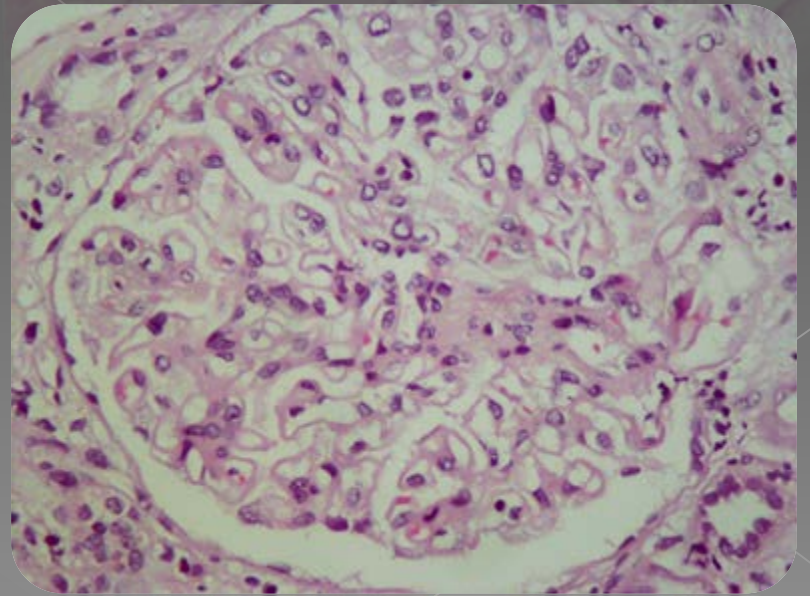
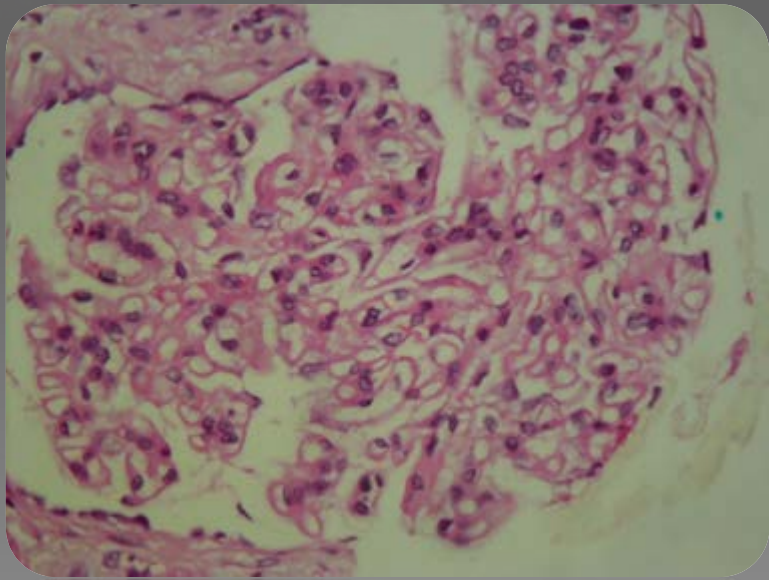
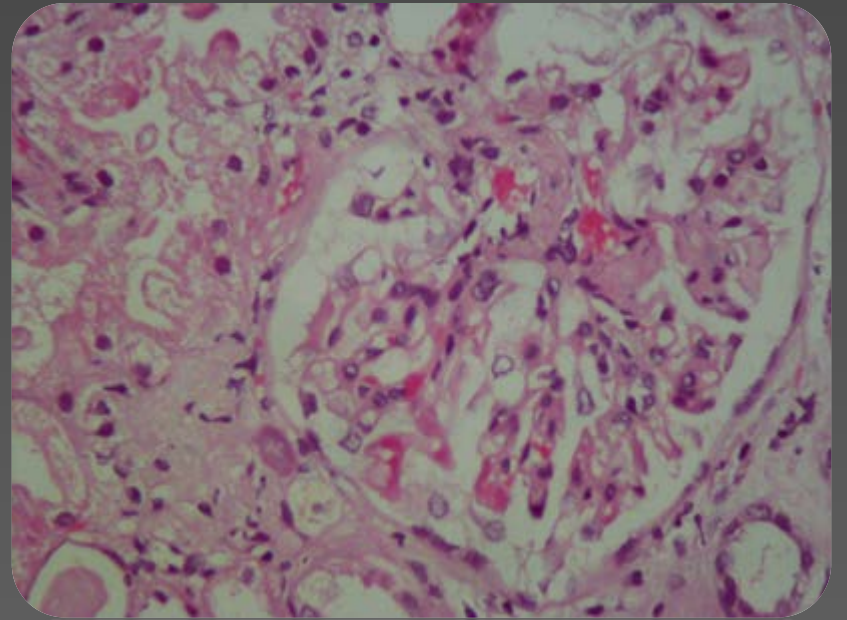
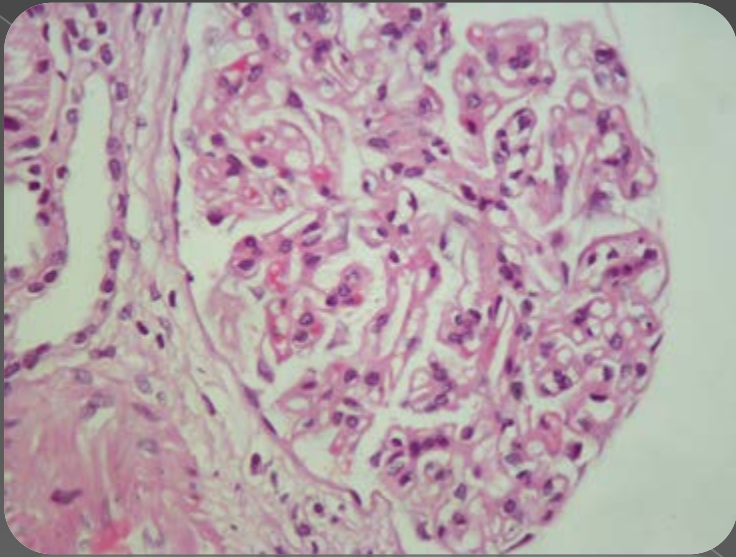
Tam İdrar Tetkiki	
PH	5
Dansite	1009
Protein	+++
RBC	3
WBC	1
Nitrit	-
Esbach	12gr/gün

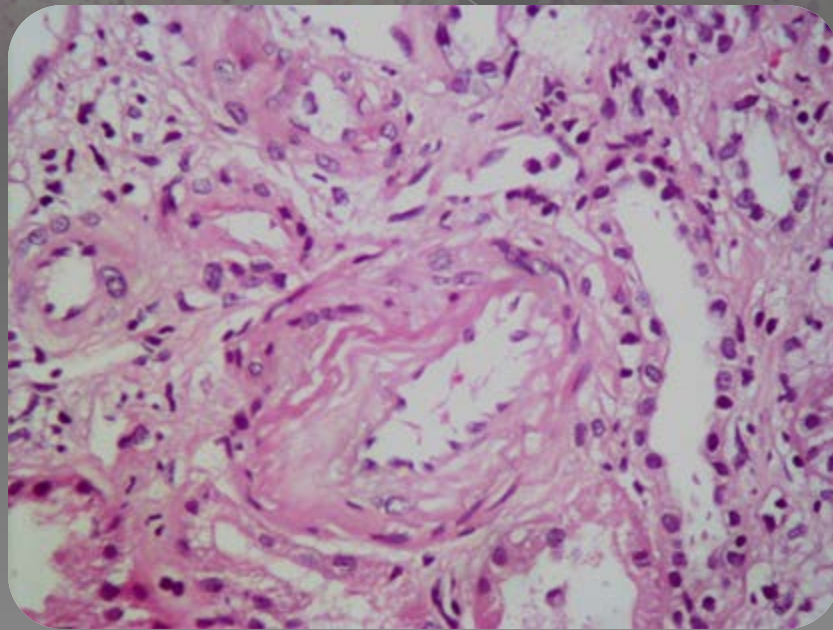
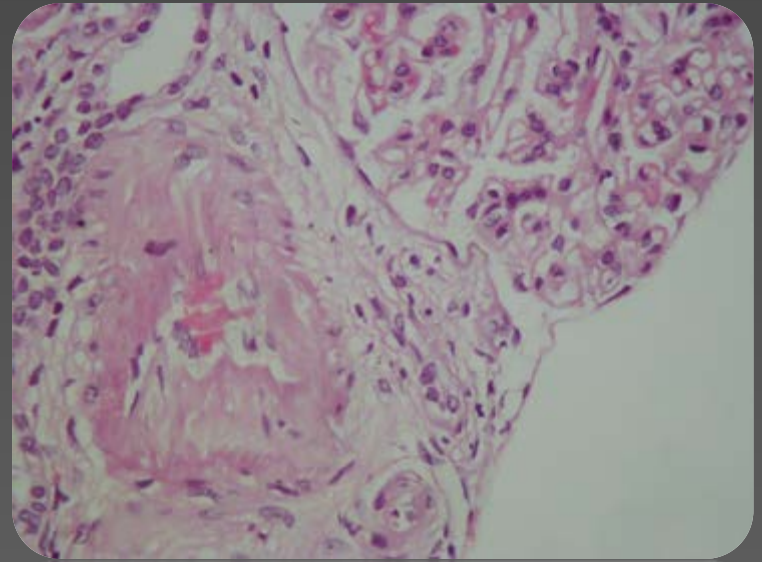
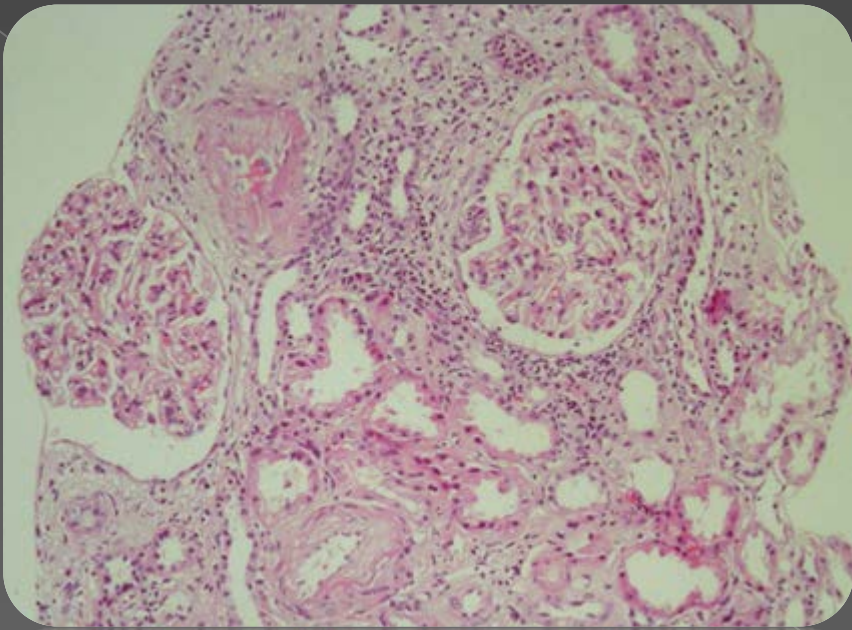
Olgu

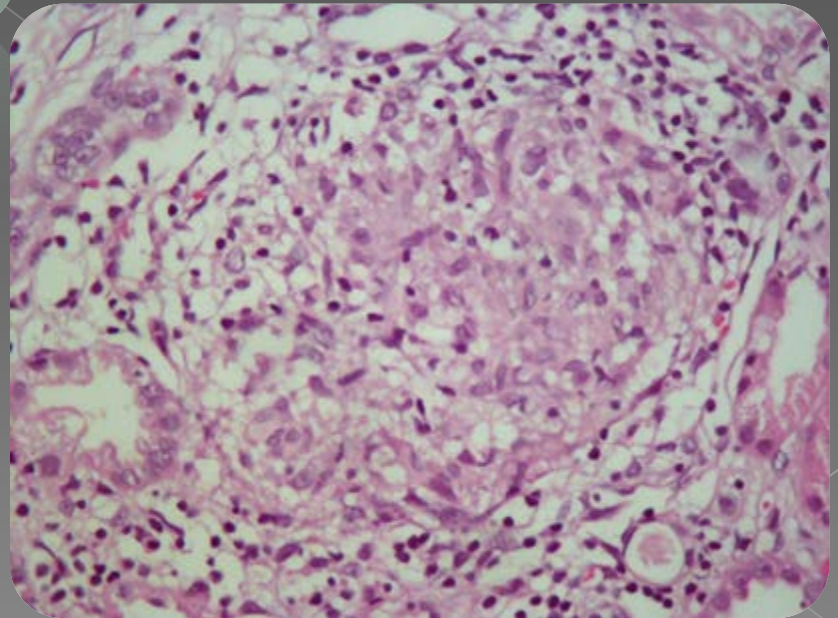
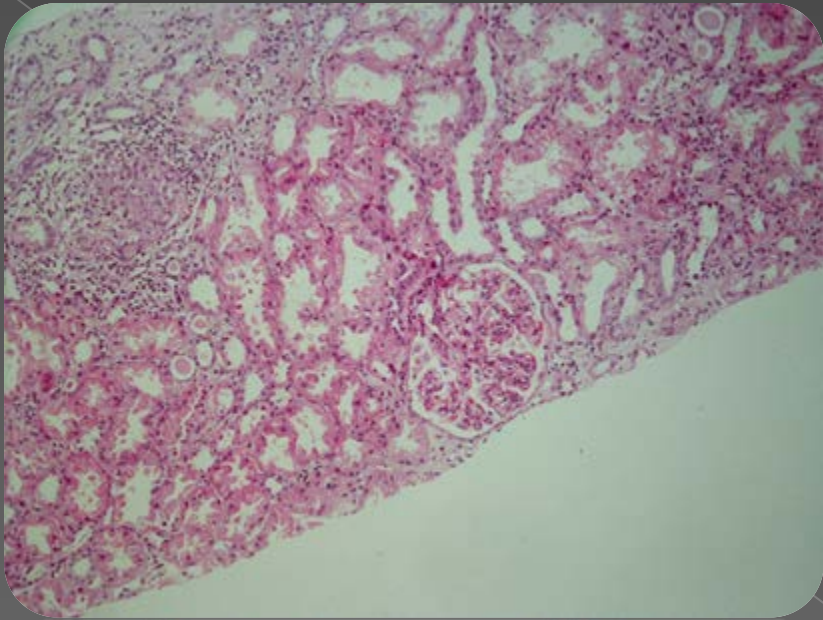
- Olguya böbrek iğne biyopsisi yapıldı...

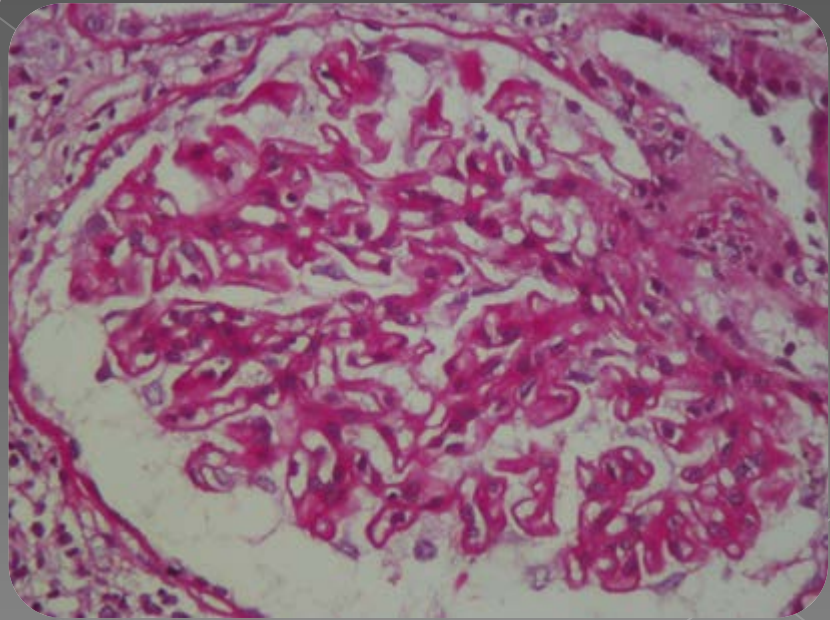
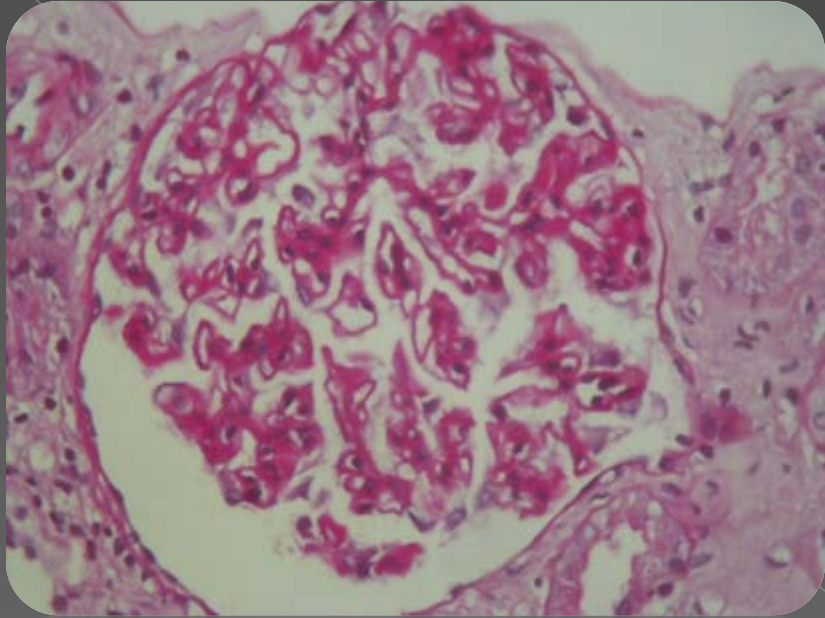




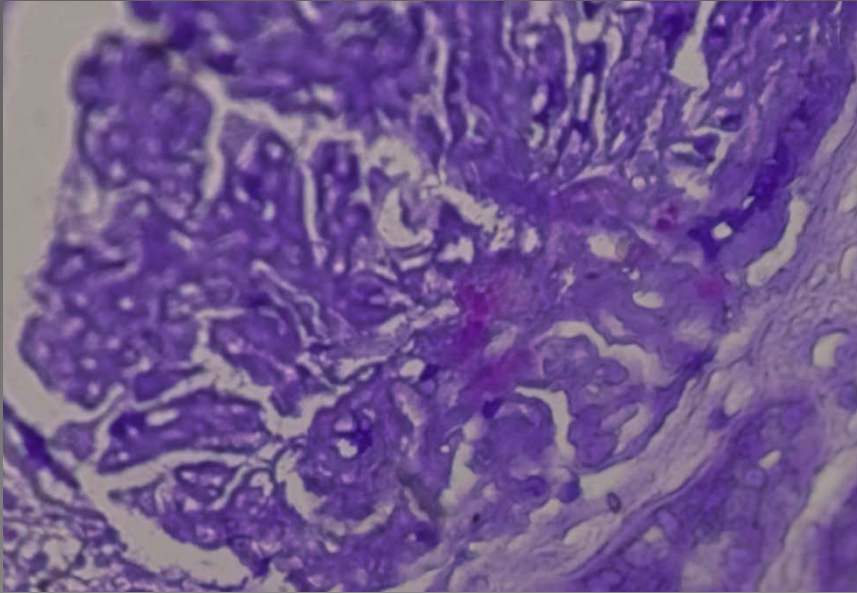
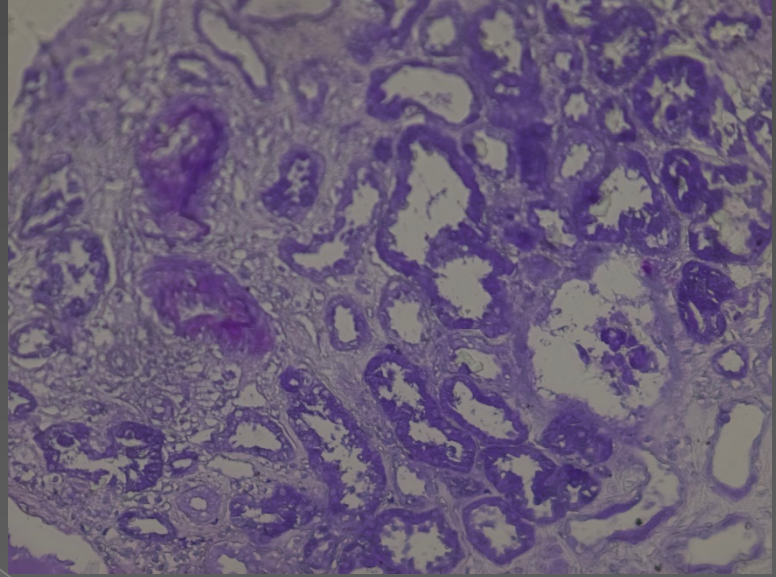
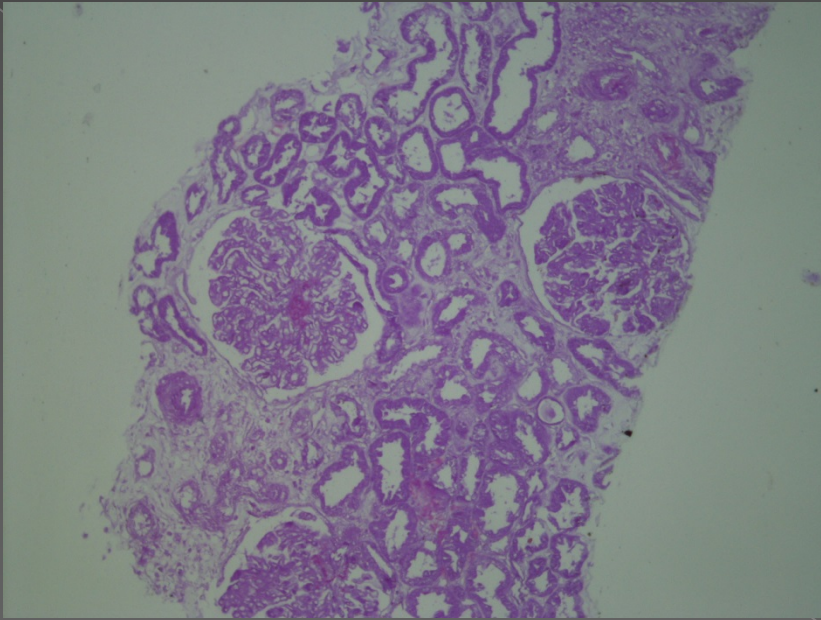


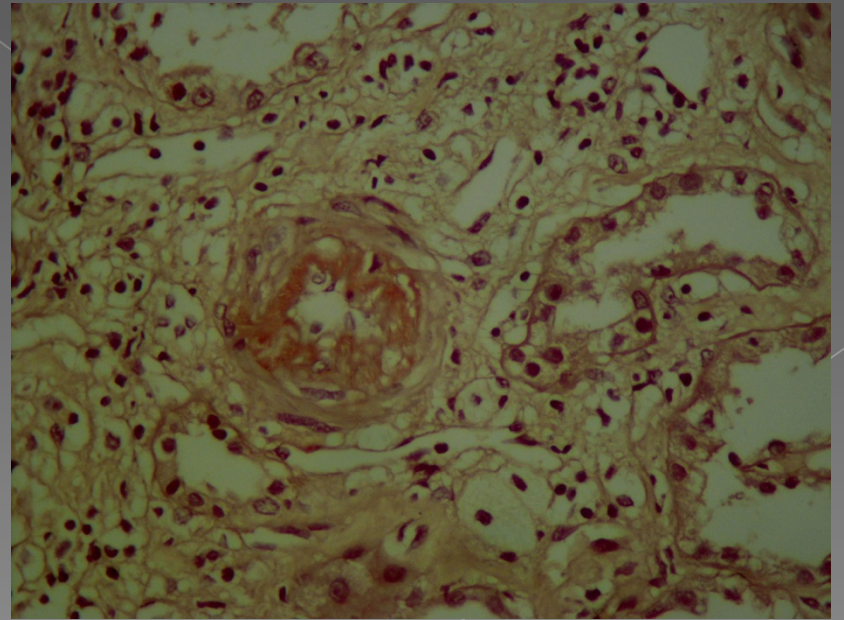
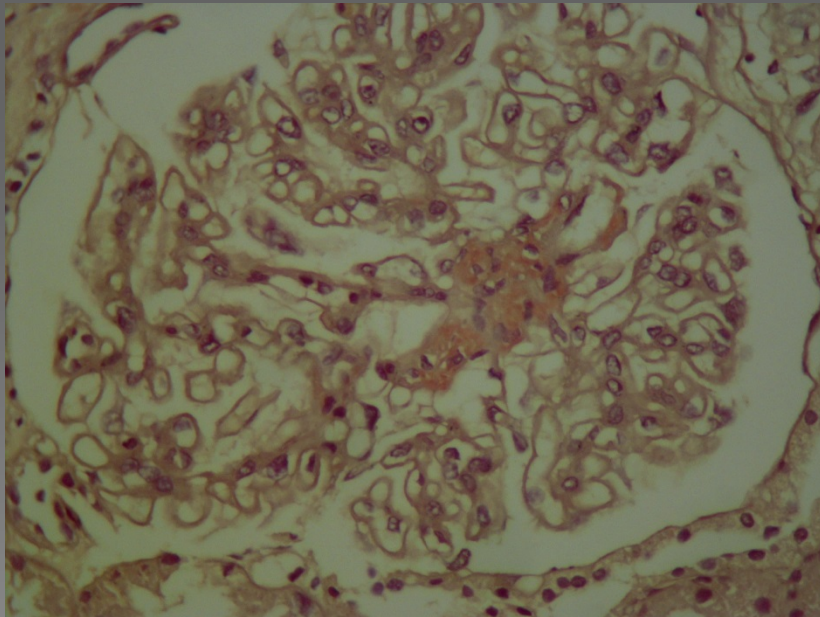
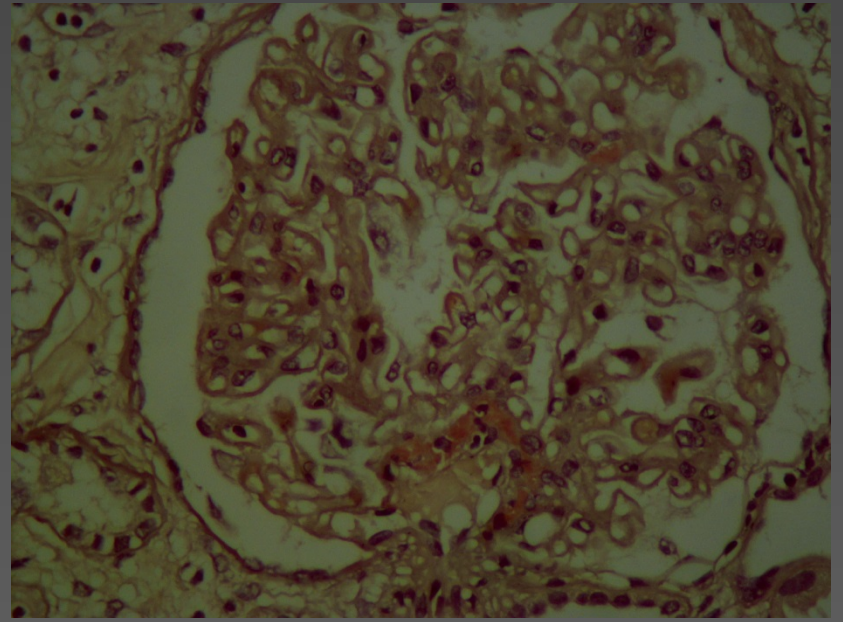
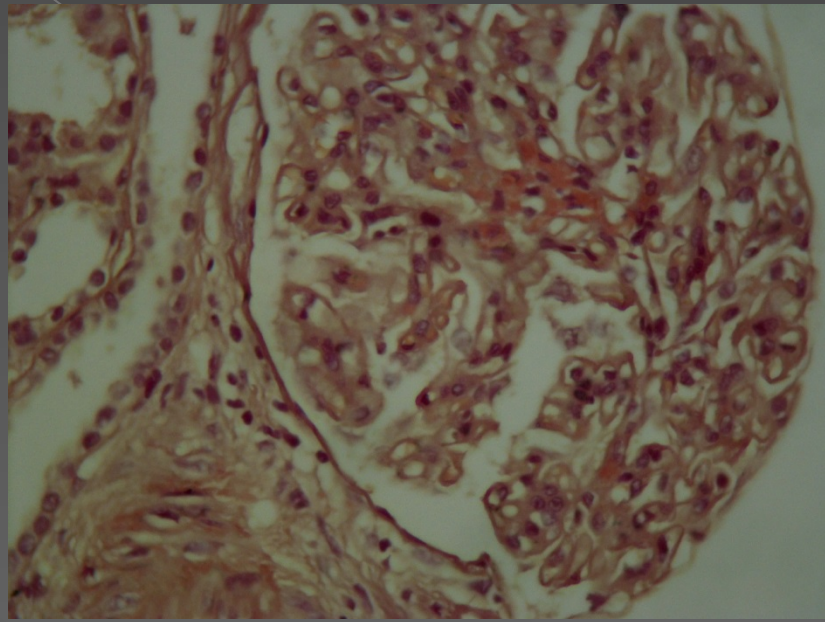


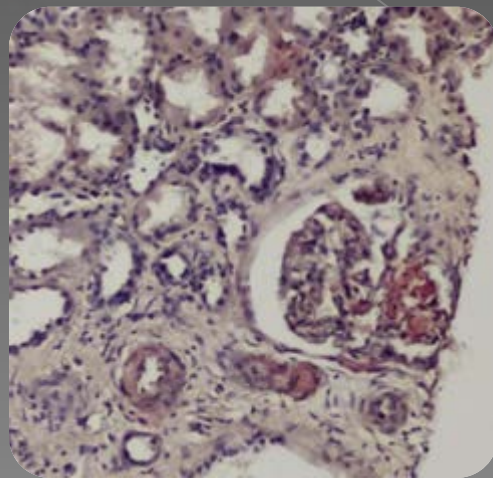
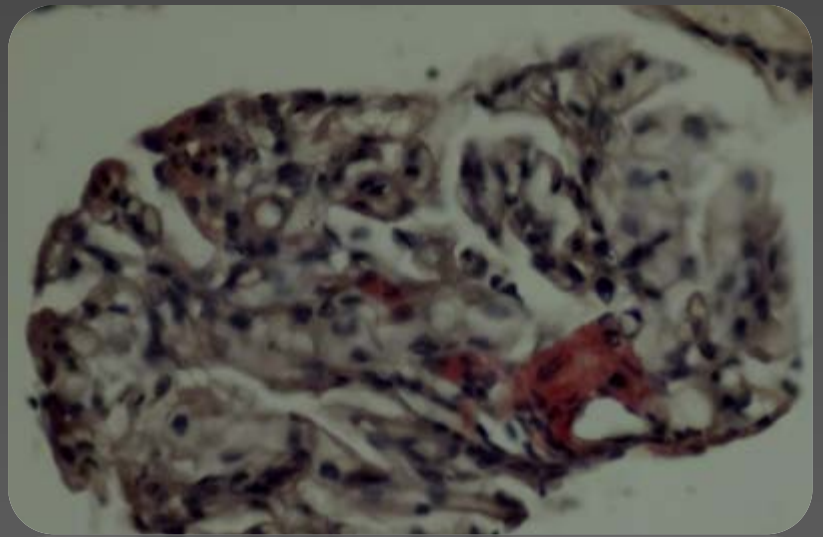
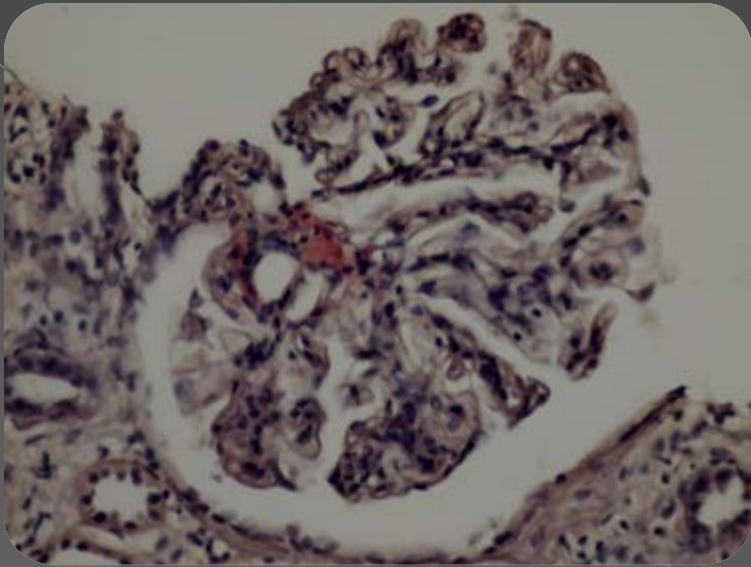


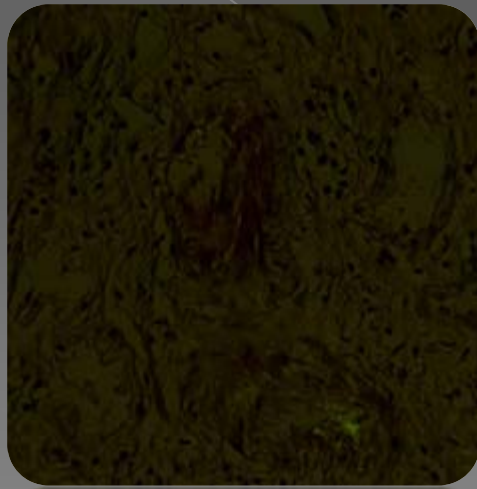

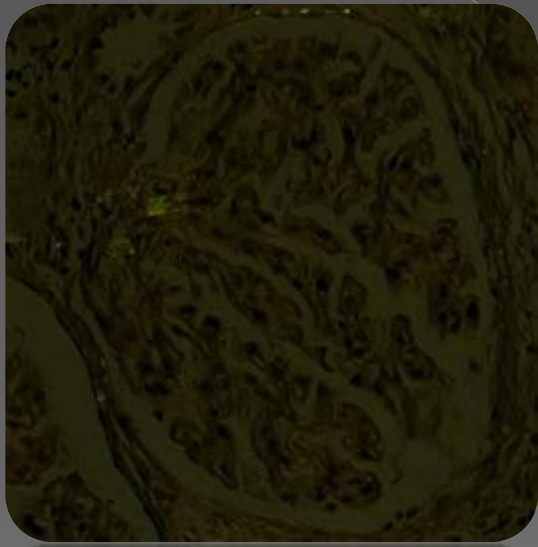


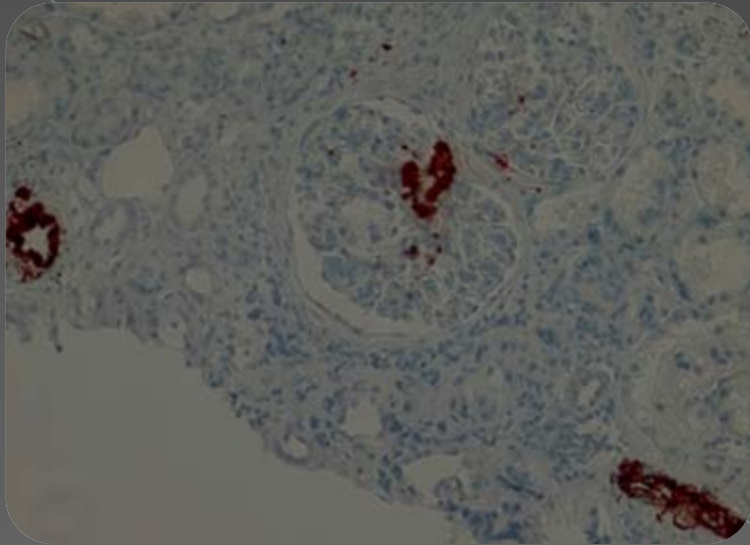




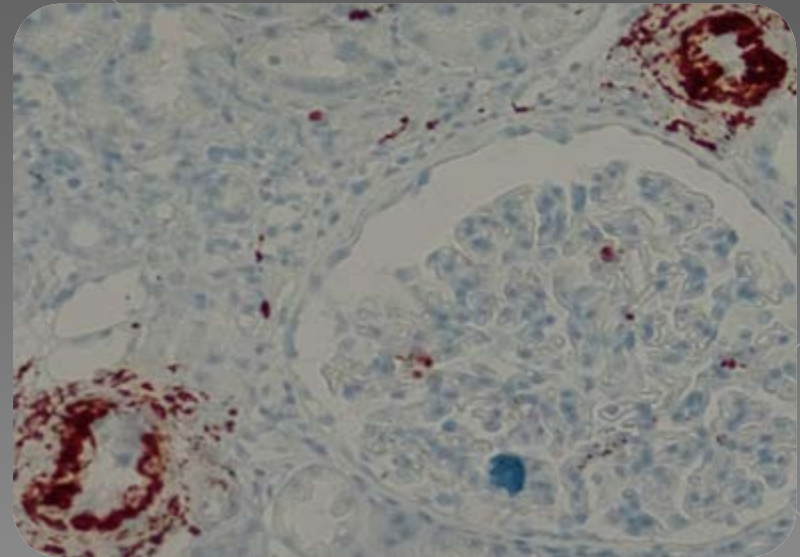


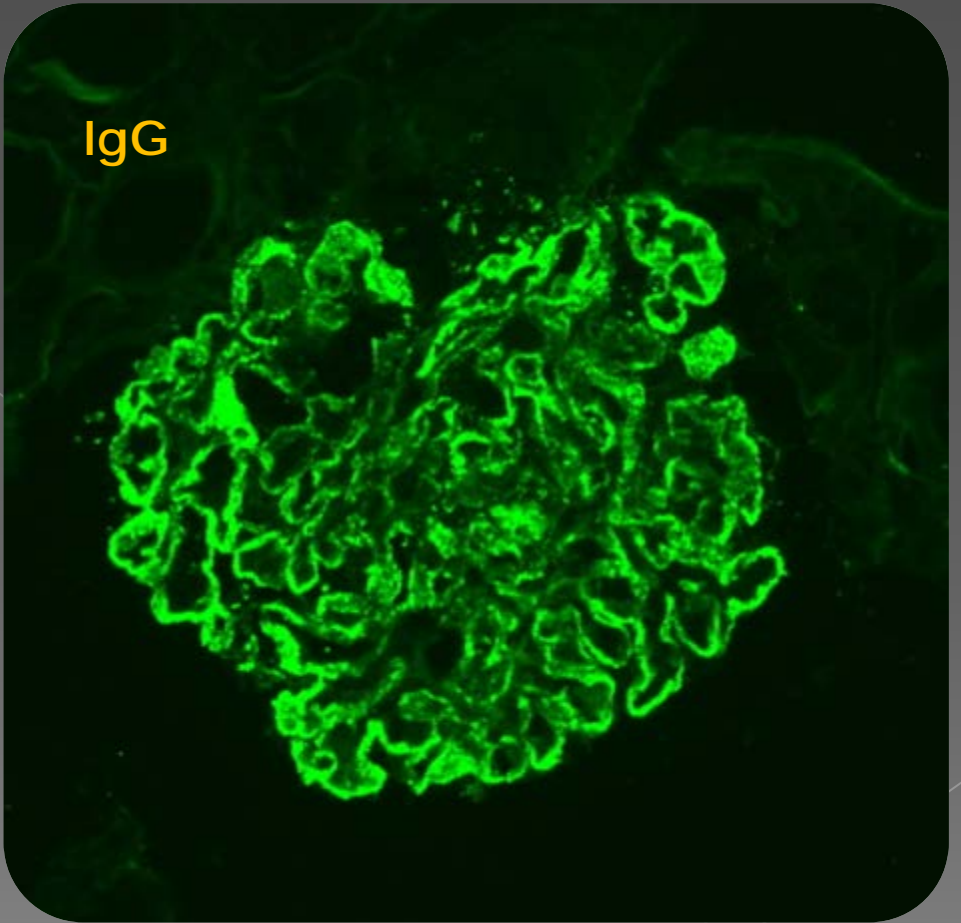
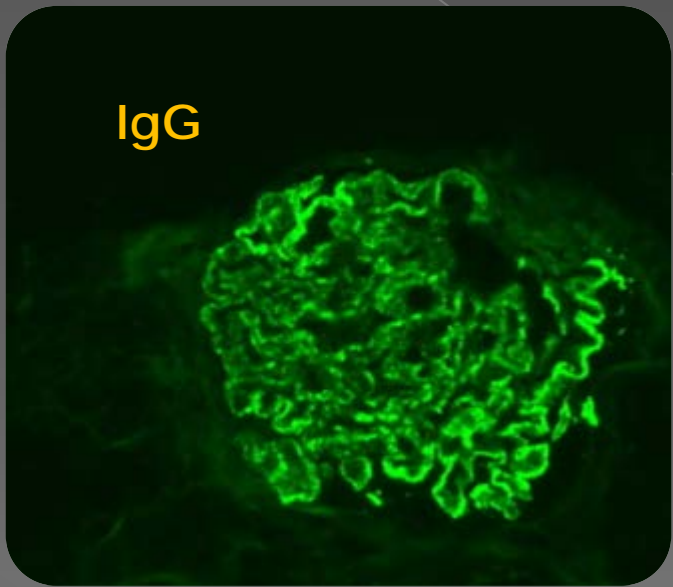


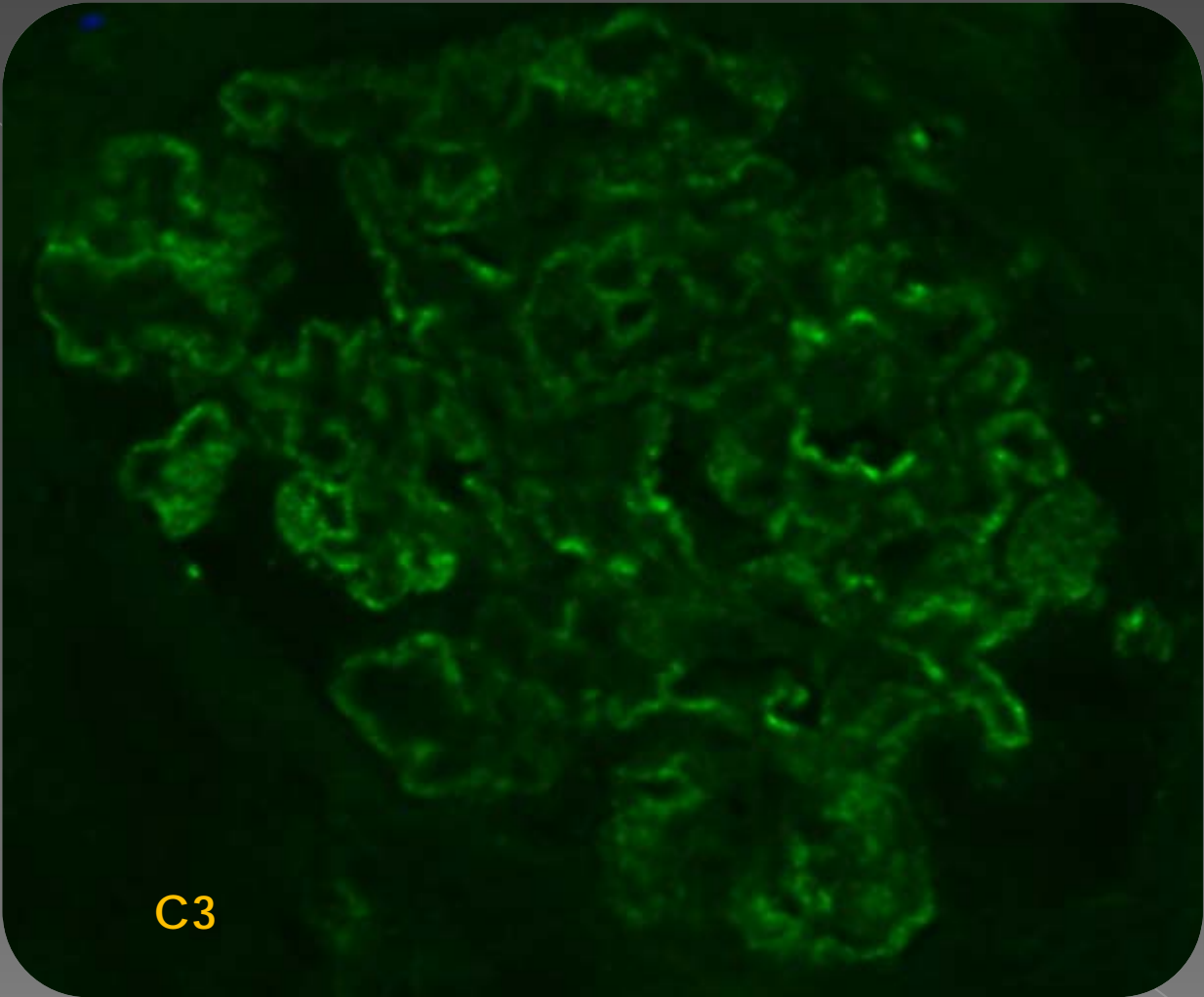




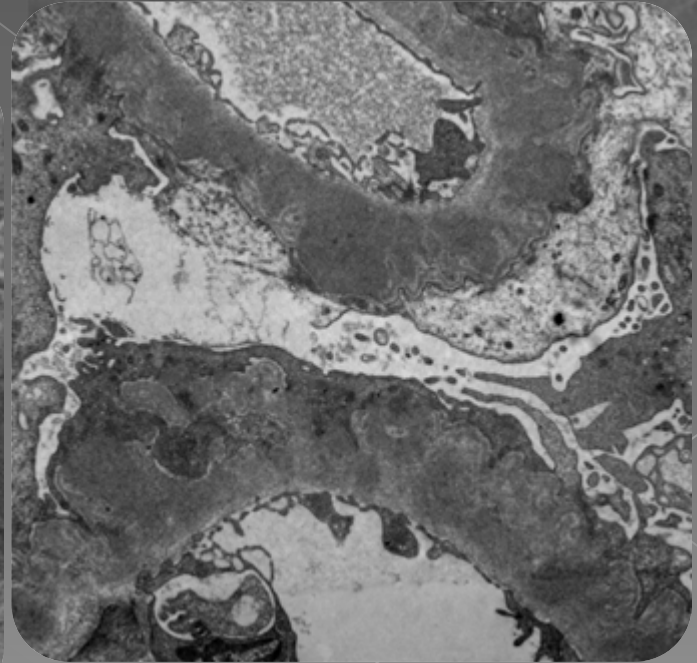
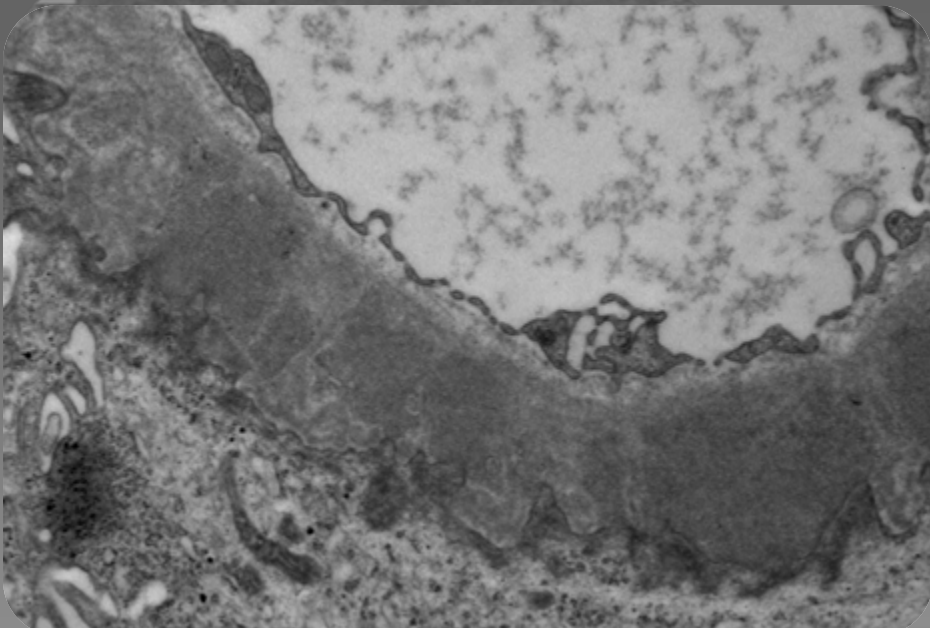
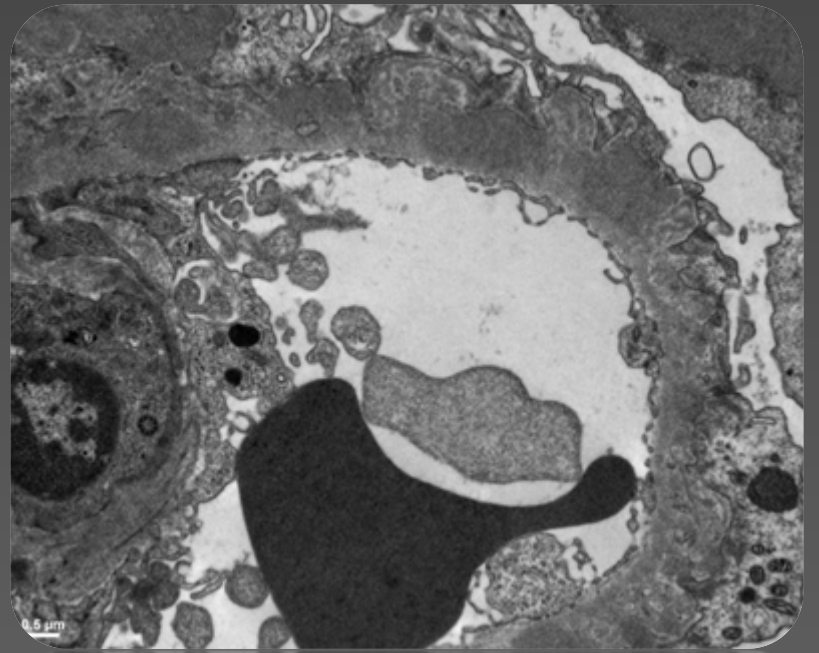
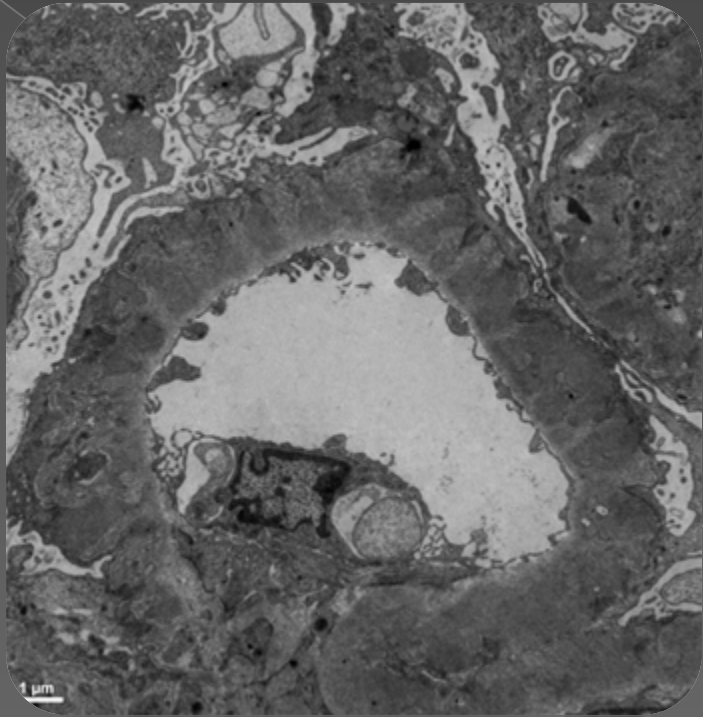
AA amiloid







C3



TANI

Membranöz Glomerülonefrit
+
AA (Sekonder) Amiloidozis
+
Granülomatöz İnflamasyon

Olgu

- ◉ Gut hastalığı +
- ◉ Hipertansiyon +

- ◉ Tbc, sarkoidoz yok
- ◉ Hepatit, kanser öyküsü yok
- ◉ Sistemik başka bir hastalığı yok

Gut hastalığına bağlı gelişmiş Sekonder Amiloidozis

- «Amyloidosis secondary to gout. Identification with a monoclonal antibody to amyloid protein A.»
 - > Polyartiküler gut hastası
 - > Böbrekte AA amiloidosis saptanıyor

- Jacobelli S1, Vial S, Rosenberg H, Benson MD, Scheinberg MA.
- Clin Rheumatol. 1988 Dec;7(4):534-7.

Gut hastalığına bağlı gelişmiş Sekonder Amiloidozis

- ◉ «Gout and Secondary Amyloid»
 - > Gut hastalığı ve sekonder amiloidozis birlikteliği tanımlanmış

- ◉ M. Guma et al. Clin Rheumatol (1999) 18:54-55

Gut hastalığına bağlı gelişmiş Sekonder Amiloidozis

- «An unusual cause of renal amyloidosis secondary to gout: the first description of familial occurrence.»
 - > Polyartiküler tutulumlu, hiperürisemi ve tofus oluşumlu 2 kardeşte (44 ve 47 yaşında) 7 ve 10 yıl içinde proteinüri ve kronik böbrek yetmezliği saptanıyor.
 - > Alınan böbrek biyopsilerinde sekonder AA amiloidozis saptanıyor

- Vernerová Z1 et al.
- Nucleotides Nucleic Acids. 2006;25(9-11):1305-8.

Gut Hastalığına bağlı gelişmiş Membranöz GN

- ◉ «Gouty kidney associated with membranous nephropathy: participation of renal tubular epithelial antigen.»
 - > Gut hastalığı ve proeteinüri saptanan 3 olgunun böbrek biyopsileri incelenmiştir;
 - > Sonuç olarak MNP gutlu hastalarda gelişebiliyor ve RTE patogeneziyle ilişkili olabiliyor
 - > Yokoyama H et al. 1986:44(4):361-4

Membranöz GN ile Amiloidozis birlikteliği

- «Membranous nephropathy associated with kidney amyloidosis.»
- 13 hastadan alınan 15 böbrek biyopsisinde MNP ve amiloidozis var
- Varshavski VA et al. Arkh Pathol, 1991;53(7):19-23

Membranöz GN ile Amiloidozis Birlikteliği

- «Secondary systemic amyloidosis A combined with primary GN and systemic diseases)
 - > 155 Primer GN olgusu
 - 11'i (%7) amiloidozis saptanıyor
 - Membranöz GN
 - FSGS
 - > Bogov B et al. 1999; 31(1):1922

K S m r e a v z

