

Foliküler paternli neoplazmlarla karışabilecek durumlar

Prof. Dr. Cenk Sökmensüer

Hacettepe Üniversitesi

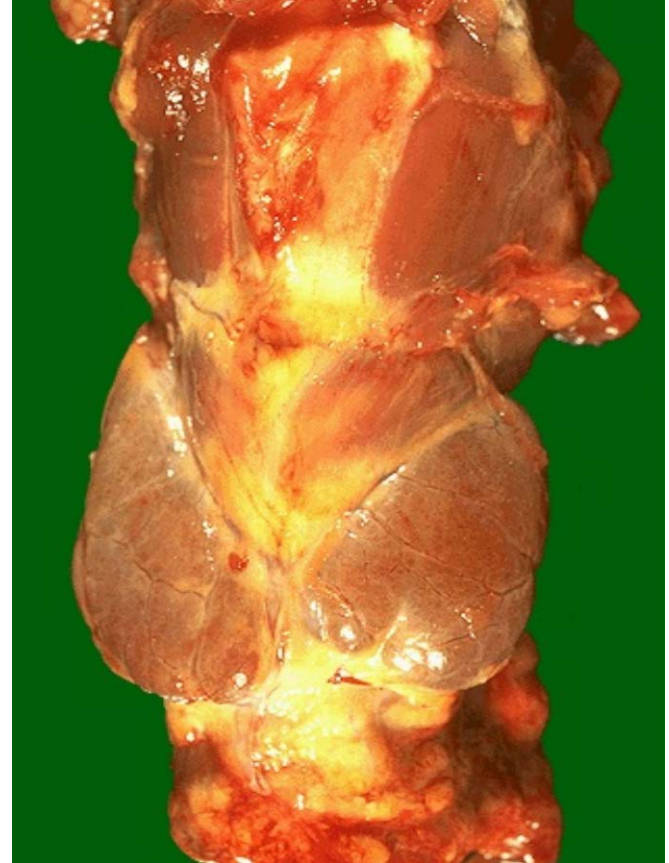
Tıp Fakültesi

Patoloji AD

Ulusal Patoloji ve Sitopatoloji 2015 Bursa

Tiroid Anatomisi

- En hacimli ve yüzeyel **yerleşimli organ**
- 15-20 gm, iki yan lob ve istmus (%40 piramidal lob)



Embriyoloji

- **14.haftada**
Ağız boşluğu → farengeal epitel
→ tiroglossal kanal → boyun ön kısmı
 - **Atipik lokalizasyon olabilir :**
lateral aberan tiroid (UBB),
lingual, subhyoid, substernal
(*total tiroidektomide dikkat gerek*)
- Brankial poş kalıntıları:**
intratiroideal timus, paratiroid

Olgu 1

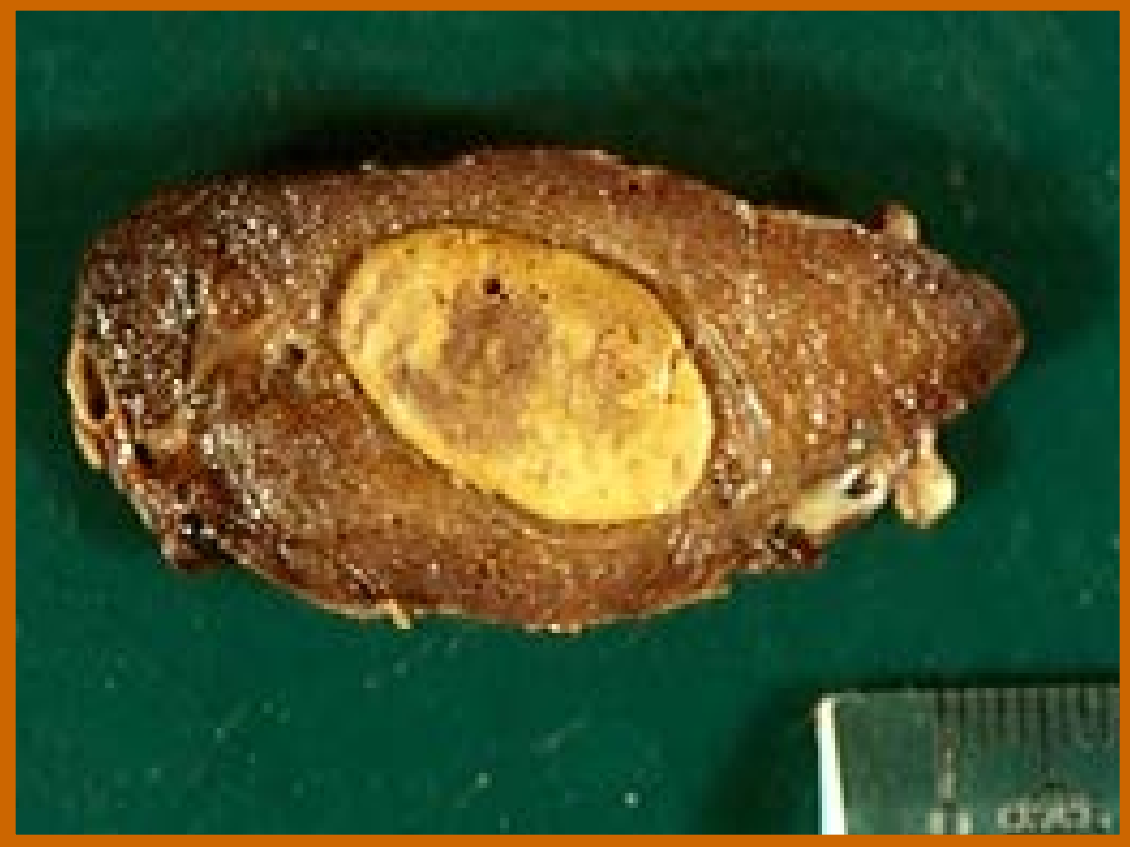47 yaşında bayan hasta

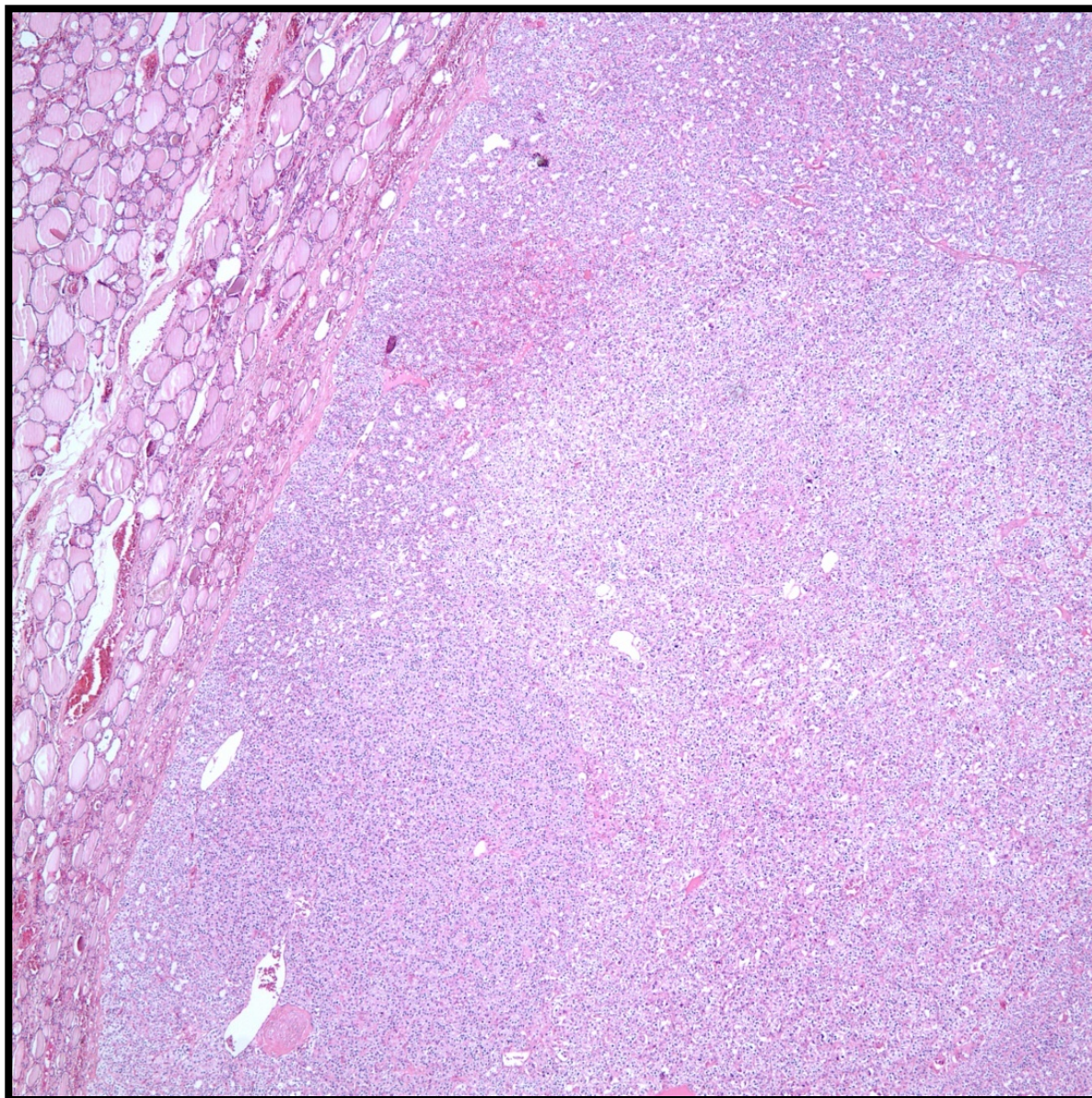
Hiperkalsemi nedeni ile baş vuruyor.

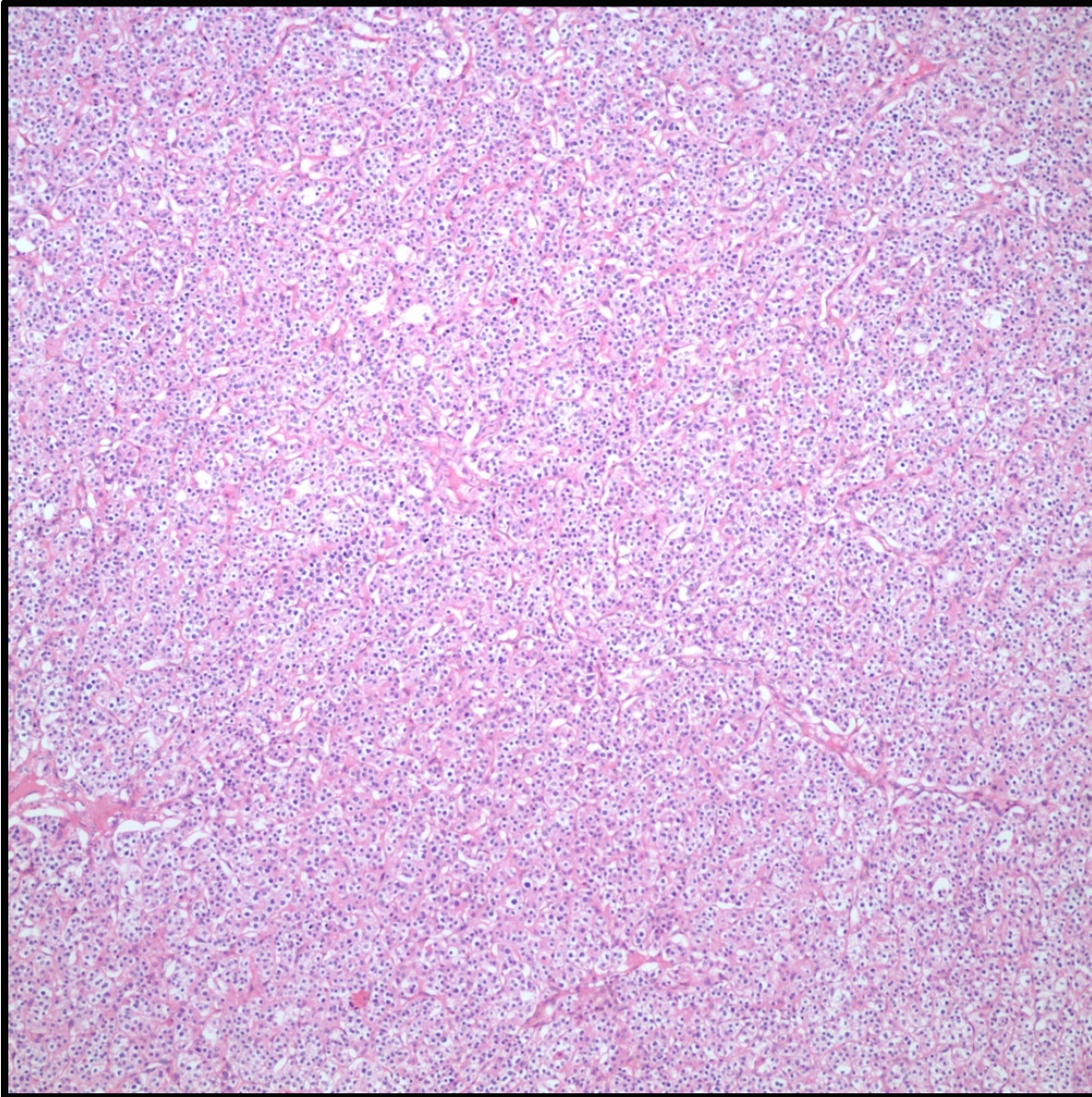
Yapılan ultrasonda belirgin paratiroid büyümesi yok.

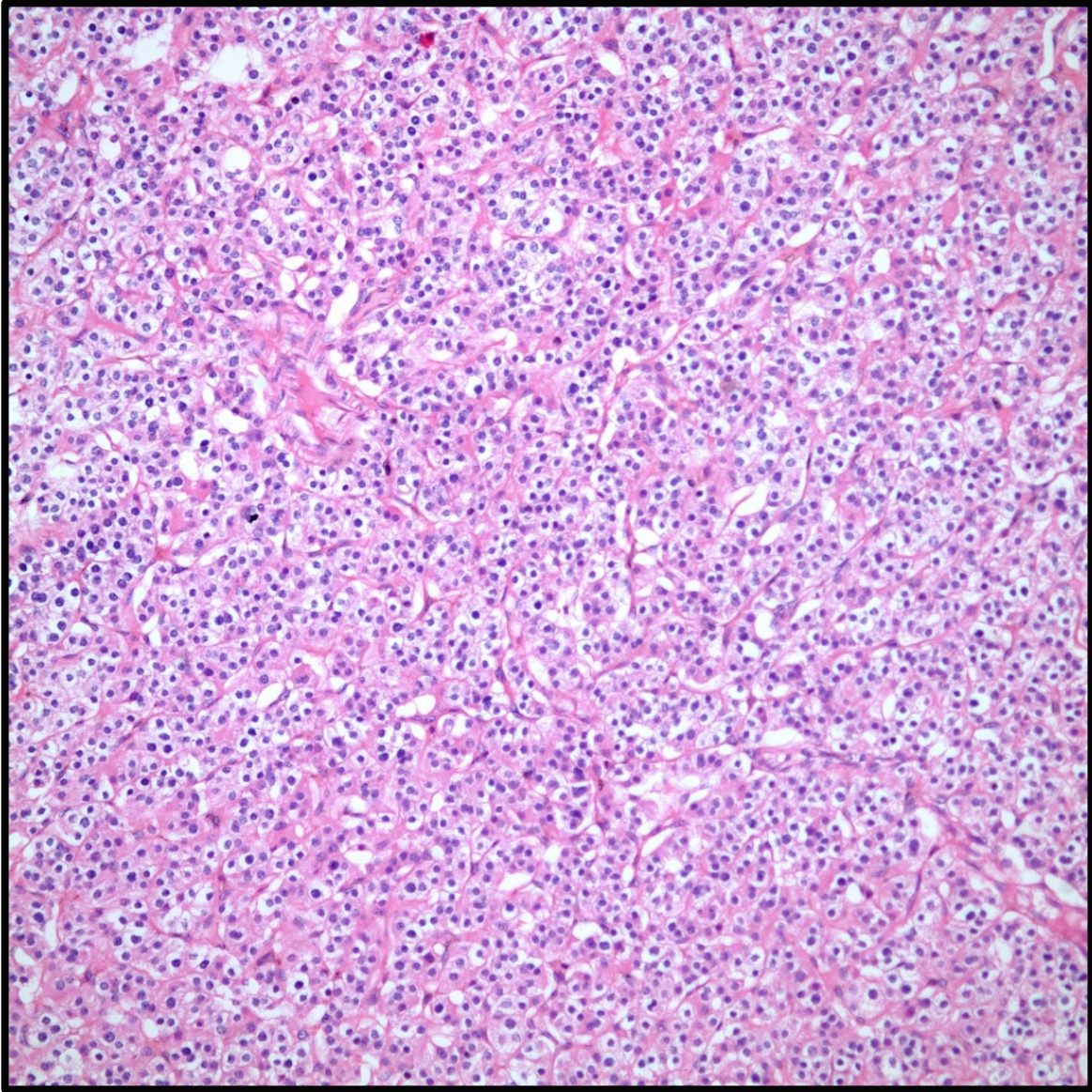
Tiroid sol lobda 2,5 cm çapında nodül

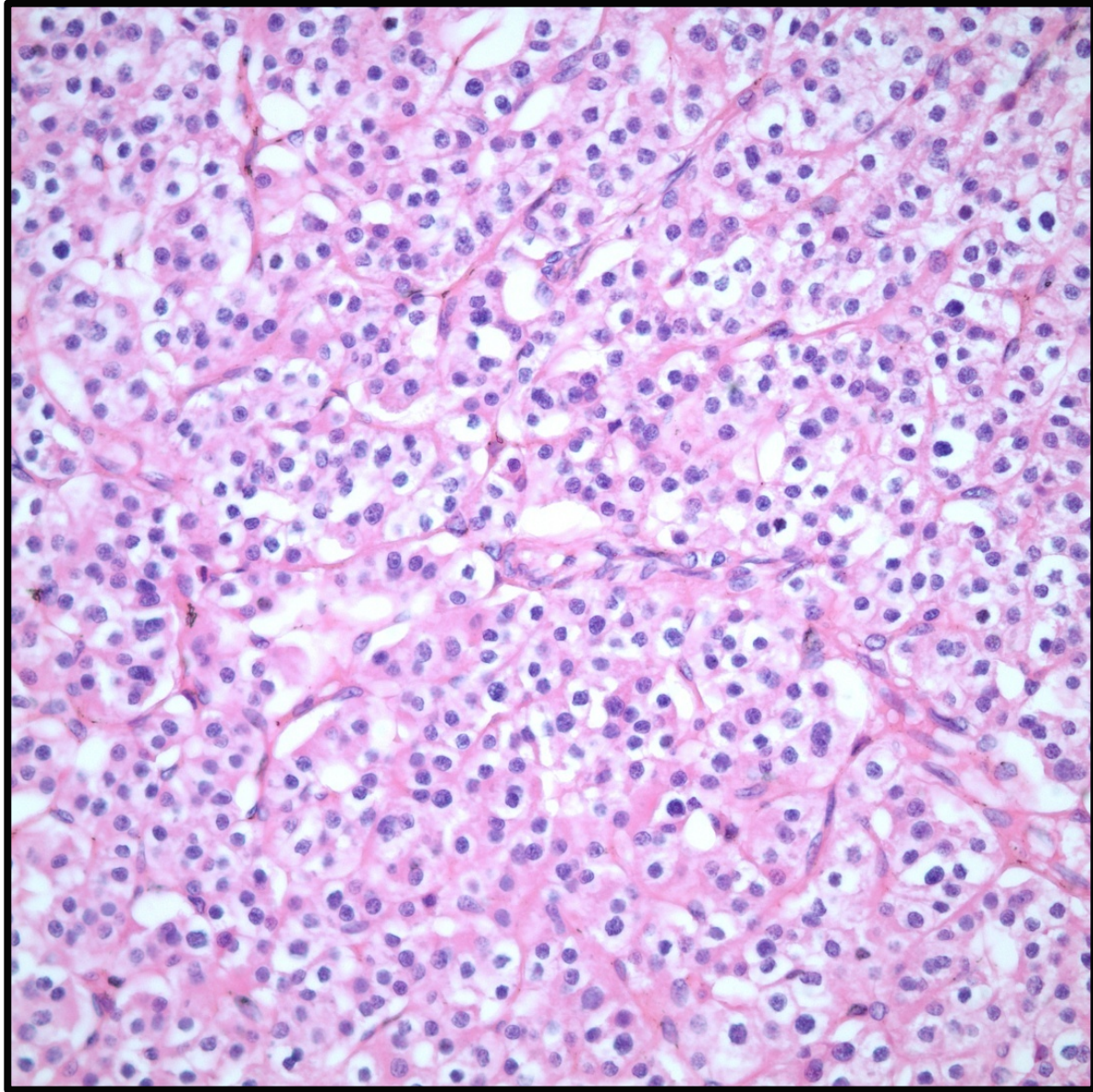
Hasta opere ediliyor ve operasyon sırasında paratiroid bezlerinden intraoperatif örnekleme yanında sol total sağ subtotal tiroidektomi yapılıyor.

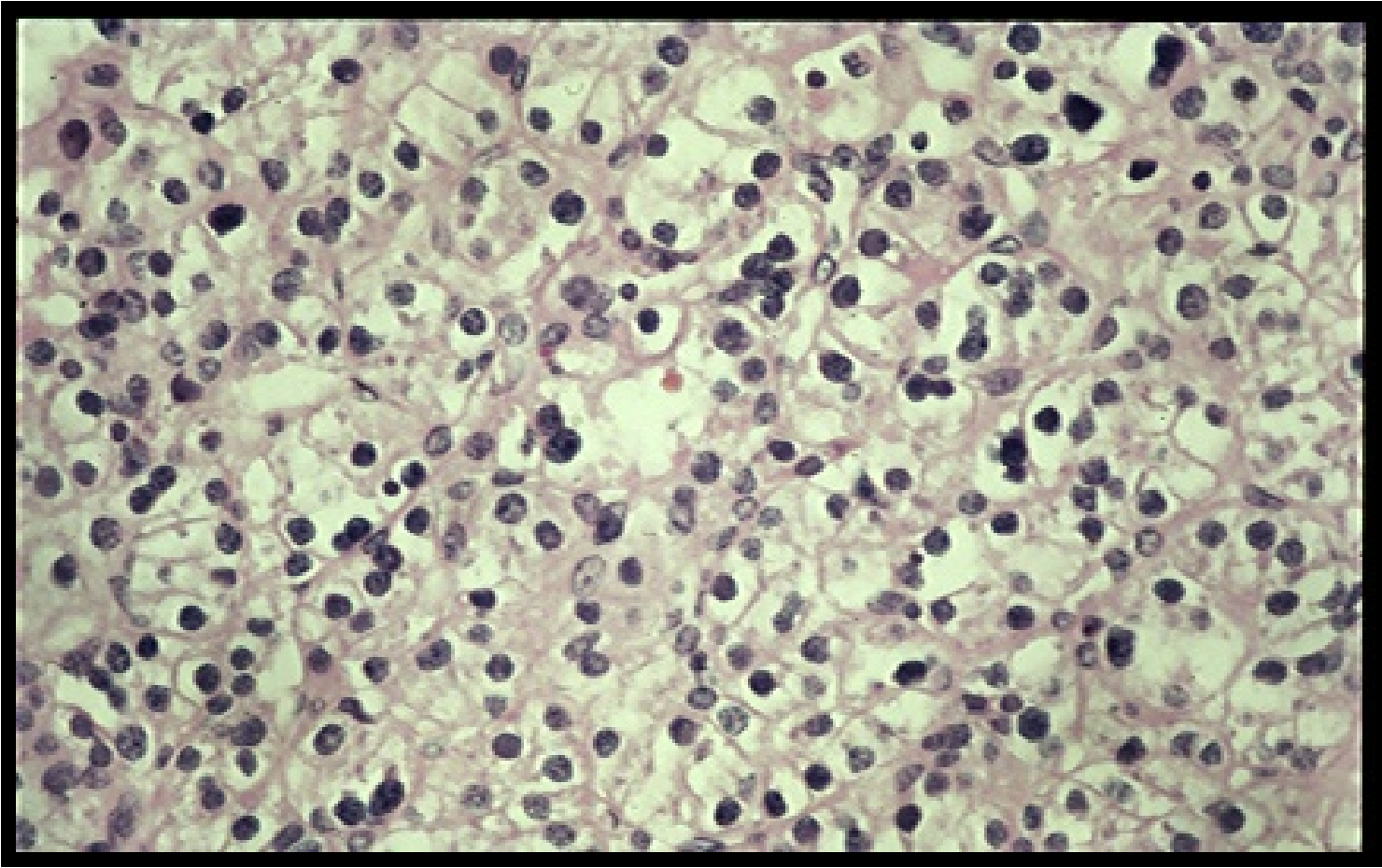






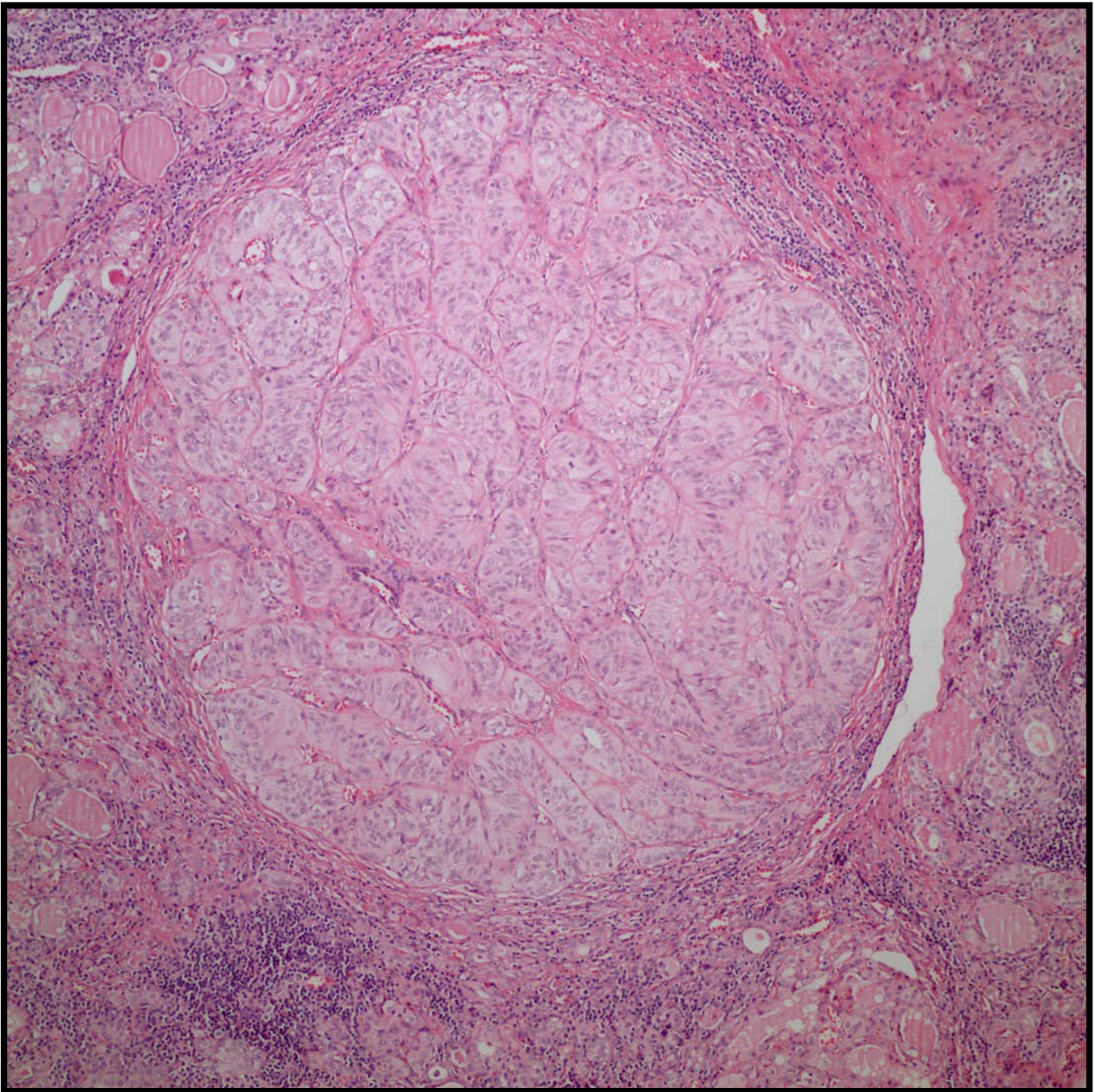


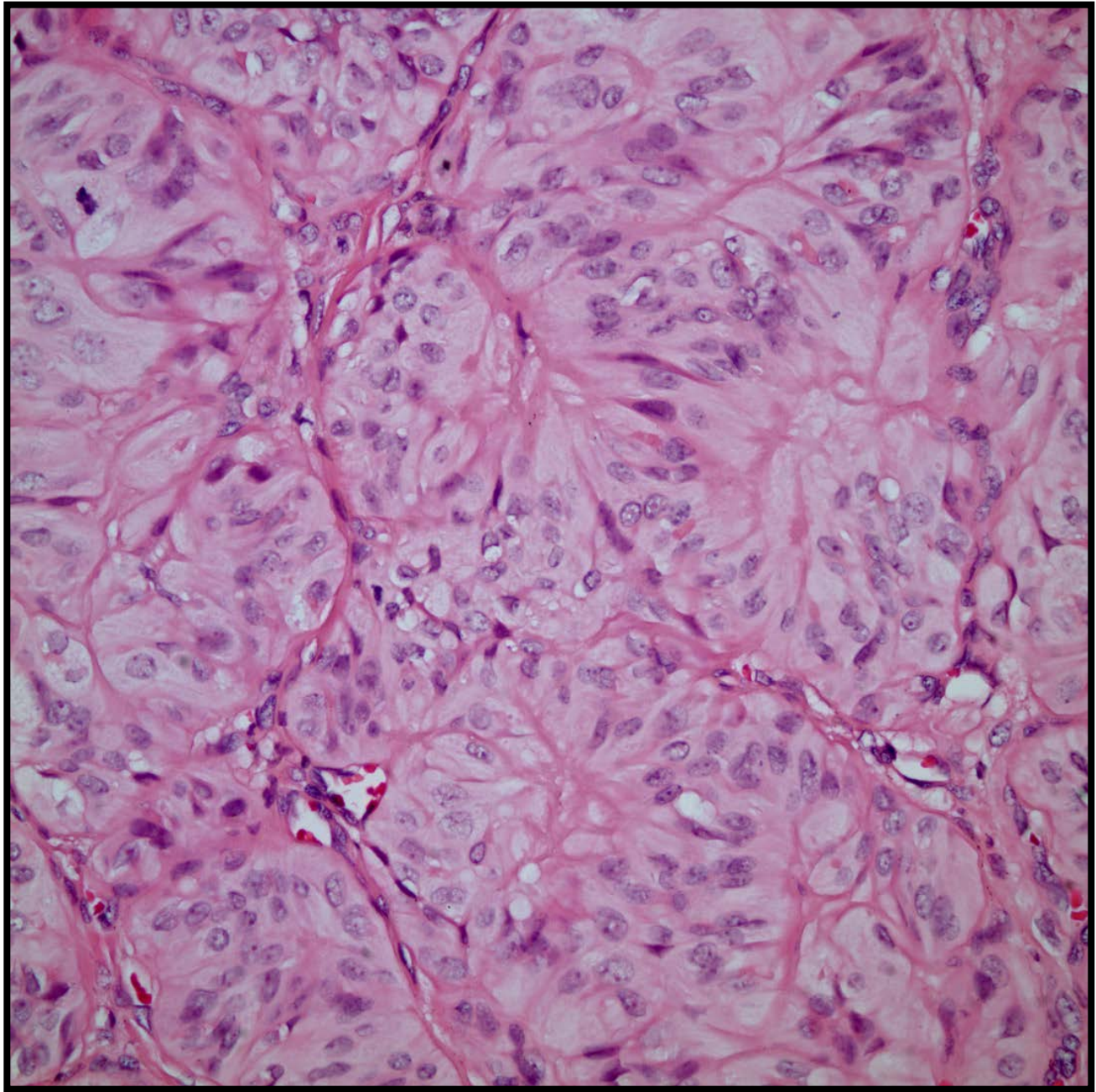


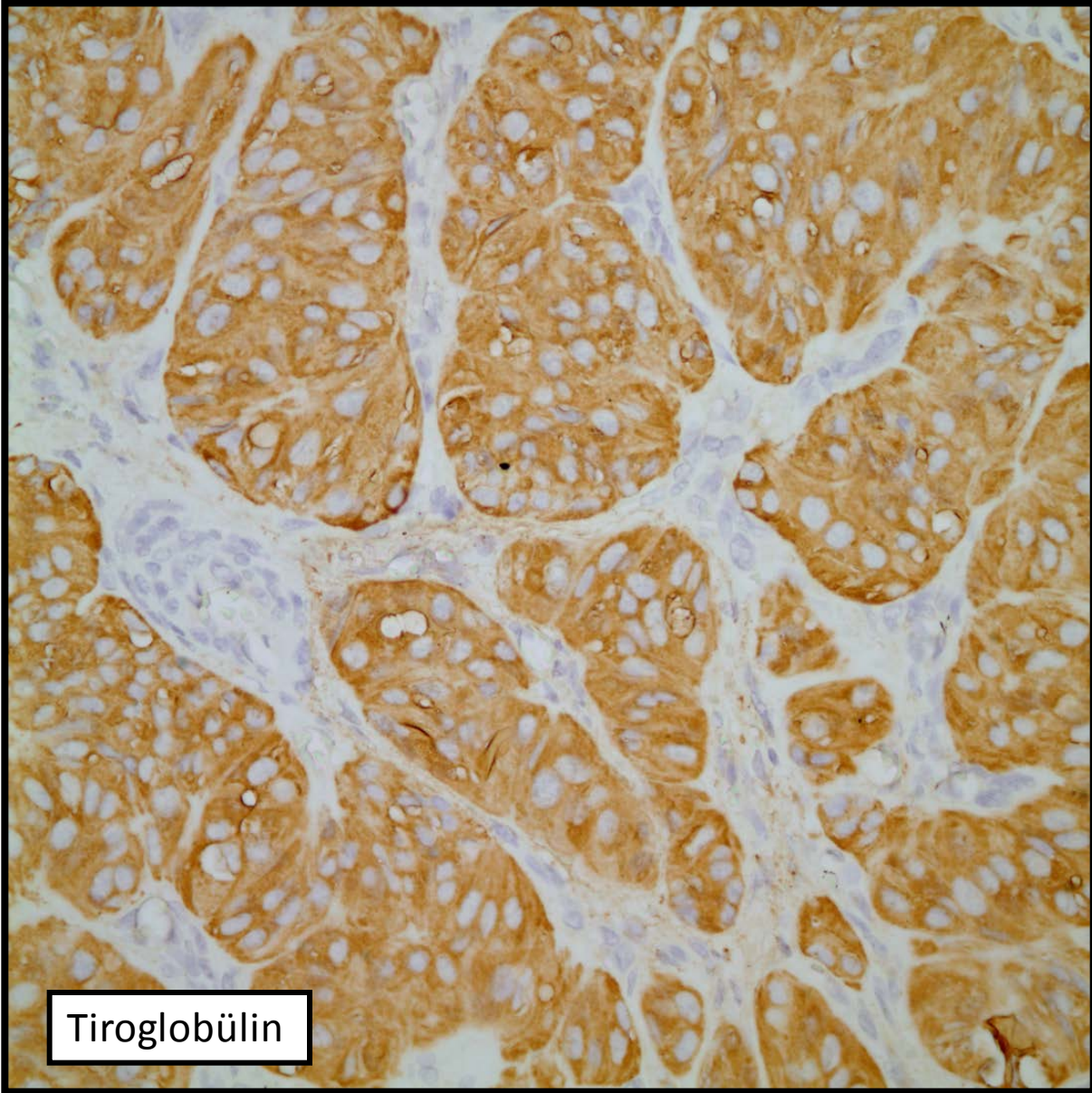


Olgu 2

- 36 yaşında kadın hasta
- Sitoloji: Hurthle hücreleri mevcut, tiroidit?
- Makroskopide sarı kırmızı alacalı görünümde kesit yüzü olan tiroidektomi de nodül yok



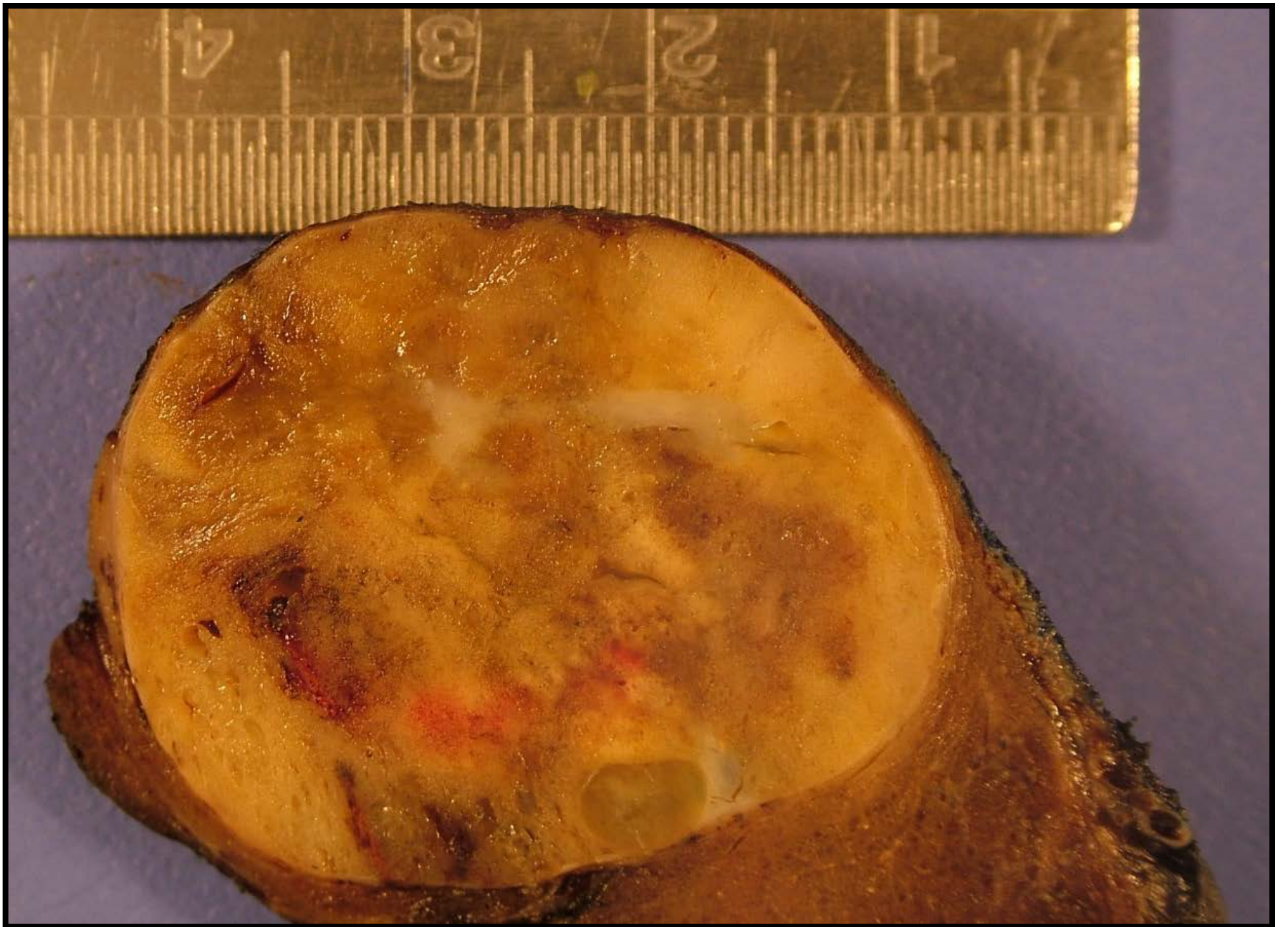




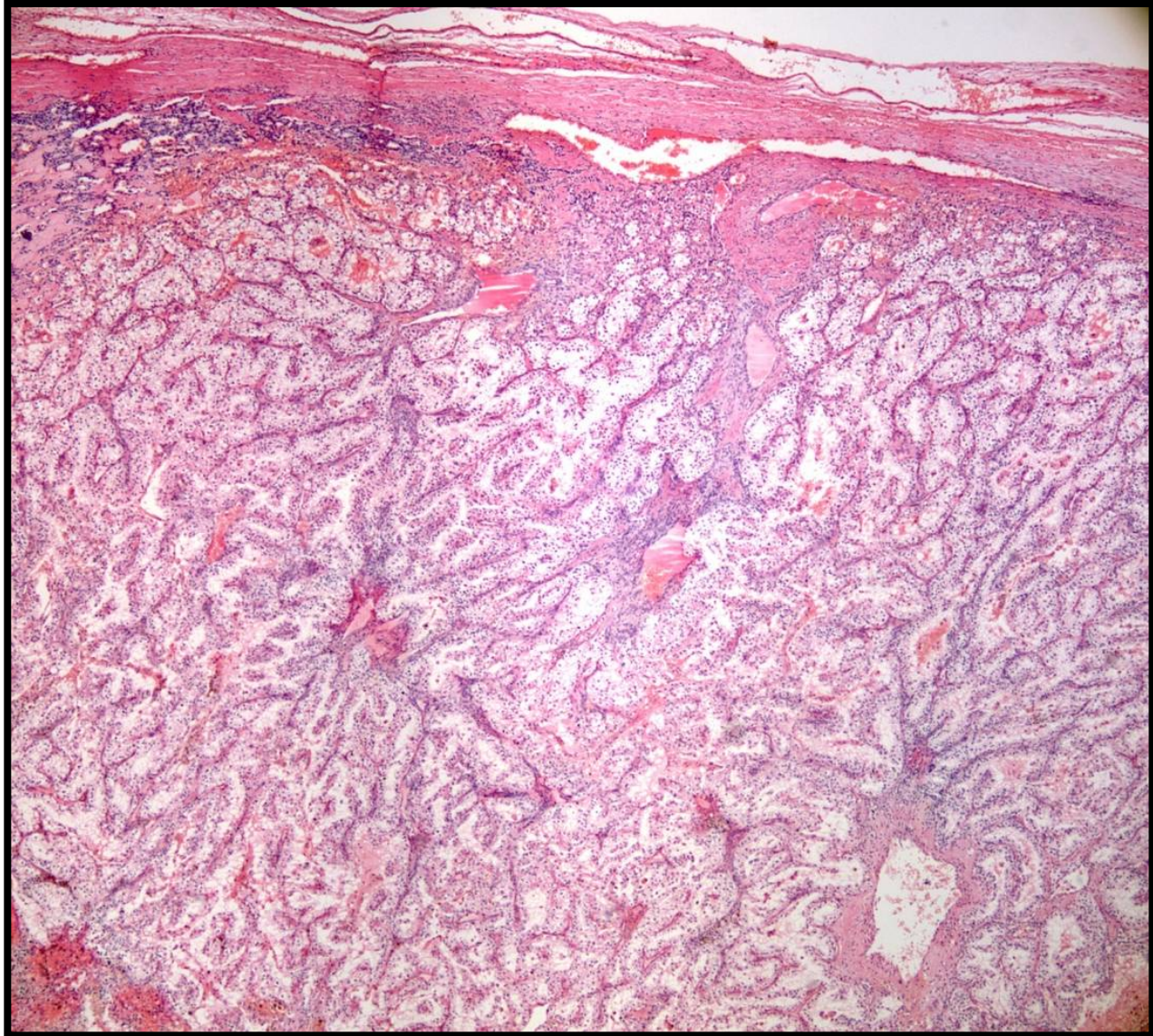
Tiroglobülin

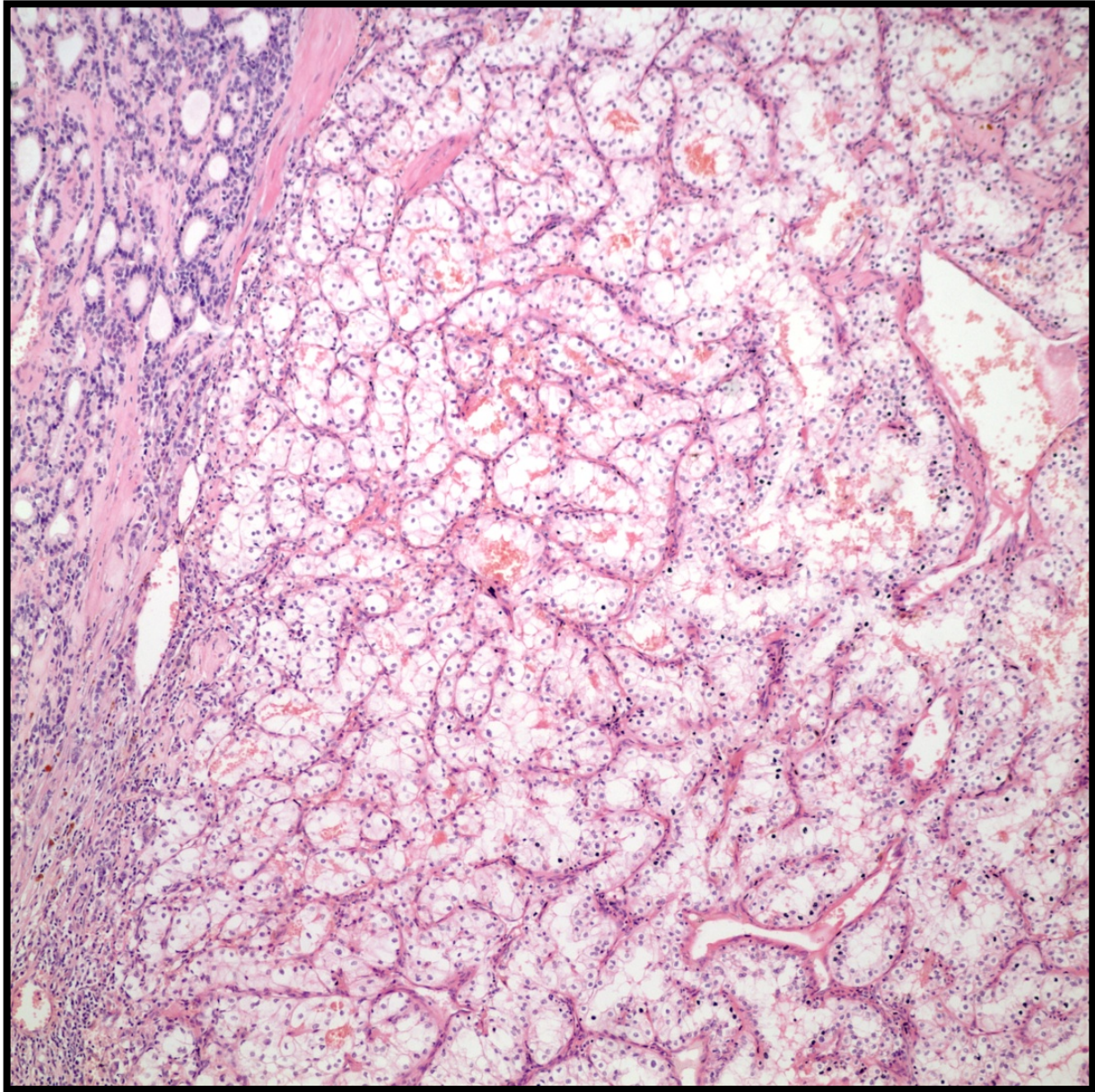
Olgu 3

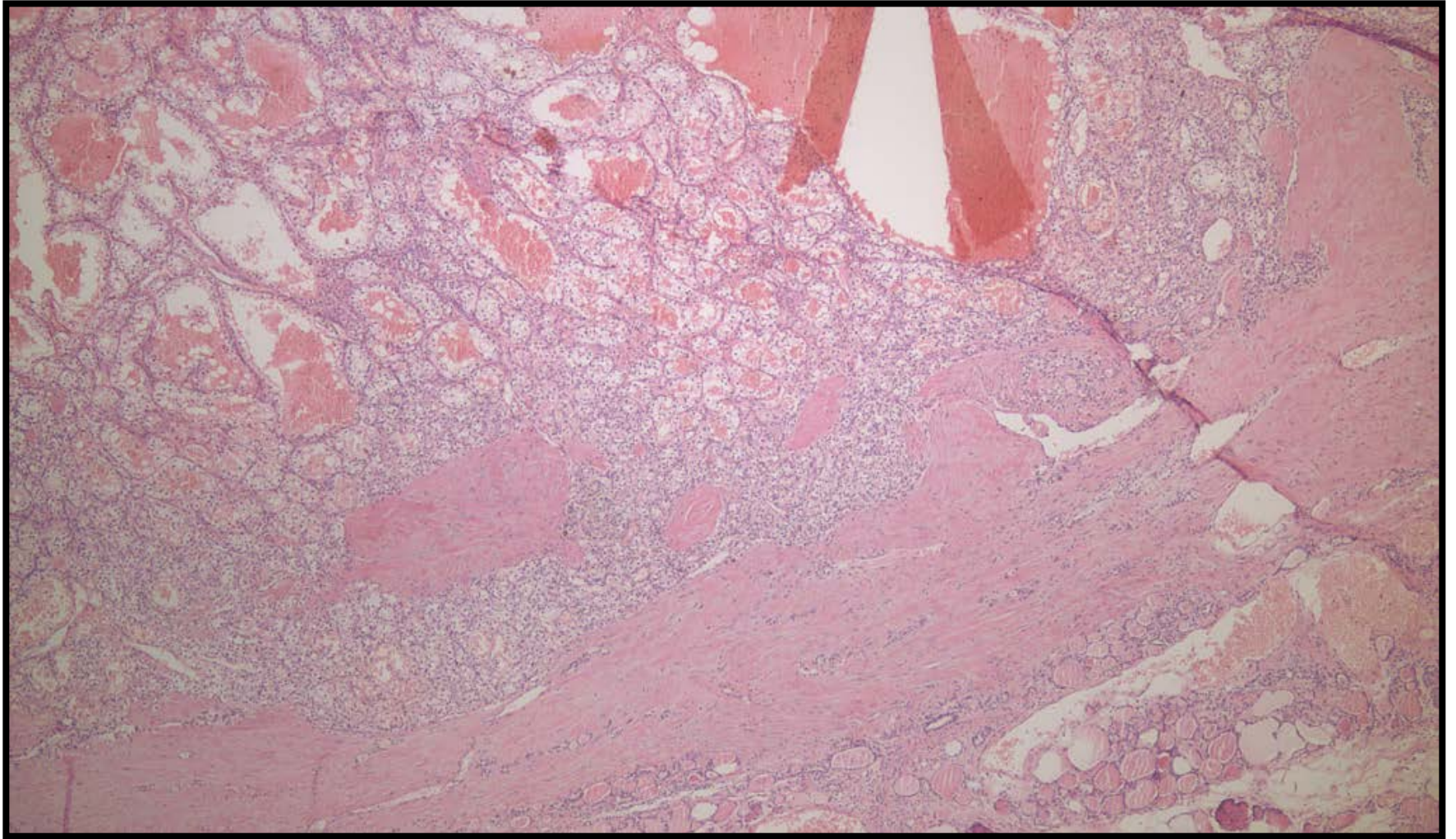
- 51 yaşında erkek hasta
- Ultrasonda sağ lobda 3 cm çapında solid kitle
- Hastaya sağ total sol subtotal tiroidektomi yapılıyor.

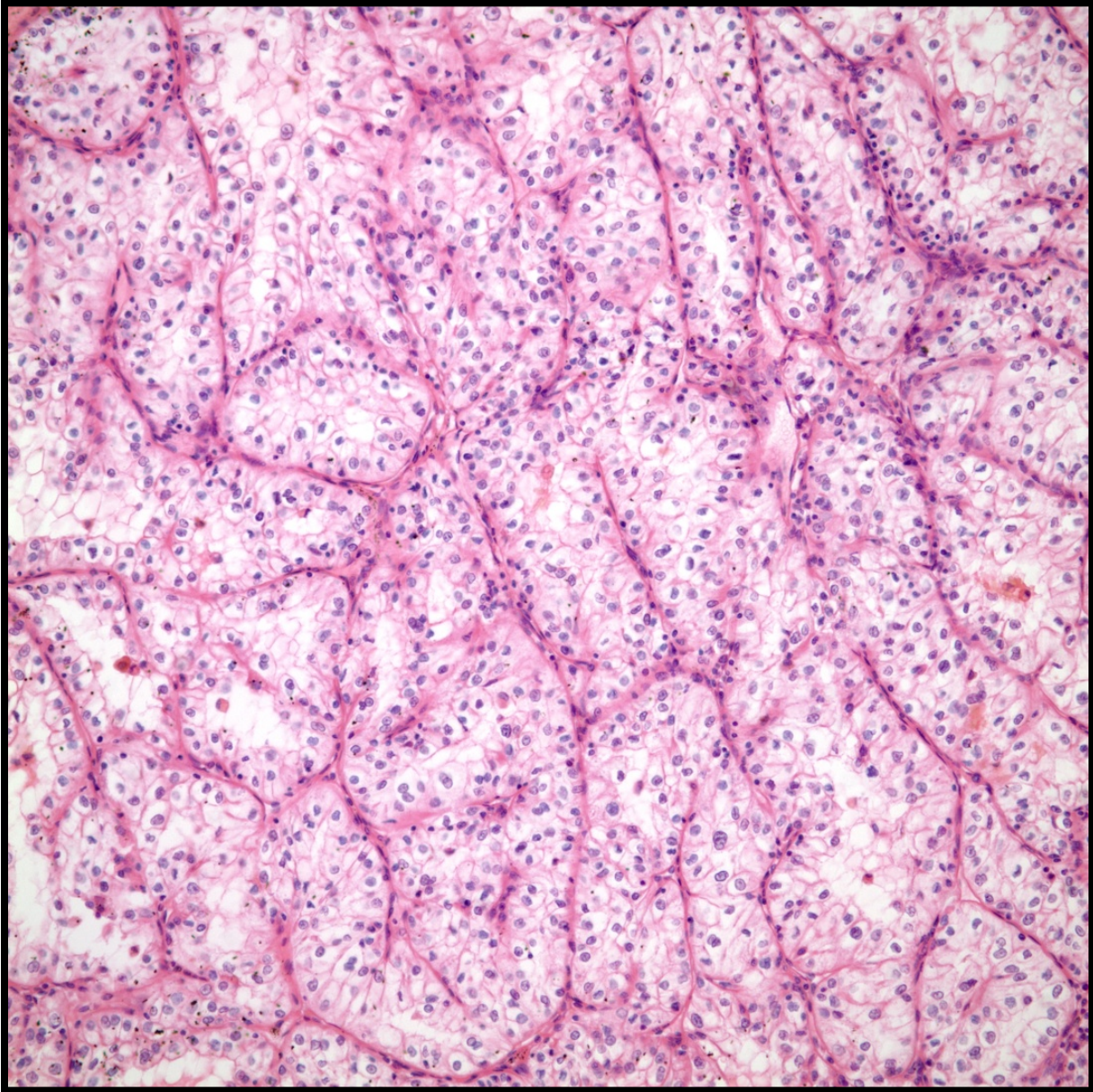


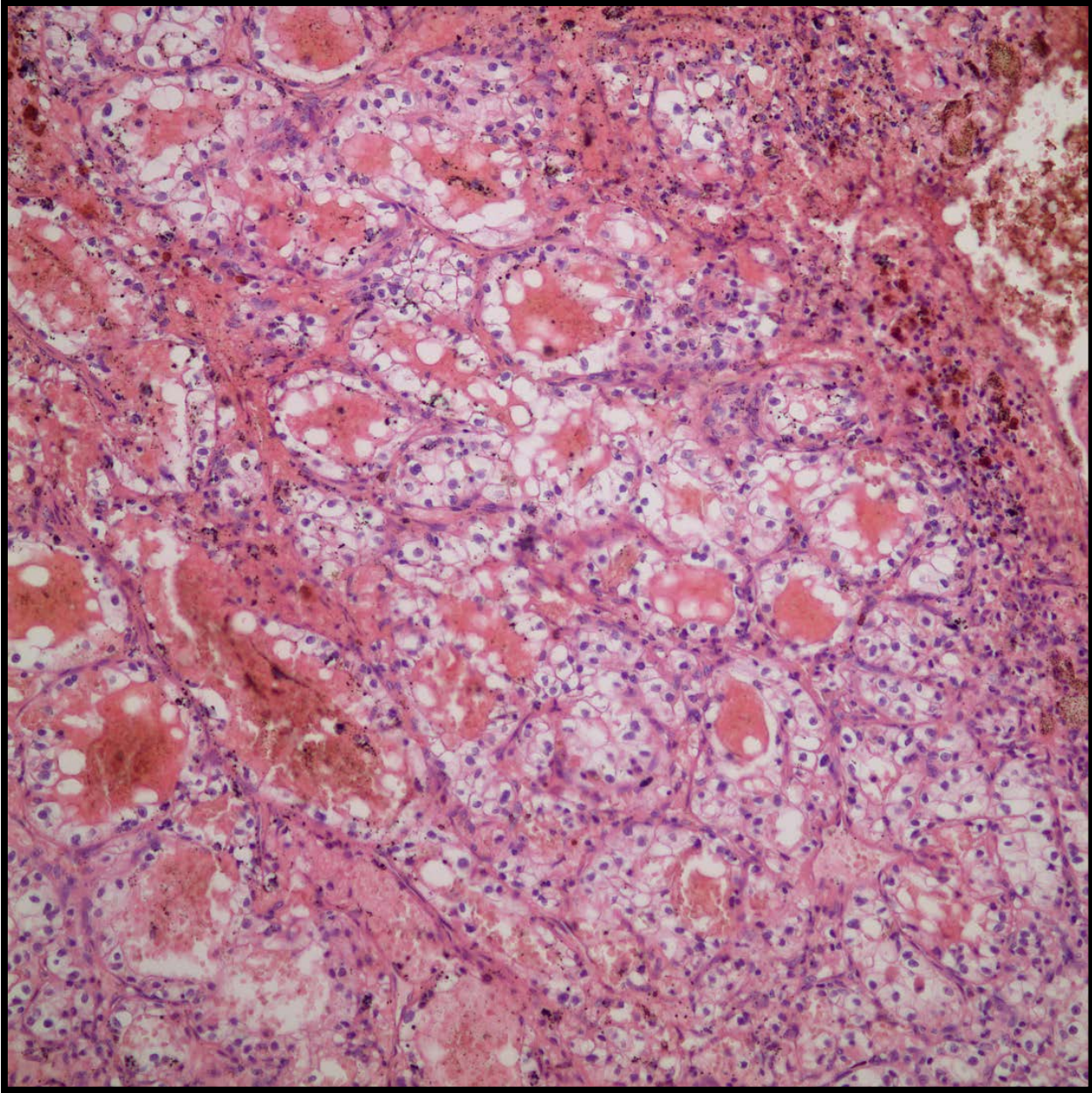
4338-08

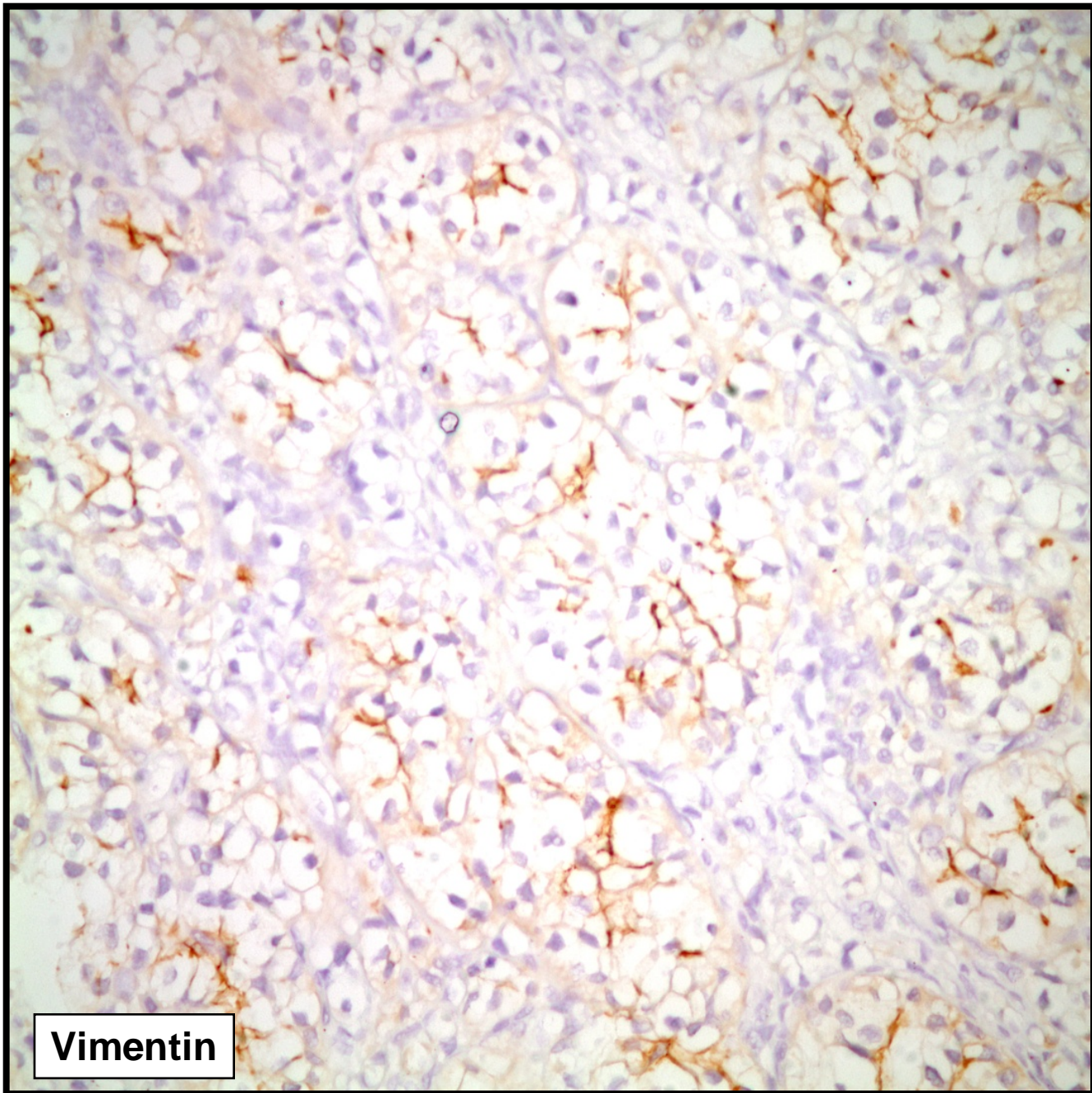




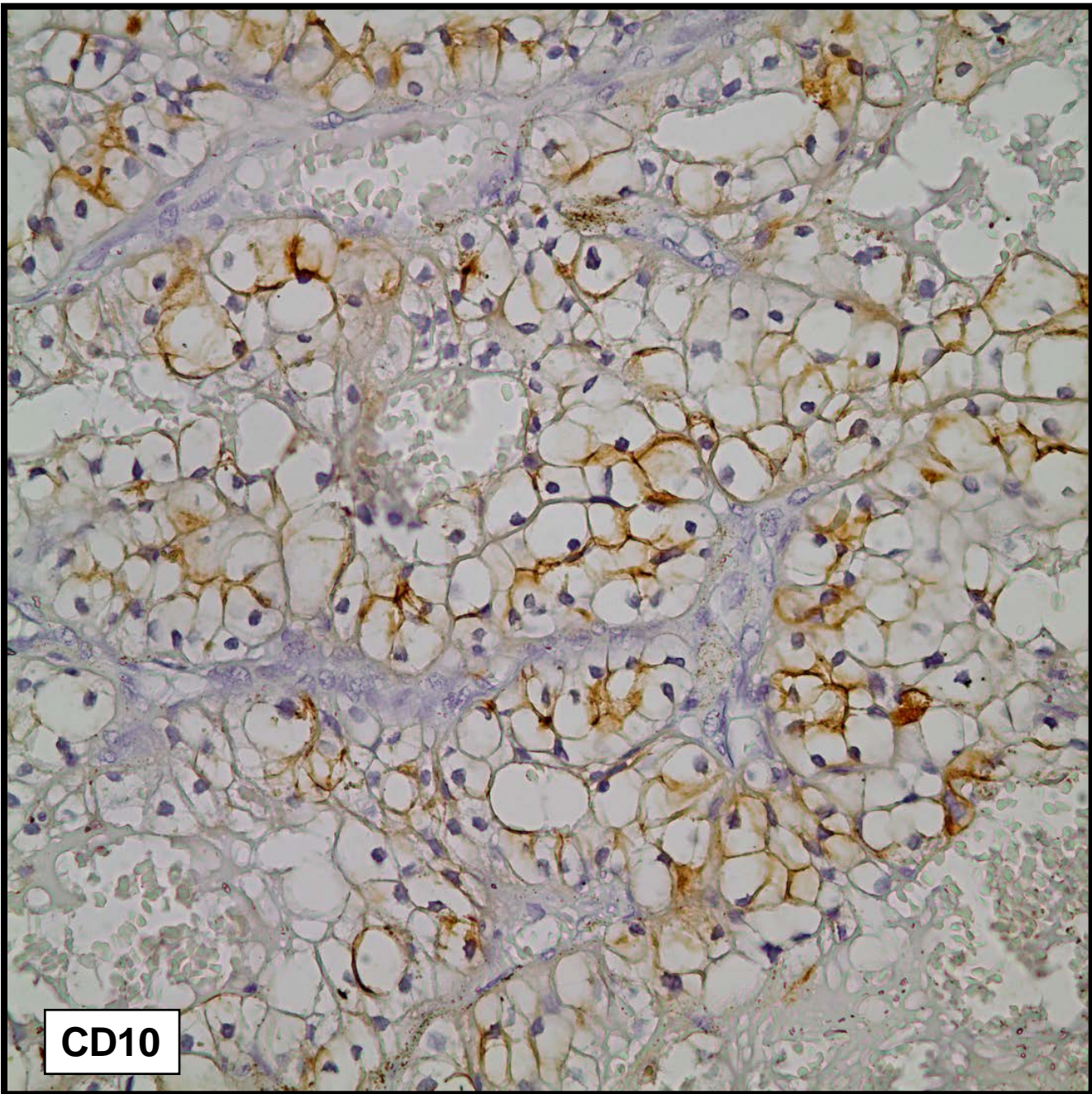








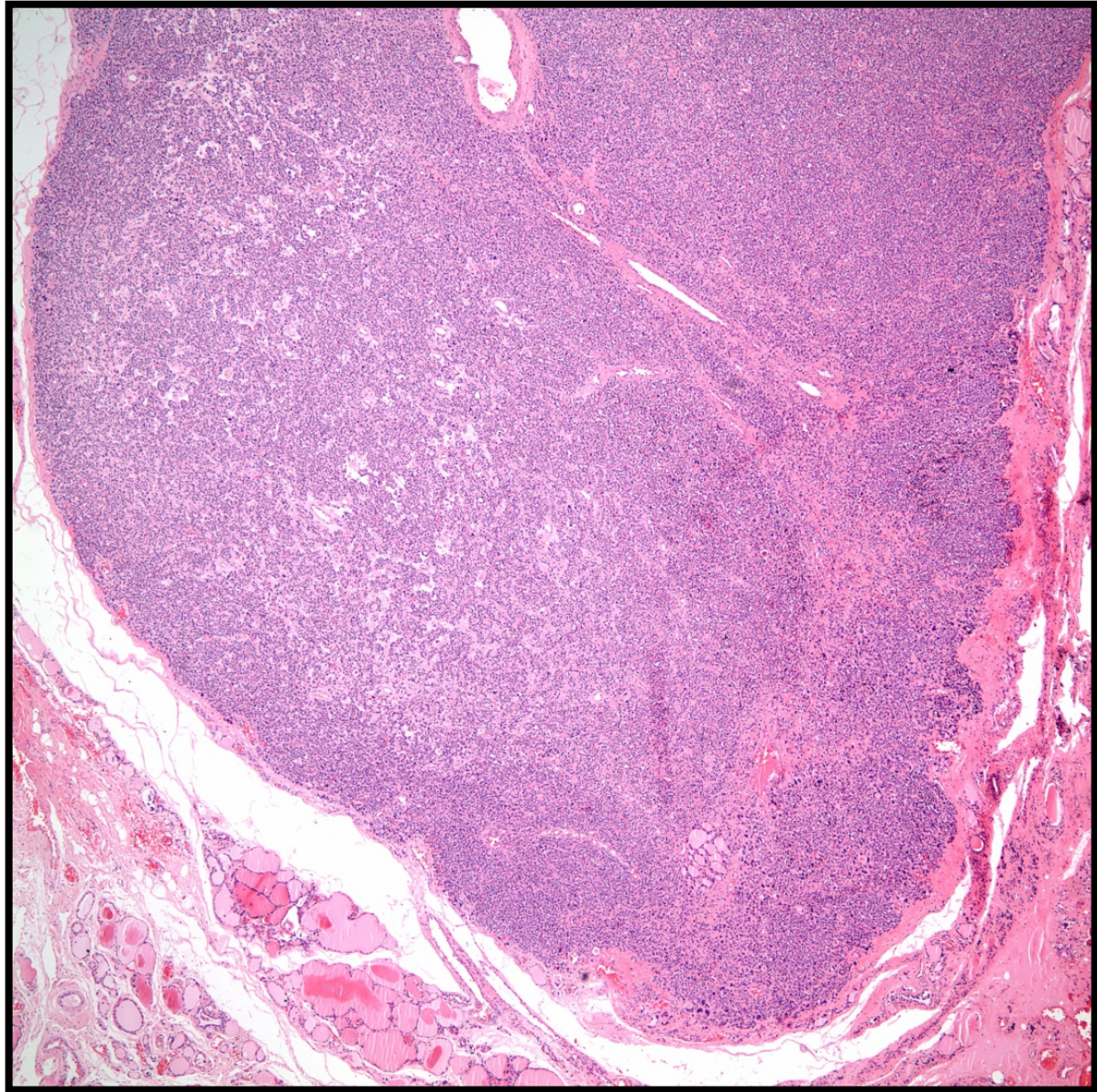
Vimentin

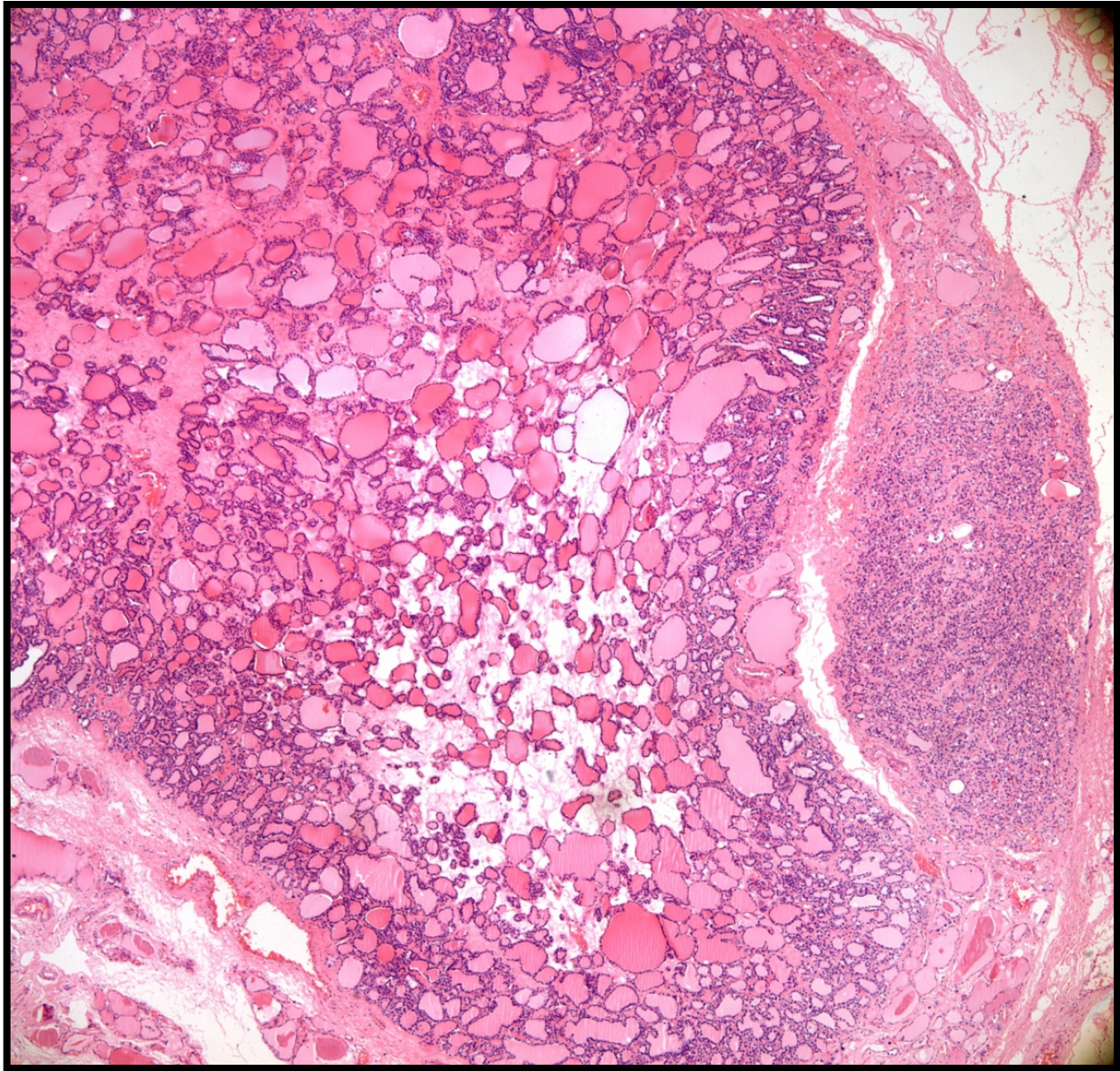


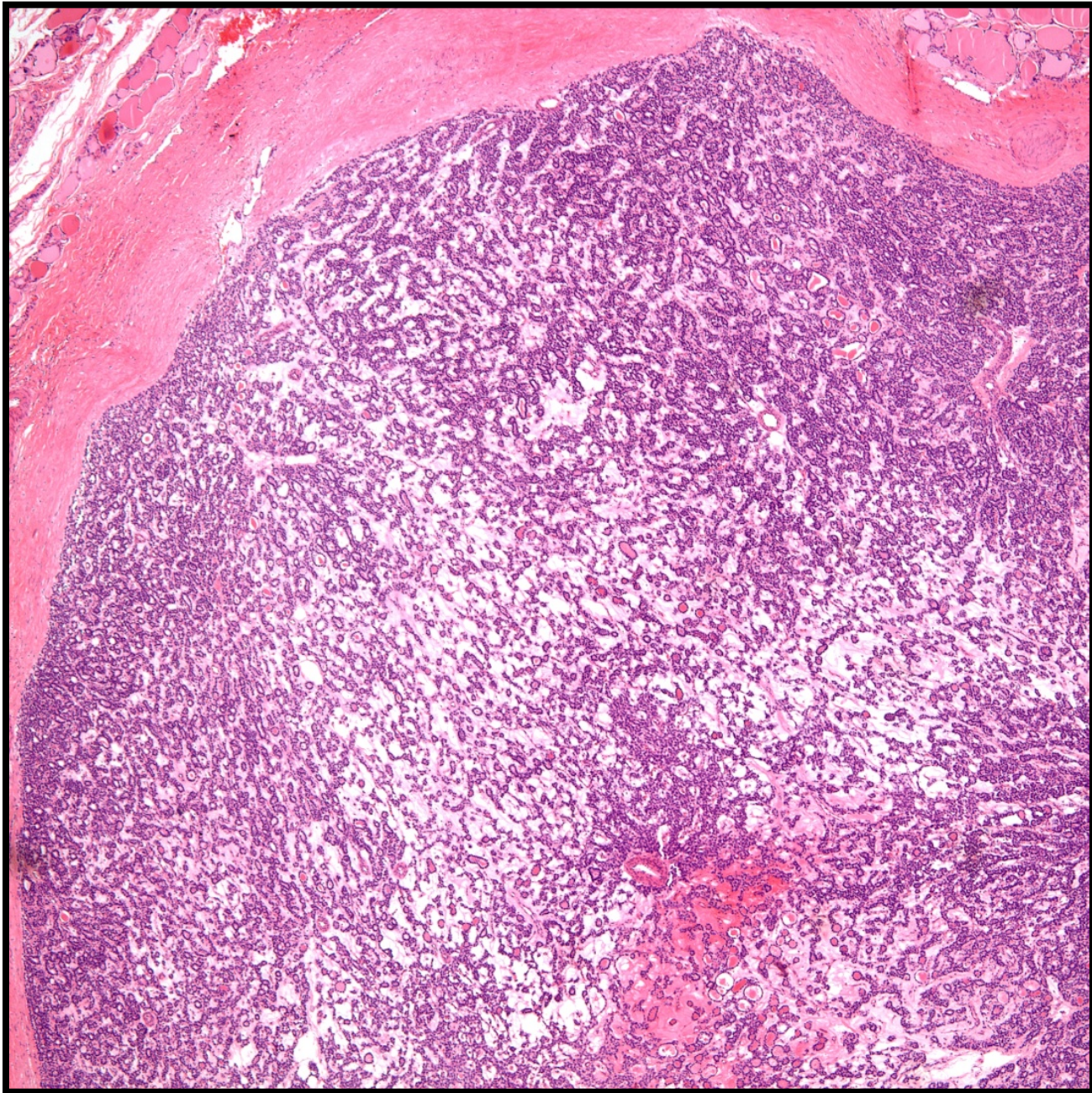
CD10

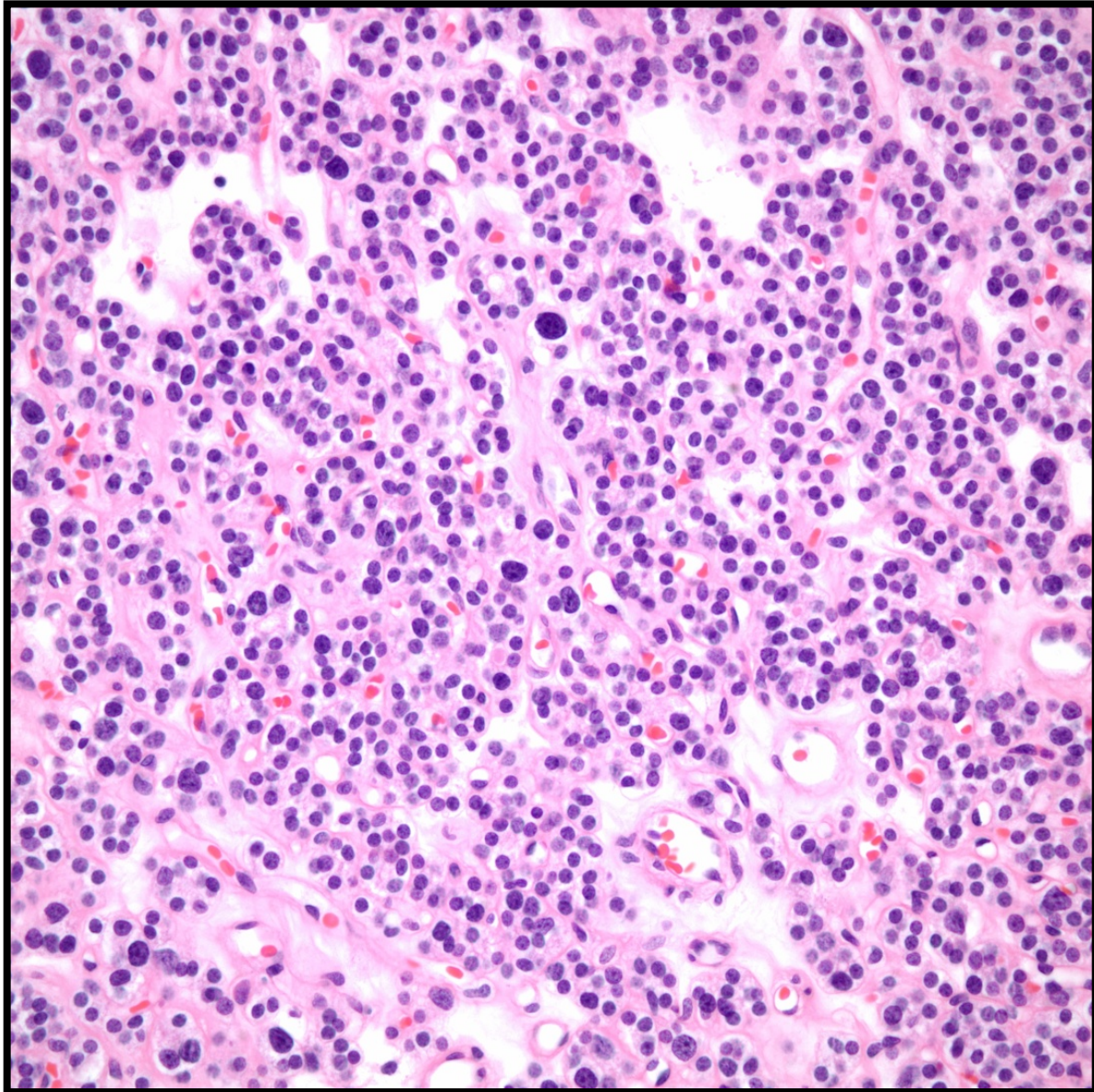
Olgu 4

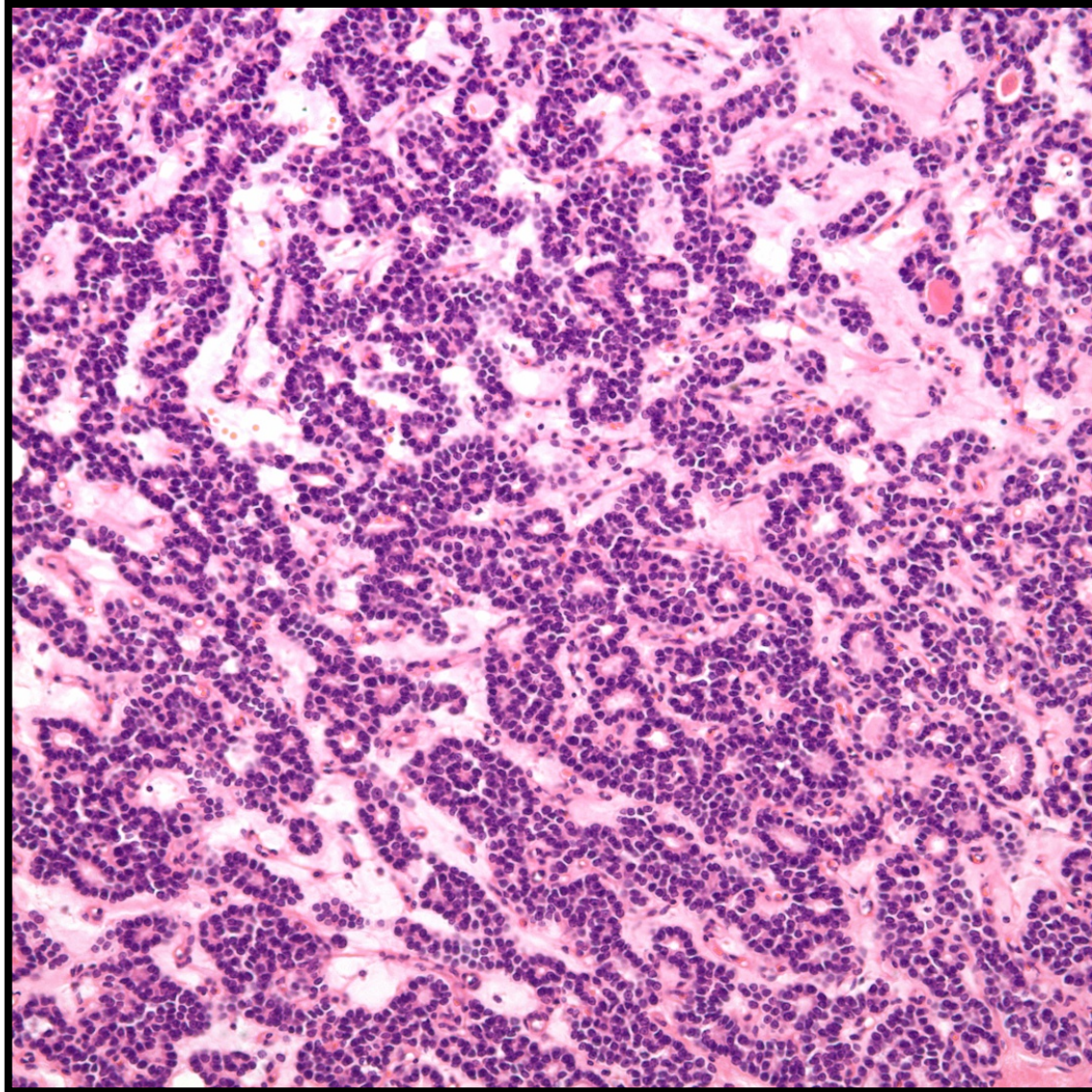
- 27 yaşında erkek hasta
- Tiroidde multiple nodüller nedeniyle izlemde
- Sitoloji malignite açısından şüpheli
- Bilateral total tiroidektomi yapılıyor.
- Makroskopi de en büyüğü sağ lobda ve 1,5 cm çapında olmak üzere her iki lobda da küçük çaplı gri beyaz ve kolloiden fakir görünümlü nodüller

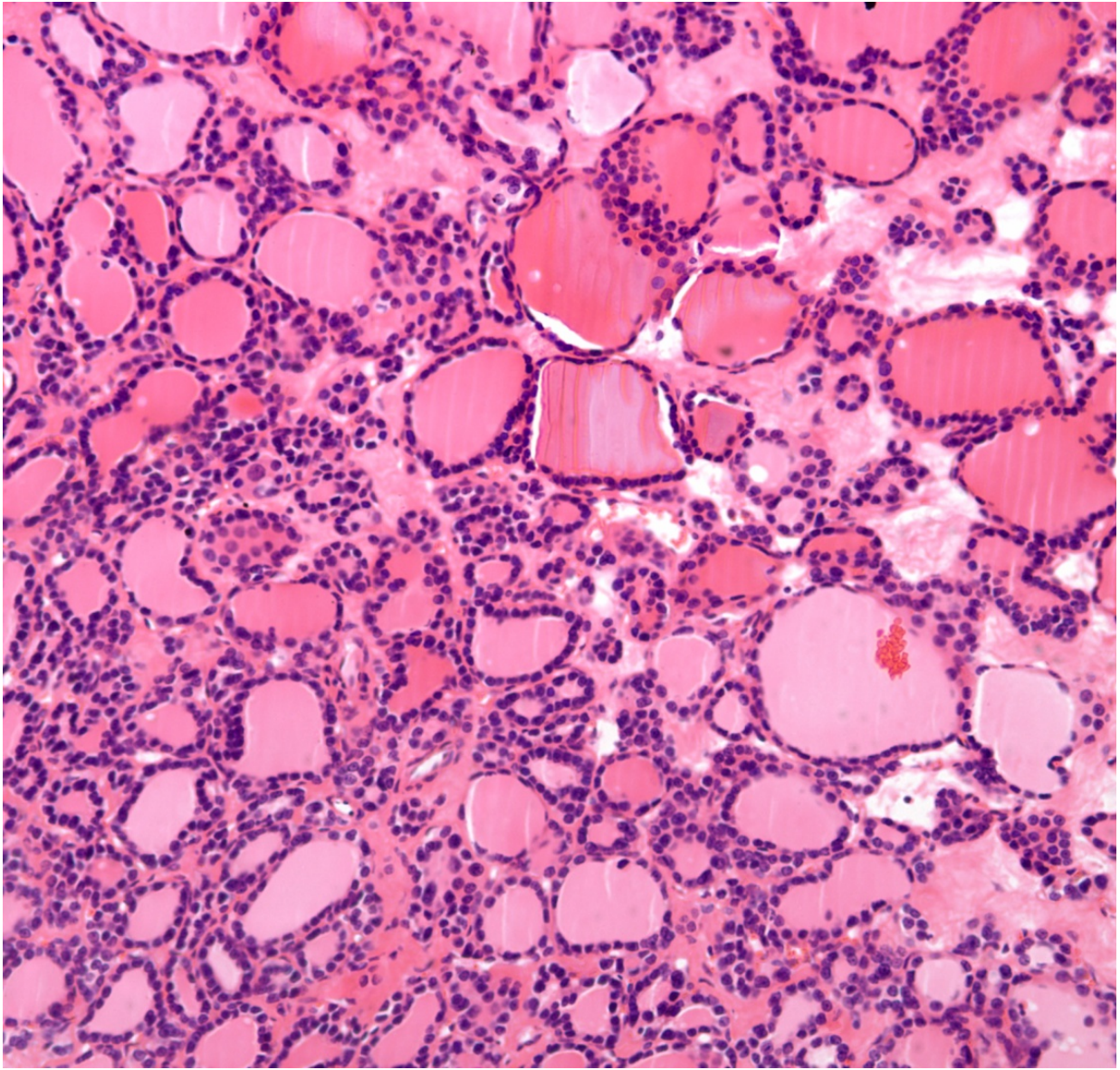


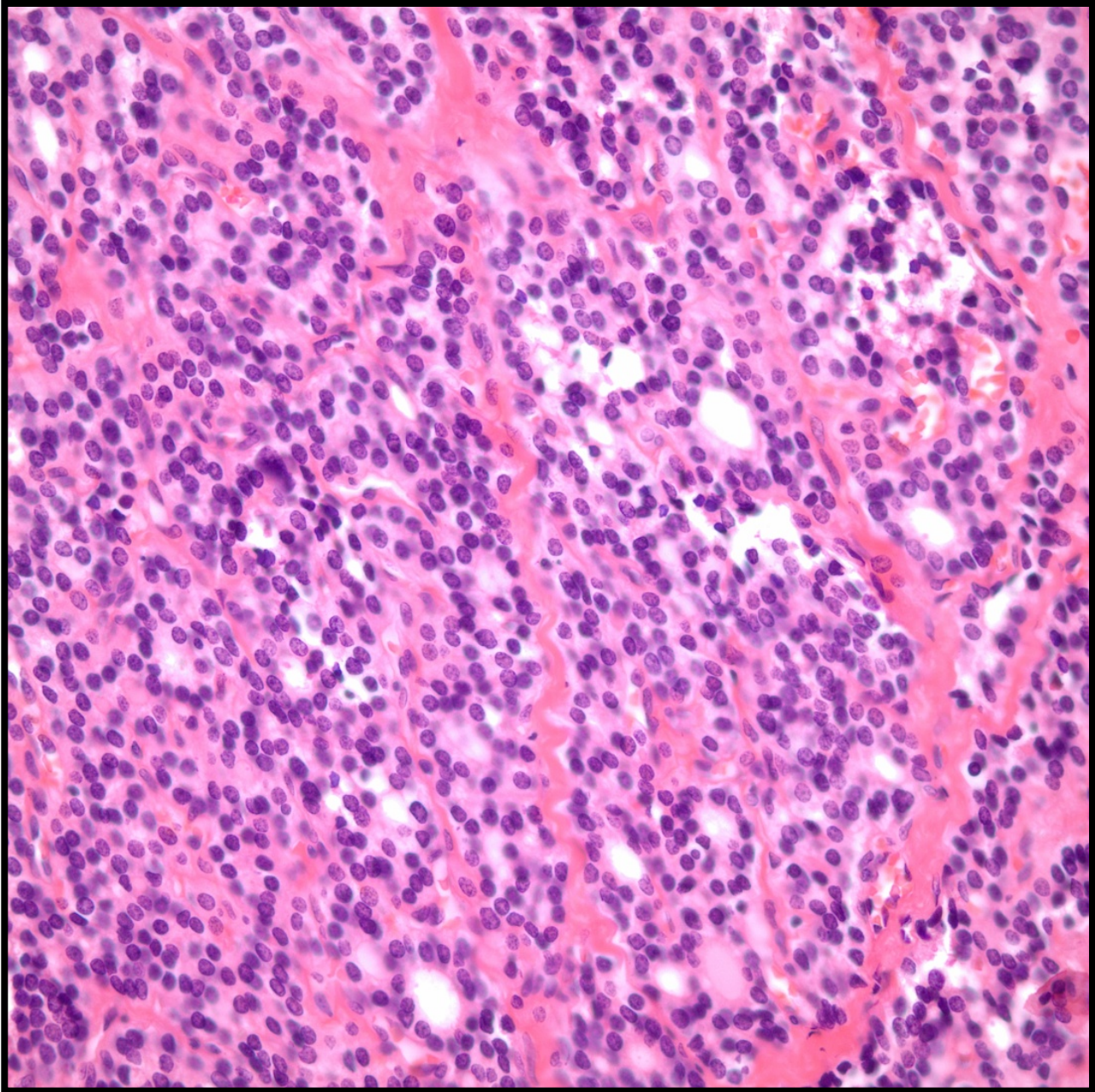


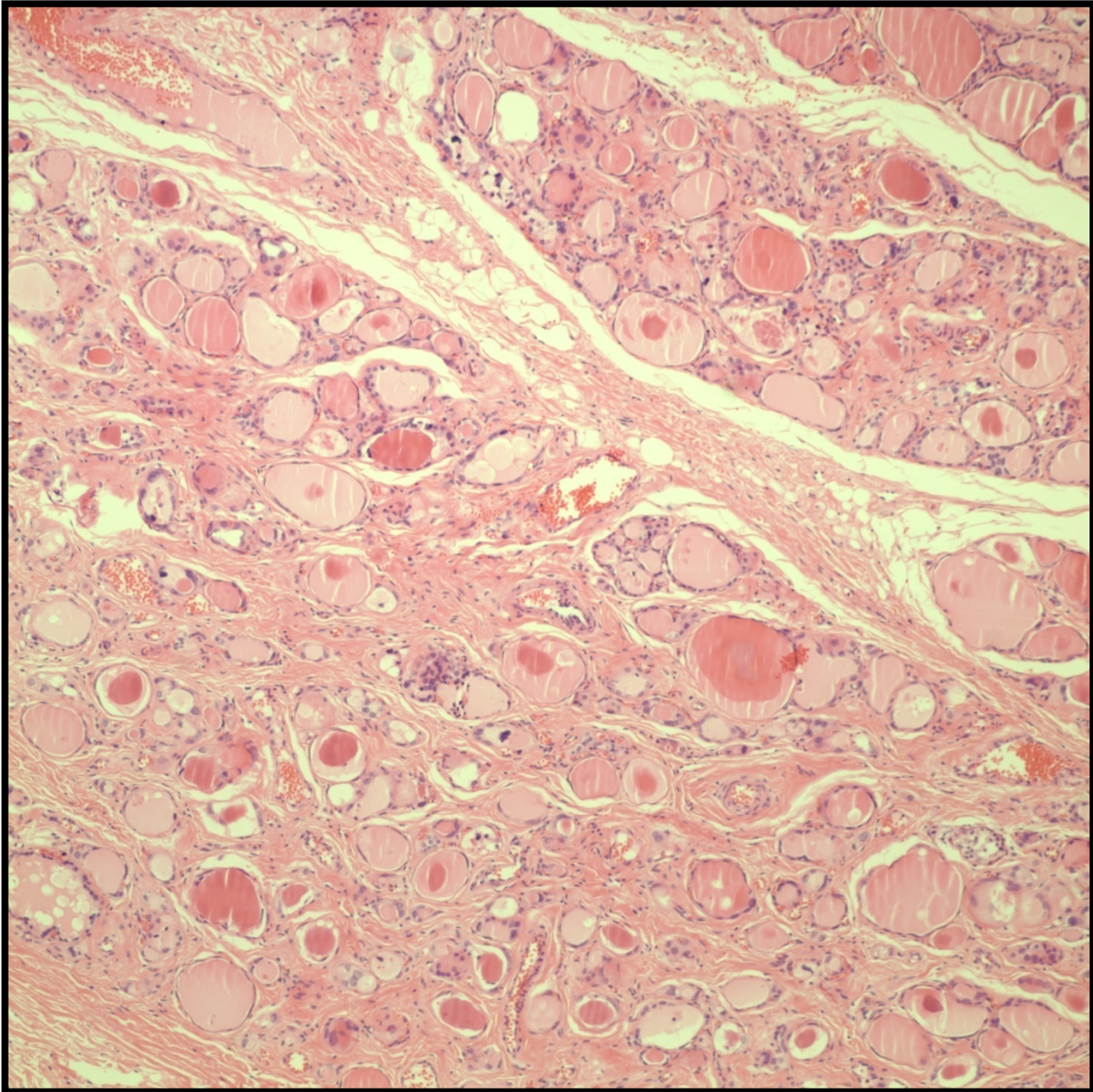


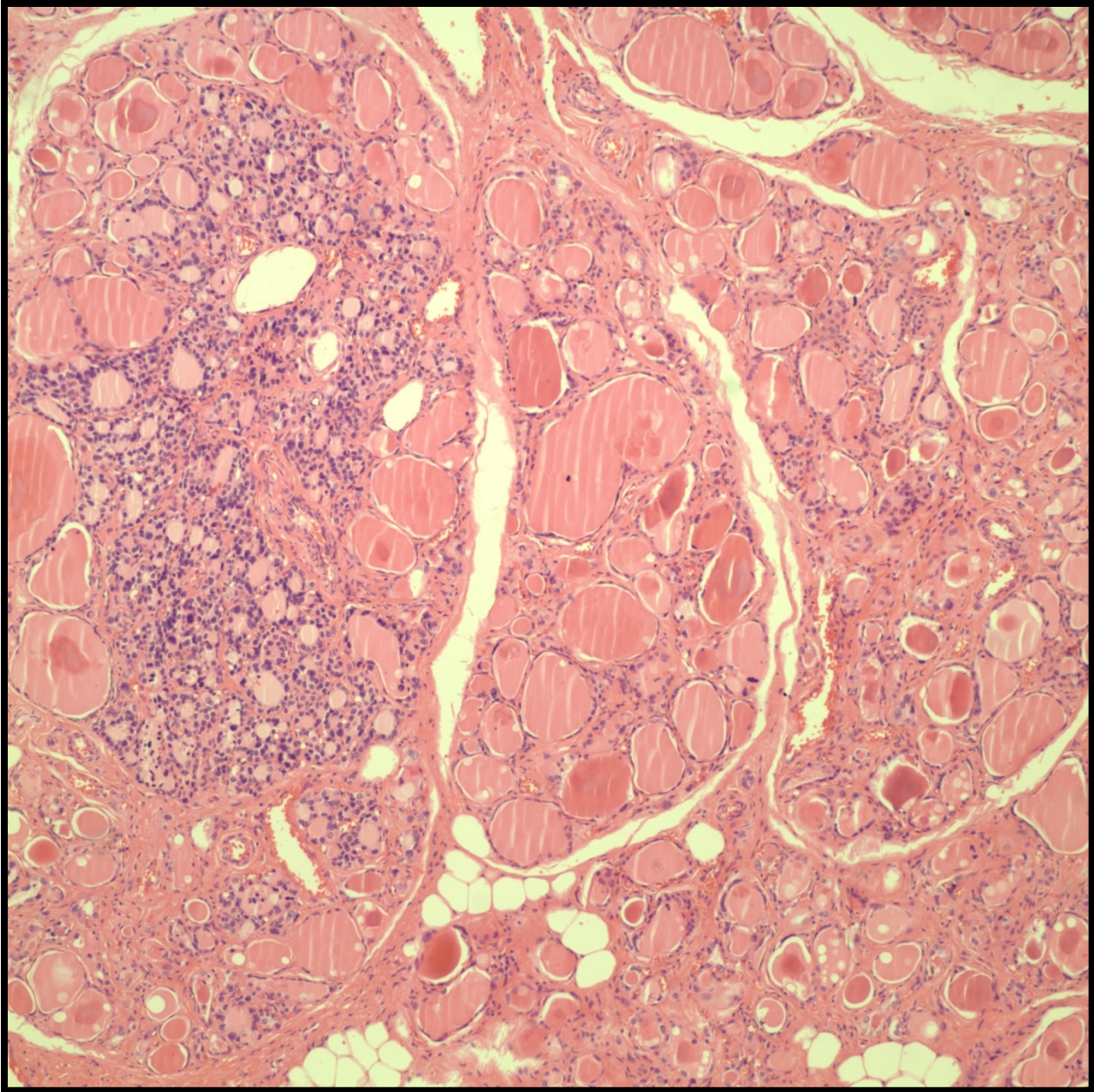


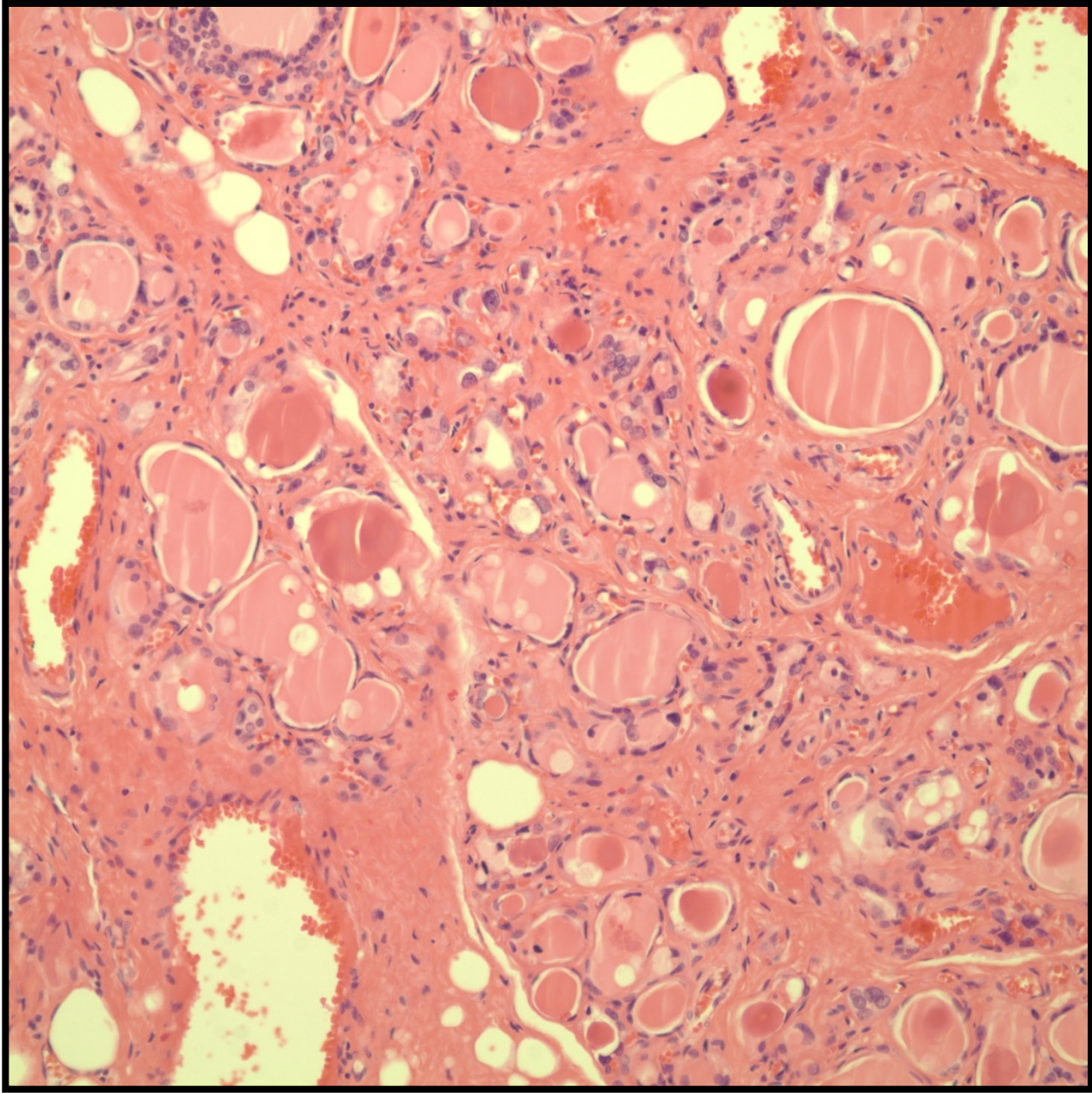


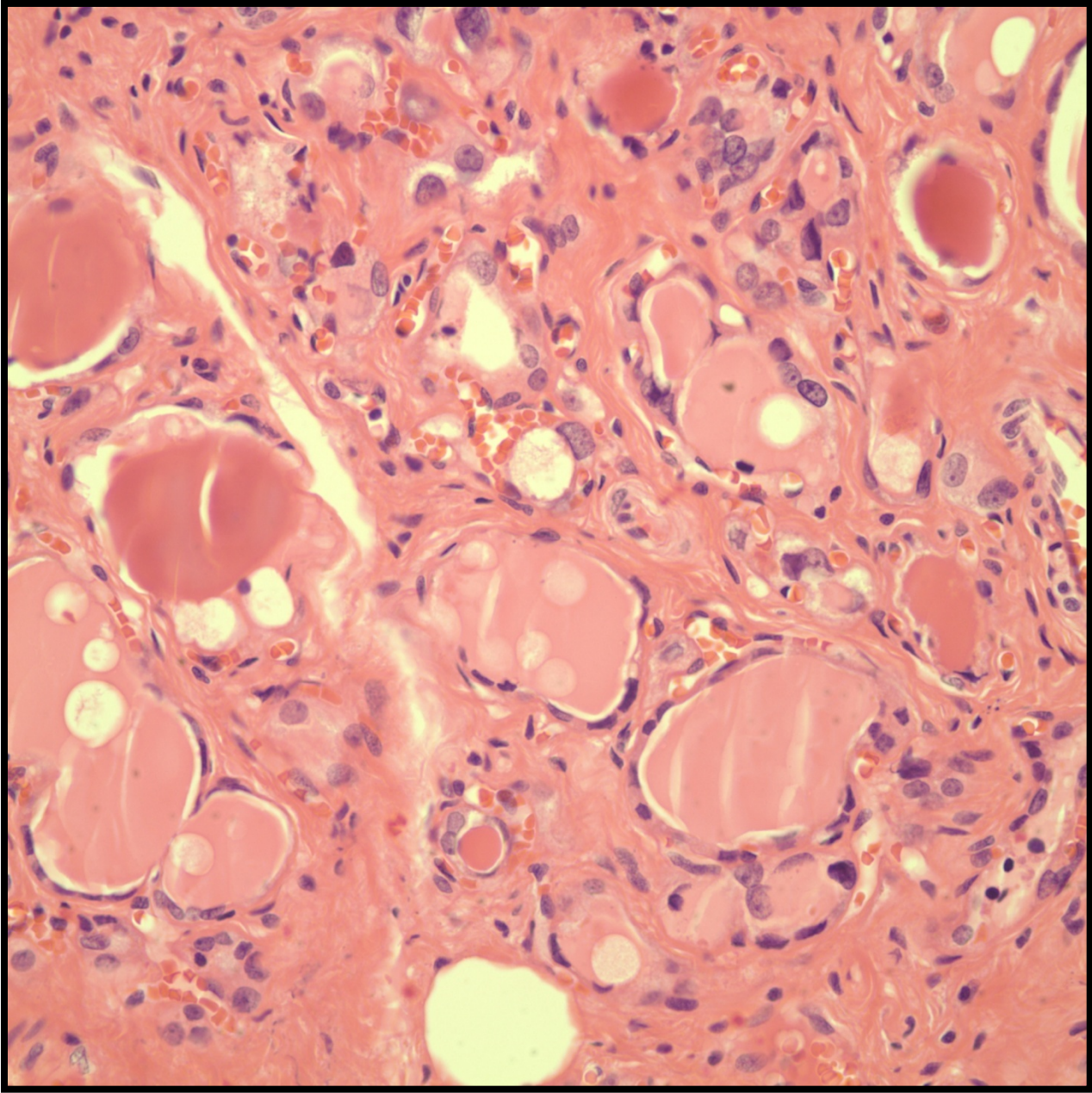






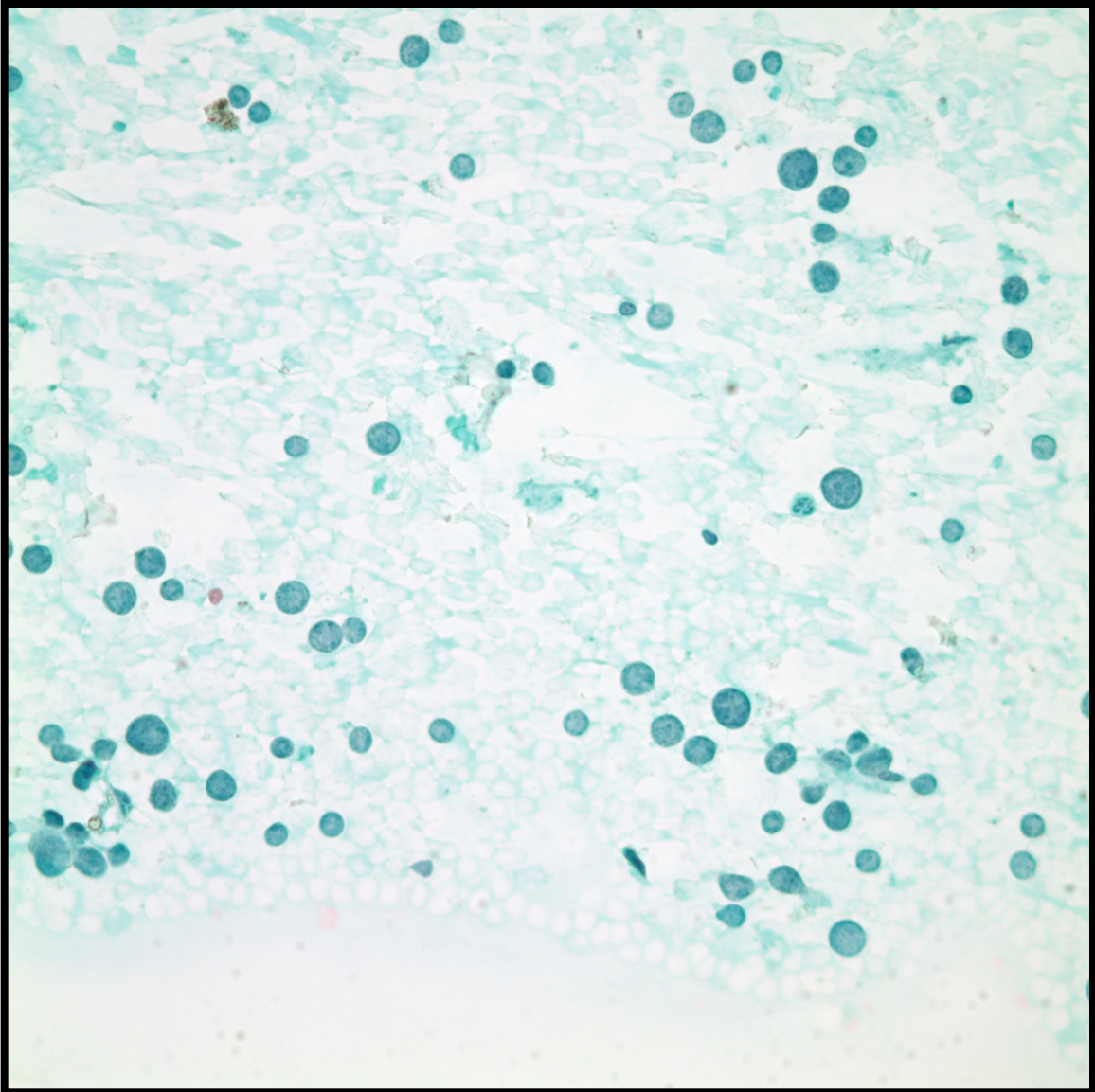


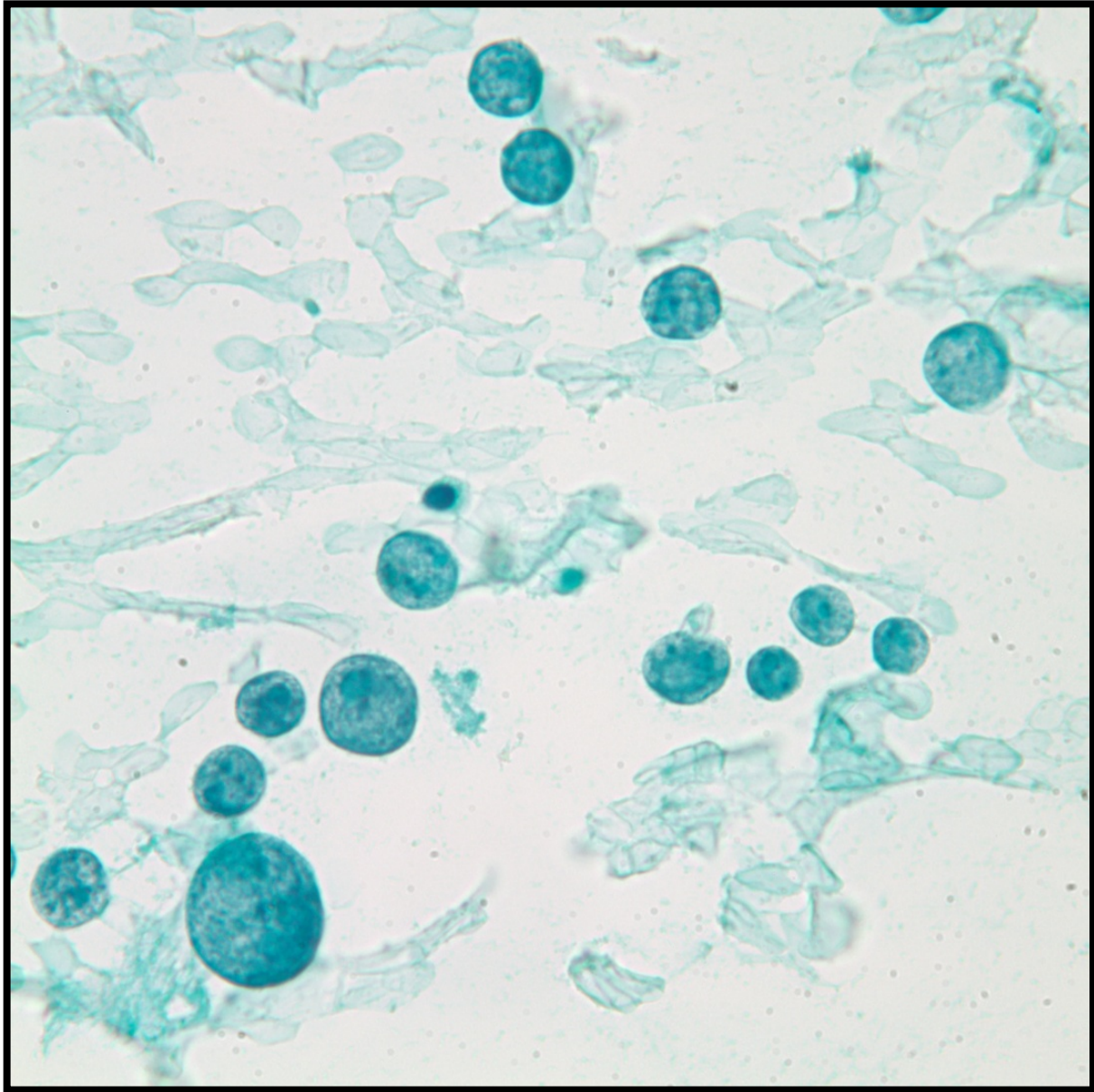


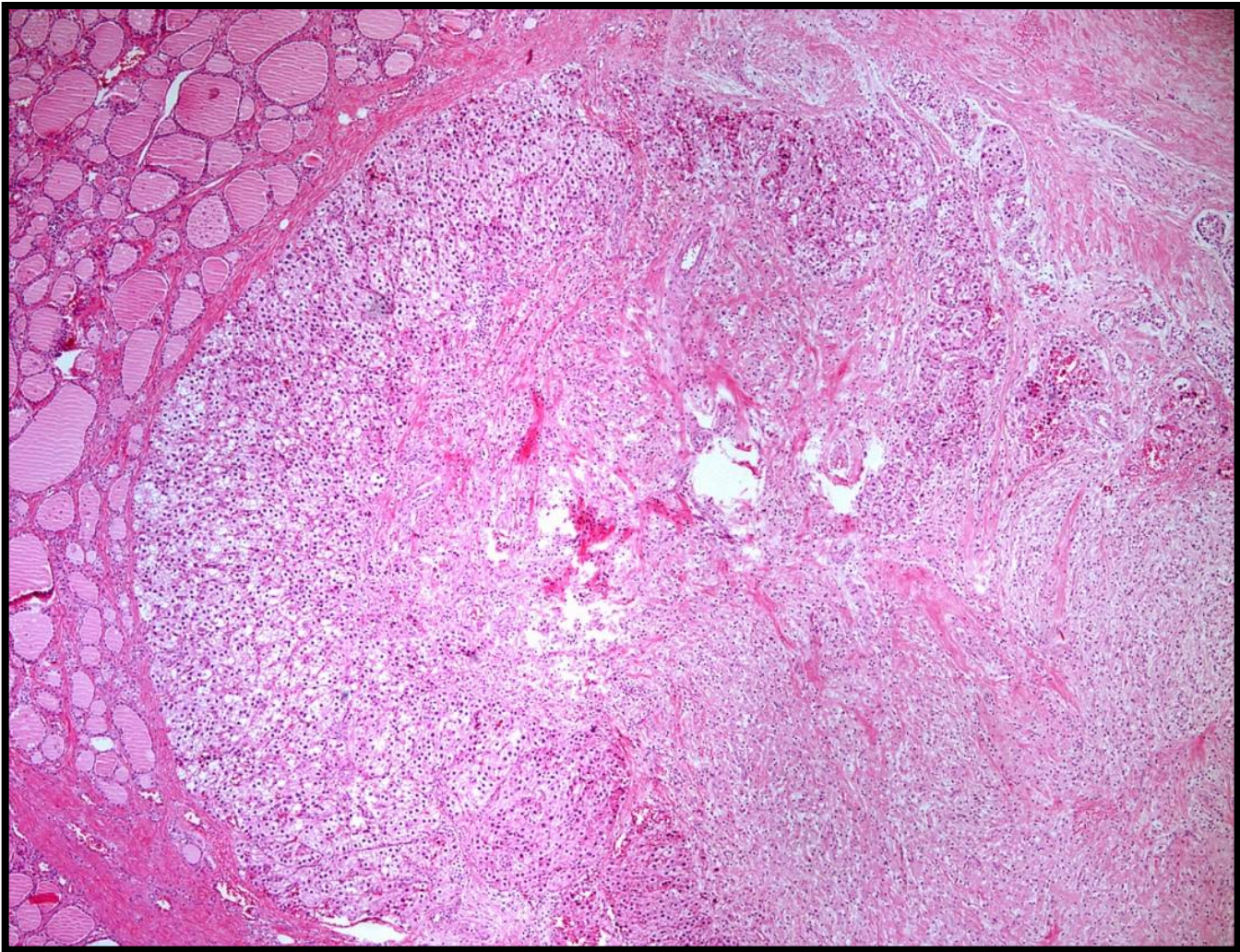


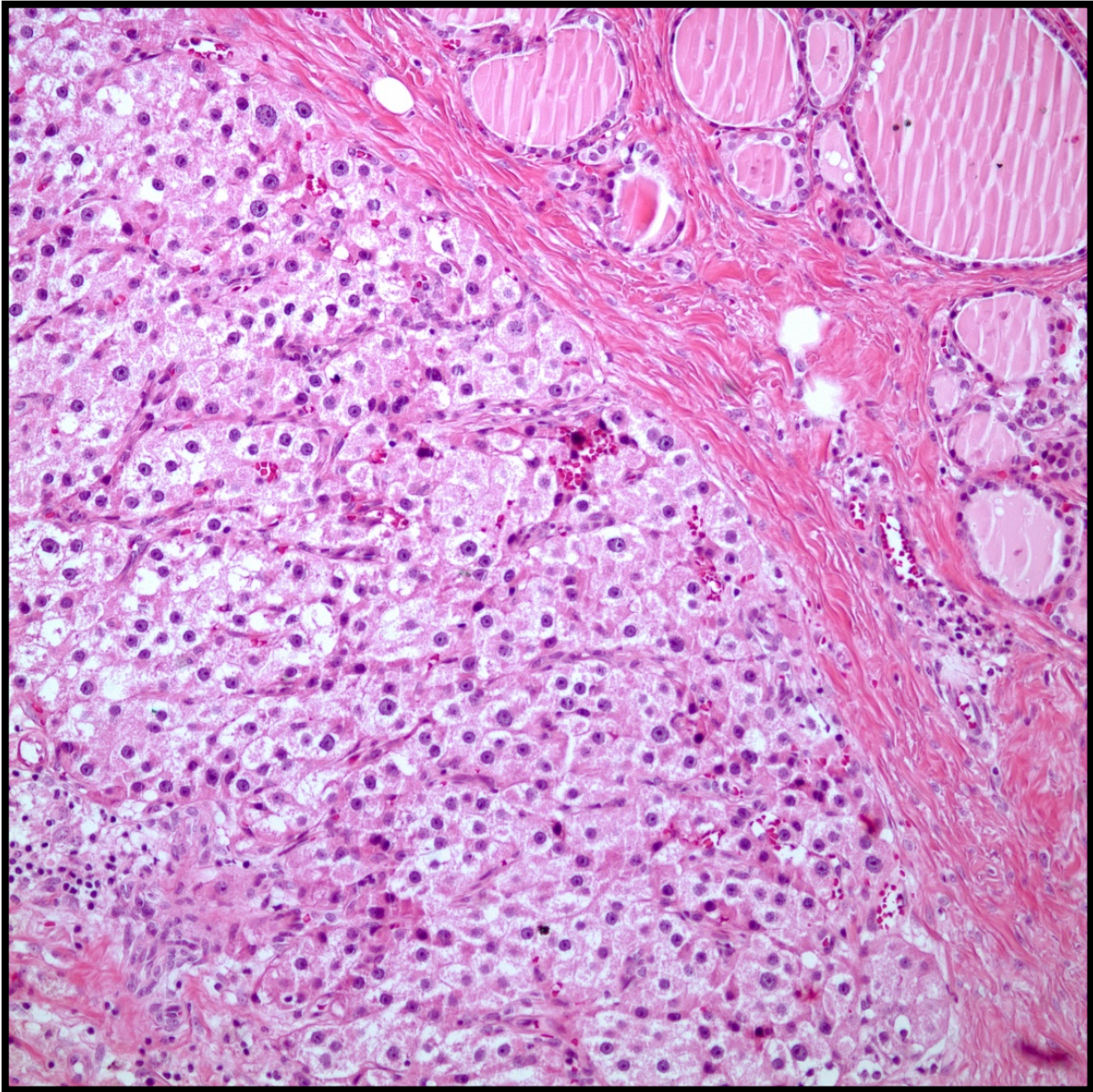
Olgu 5

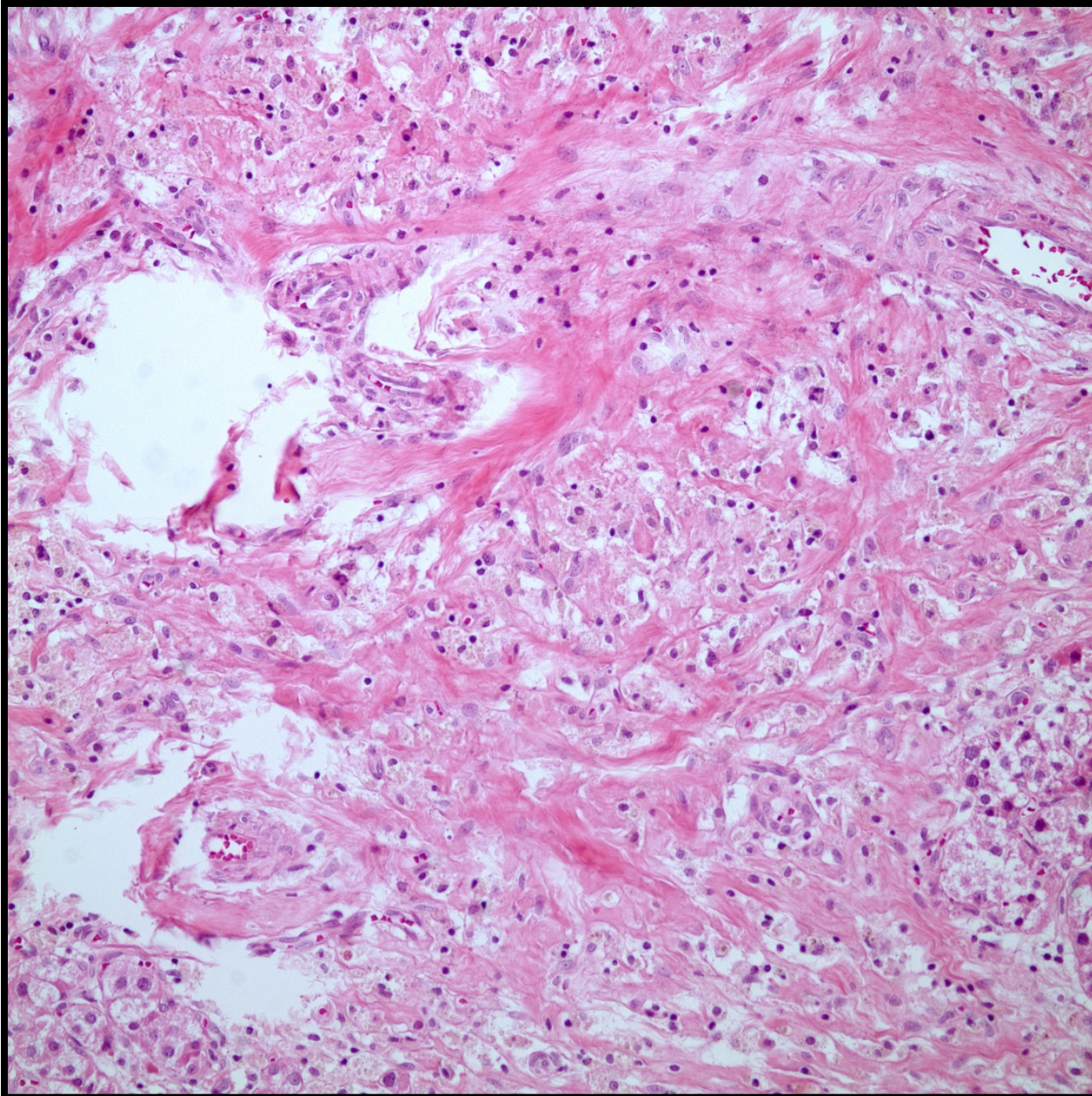
- 44 yaşında kadın hasta
- Ultrasonda sağ lobda 1 cm lik nodül
- Sitoloji: malign (metastaz veya medüller karsinom)
- Bilateral total tiroidektomi
- Makroskopi: Sağ lob kesit yüzünde 0,8 cm çapında ortası kanamalı solid nodül

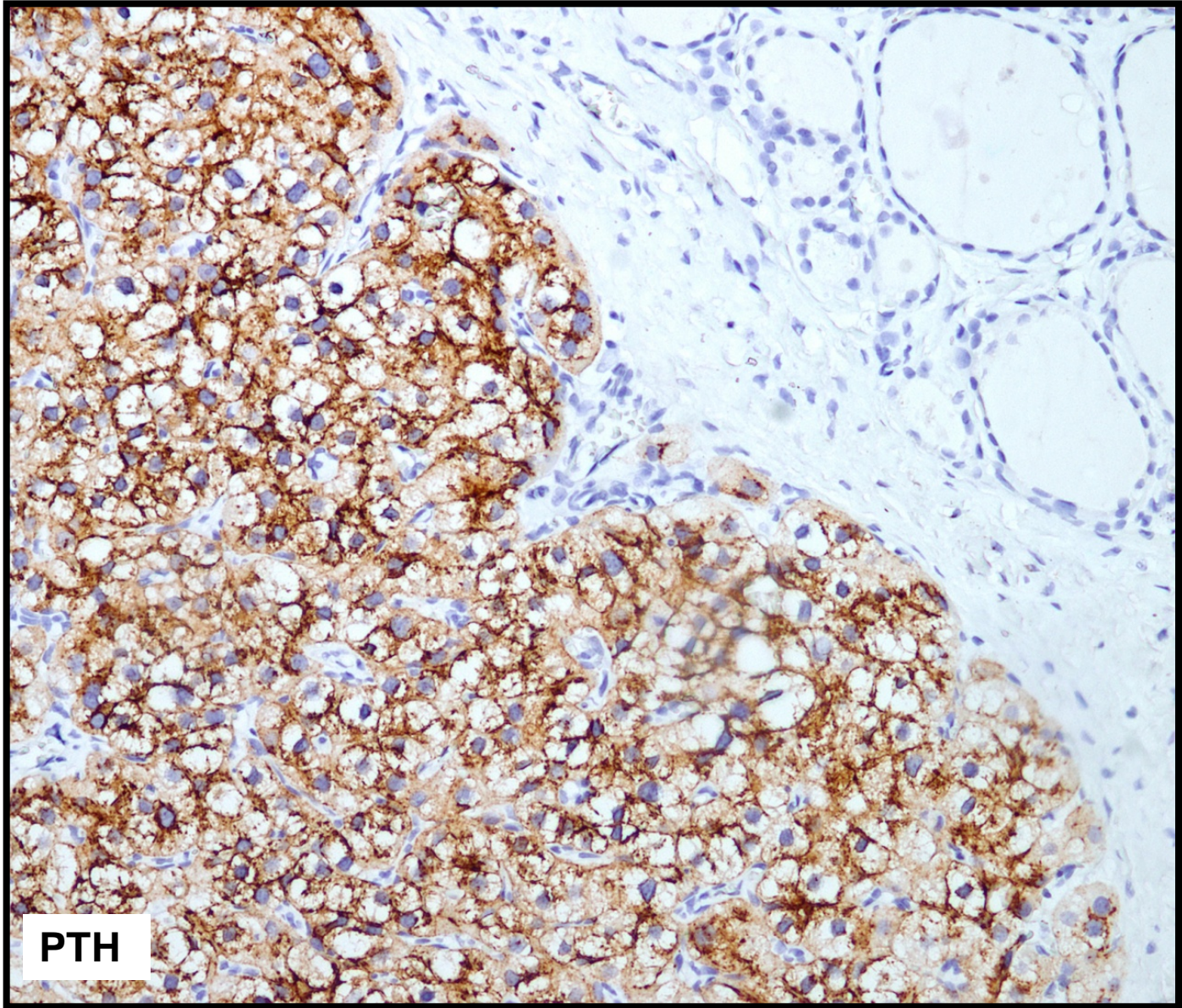








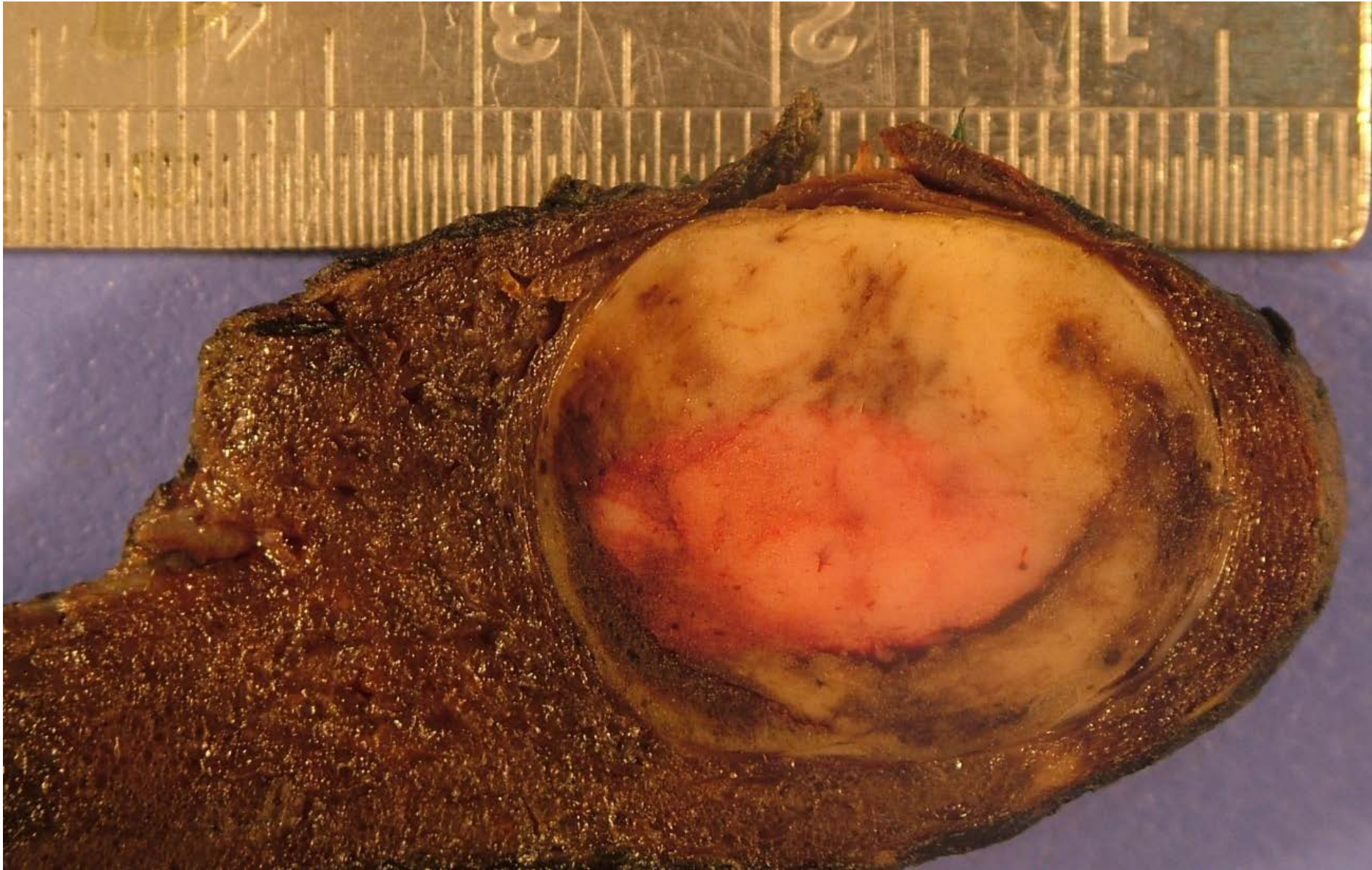


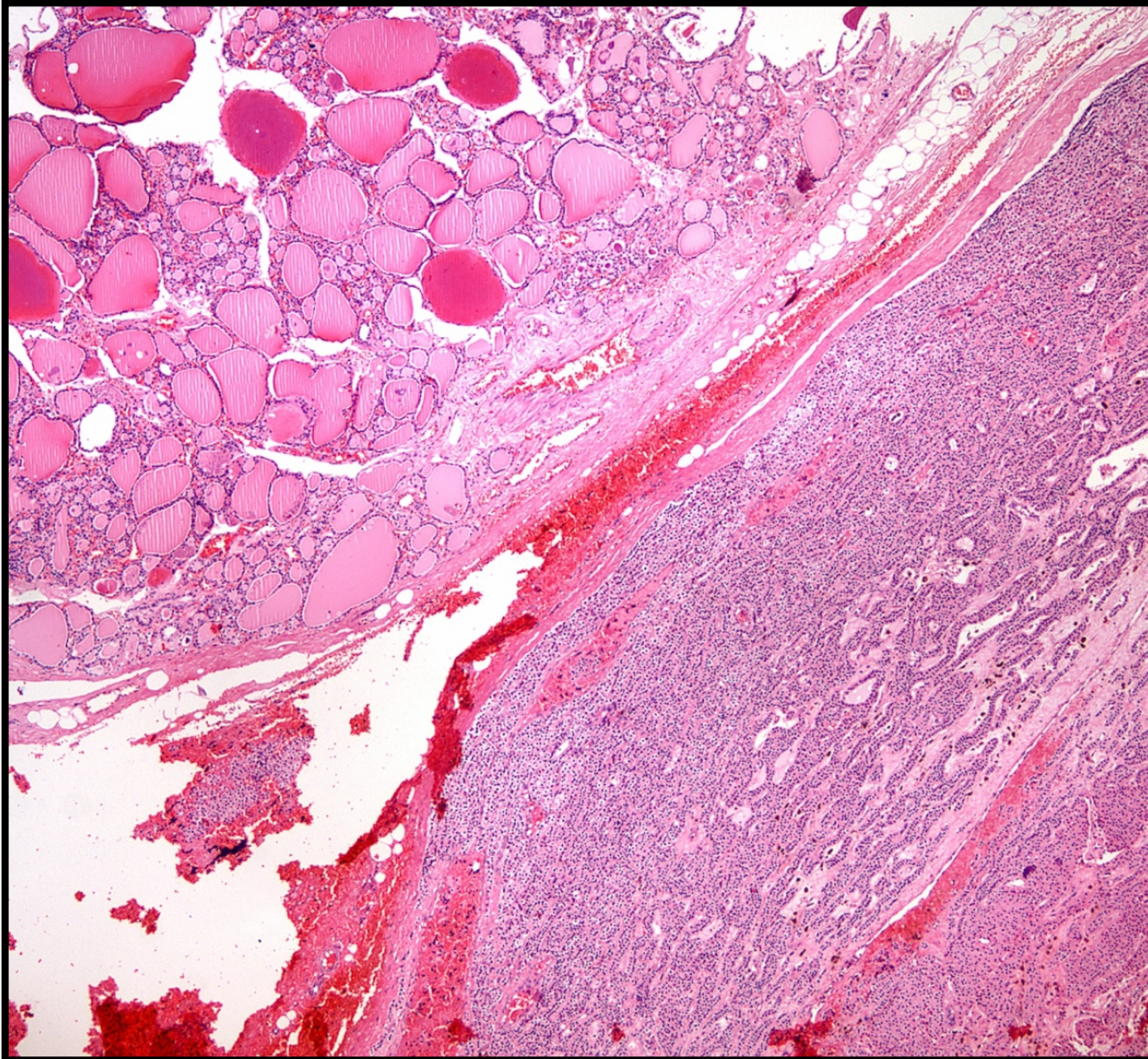


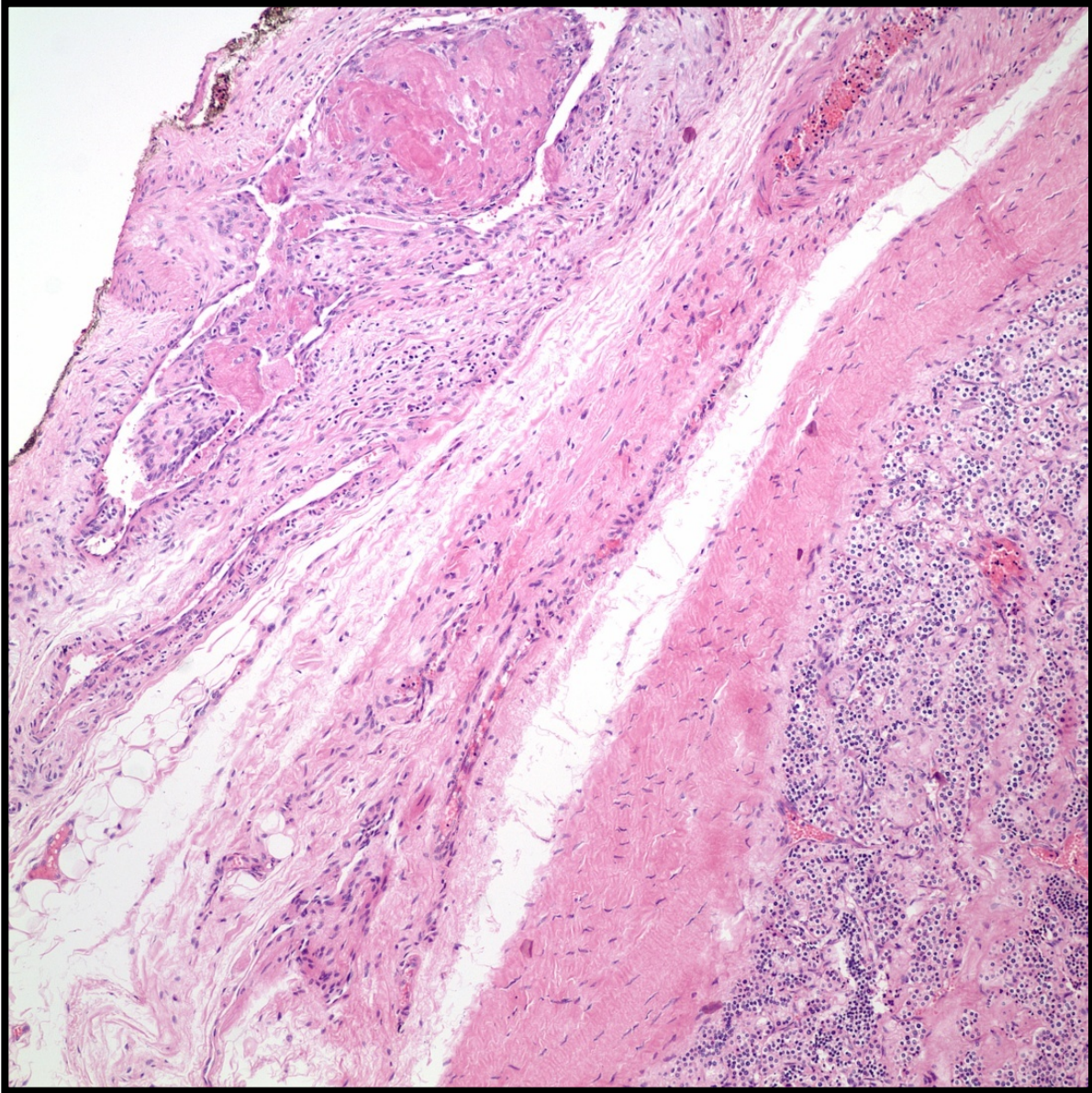
PTH

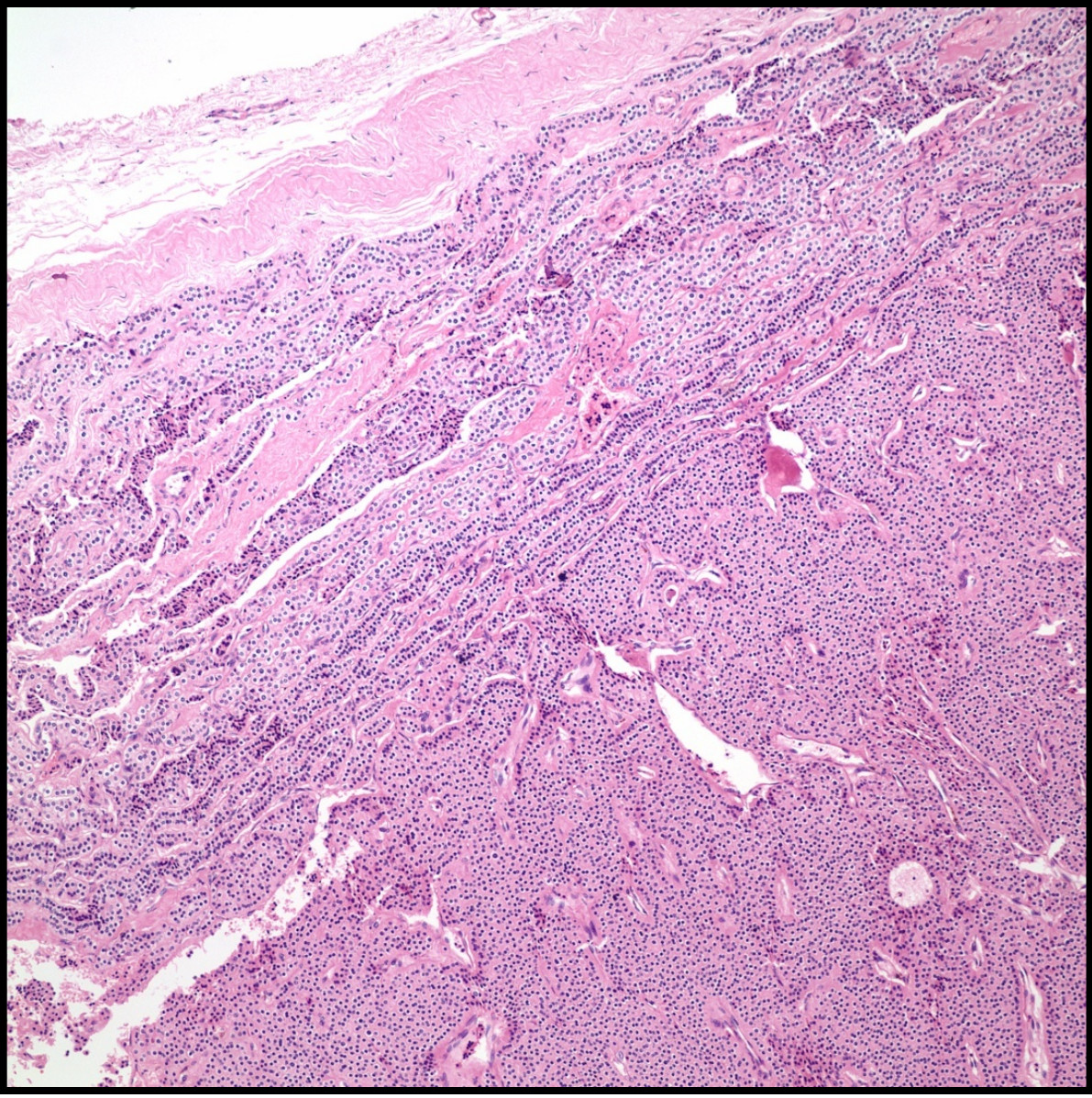
Olgu 6

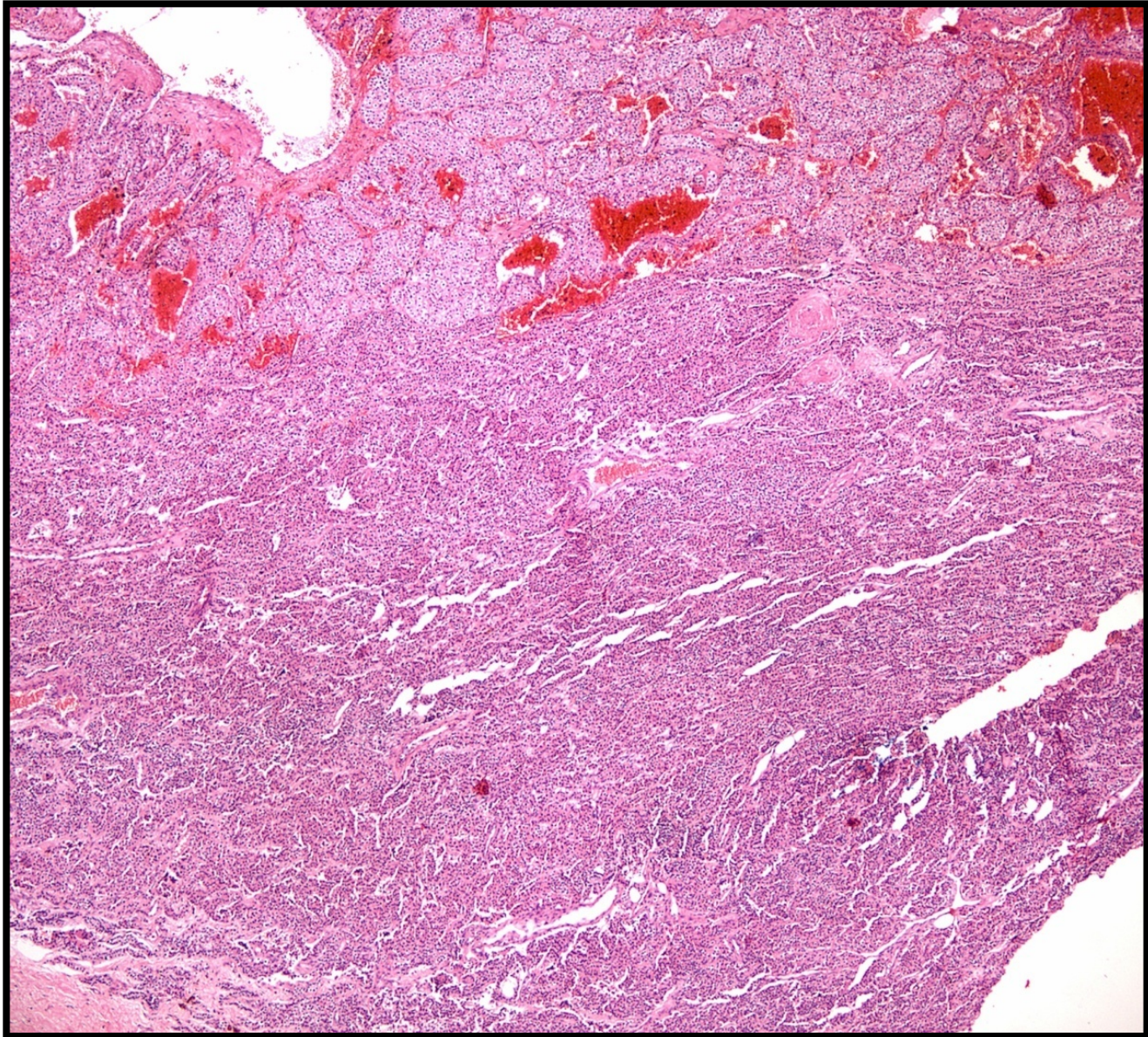
- 68 yaşında erkek hasta
- Hiperkalsemi ve yüksek PTH (1000 IU üzerinde)
- Paratiroid sintigrafisinde tiroid sol lob inferiorunda tutulum
- Ultrasonda tiroid sol lobda 4,2 cm çapında solid nodül ve sağ da 0,5 cm lik iki nodül
- İntraoperatif konsültasyonda iki adet normal sınırlarda paratiroid dokusu saptanıyor.
- Bilateral total tiroidektomi yapılarak ameliyat sonlandırılıyor.

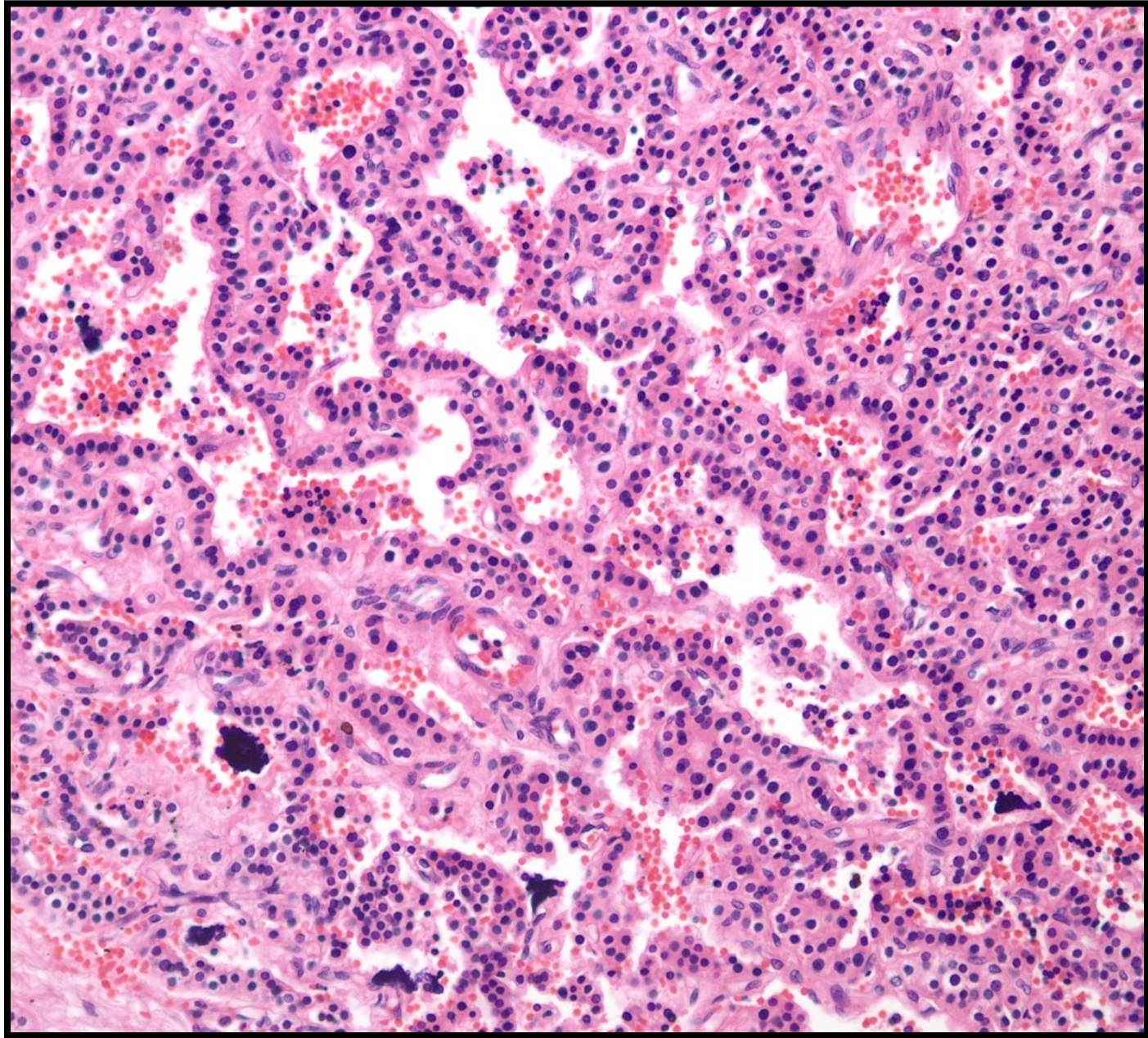


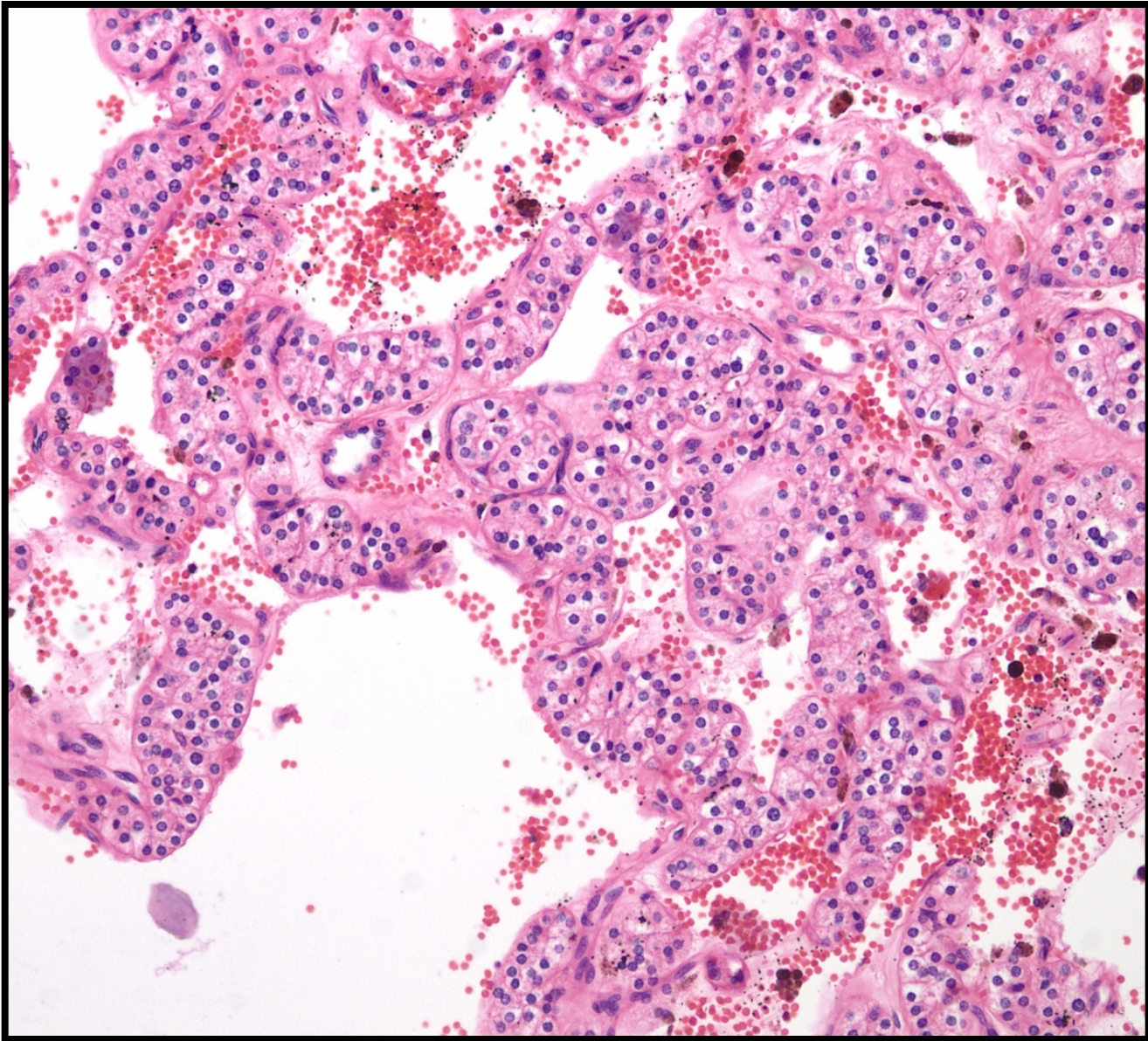


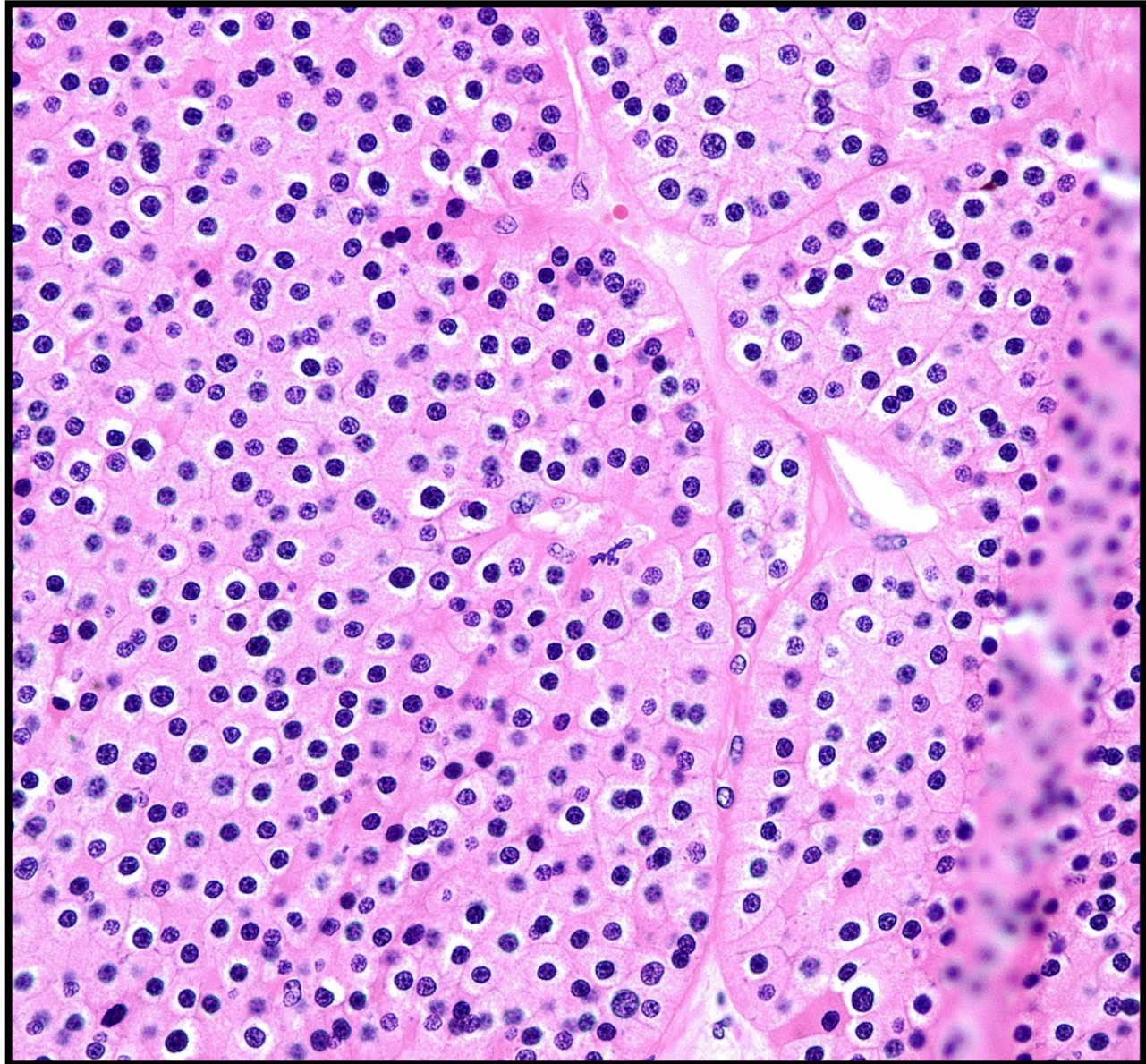


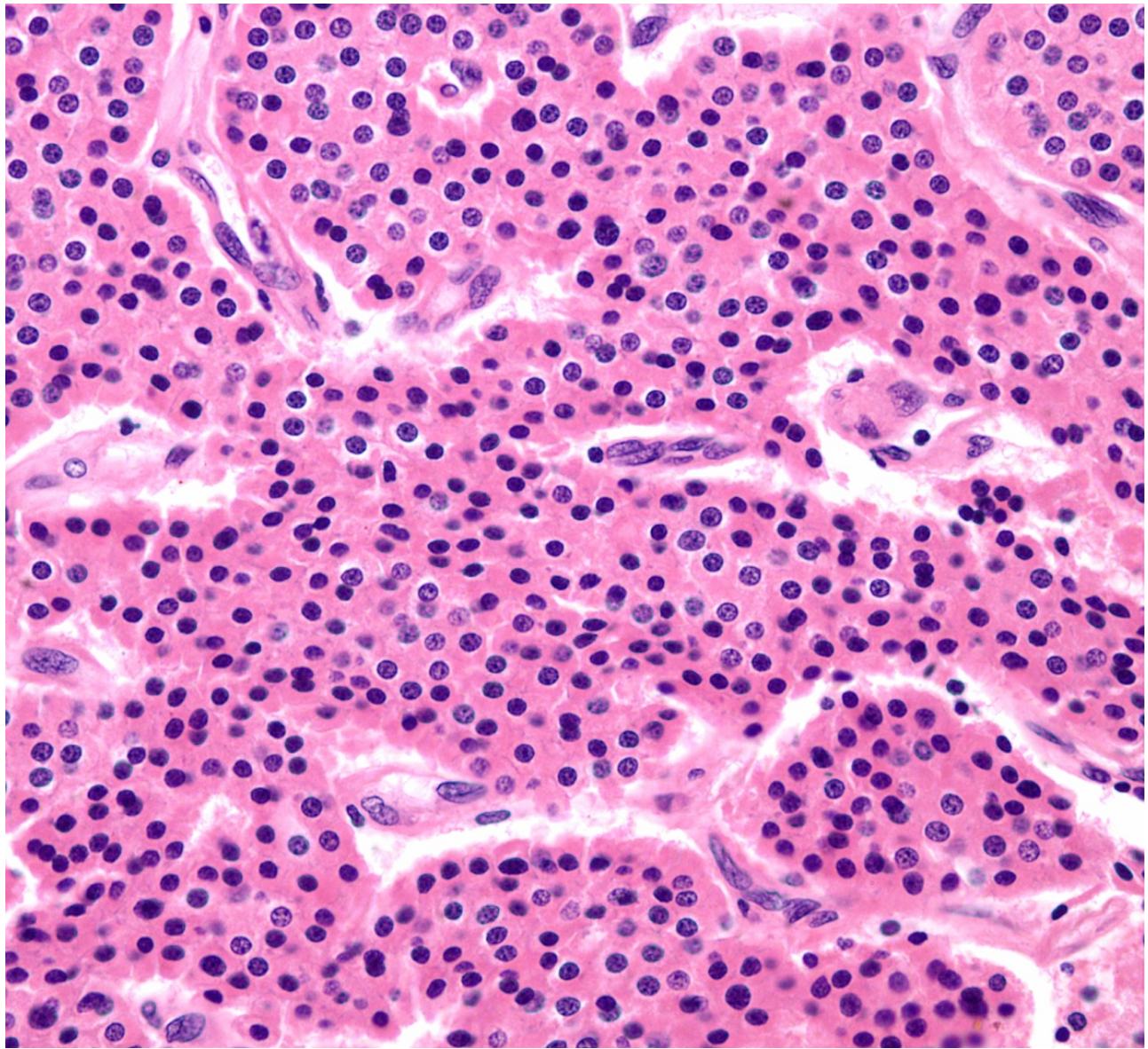


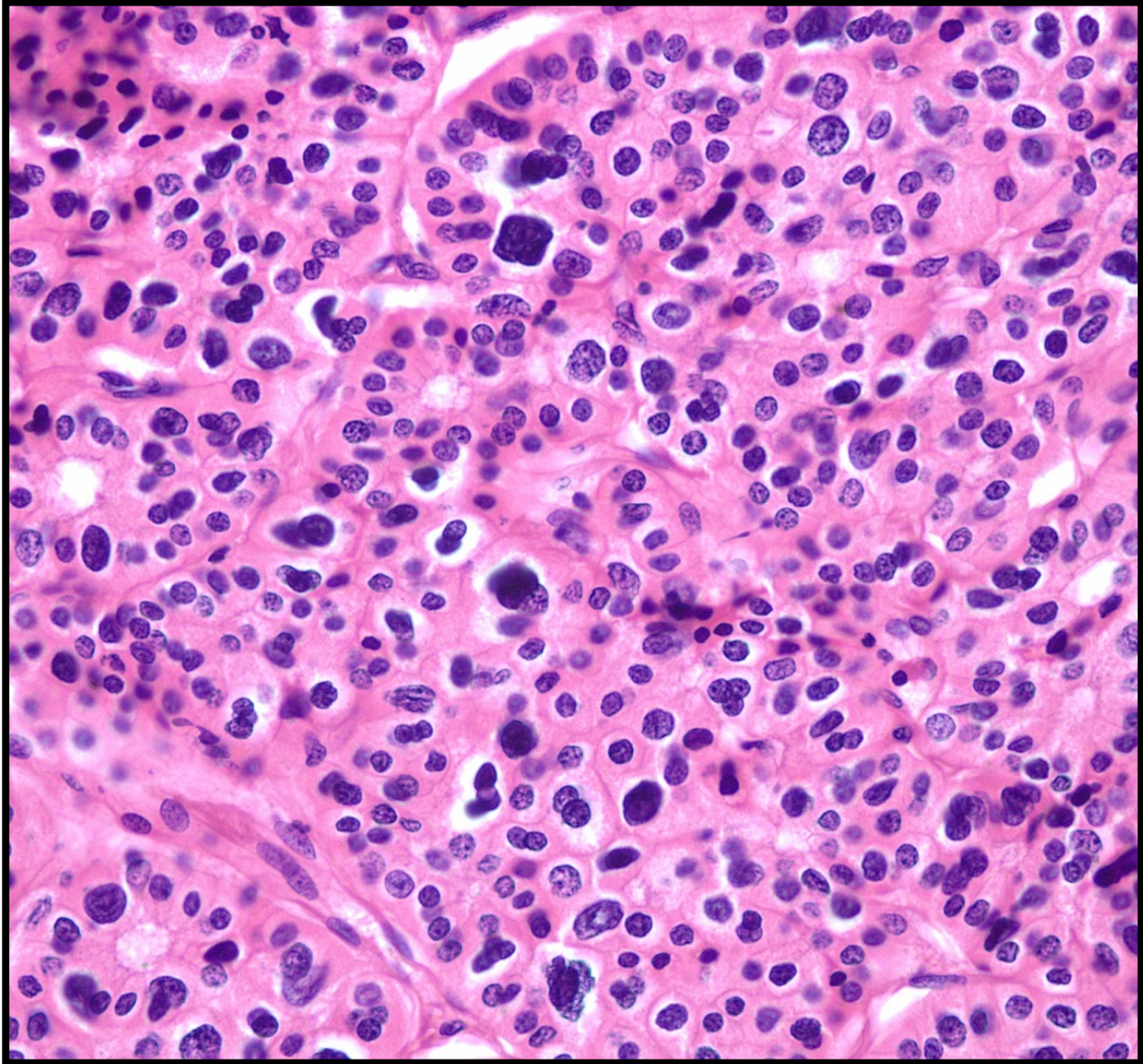


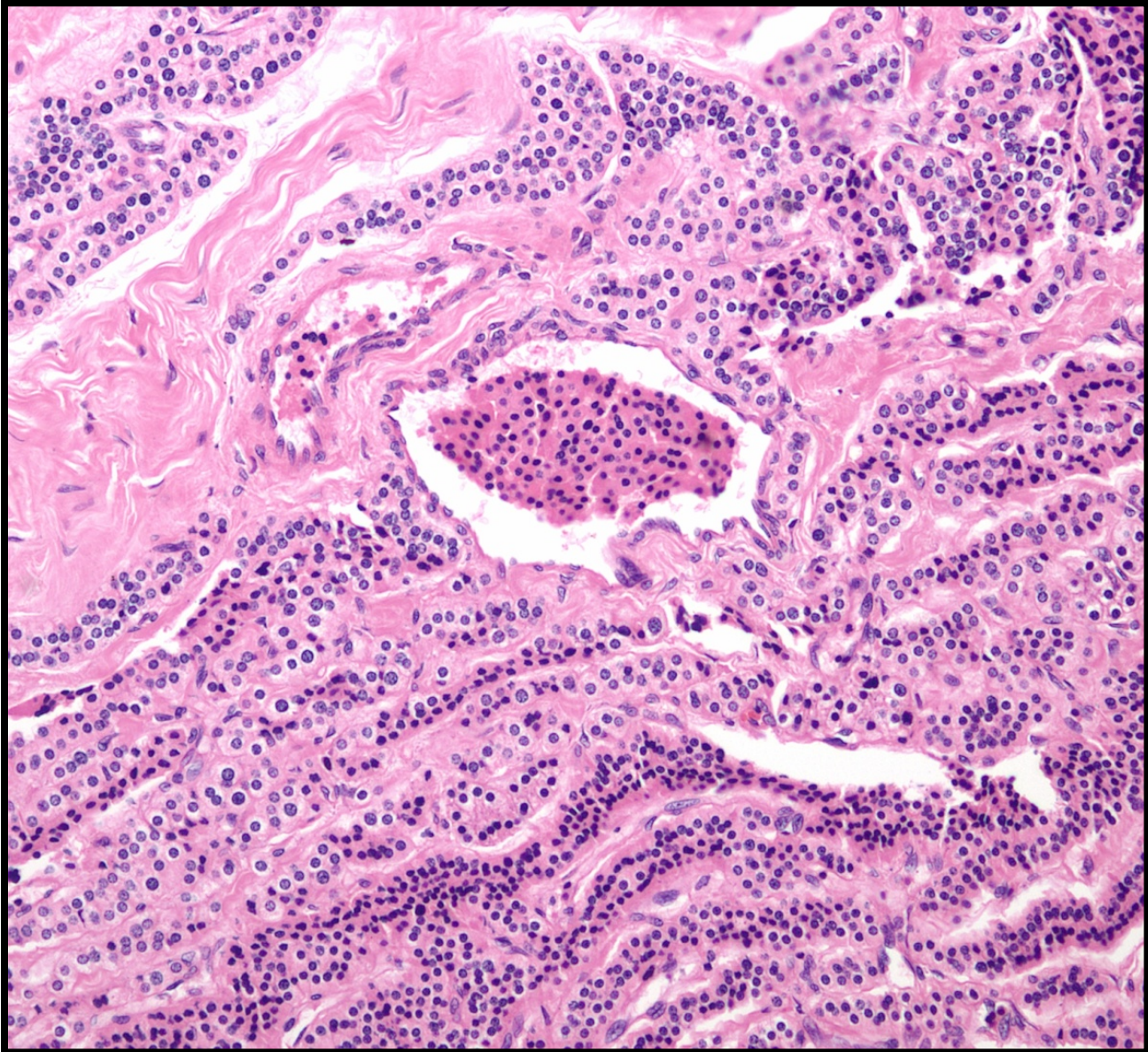


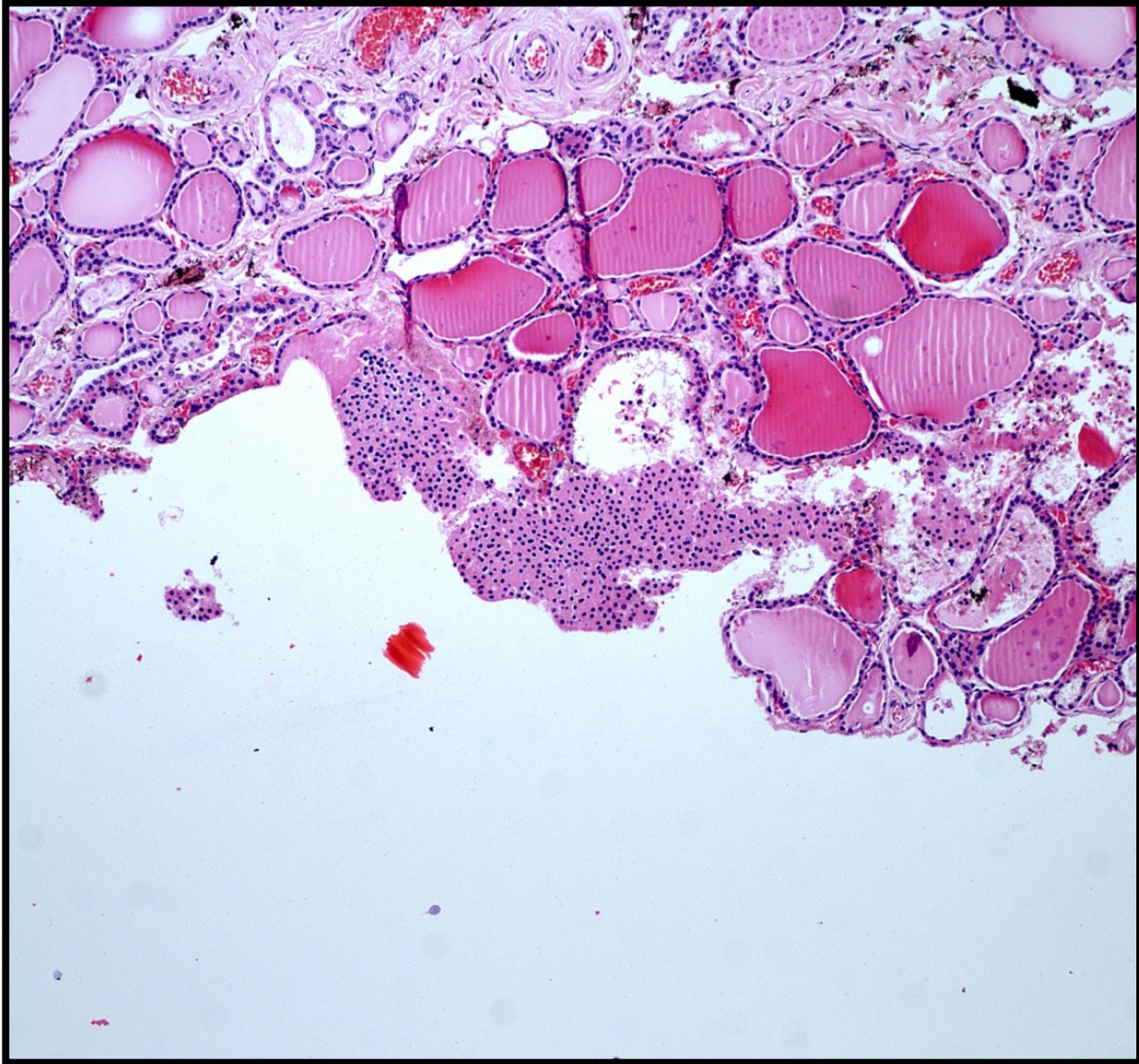


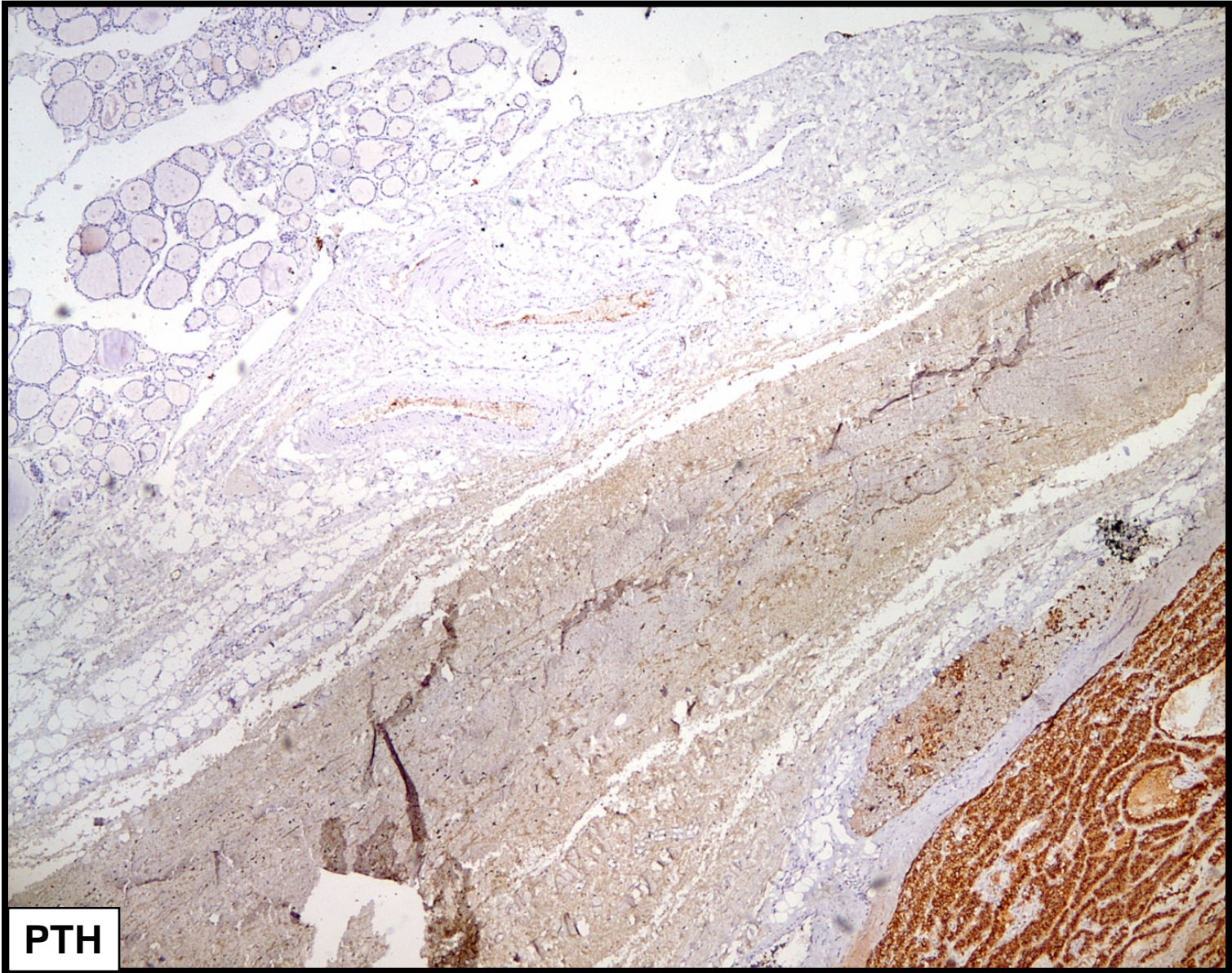




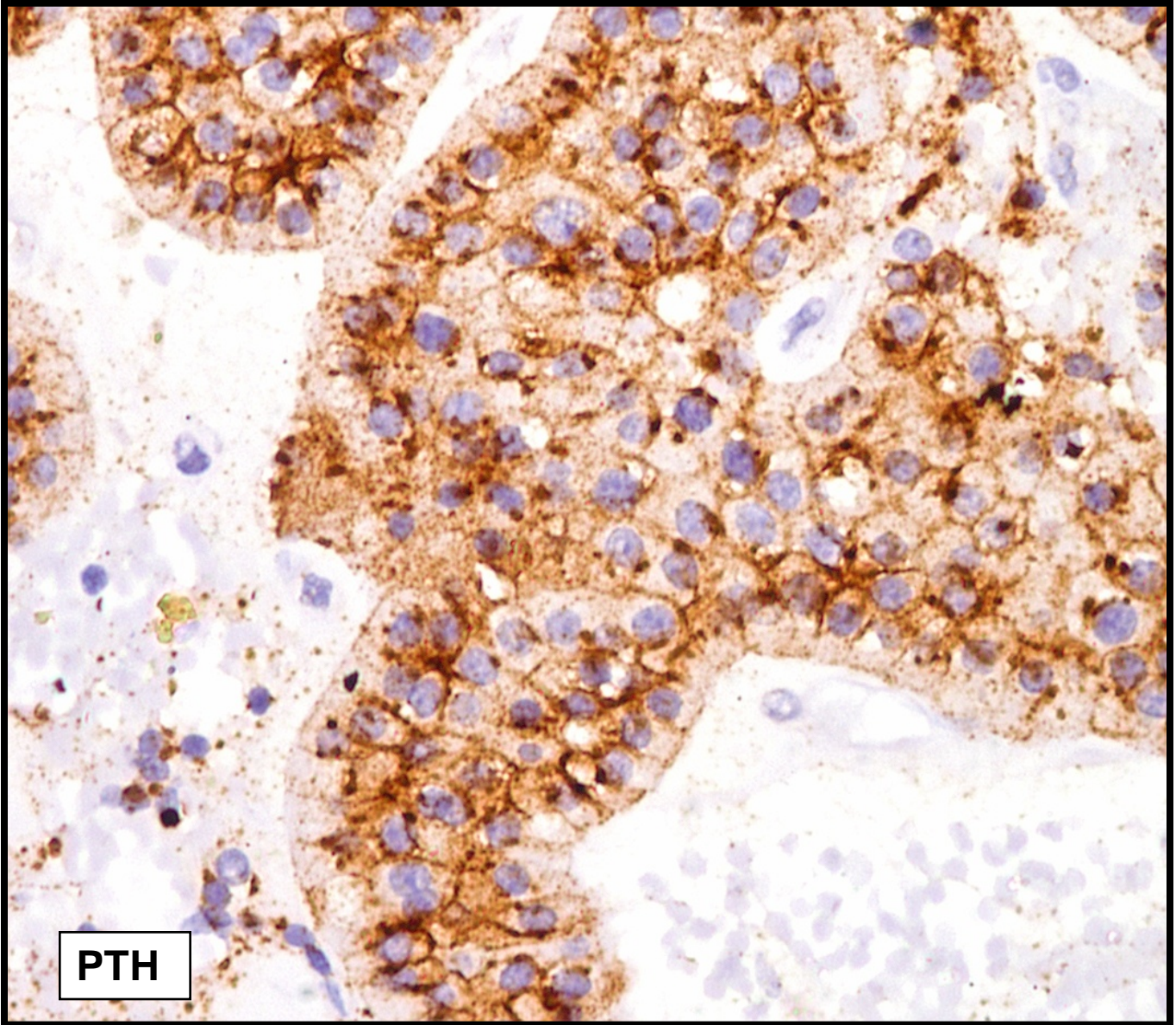




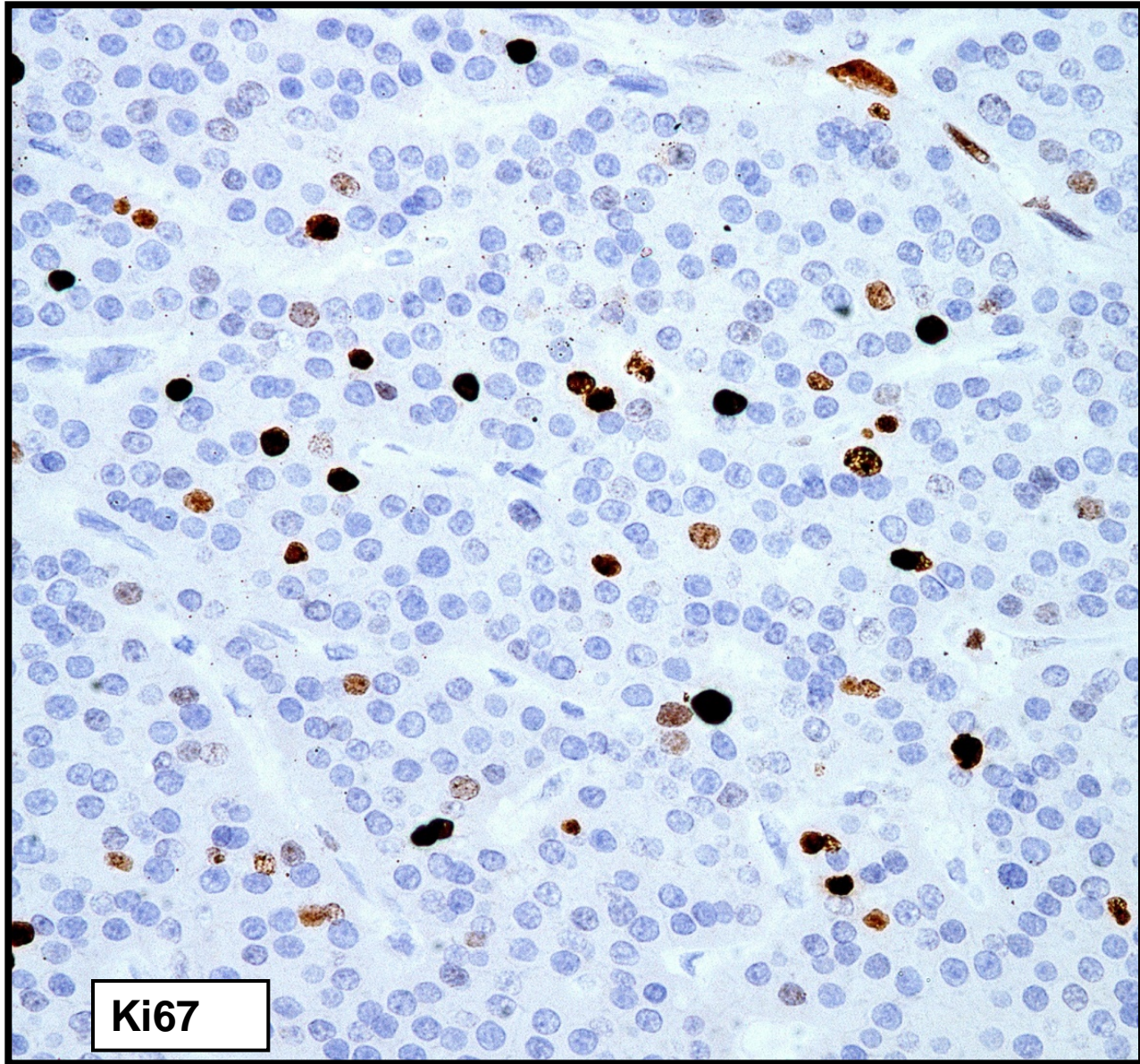




PTH



PTH



Ki67