



KAS BİYOPSİ DEĞERLENDİRMESİNDE KULLANILAN TEKNİKLER

Doç. Dr. A.Gülden Diniz



Prof.Dr.Safiye AKTAŞ



Doç.Dr.Gülden DİNİZ

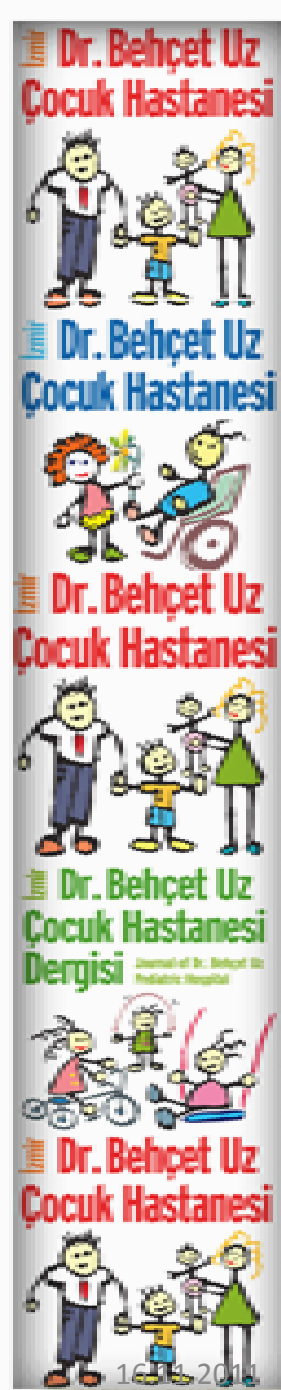


Doç.Dr.Ragıp ORTAÇ



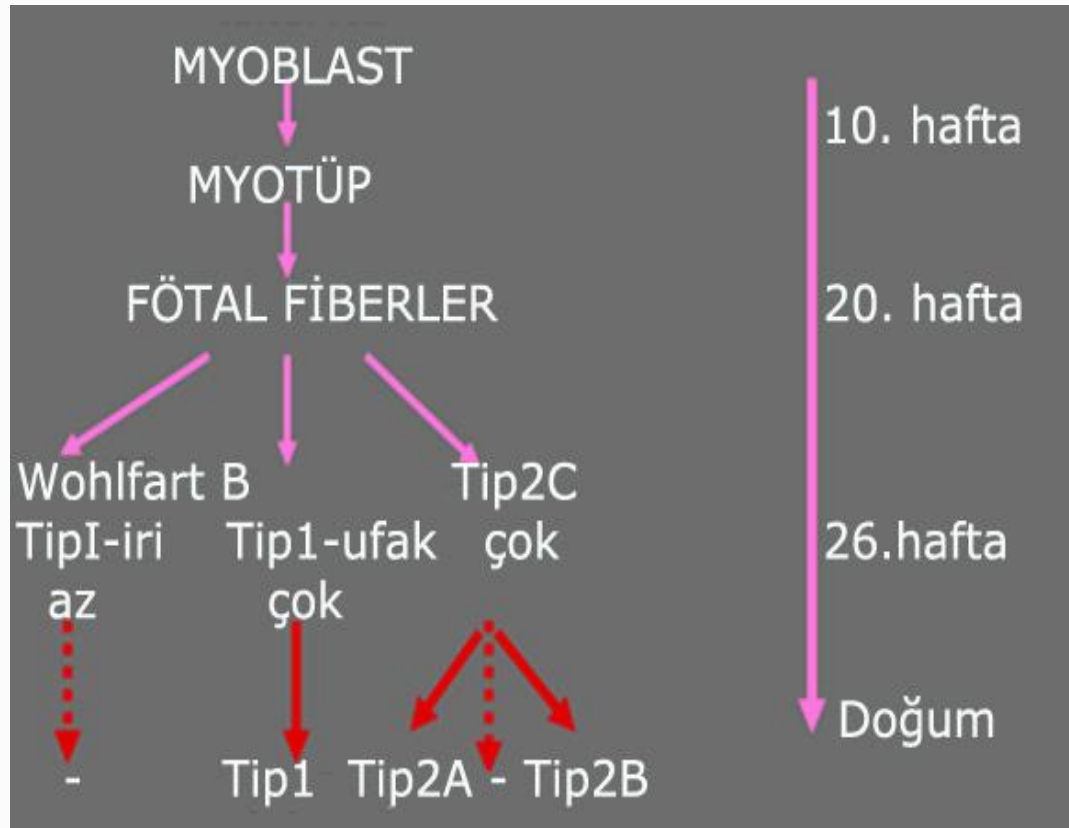
Uzm.Dr.Malik ERGİN

Dr.Behçet Uz çocuk Hastanesi
Patoloji Laboratuvarı



Embriyogenez sırasında


- Mezenkimal hücreler önce **myoblasta** döner
- Myoblastların uç uca füzyonuyla **myotüpler** oluşur.
- Kontraktil protein sentezi myoblast füzyonunu izler. **Kontraktil proteinlerin** özel dizilimi sonucunda enine çizgili, sınırlı proliferasyon yeteneği olan kas hücresi oluşur.
- **İU 20. haftadan** itibaren güçlü vimentin ve desmin ekspresyonu gösteren santral nükleuslu **fötal myofiberler** bulunur
- **26. haftadan** sonra fötal fiberler değişir. Çoğu tip 2C, geri kalanlar ise tip 1 küçük boyutlu fiberler haline gelir
- Wohlfart B denilen tip 1 iri fiberler nadirdir.
- **Doğumdan sonra** yok olurlar



- Çizgili kaslar **periferal nükleuslu** olup, kası en dışta **epimisyum** sarar ve tendon olarak devam eder
- Kas hücresinin zarı **sarkolemmadır**
- Kontraktil proteinler özel düzenlenimle **sarkomer** denen ve sarkoplazmanın büyük bölümünü kaplayan kontraktil üniteler oluşturur
- **Z bantlarının temel proteini** alfa aktinin, ince bantların **aktin**, kalın olanların temel proteini ise **myozindir**
- İntermyofibriler alanda mitokondriler, lipit, glikojen, T-tubulleri ve sarkoplazmik retikulum bulunur.

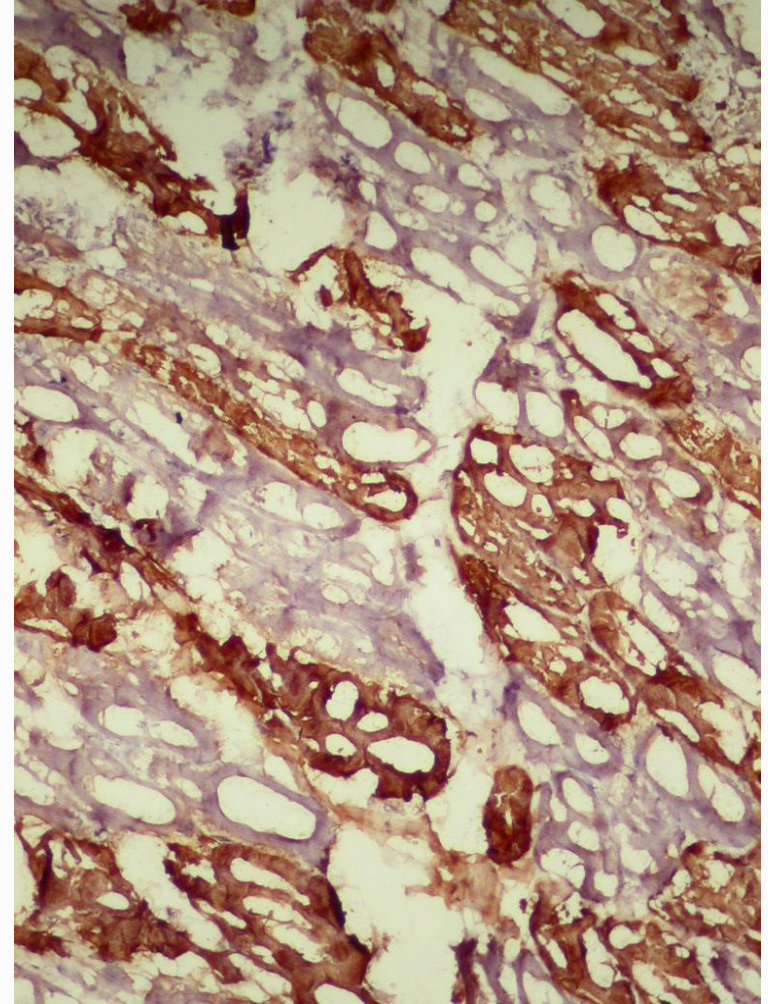
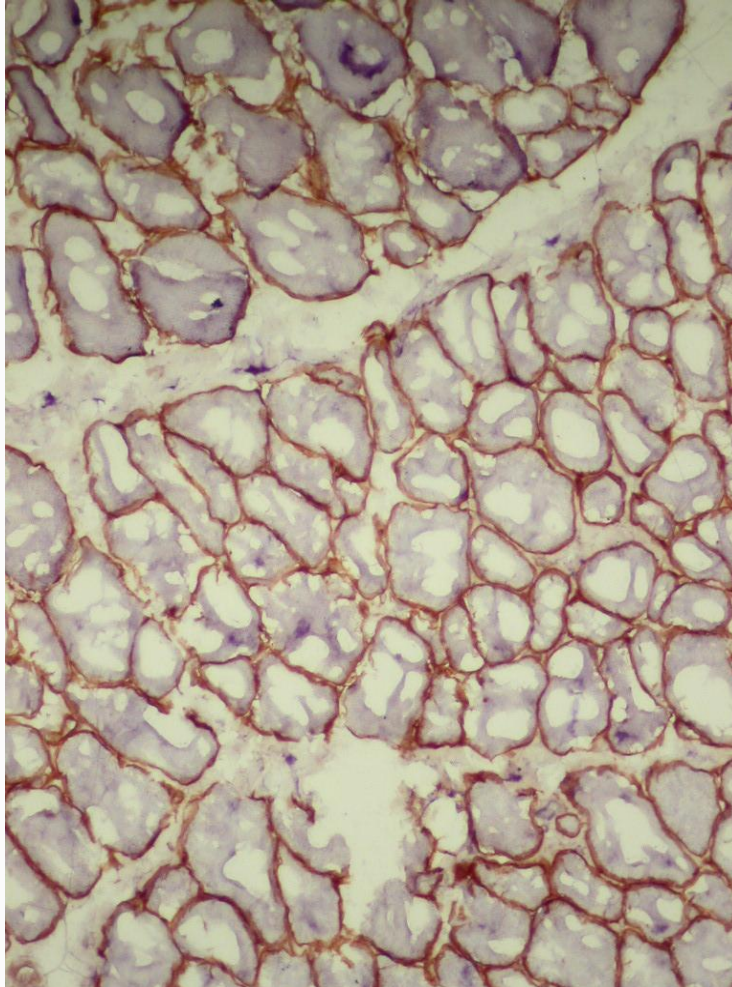
T tubulleri yüzeyde oluşan elektrik sinyallerini kontraktil üniteye iletir

Sarkoplazmik retikulum kasılma için gereken kalsiyumun depolanması ve salınımından sorumludur.



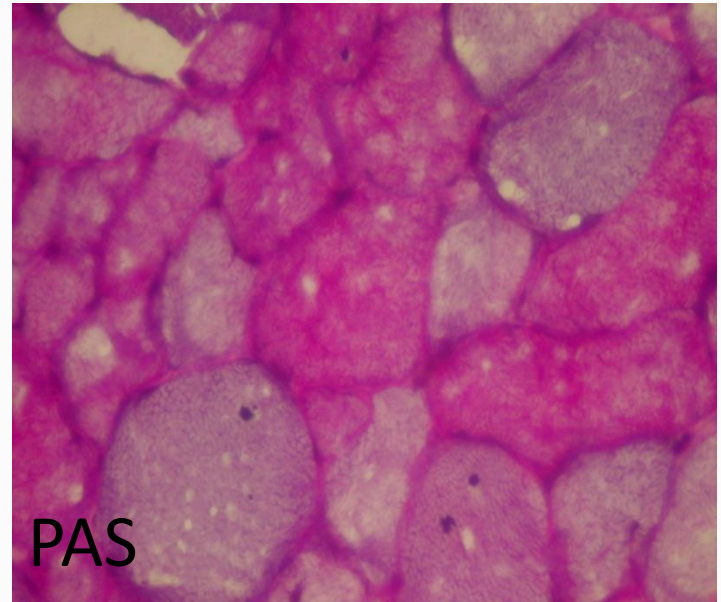
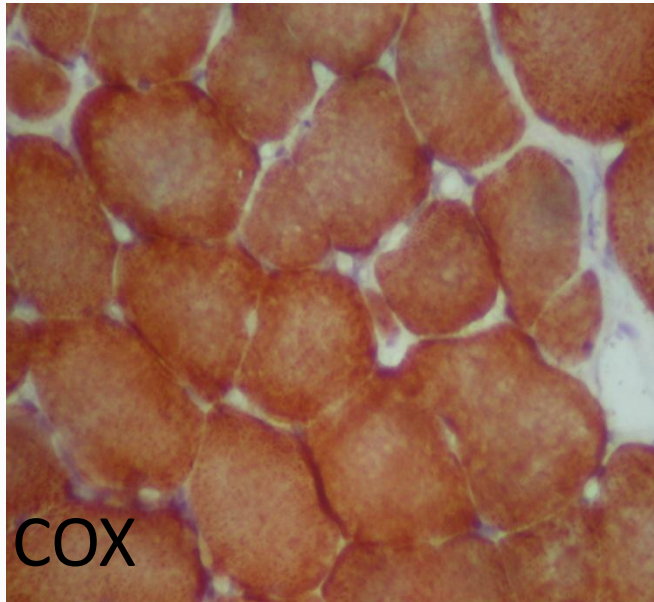
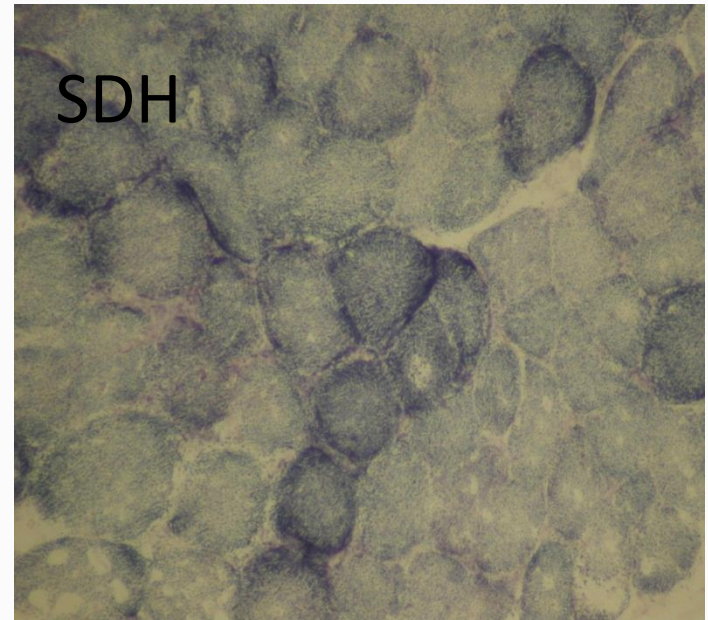
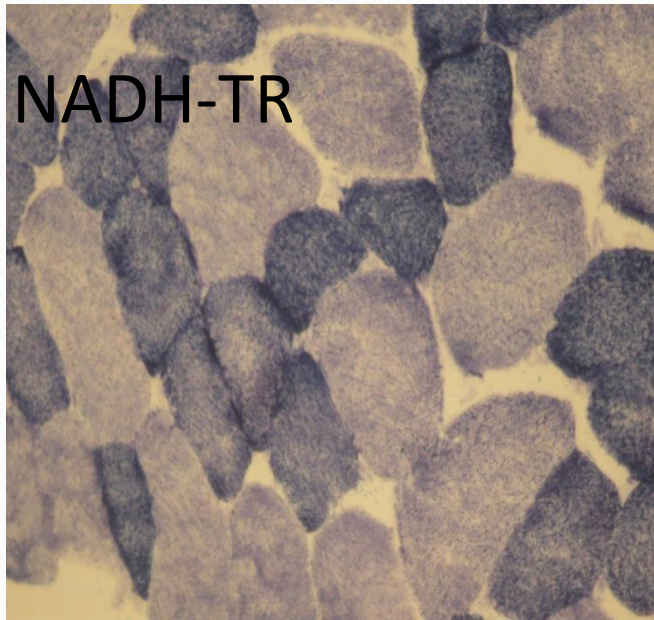


Sıvı nitrojende dondurulmamış kas biyopsisinde distrofin ve fast myozin İHK'sal boyamalarında oluşan donma artefaktları

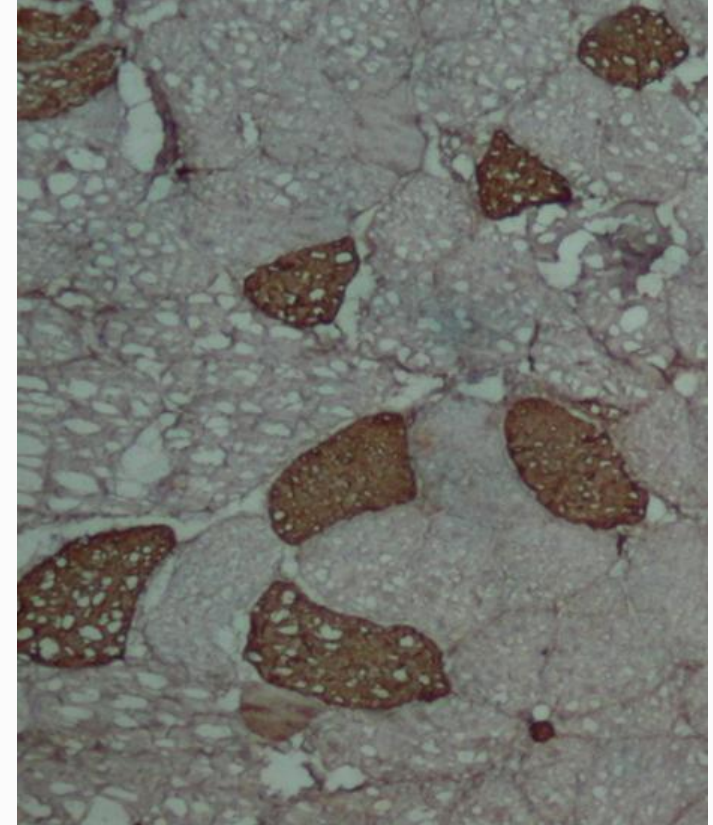
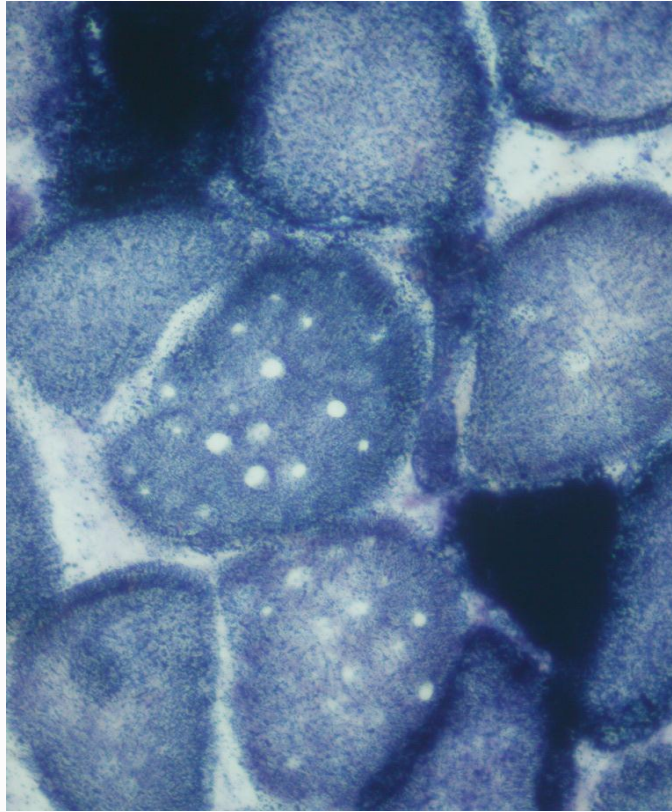


Tip1 ve tip 2 myofiber özellikleri

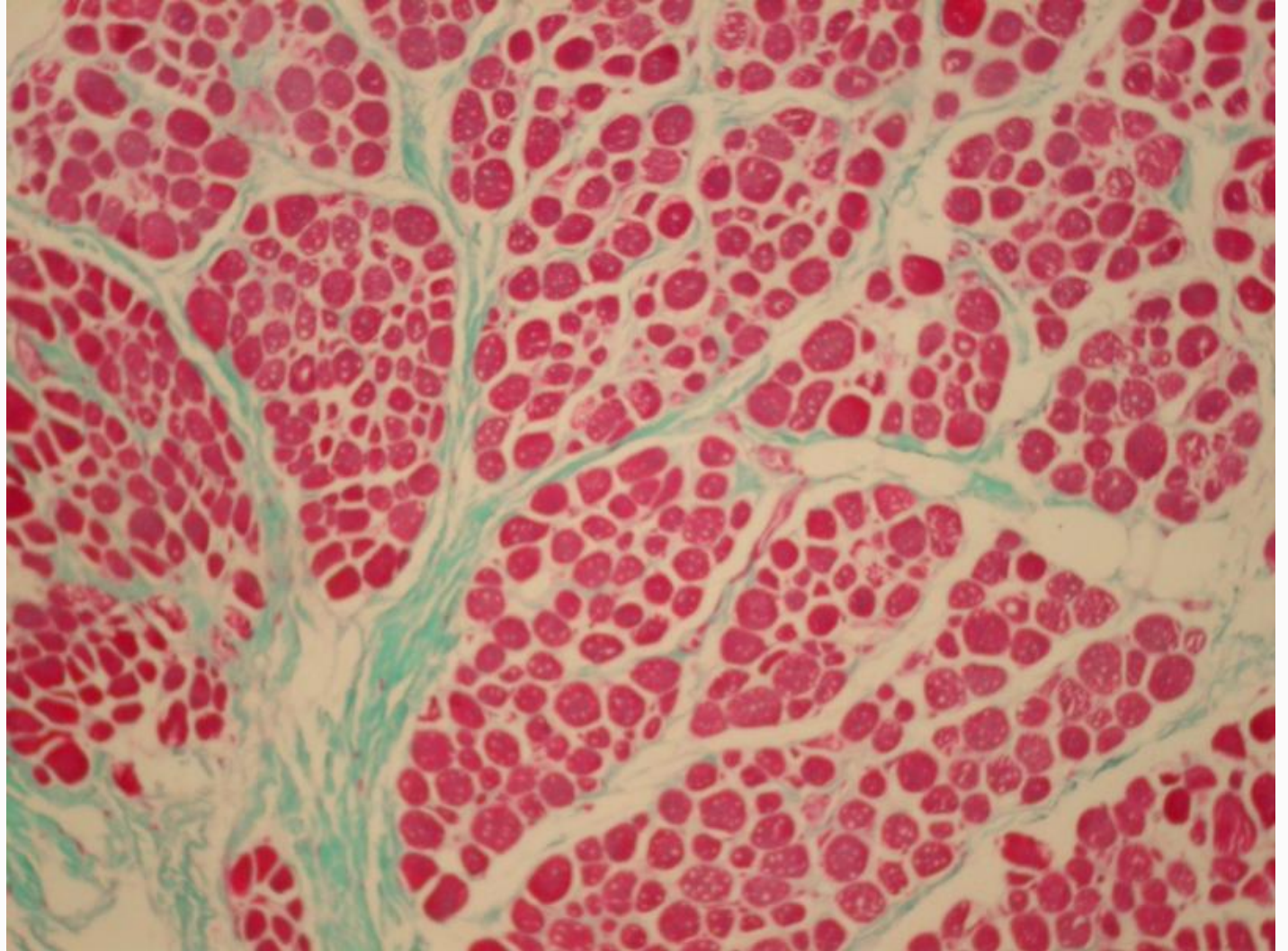
MYOFİBRİL TİPİ	TİP 1	TİP 2
ORANI	1/3	2/3
RENK	KIRMIZI	BEYAZ
MYOGLOBÜLİN VE KAPİLLER ORANI	YÜKSEK	DÜŞÜK
ATPaz (Alkalen), Fast myozin	DÜŞÜK	YÜKSEK
ATPaz (Asit), Slow myozin	YÜKSEK	DÜŞÜK
NADH-TR, SDH, COX	YÜKSEK	DÜŞÜK
Glikojen ve fosforilaz aktivitesi	DÜŞÜK	YÜKSEK
LİPİT	YÜKSEK	DÜŞÜK

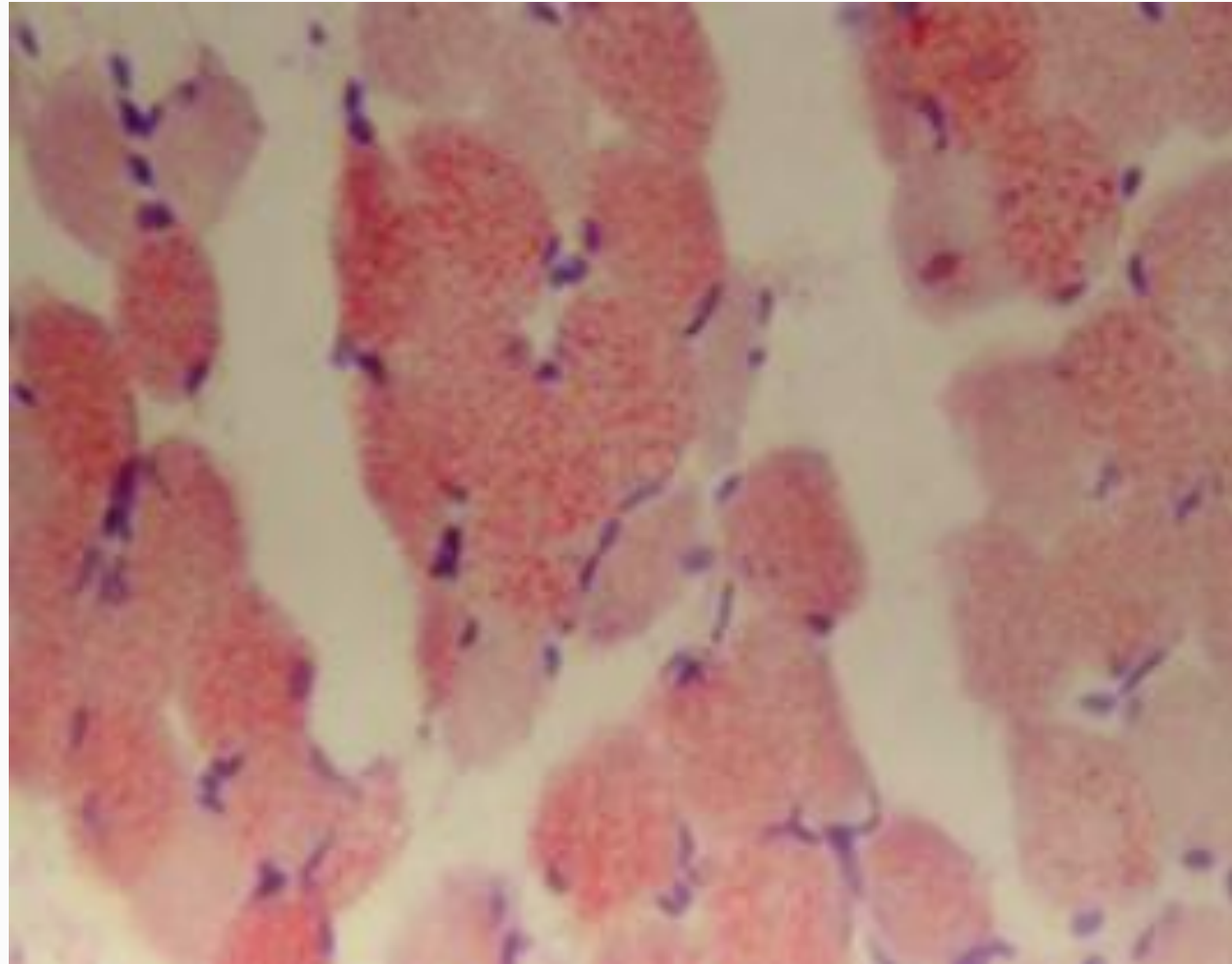
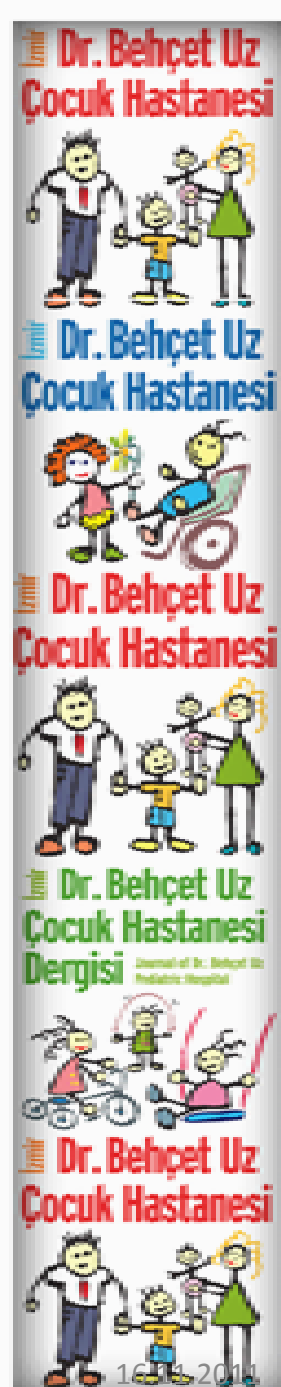

- Gözlenen vakuollerin çoğu artefaksiyeldir. Eğer örnek serum fizyolojik içinde gönderilmişse T tubullerinin şişmesi sonucu minik vakuoller izlenebilir ve mini- multikor hastalıklarıyla karışabilir.



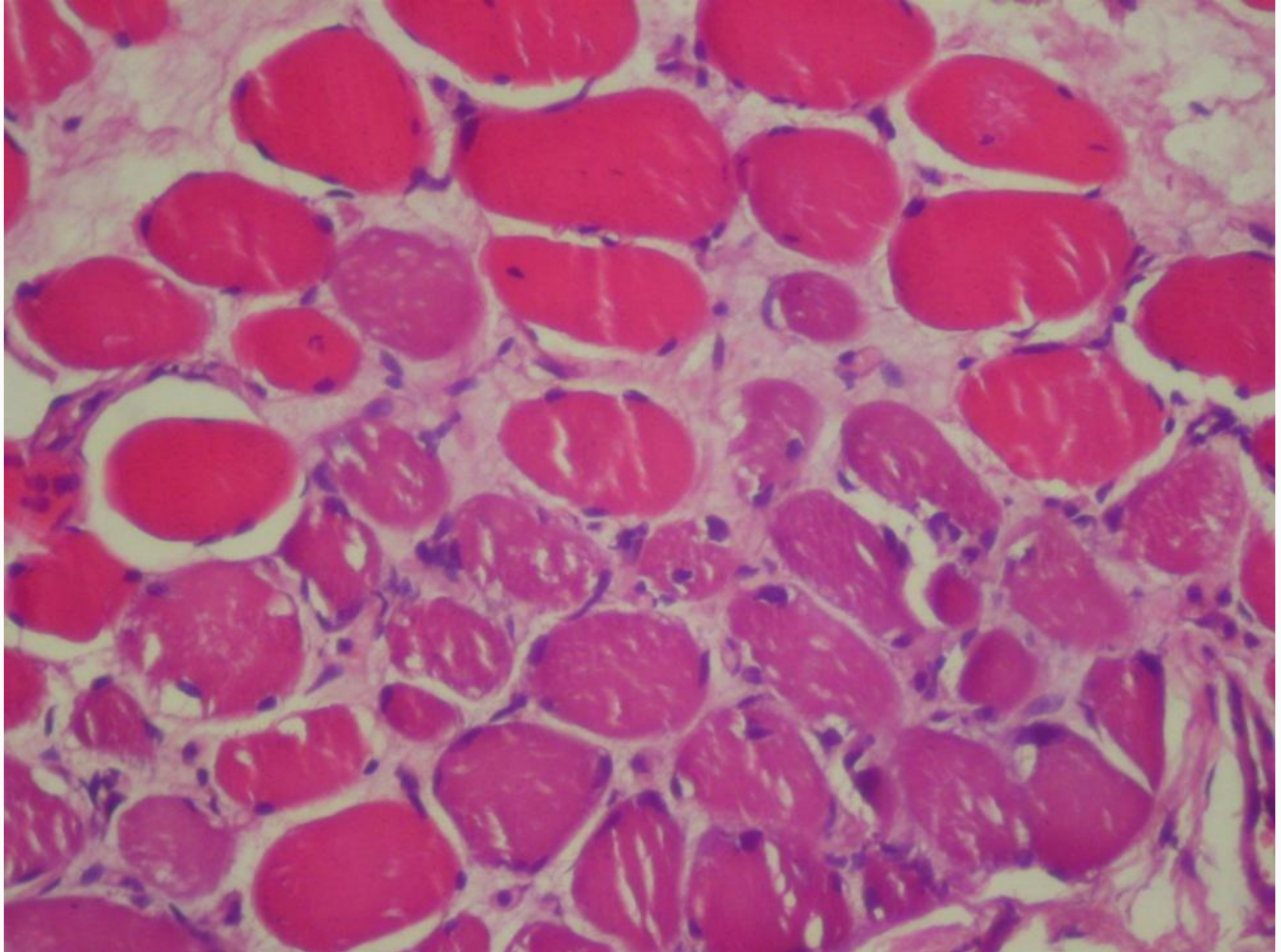
- Myofiber boyut ve Őekil farkı en 6nemli kas incinme bulgularından biridir.

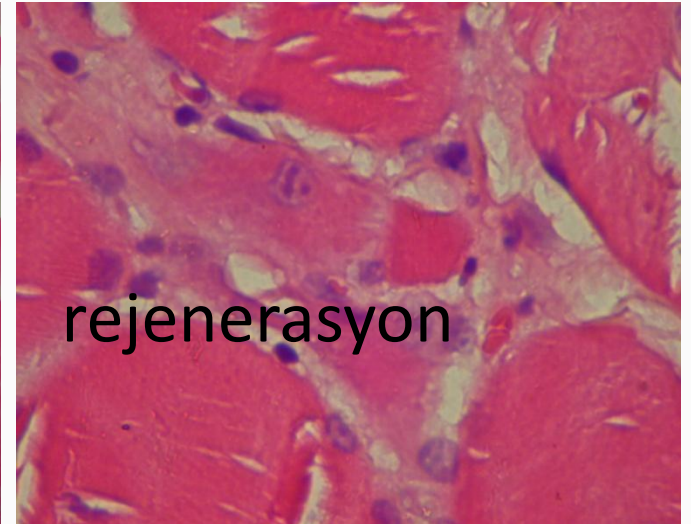
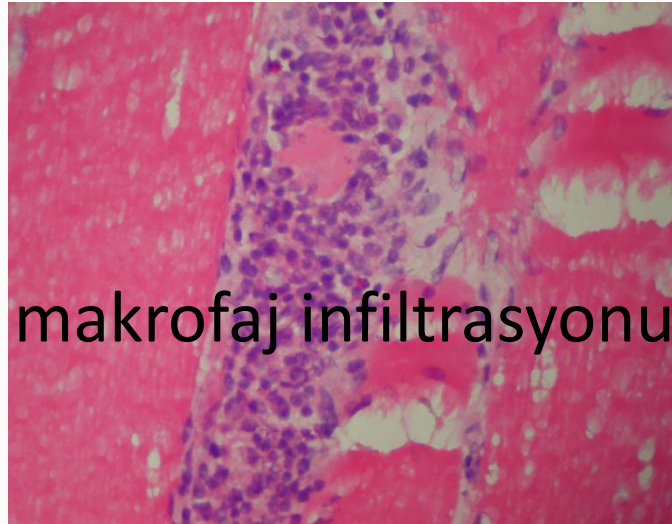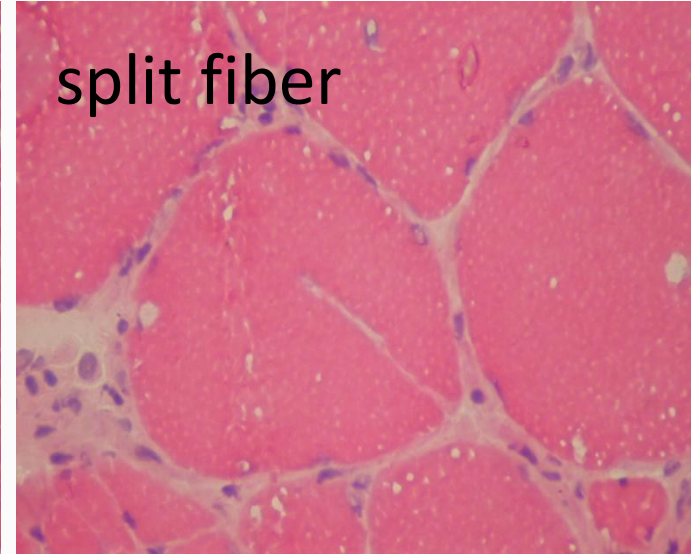

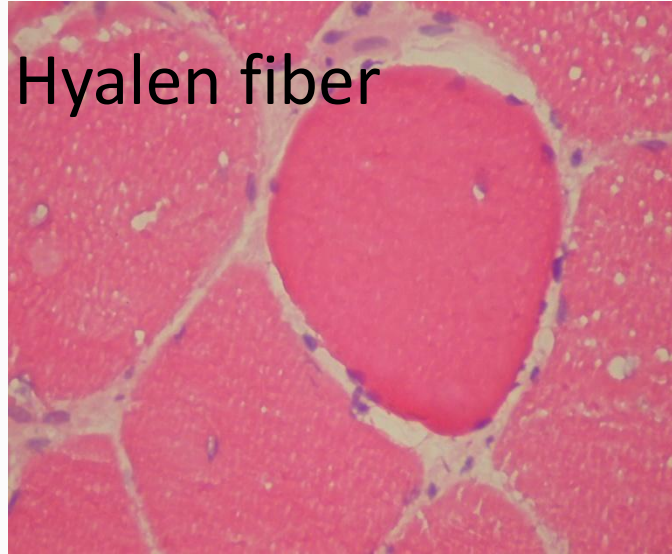
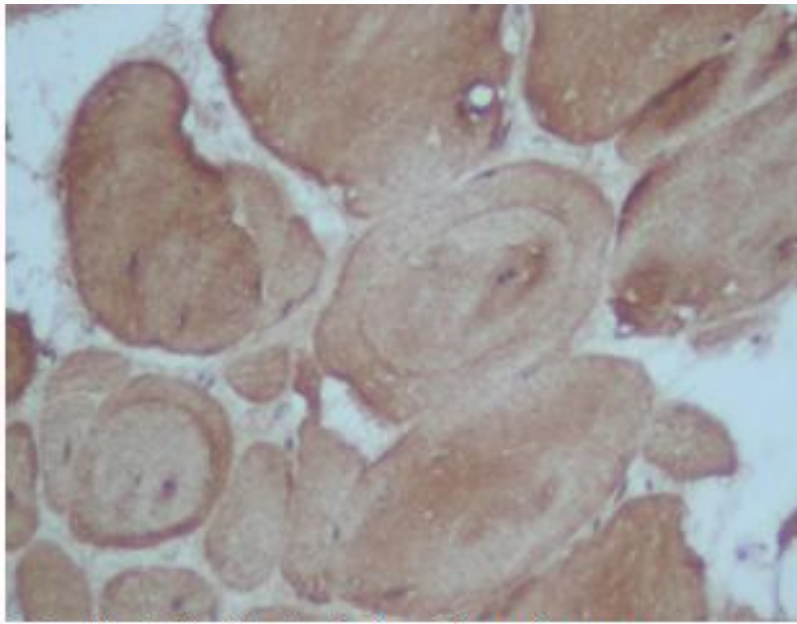





Oil red O ile intrasellüler lipit birikimi

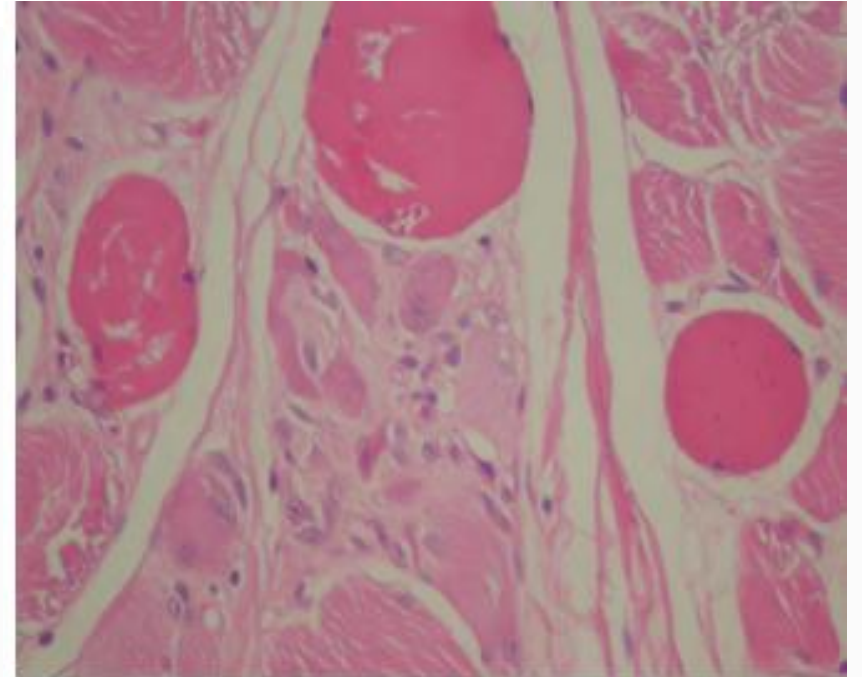
- Rejenerasyon distrofilerin damga vurucu özelliğidir





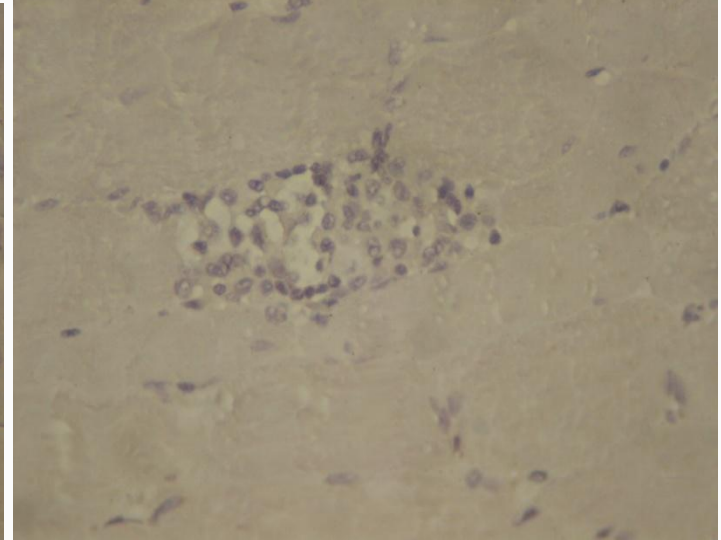
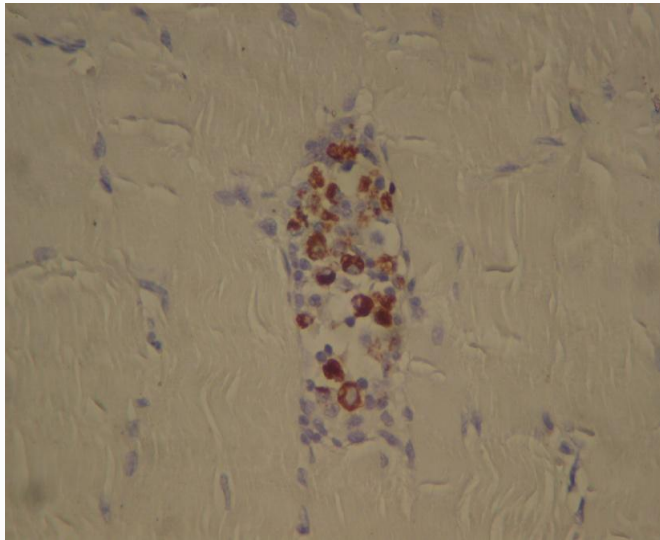
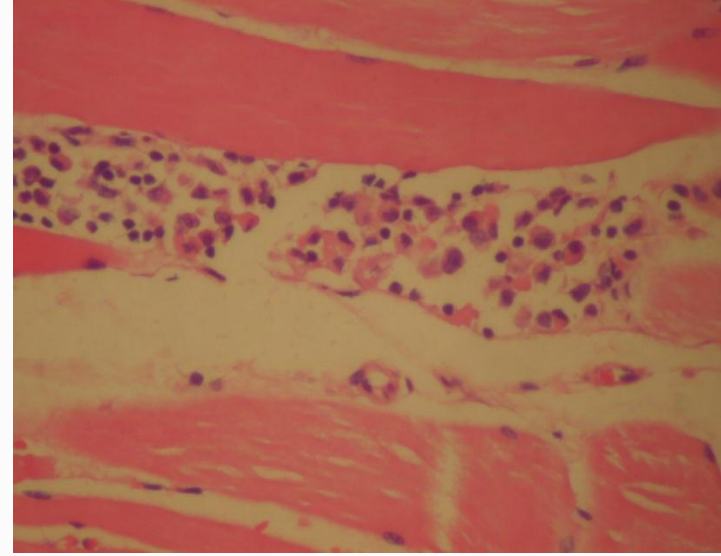
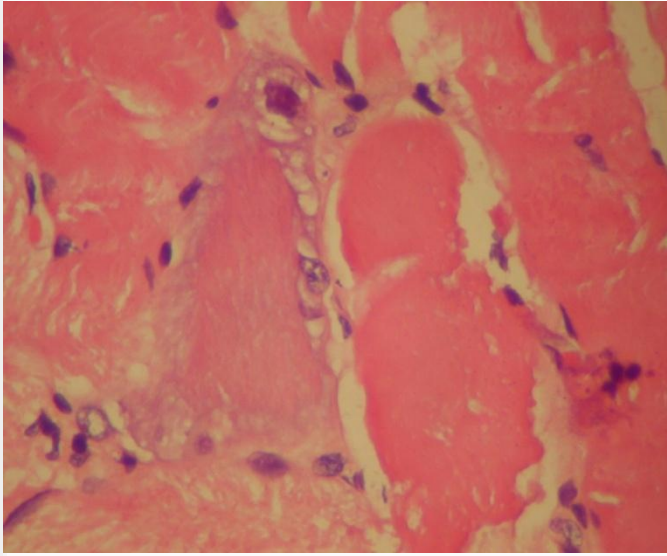


Myotilin ile belirgin girdap fiber oluşumu.



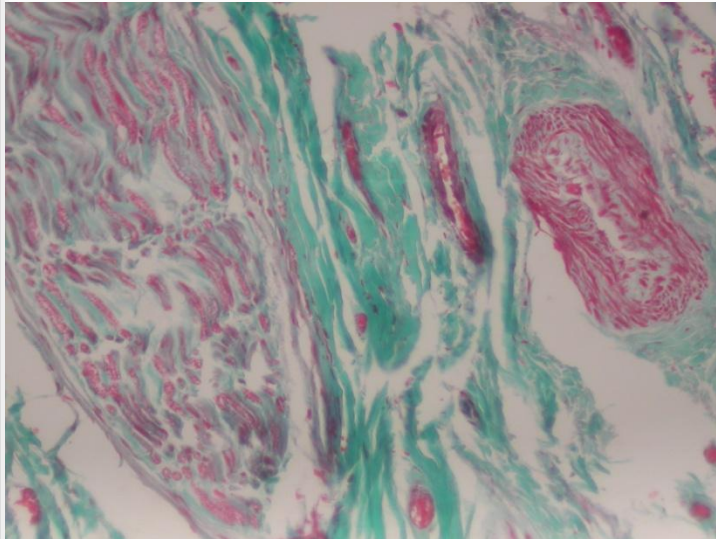
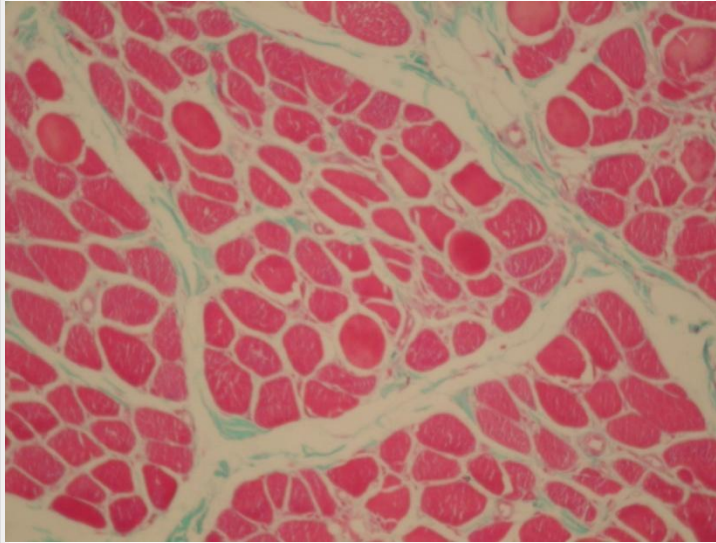
Myofiber şekil-boşut farkı, kontraksiyon, rejenerer fiber.

TANI: Disferlinopati, LGMD-2B fenotipinde


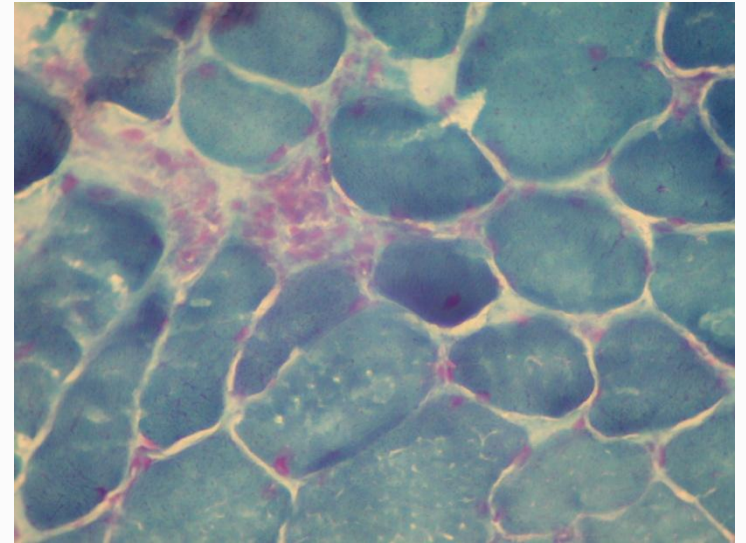


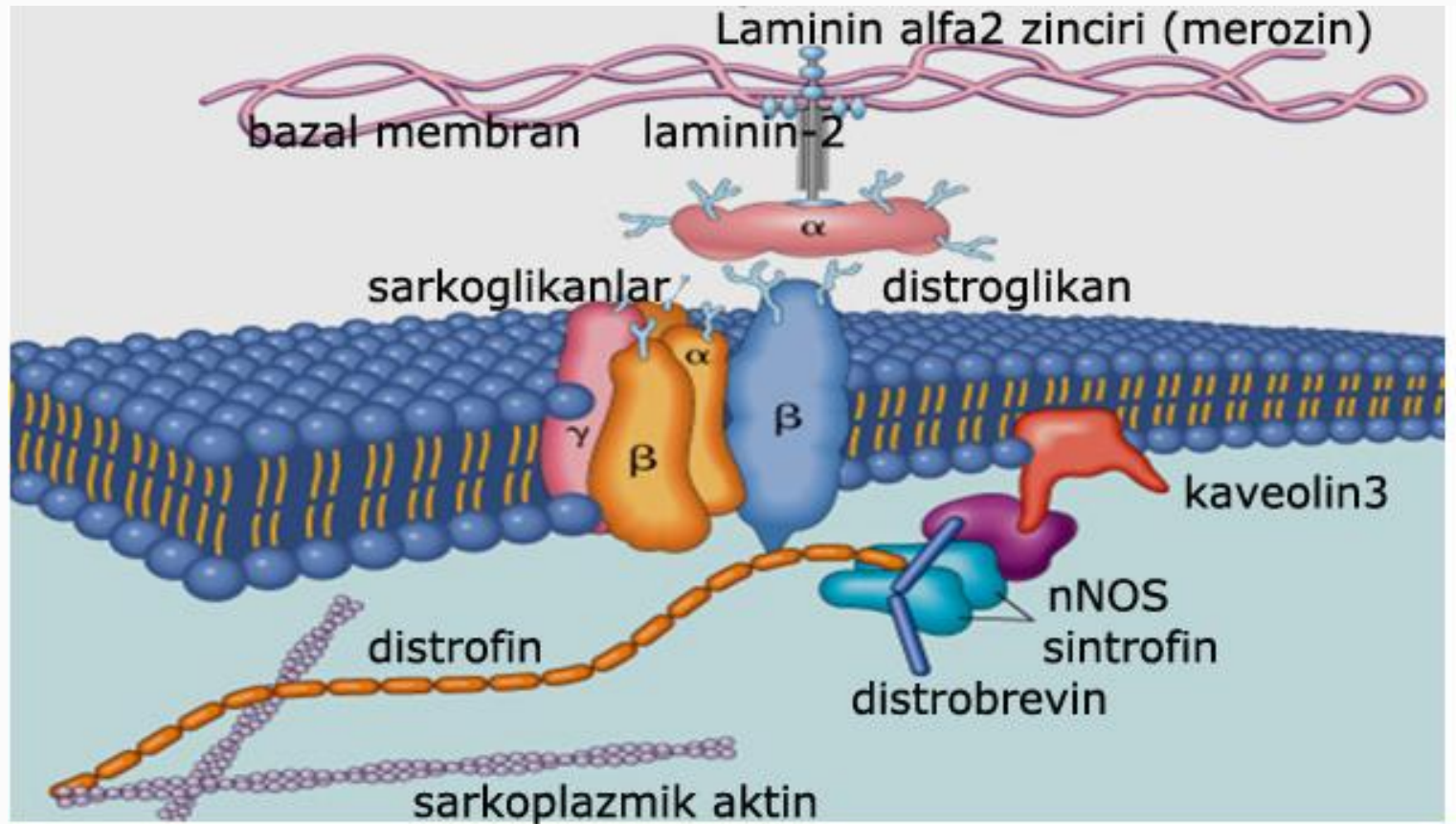
27 yaşında erkek olgu, askerdeyken yapılan kas biyopsisinde inflamatuvar myopati tanısı almış

Gomori trikrom



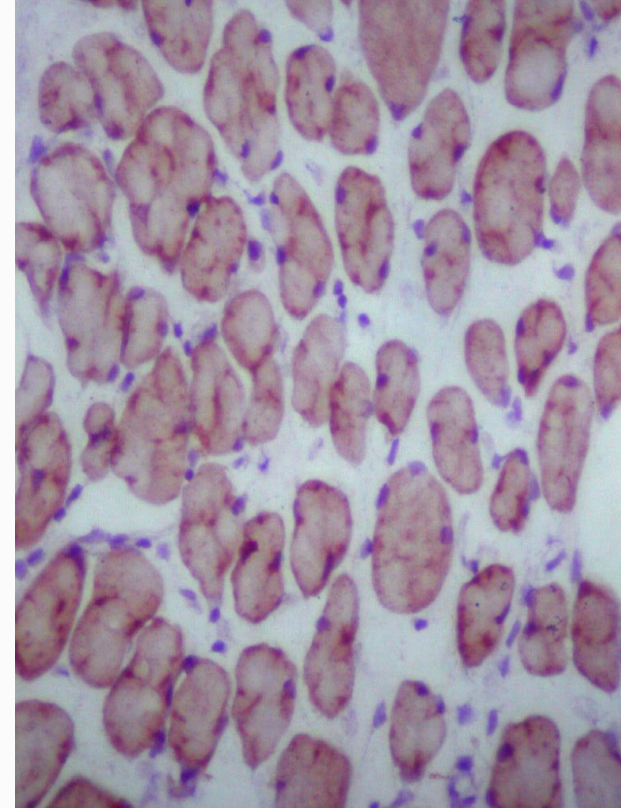
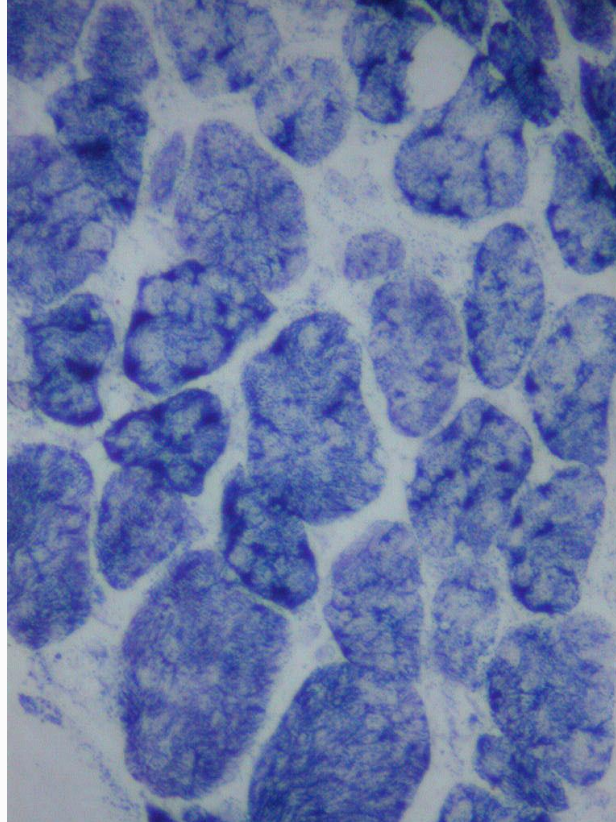
Modifiye Gomori trikrom
(Engel- Cunningham modifikasyonu)



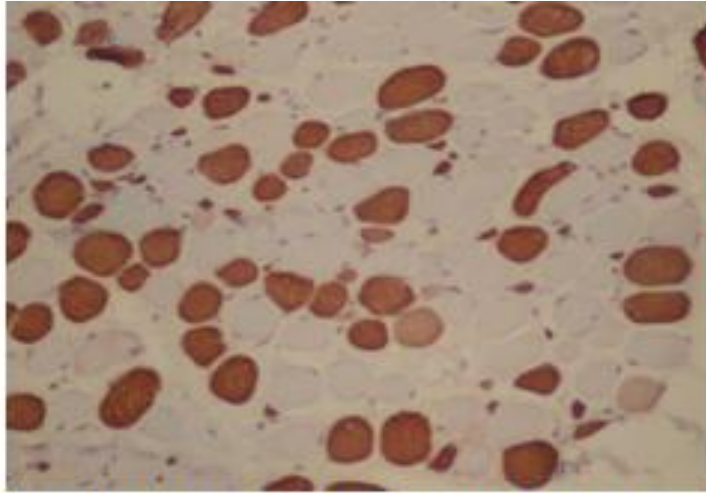


LGMD 1A	MYOTİLİN	LGMD 2C	D-SARKOGLİKAN
LGMD 1B	LAMİN A/C	LGMD 2D	A-SARKOGLİKAN
LGMD 1C	KAVEOLİN 3	LGMD 2E	B-SARKOGLİKAN
LGMD 2A	KALPEİN 3	LGMD 2F	G-SARKOGLİKAN
LGMD 2B	DİSFERLİN	EDMD	EMERİN

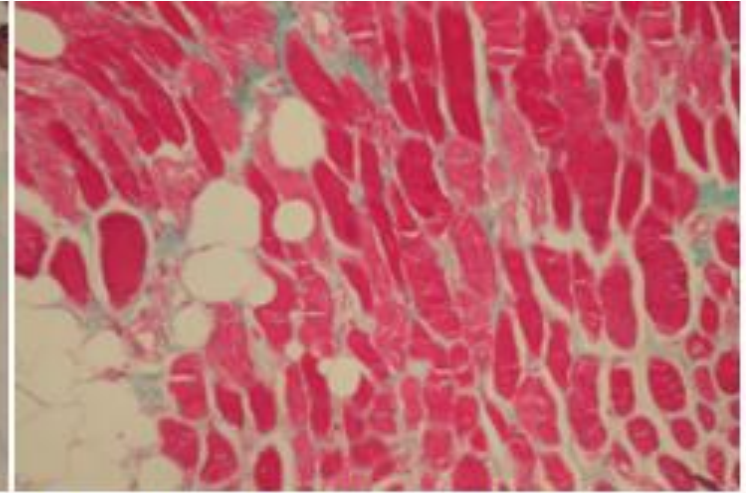
Lobüle veya trabeküler myofiber oluşumu
başta LGMD olmak üzere distrofilerde gözlenir



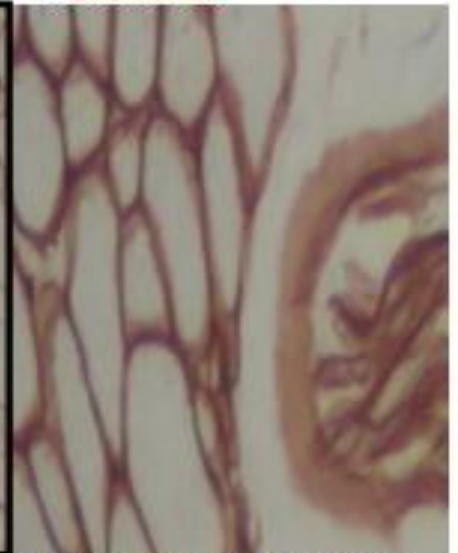
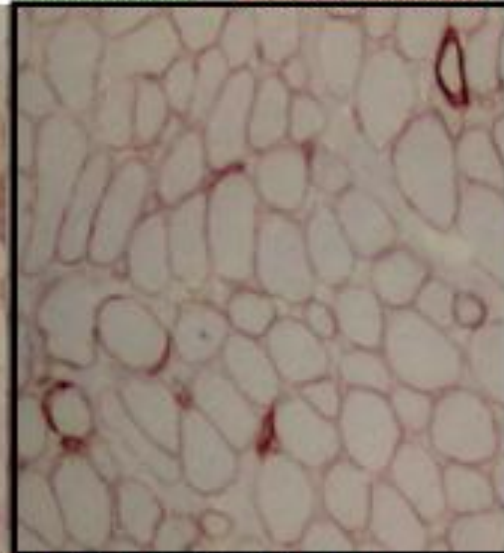
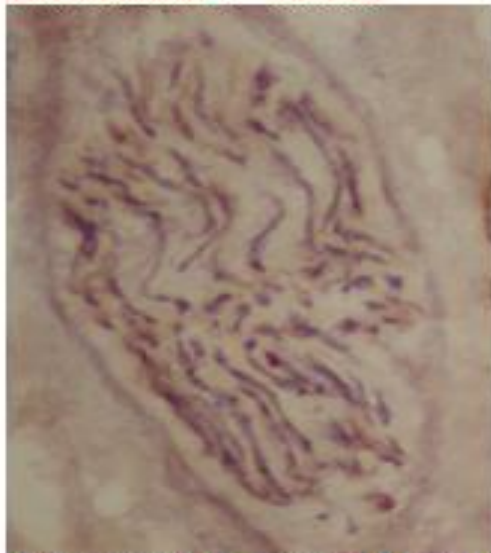
TANI: Merozin fokal pozitif konjenital muskuler distrofi.



Fast myozinde tip2 myofiber oranında hafif azalma.

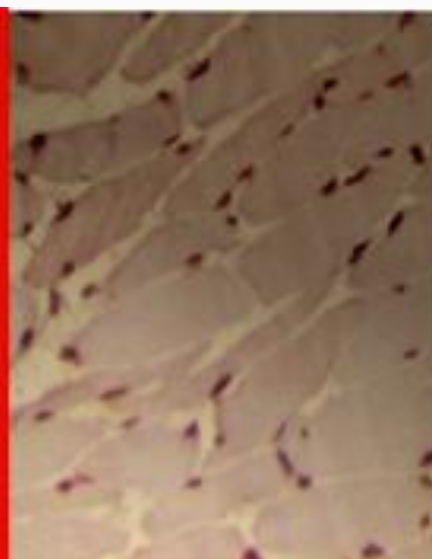
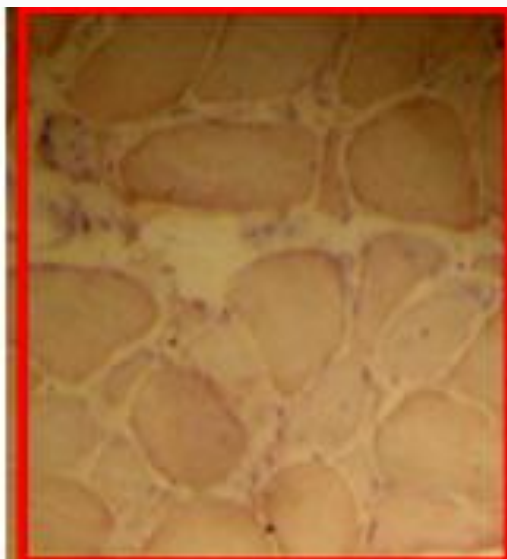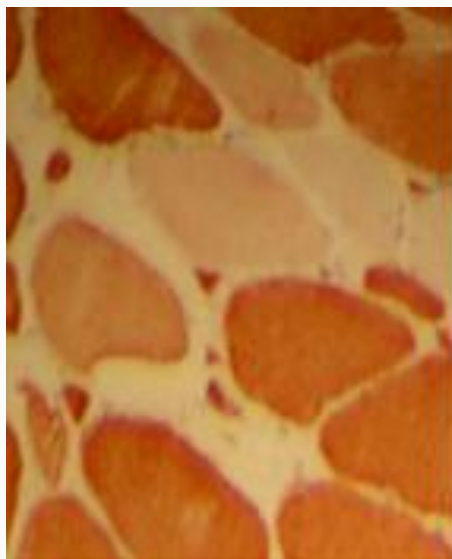
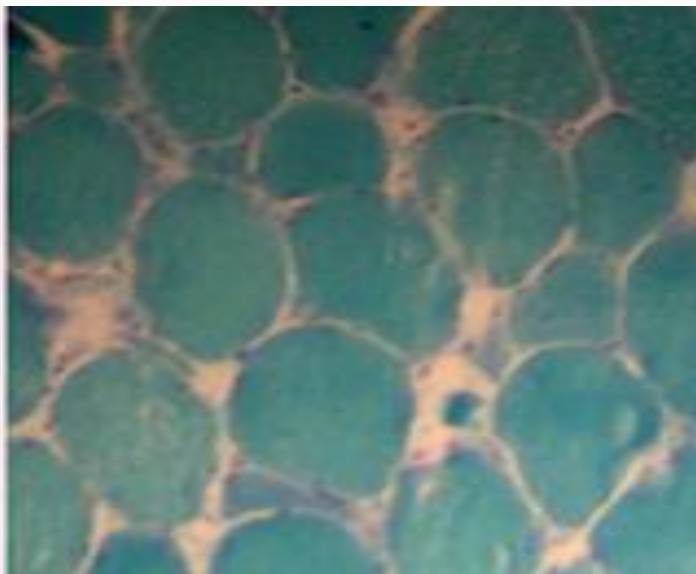
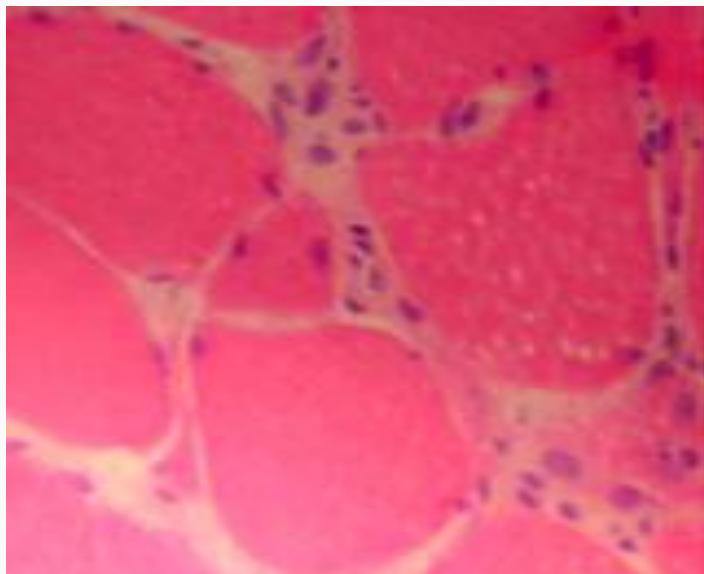


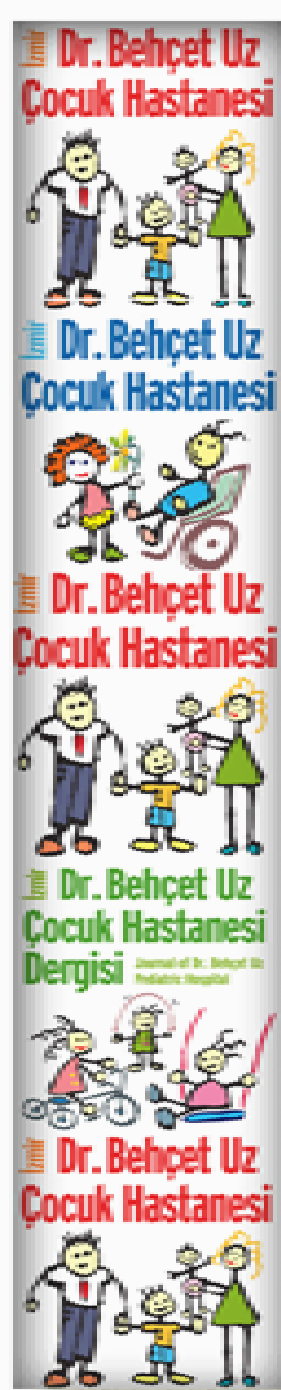
Gomori trikromda artmış interstisyel doku.



Olguda sinirde (solda) ve kasda (ortada) fokal MEROZİN defekti. Kontrol kasında sarkolemmada ve sinirde MEROZİN pozitifliği (en sağda).

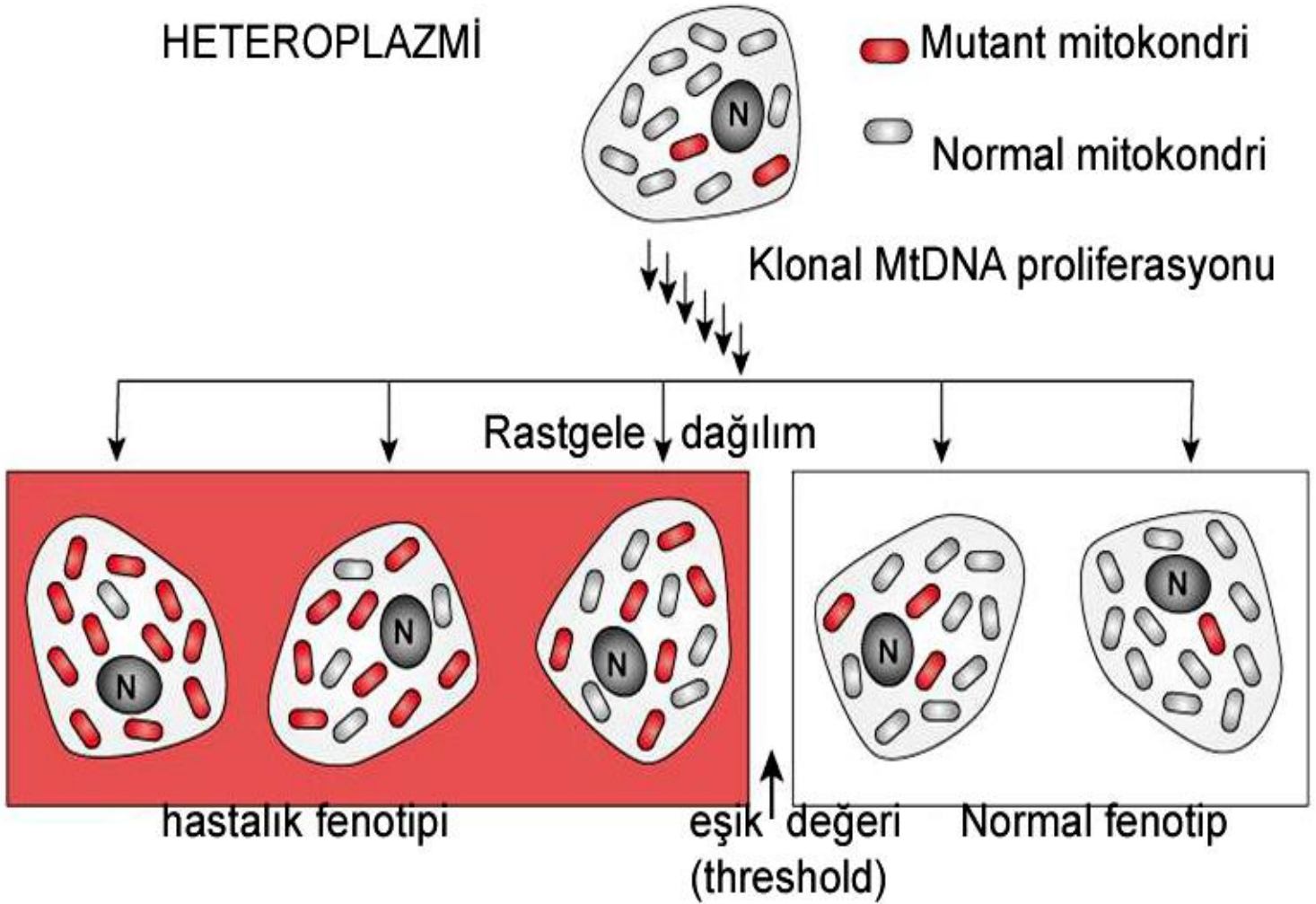
TANI: Emery Dreifuss Muskuler Distrofisi



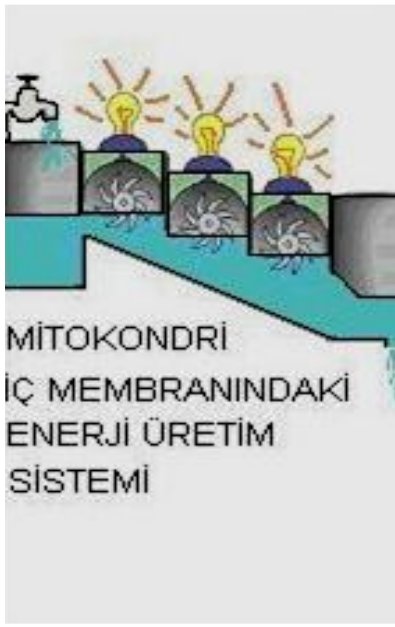

MITOKONDRIAL HASTALIKLAR

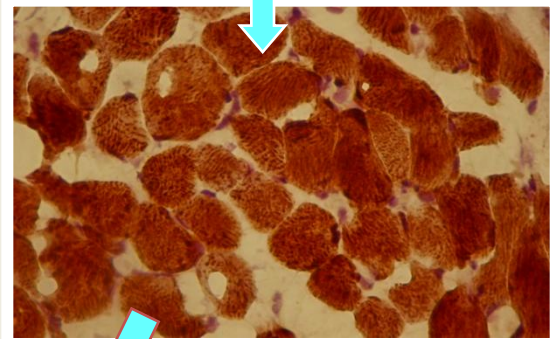
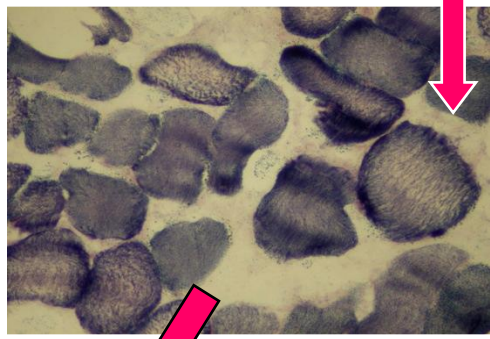
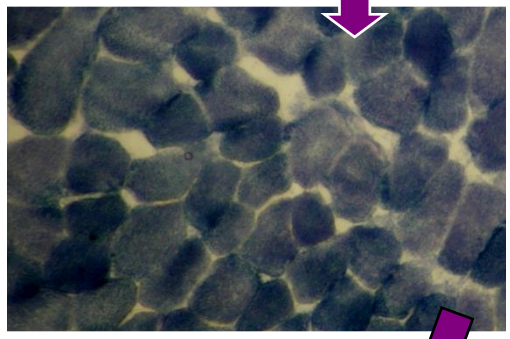
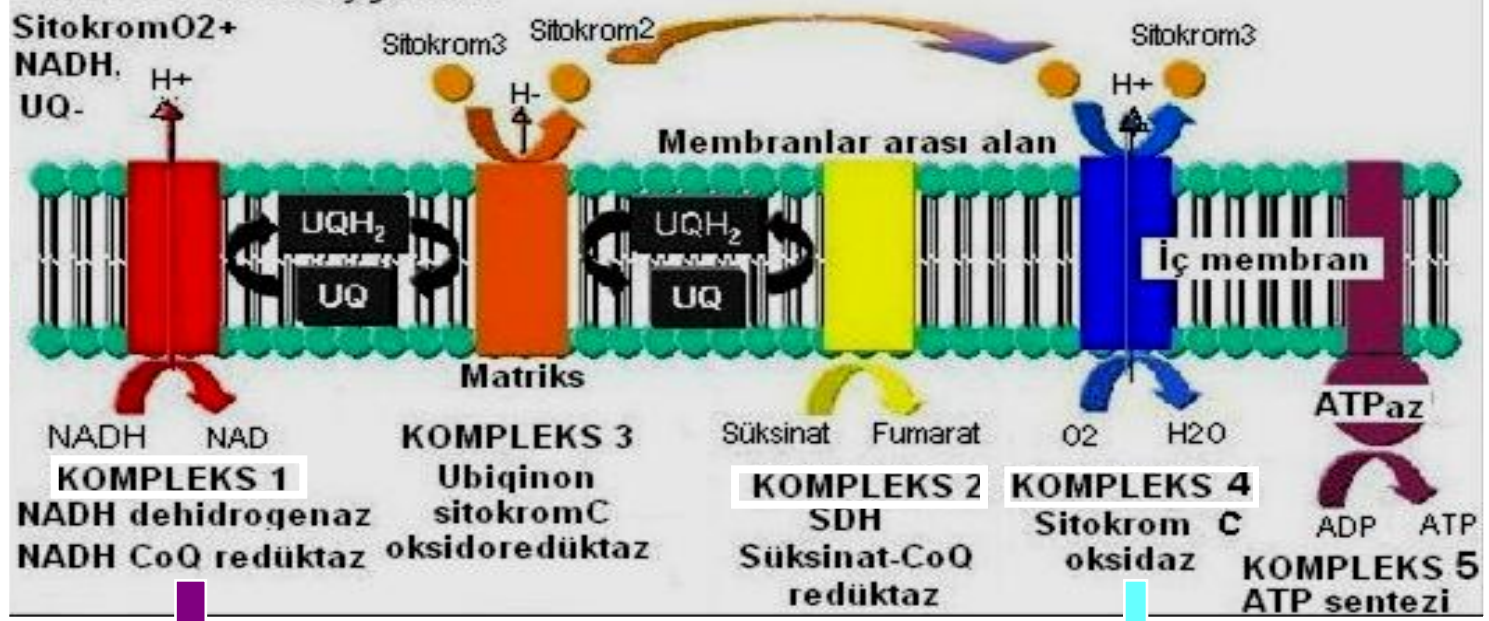HETEROPLAZMİ



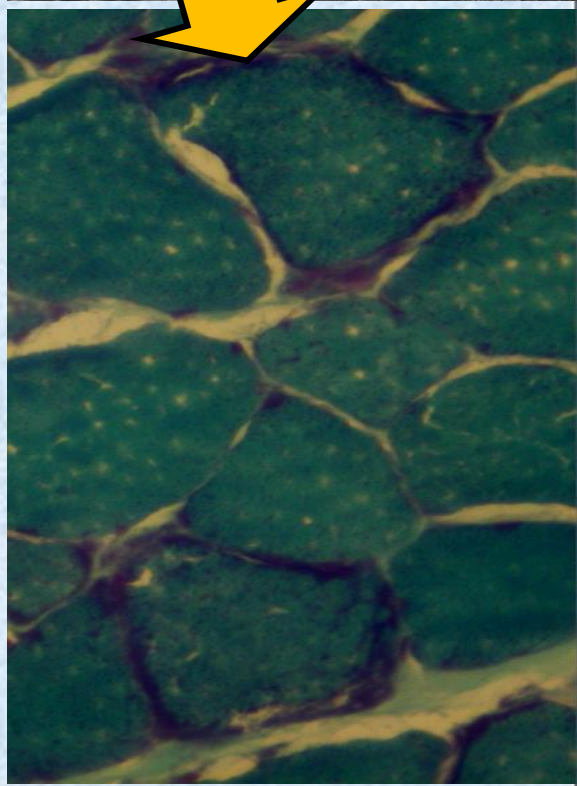

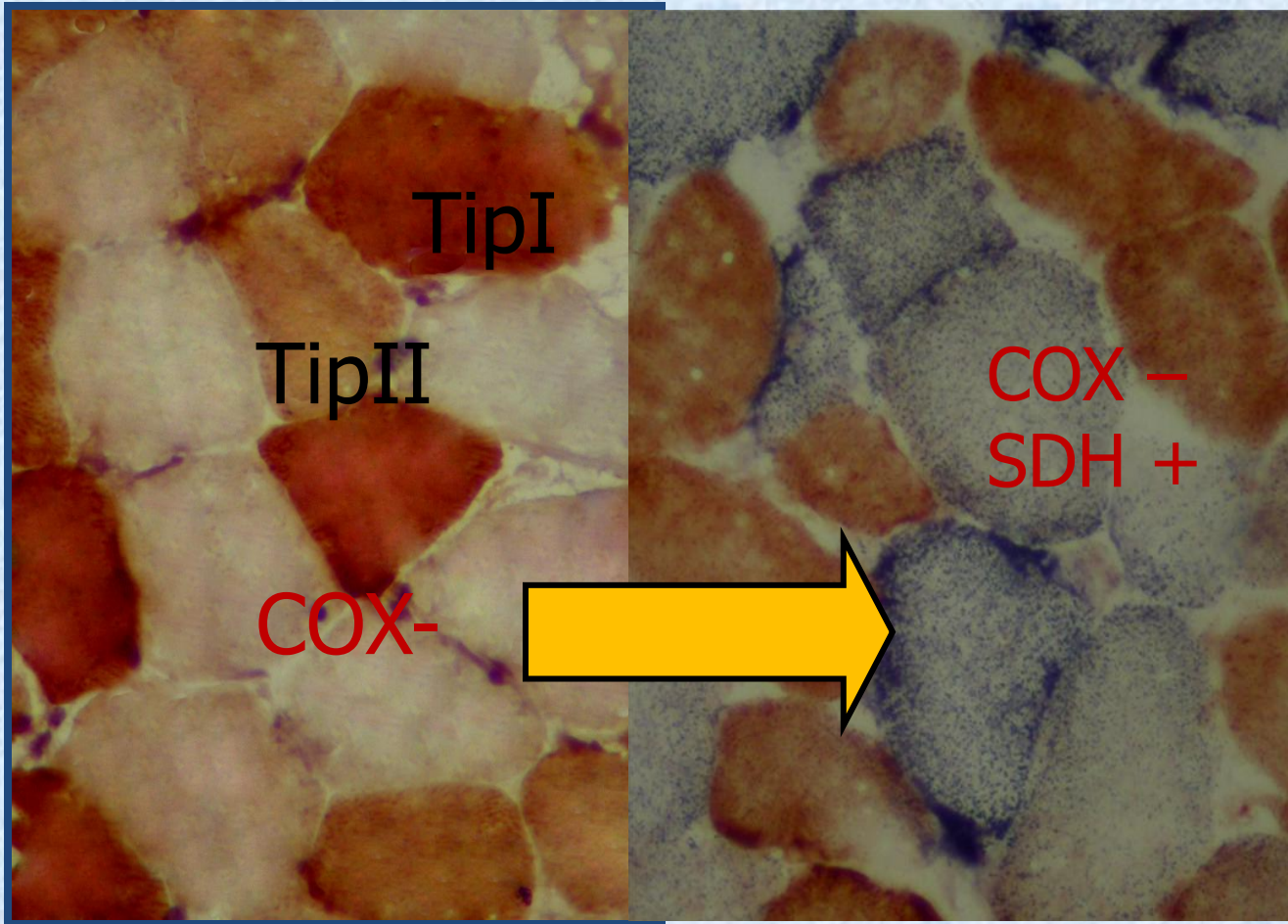
- Her hücrenin mitokondri içeriği, her mitokondrinin MtDNA içeriği farklıdır. Disfonksiyona neden olacak minimum mutant MtDNA miktarına eşik değer etkisi denir.

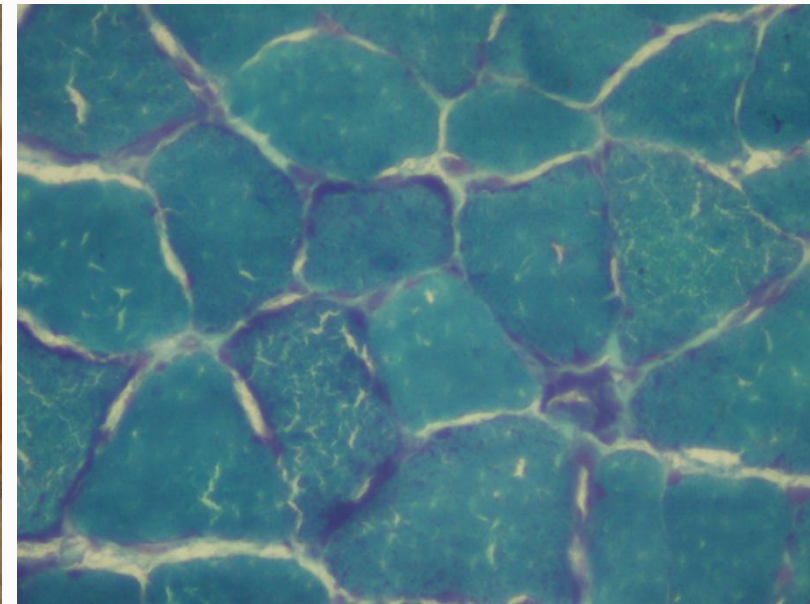
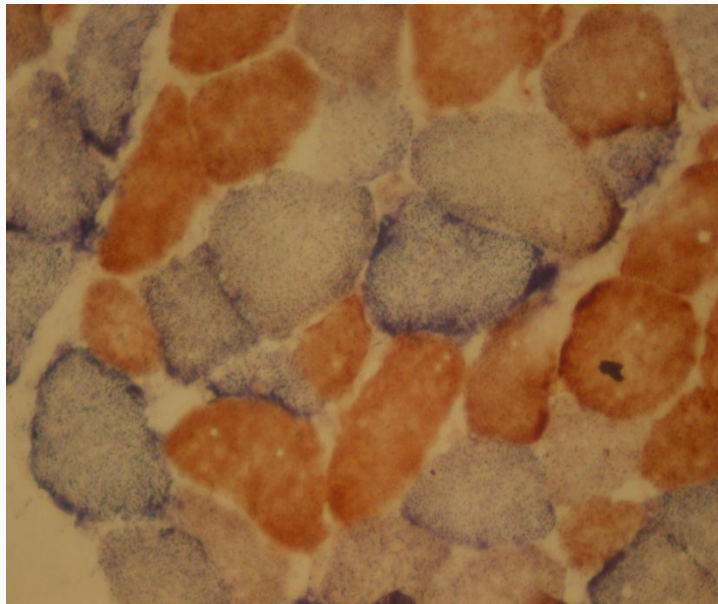
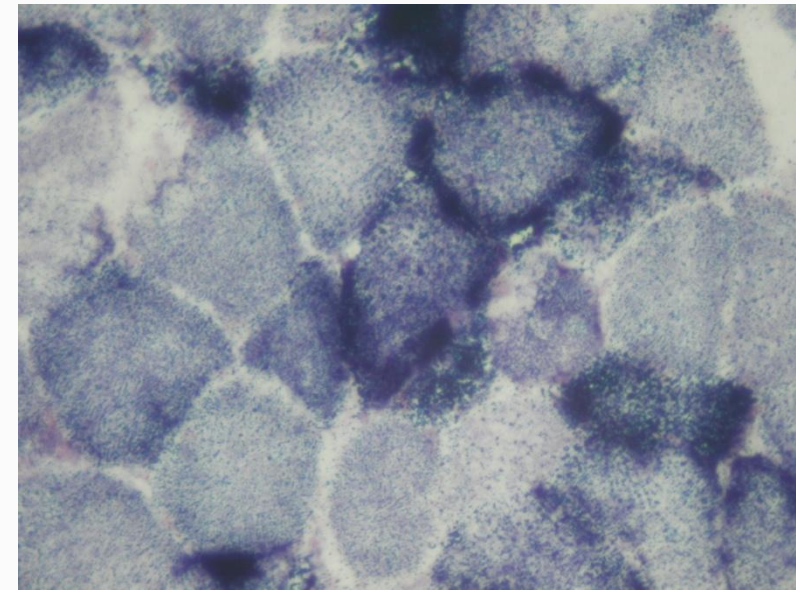
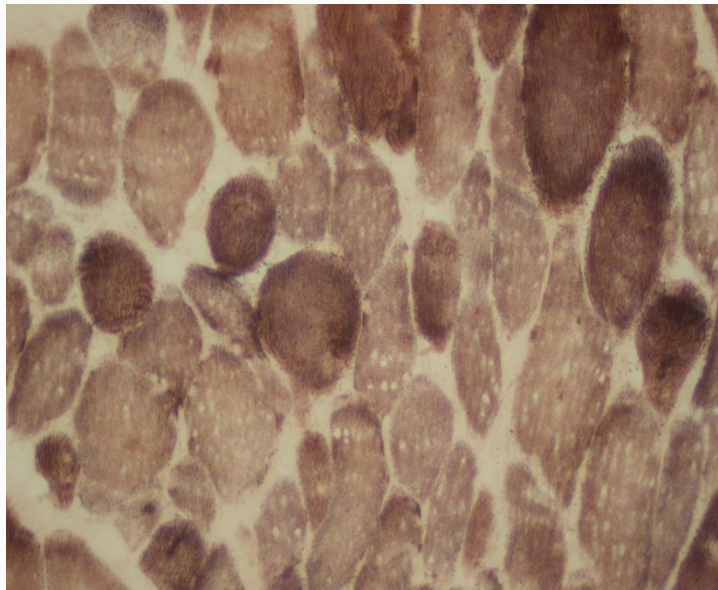


Serbest elektron taşıyıcıları:



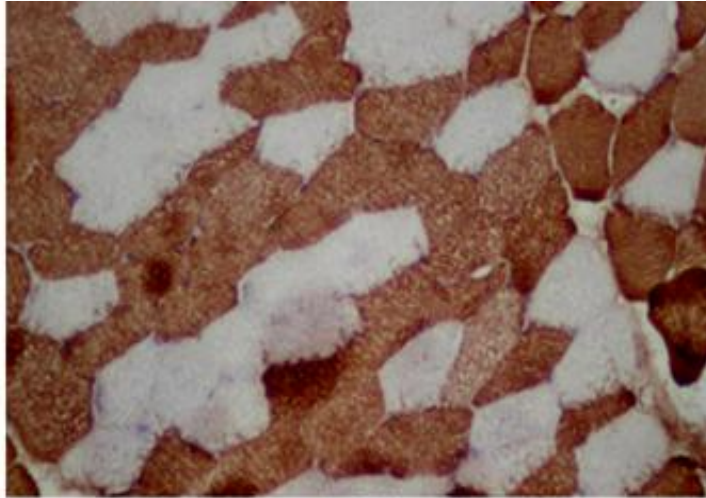
Alt birim	Komp1 NADH dehidrogenaz	Komp2 SDH	Komp3	Komp4 COX	Komp5 ATP sentetaz	Adenin taşıyıcısı
mtDNA	%17	0	% 10	%23	%15	0
nDNA	%83	%100	%90	%77	%85	%100



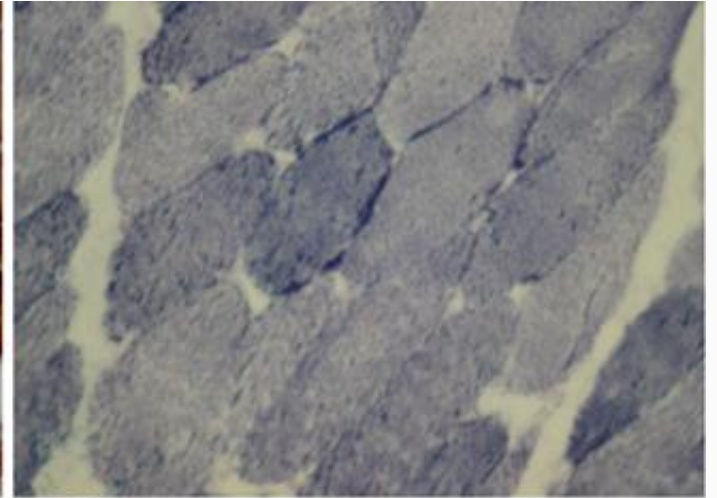


Mitokondrial hastalık bulguları

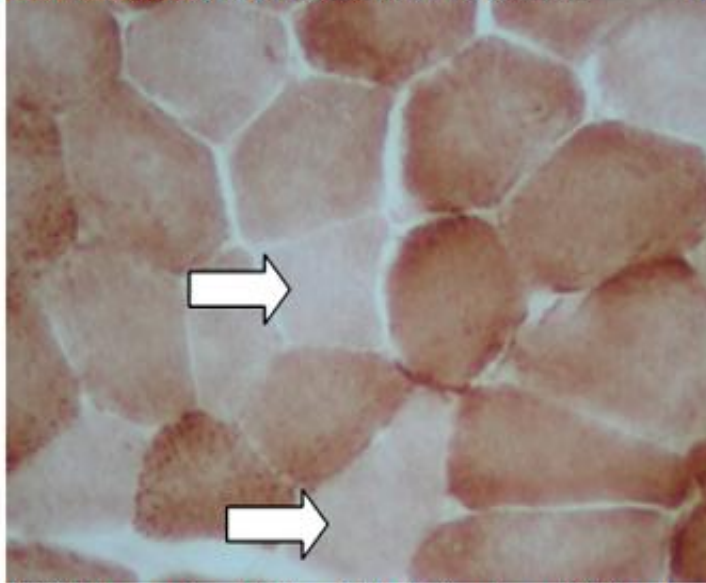
TANI: Mitokondrial myopati



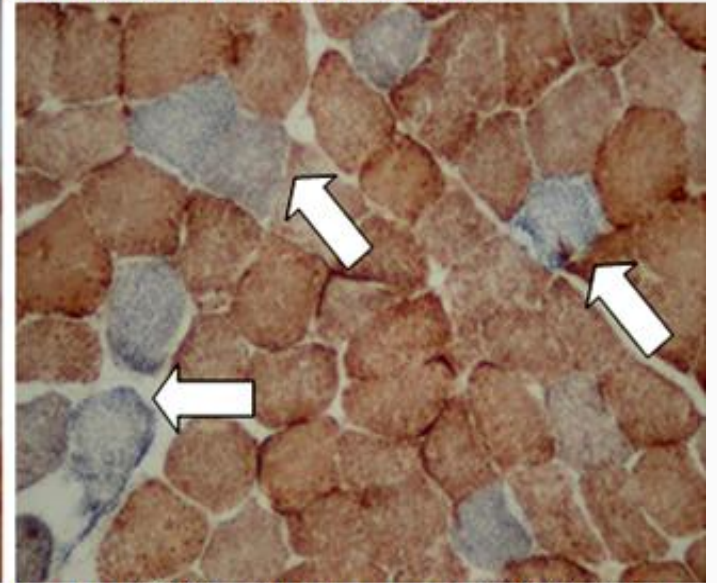
Fast myozinle olağan tip 2/ tip1 fiber oranı.



NADH-TR ile olağan myofibriler yapı.




COX ile enzim aktivitesi düşük (açık renk) fiberler arasında ortada 2 negatif lif varlığı (ok).




Kombine COX + SDH boyamada COX(-), SDH(+) MAVİ fiberler (oklar).


Dr. Behçet Uz
Çocuk Hastanesi



Dr. Behçet Uz
Çocuk Hastanesi



Dr. Behçet Uz
Çocuk Hastanesi



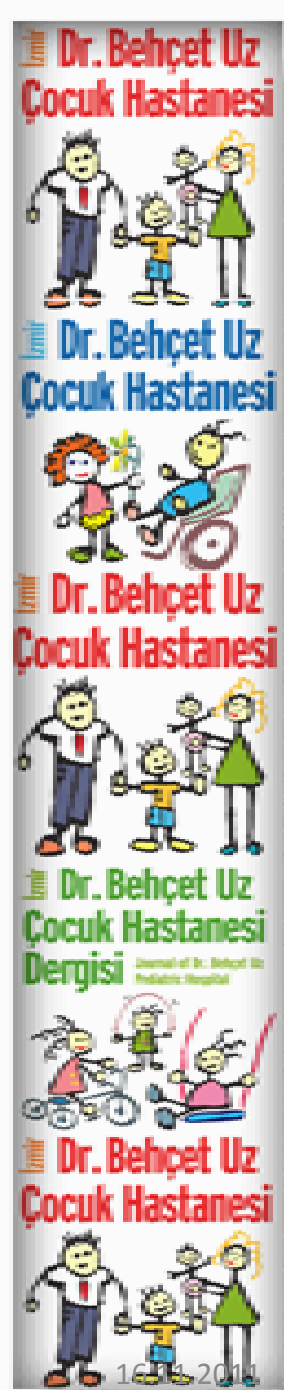
Dr. Behçet Uz
Çocuk Hastanesi
Dergisi



Dr. Behçet Uz
Çocuk Hastanesi



16 Ocak 2011



primum non nocere !

