

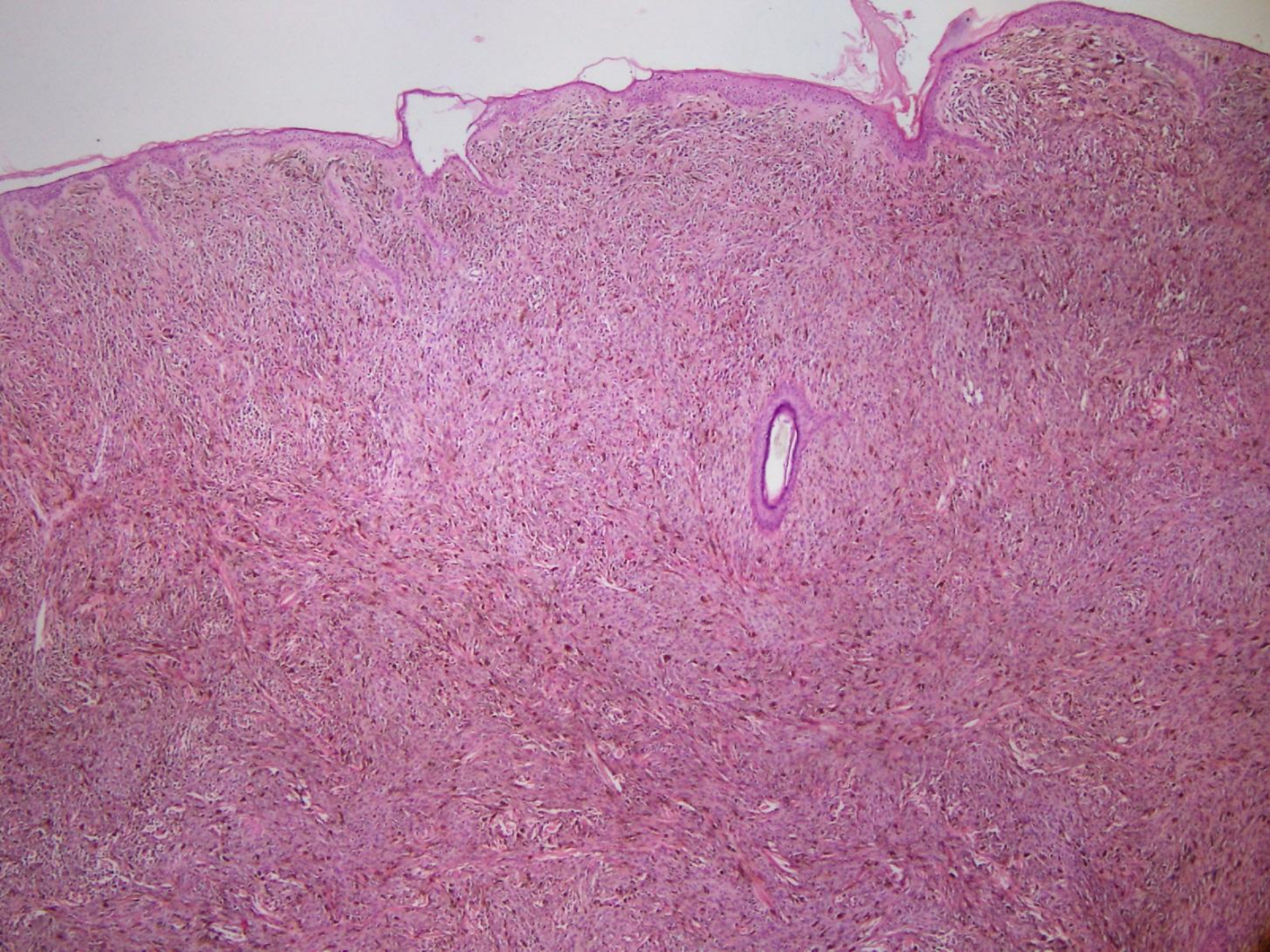


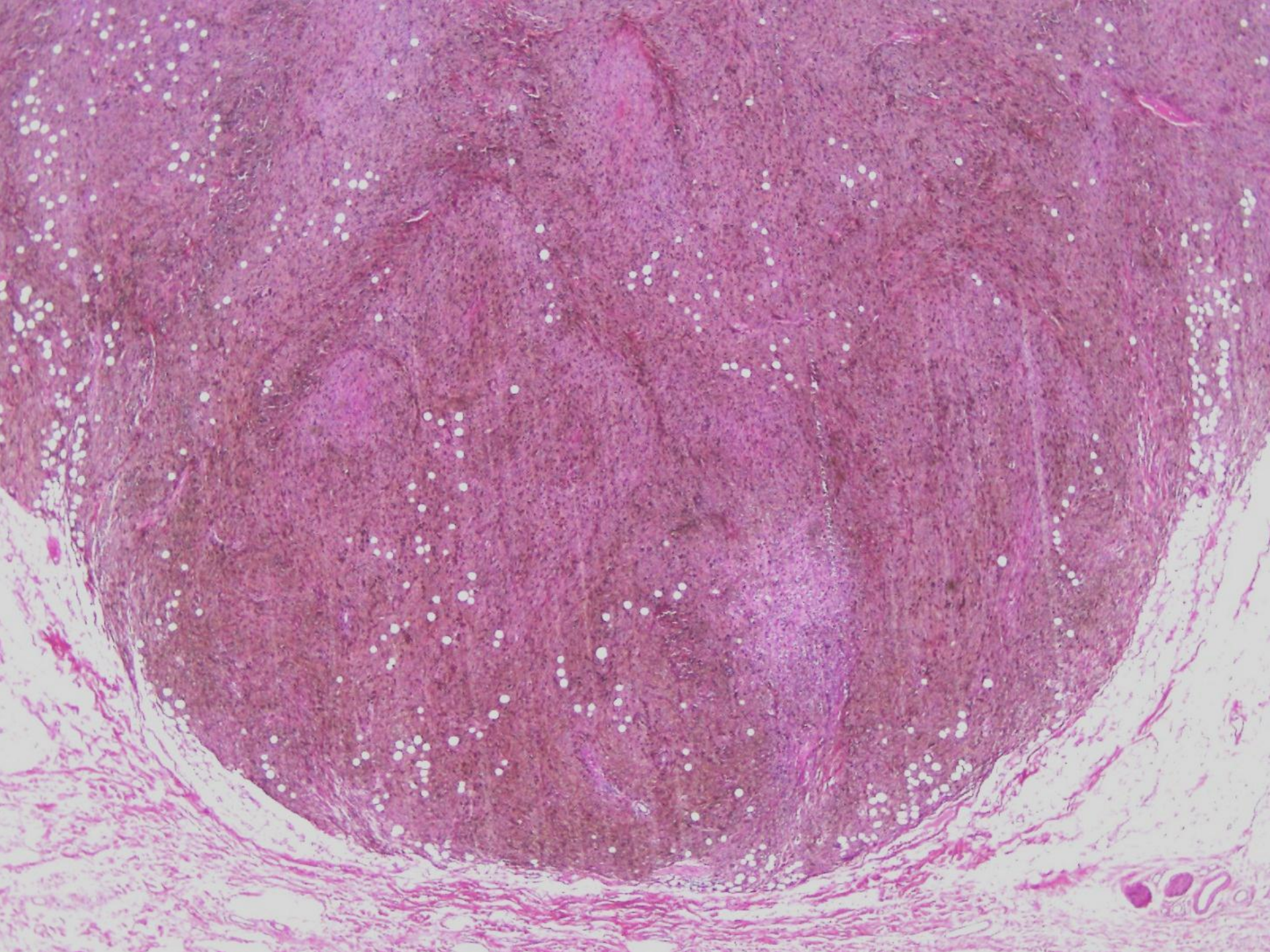
Dermatopatoloji Slayt Semineri: Ürkütücü Soru: Nevus veya Melanom

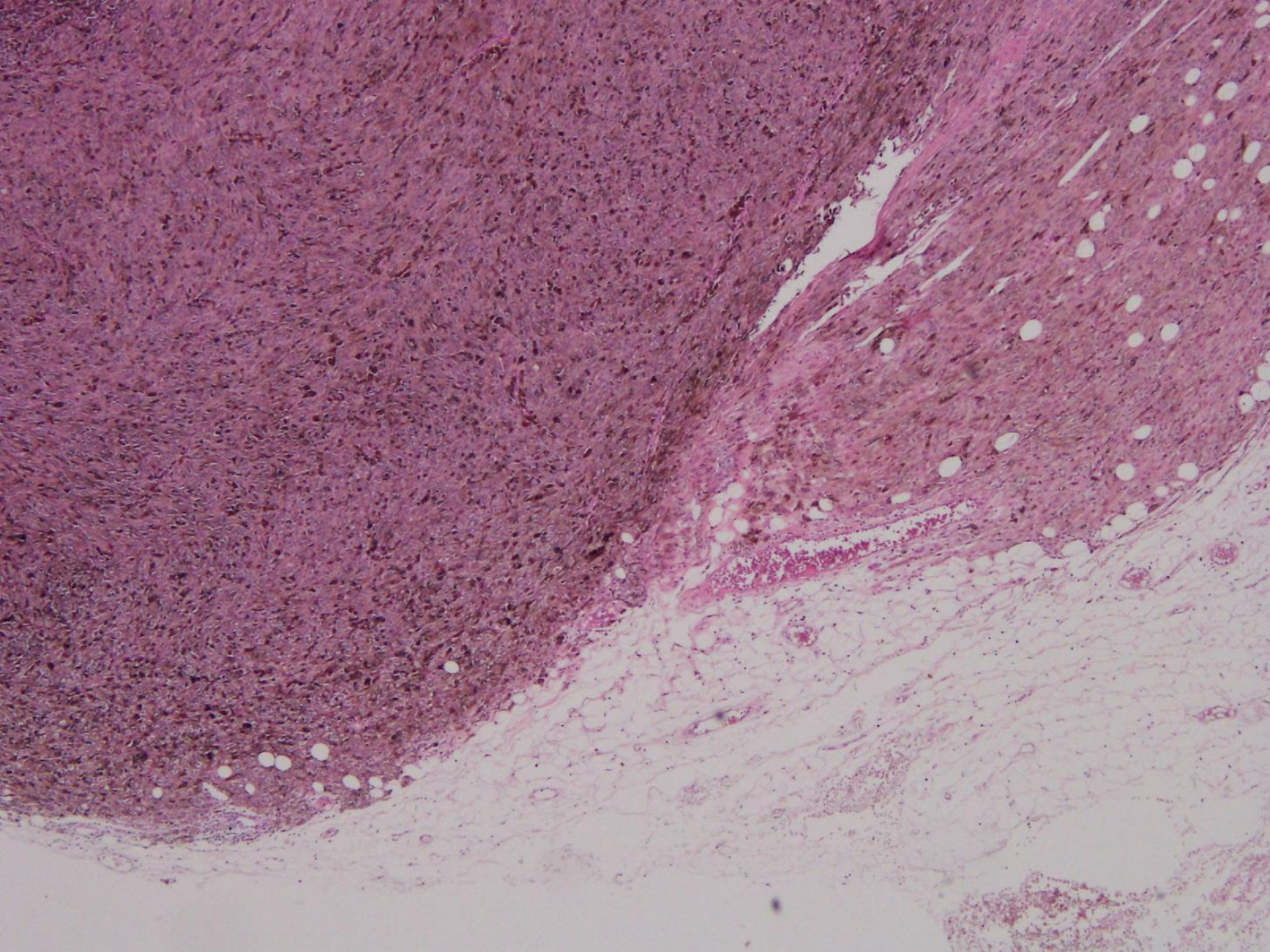
Prof Dr Taner Akalın
Ege ÜTF Patoloji AD

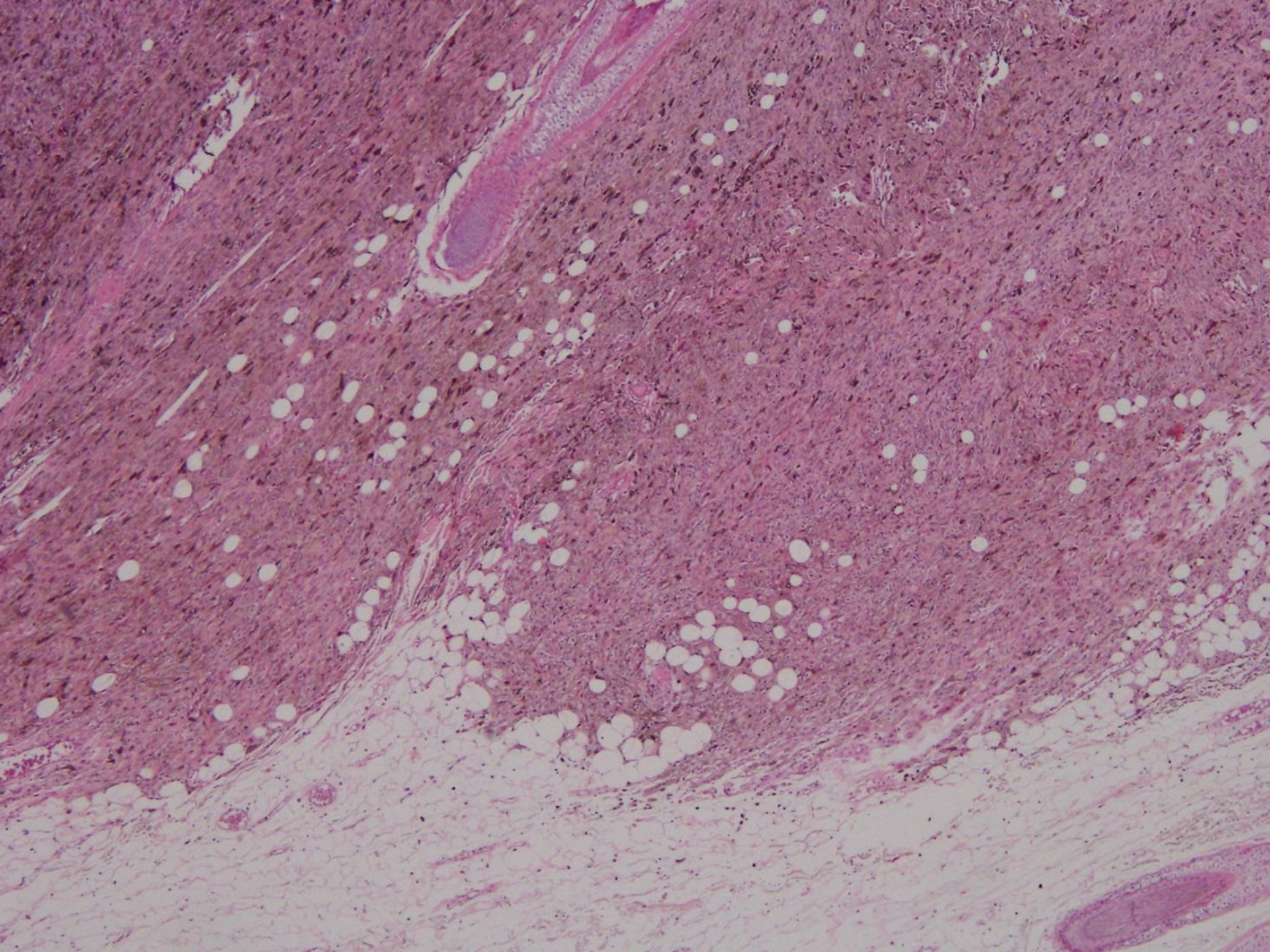
21. Ulusal Patoloji Kongresi, İzmir

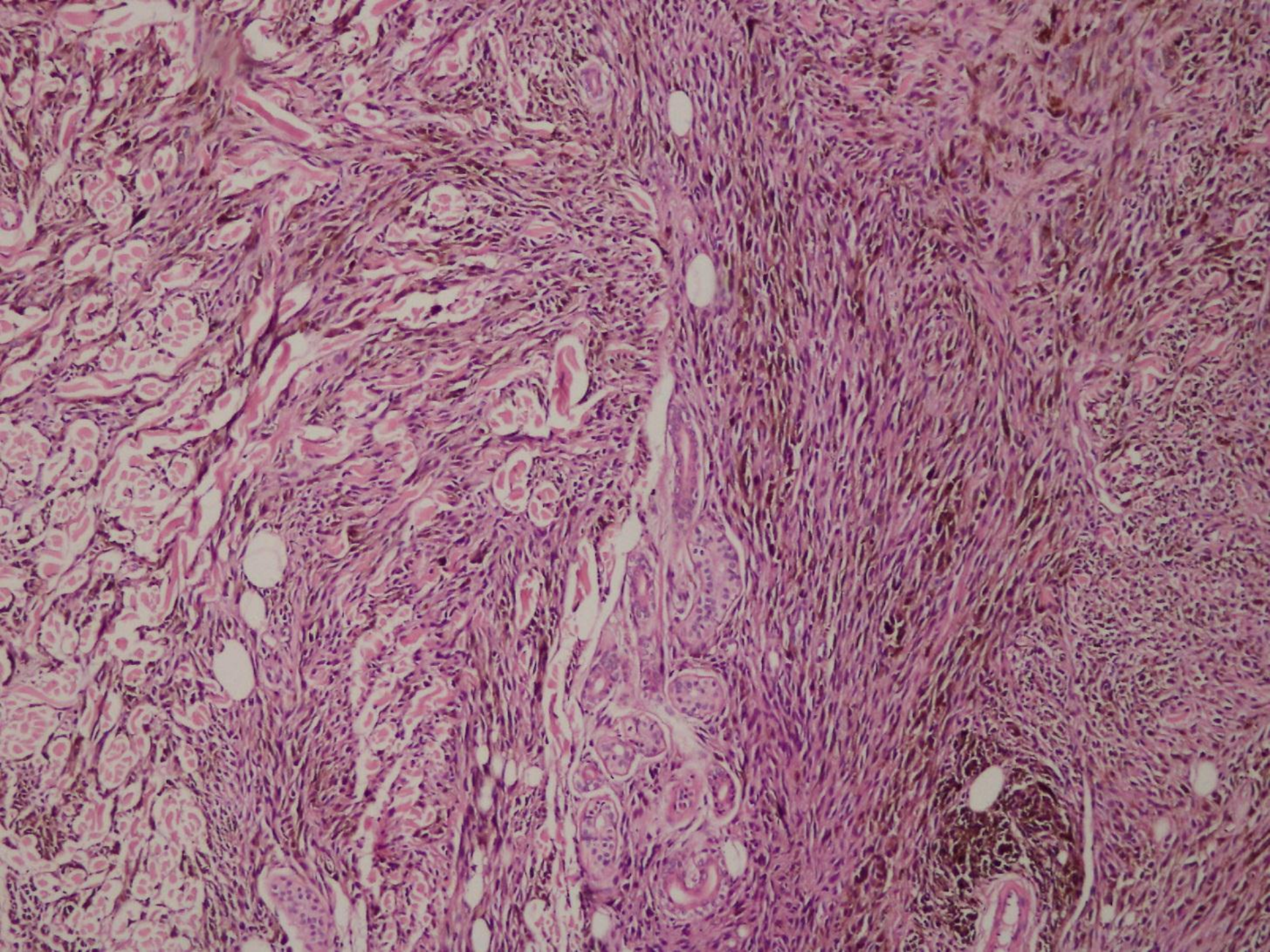
- 18 yaşında kadın
- Saçlı deride yerleşmiş pigmentli lezyonu (2,6x2x1,2 cm) eksize edilmiş
- Bir yıl sonra aynı bölgede nüks gelişmiş
- Konsültasyon için gönderilmiş 4 blok

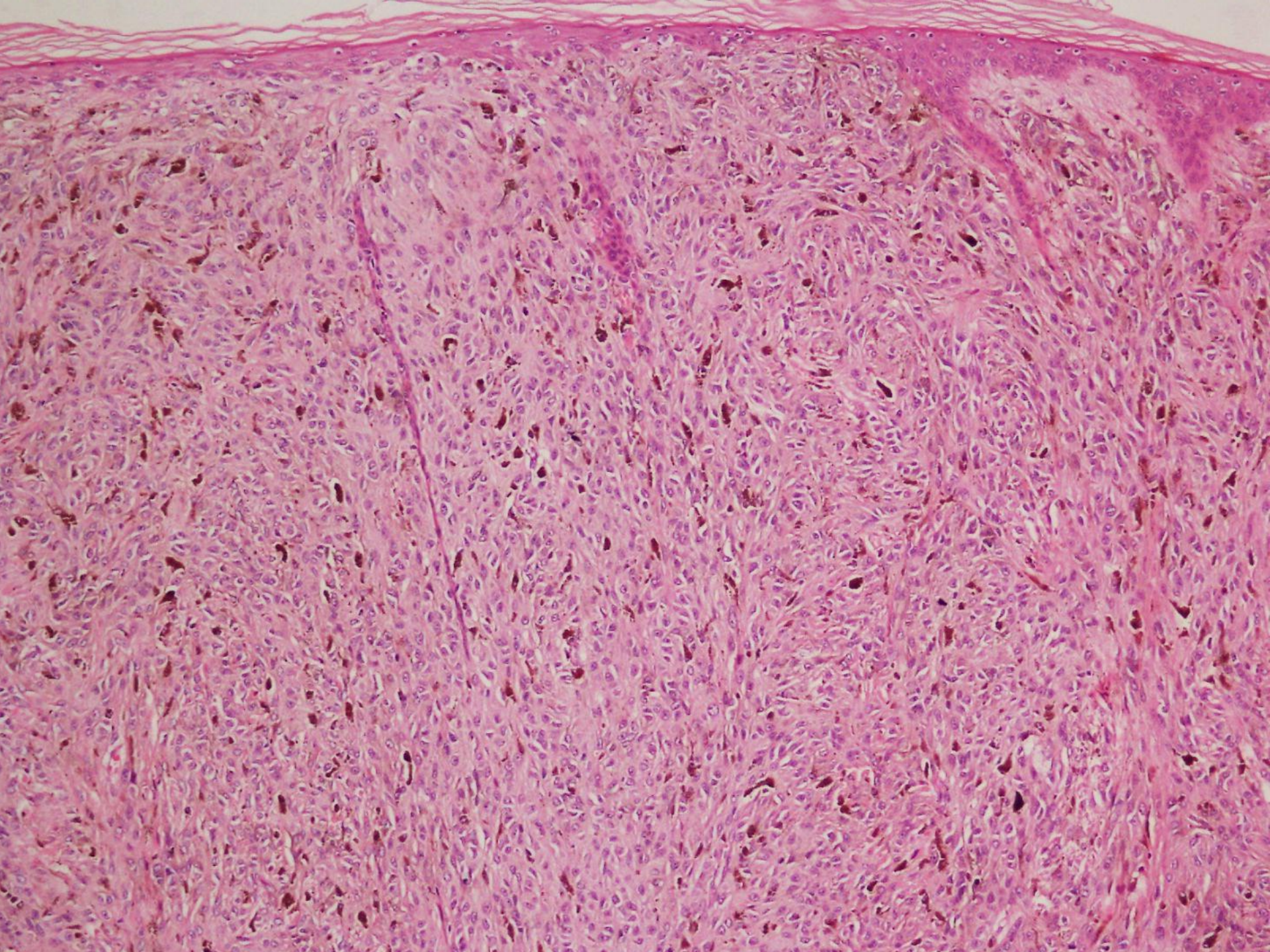


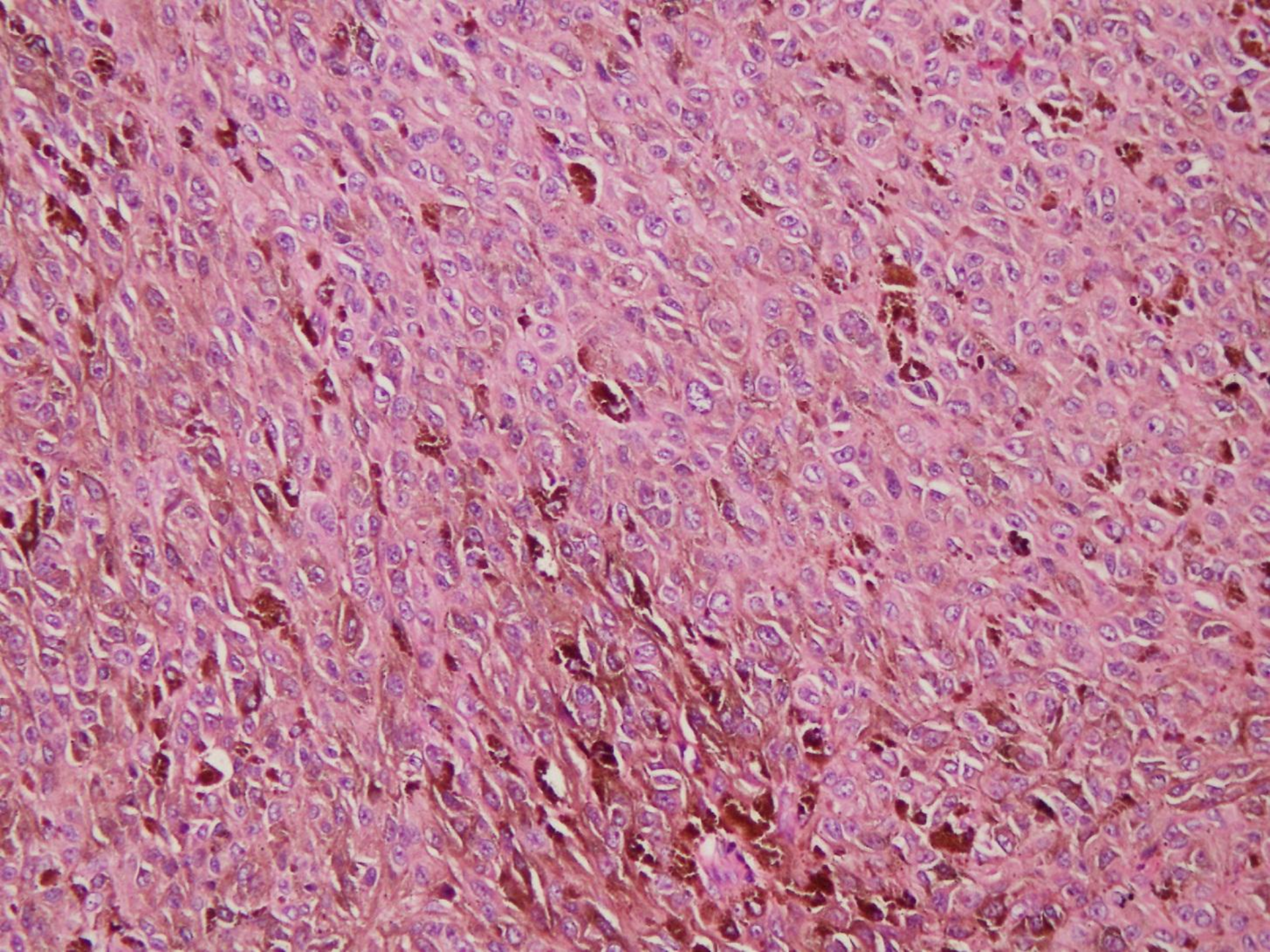


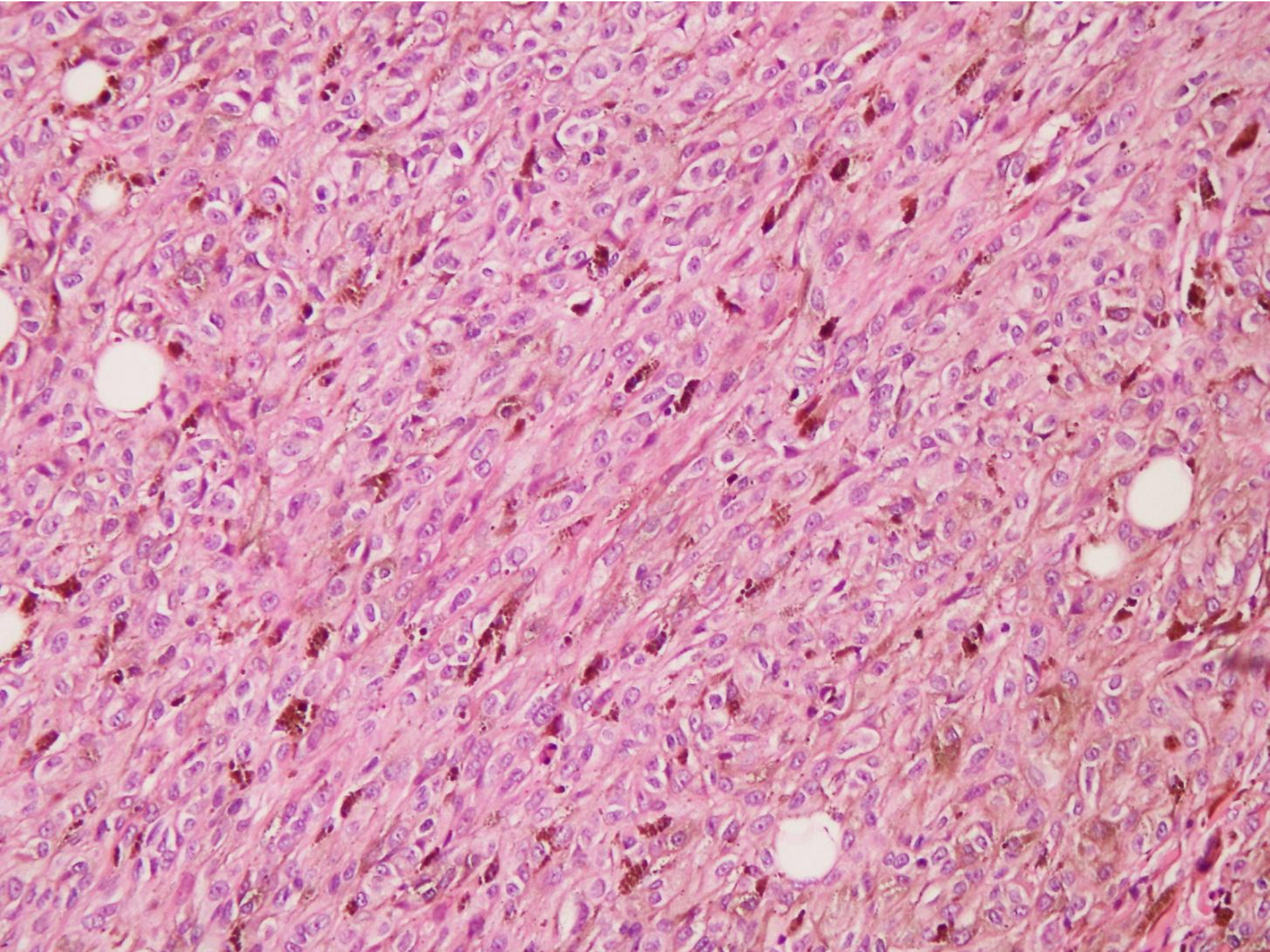




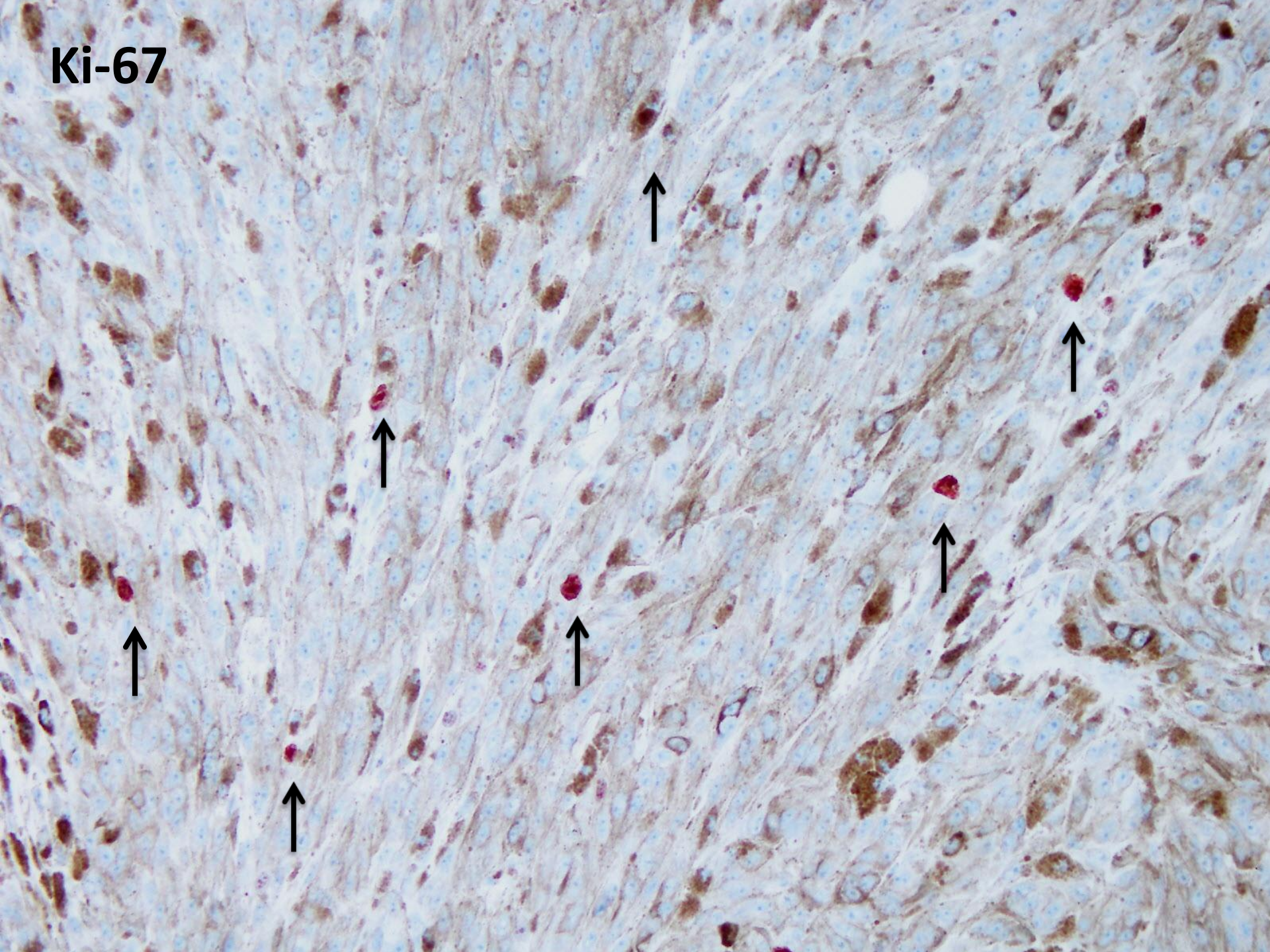


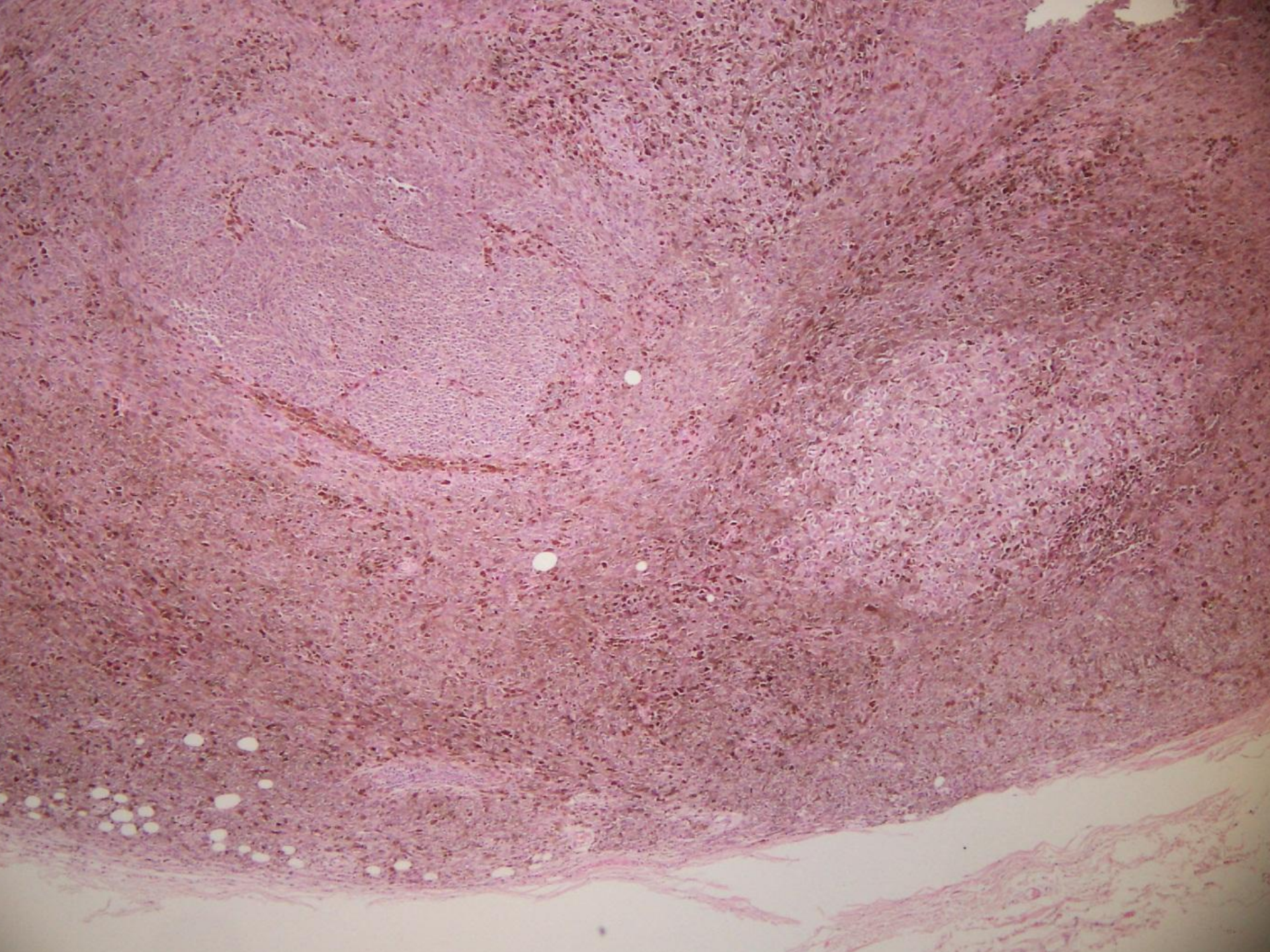


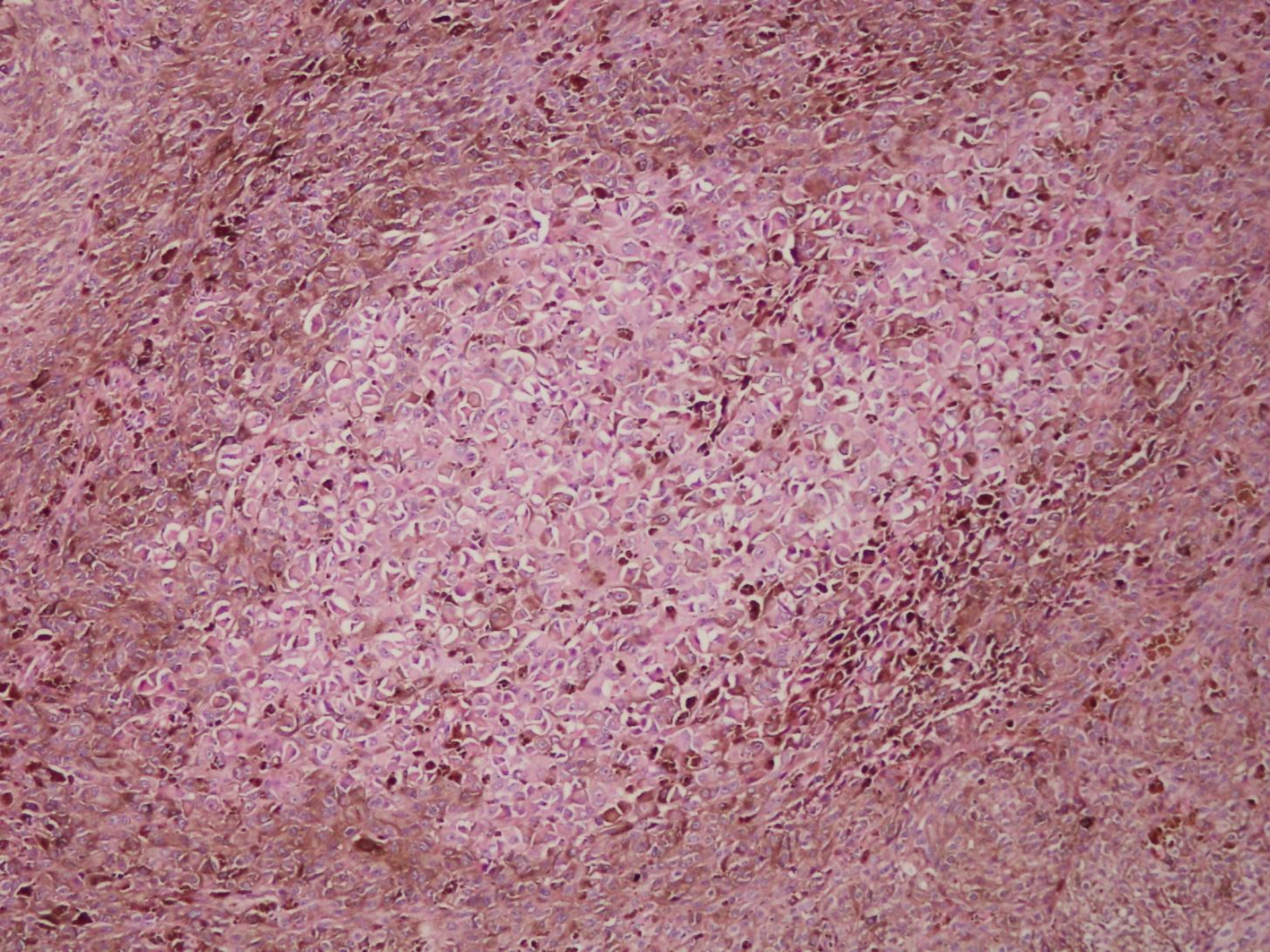


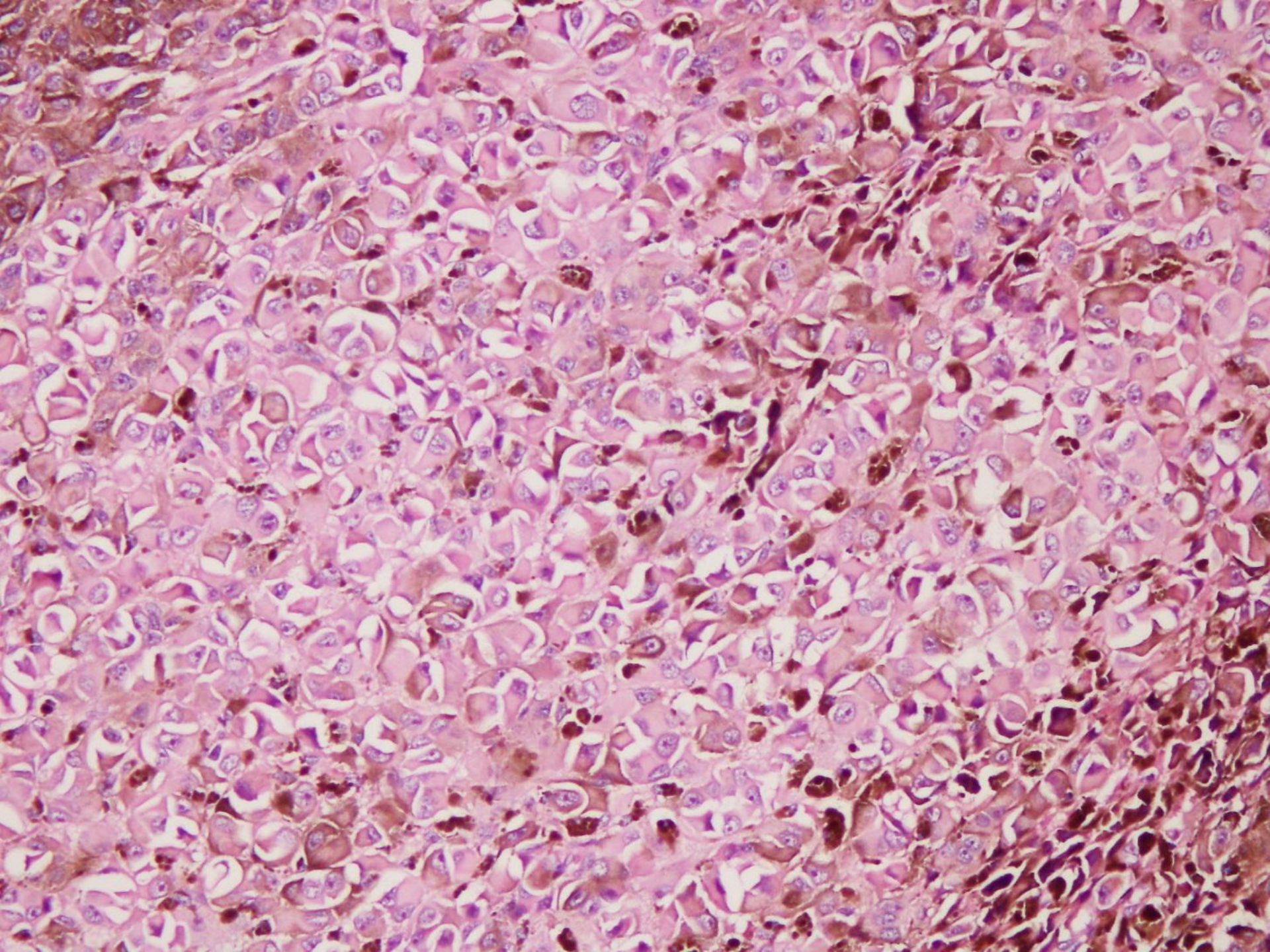


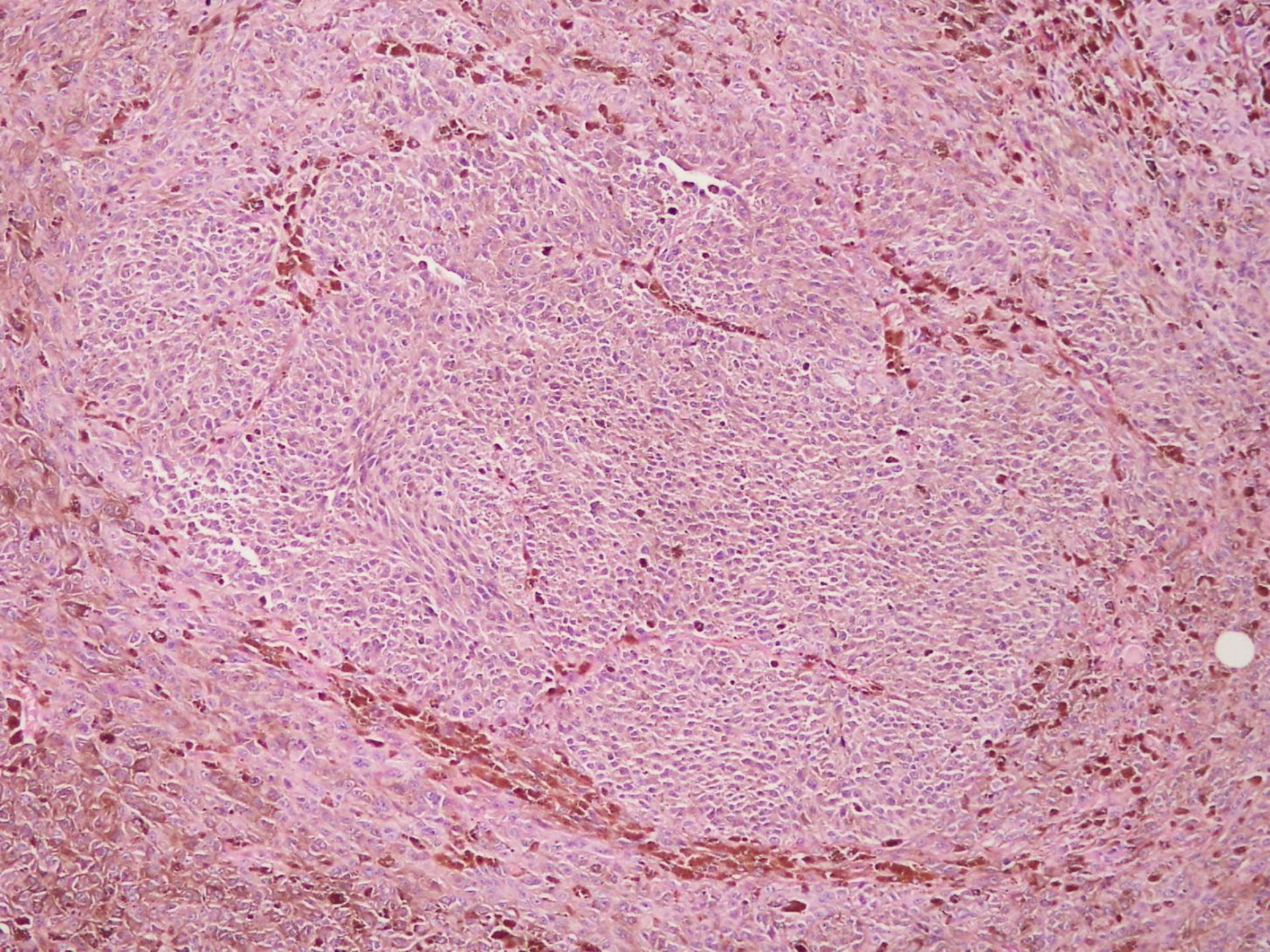
Ki-67

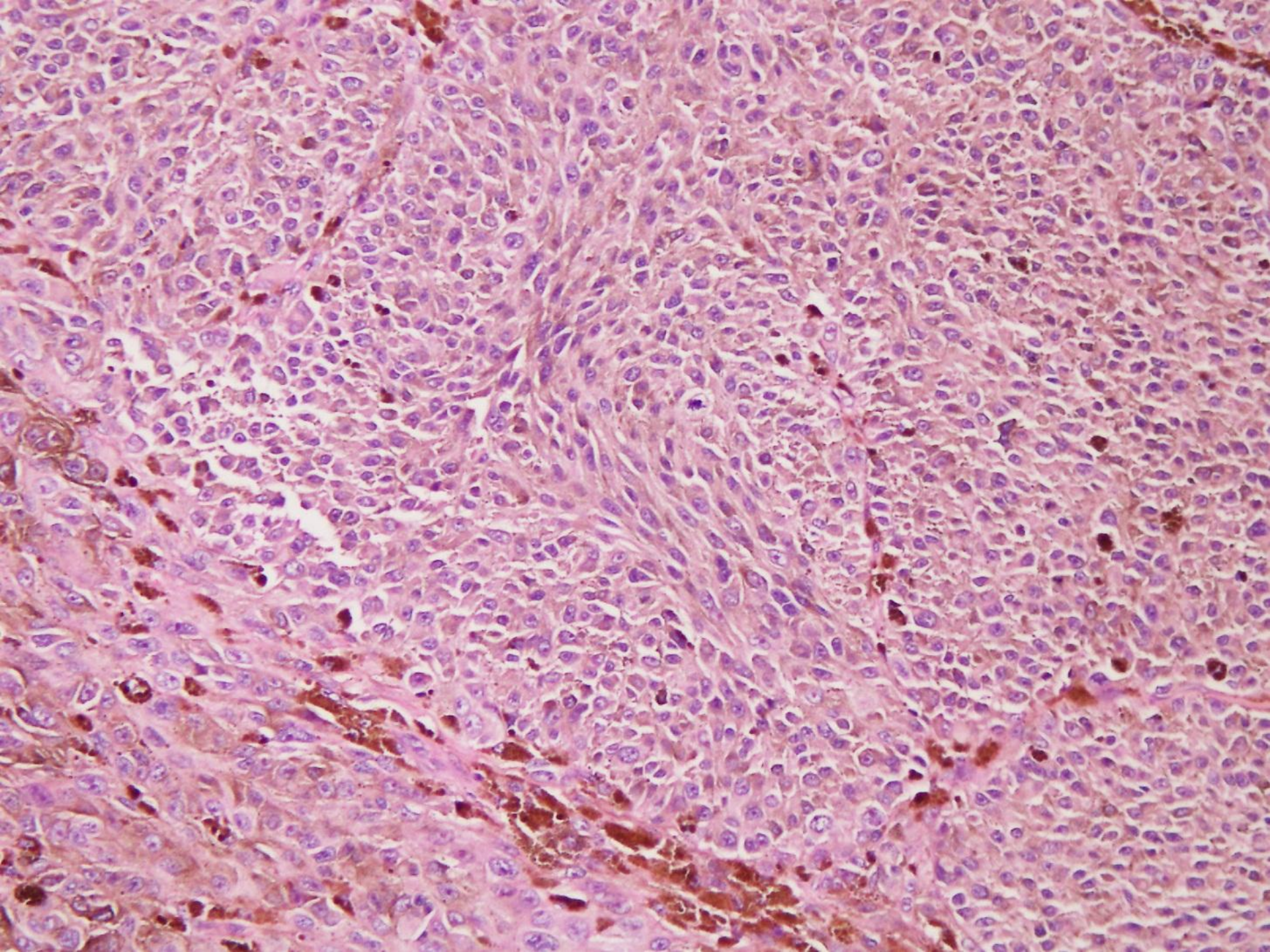


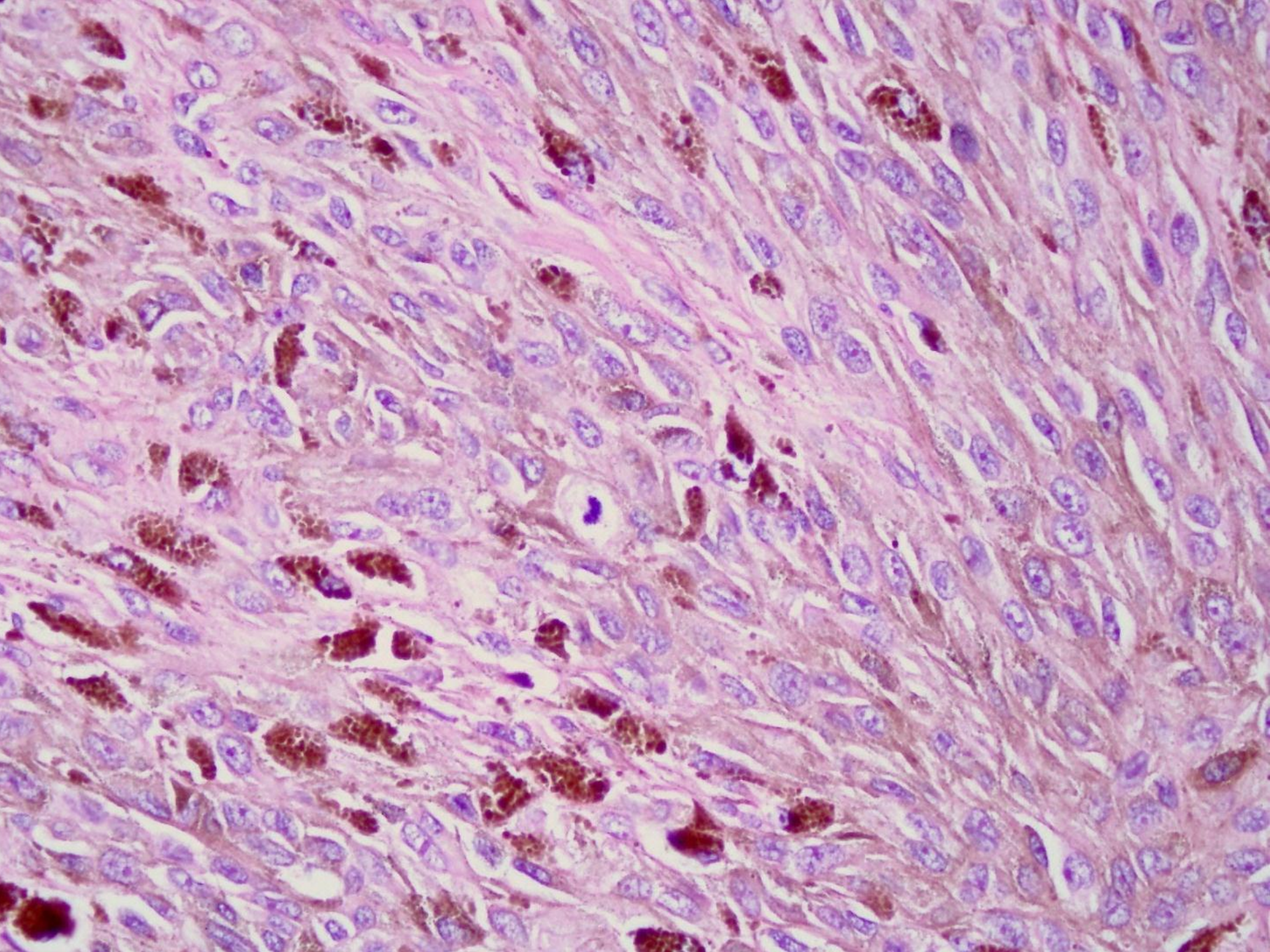




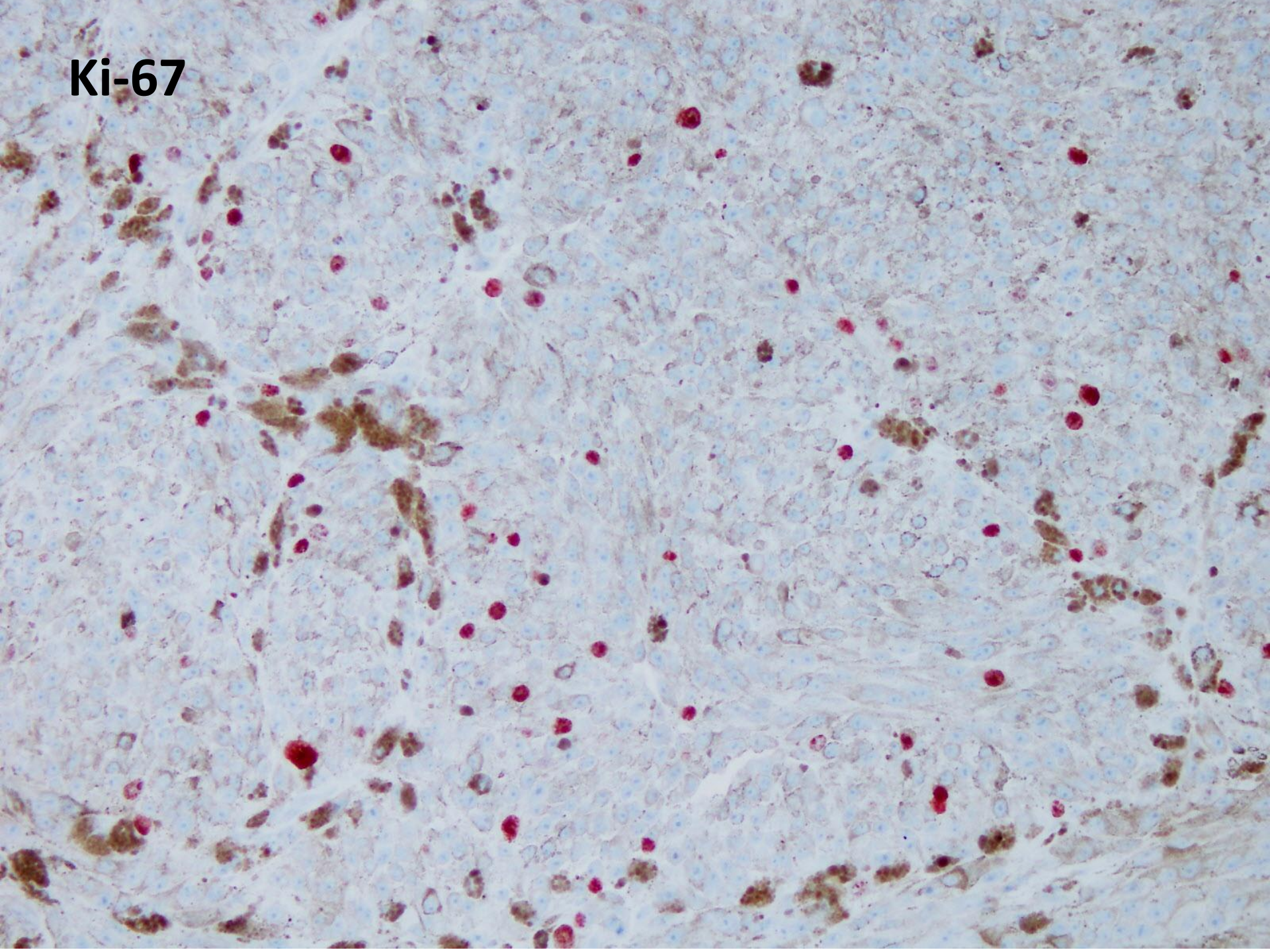


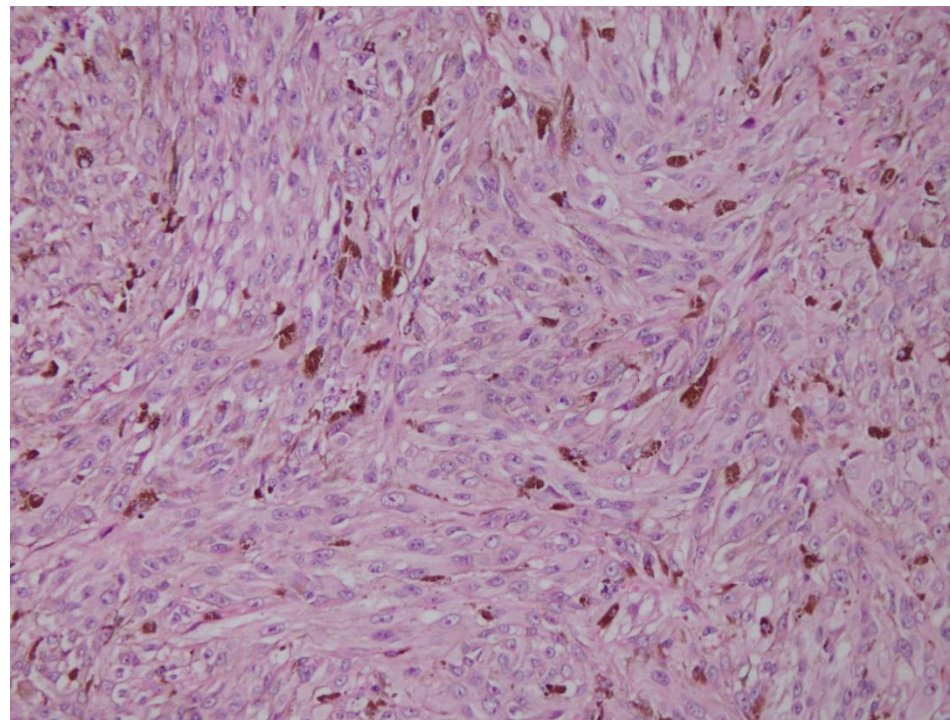
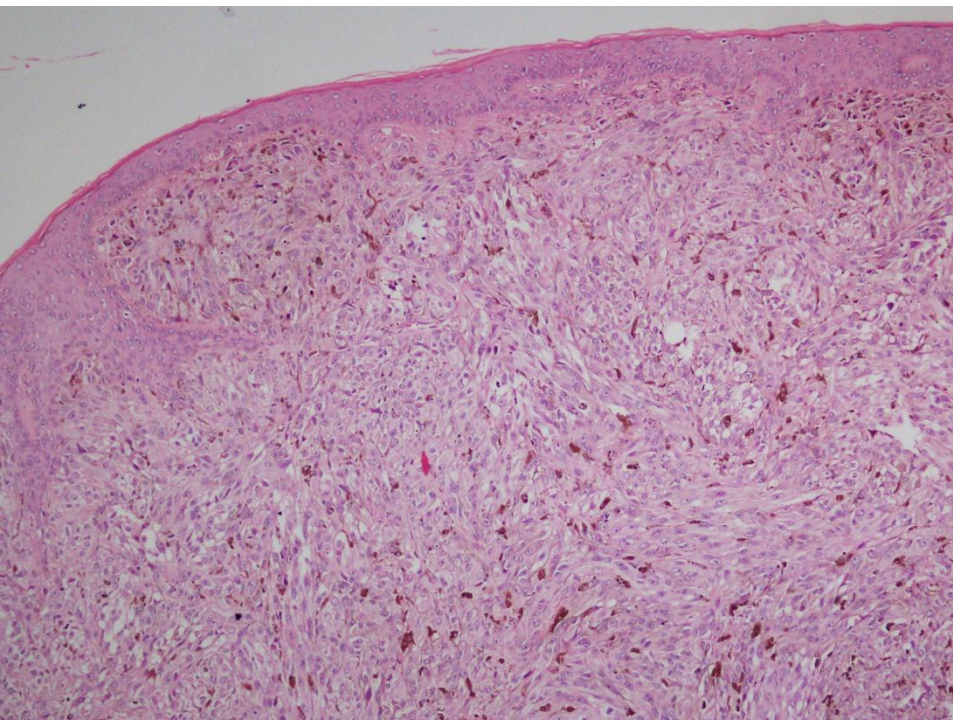
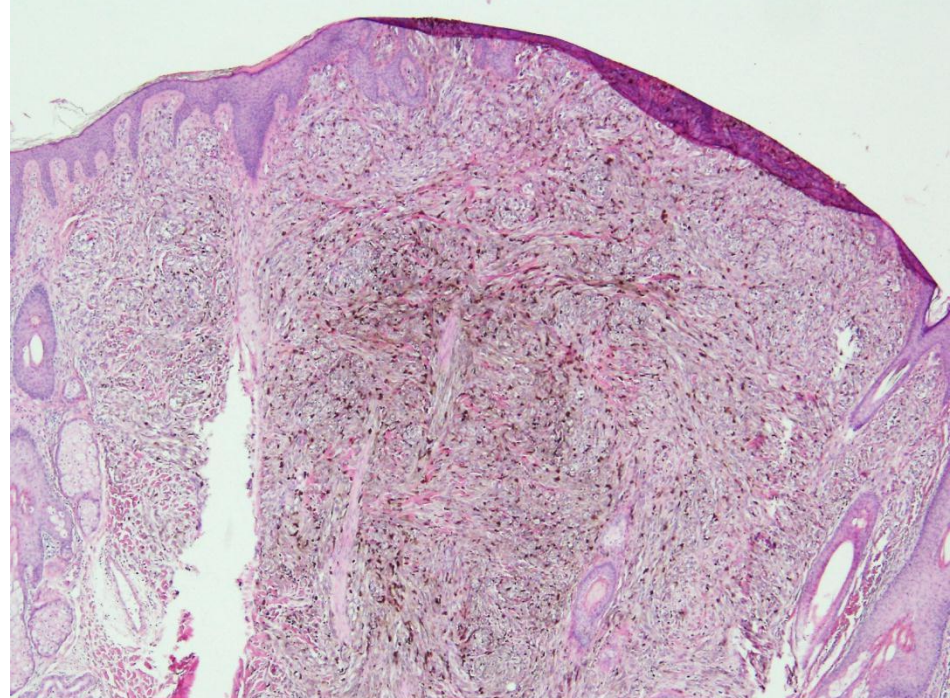
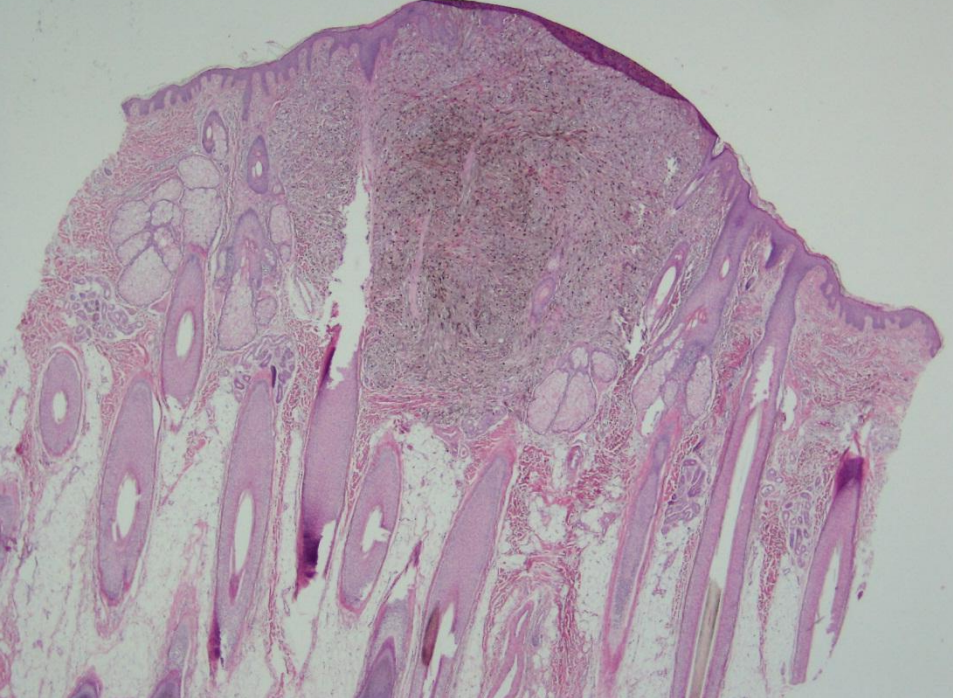




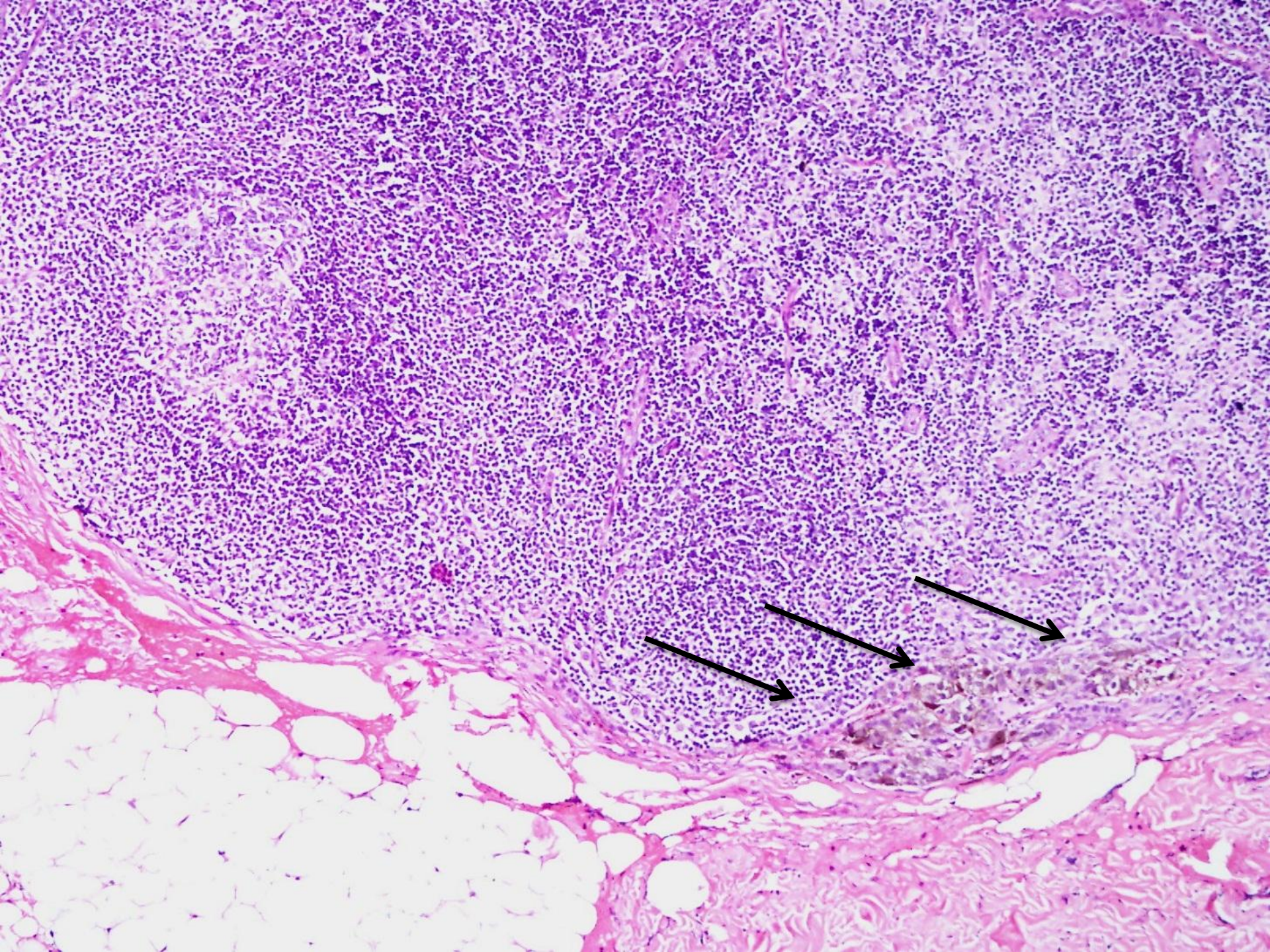


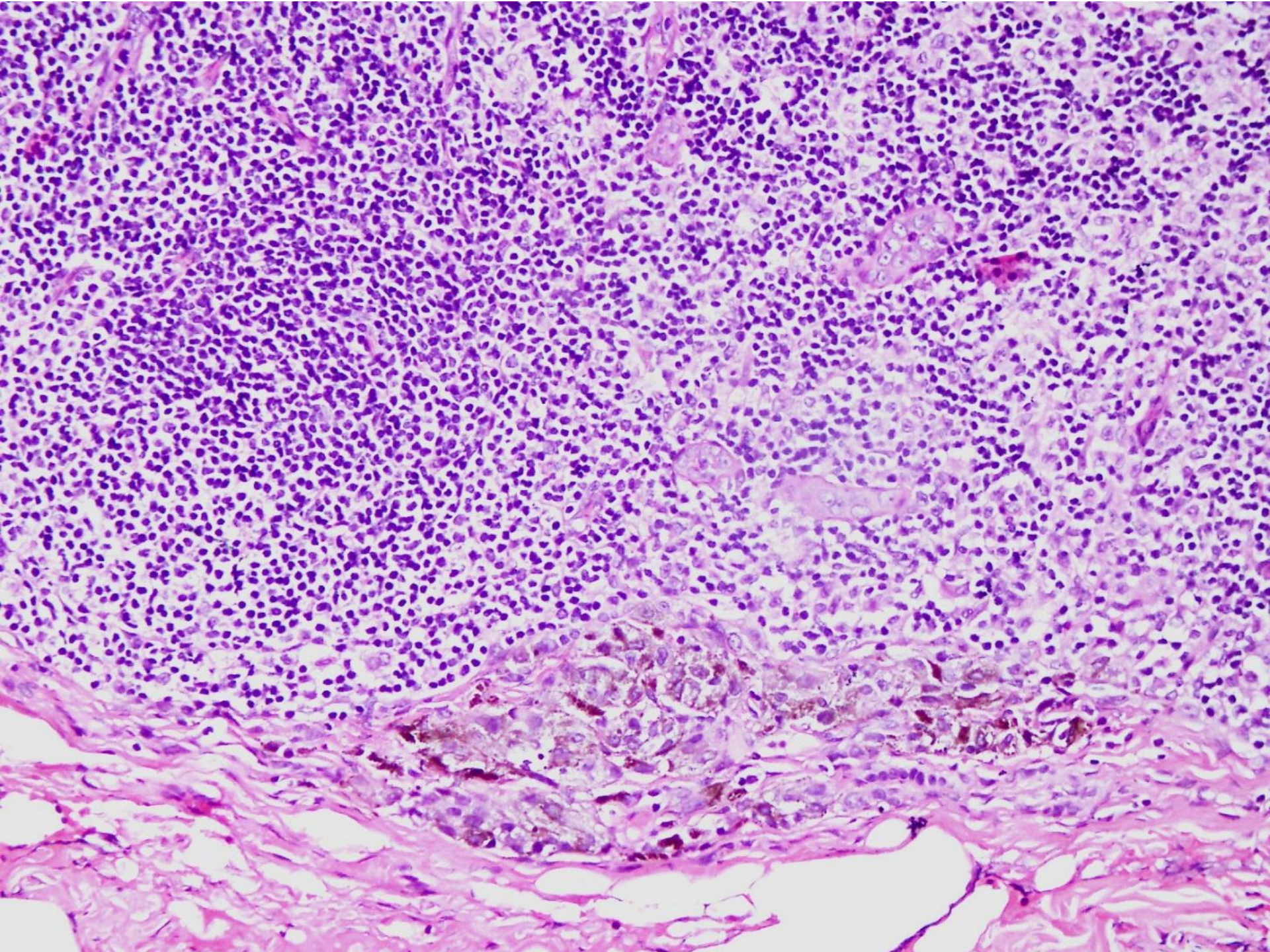
Ki-67

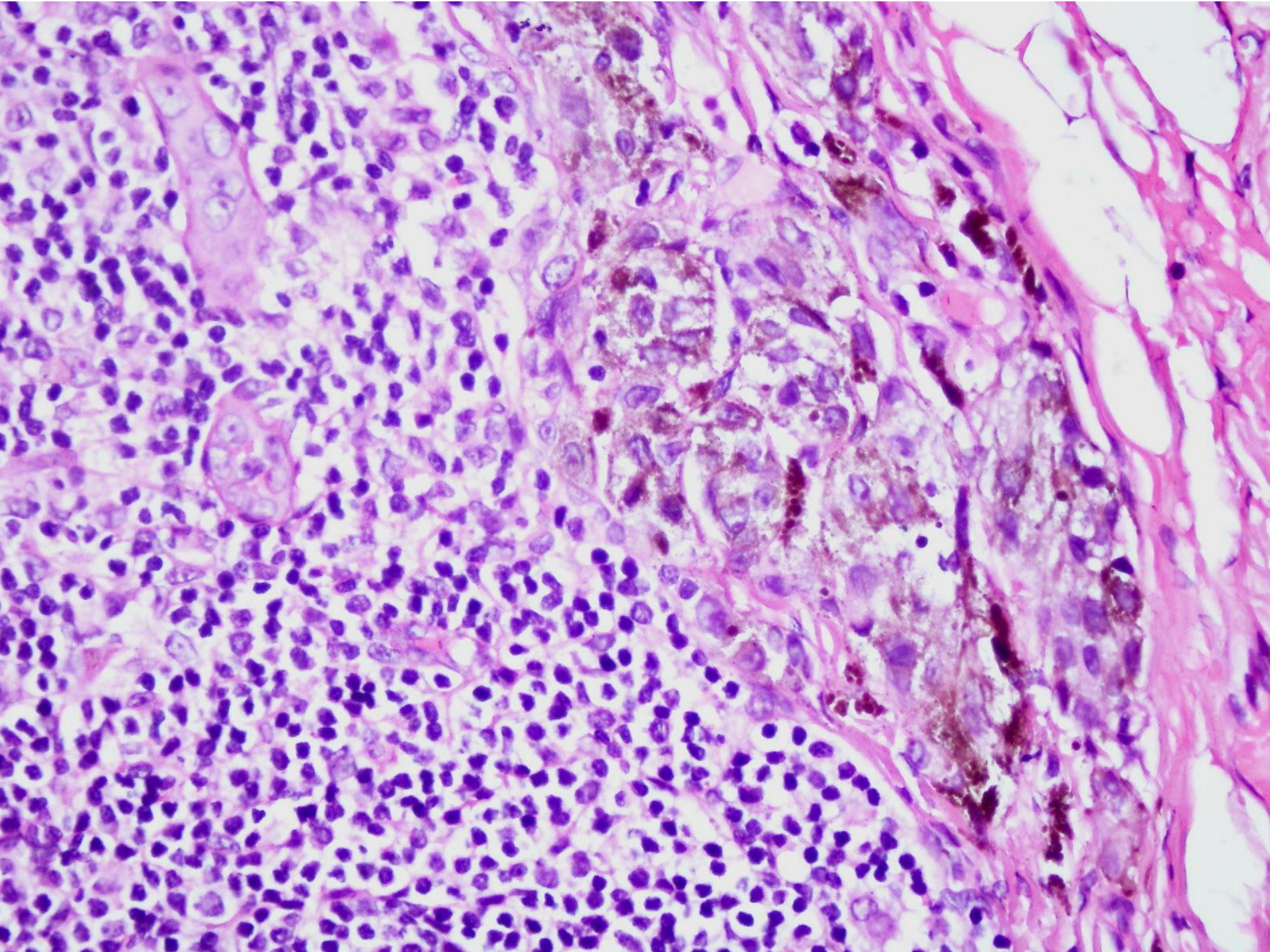




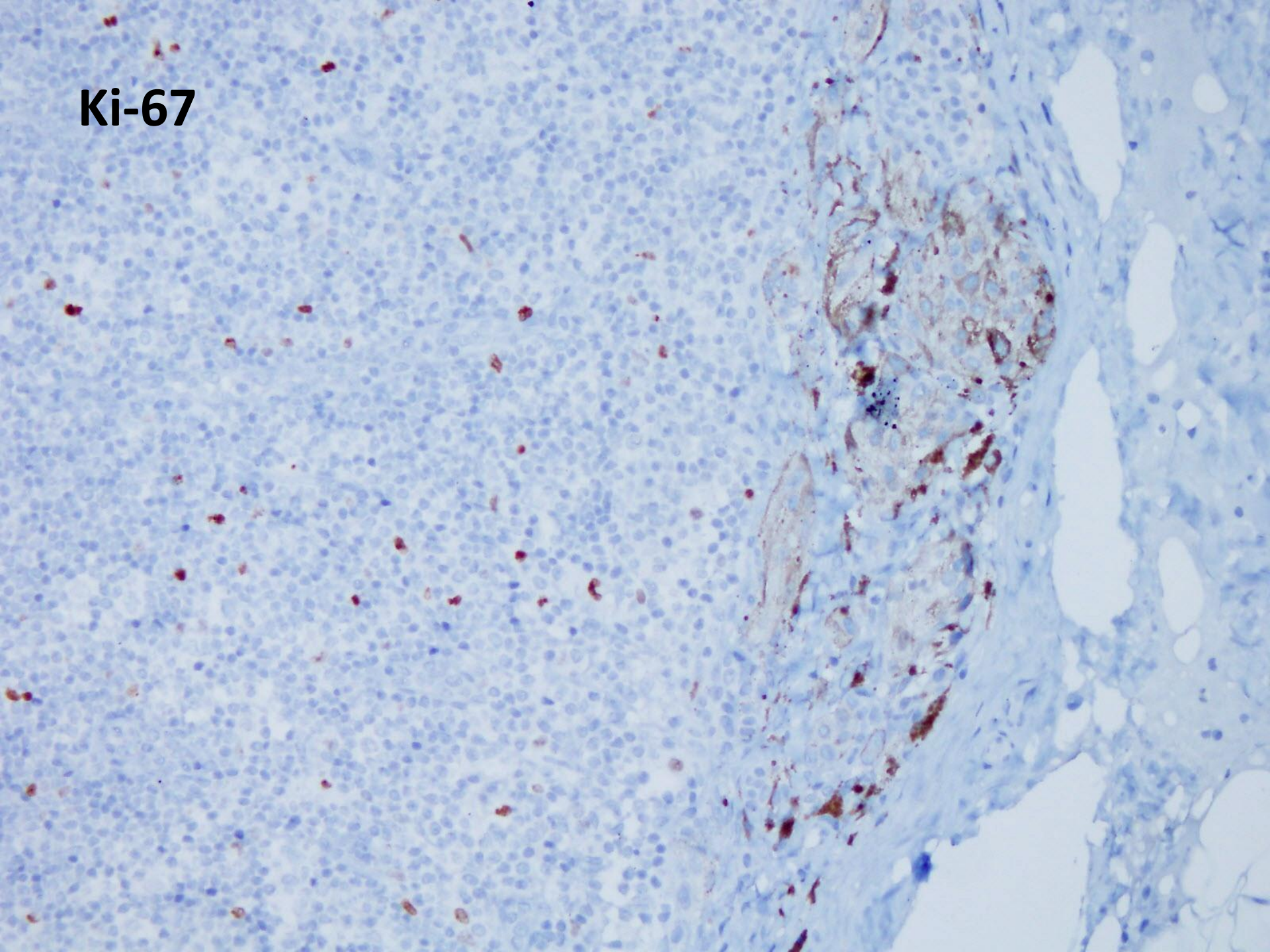
- 18 yaşında, saçlı deride, 2,5 cm boyutlarında
- yoğun pigmentli, solid gelişim gösteren, aşikar atipi bulguları olmayan, proliferatif aktivitesi düşük melanositik tümör







Ki-67



TANI

- Hücresel mavi nevus bulguları olan malignite potansiyeli belirsiz melanositik tümör
- Hücresel mavi nevus bulguları olan düşük malignite potansiyelli melanositik tümör
- Hücresel mavi nevus bulguları olan melanom
- Blue nevus benzeri melanom
- Atipik hücresel mavi nevus/tümör

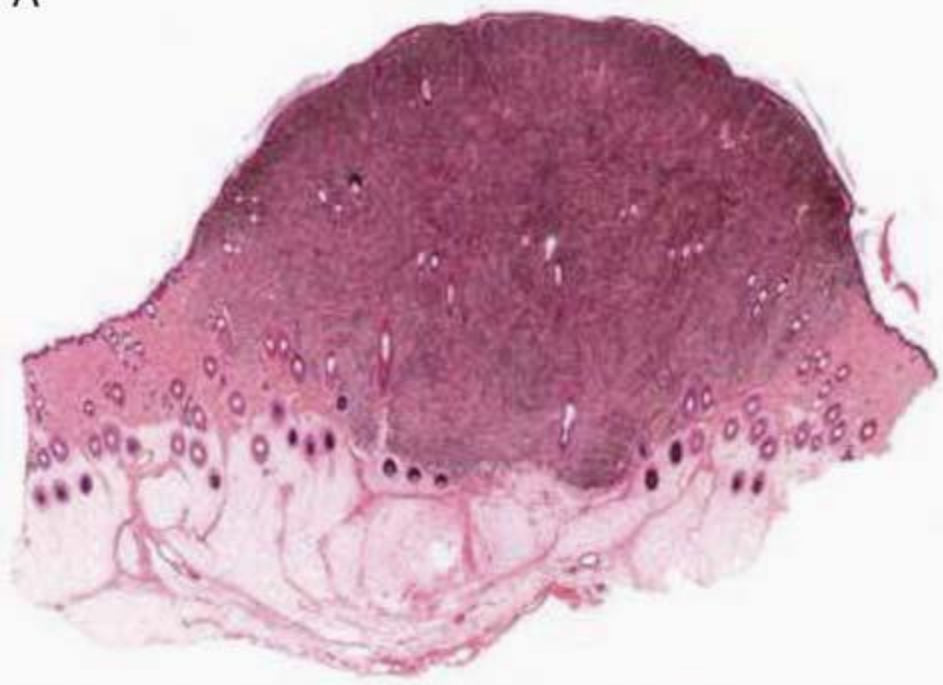
- Cerroni L et al
- Melanocytic Tumors of Uncertain Malignant Potential Results of a Tutorial Held at the XXIX Symposium of the International Society of Dermatopathology in Graz, October 2008
- Am J Surg Pathol 2010;34:314–326

Kriterler

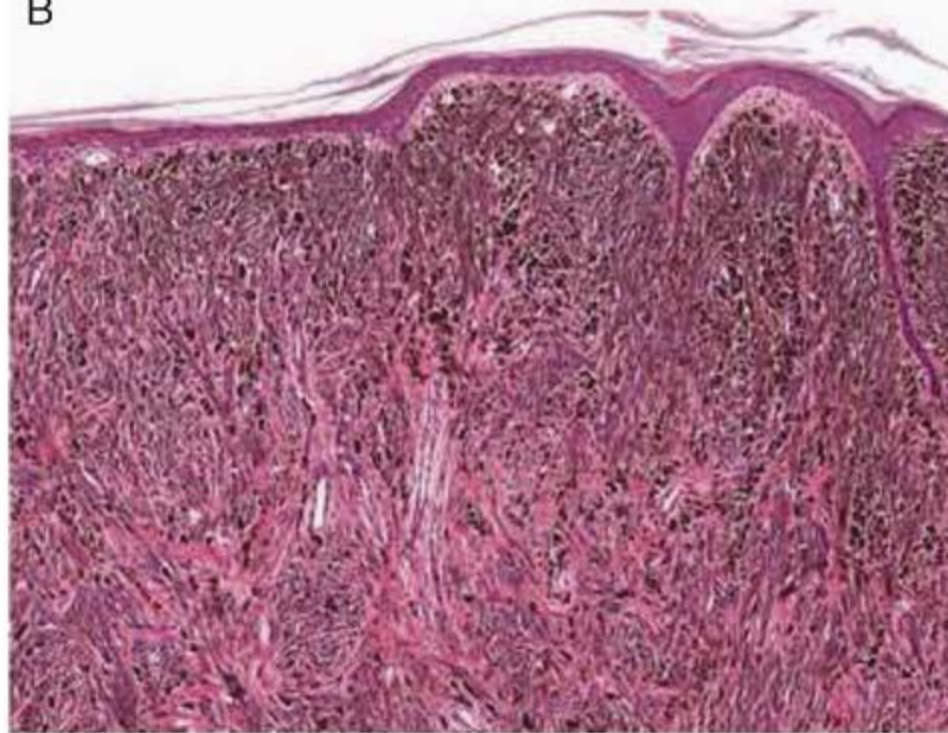
- Favorable (prognozu iyi) grup: Beş yıldan fazla klinik takipte metastaz yok
- Unfavorable (prognozu kötü) grup: Tümöre bağlı ex ve/veya visseral – lenf nodu metastazı
- Borderline grup: Lenf nodunda $\leq 0,2$ mm lik deposit

- Malignite potansiyeli belirsiz melanositik tümör (MELTUMP) diye bir grup vardır
- Biyolojik davranışı melanom ve nevustan farklı olabilir (Düşük malignite potansiyelli melanositik tümör ?)
- Terminoloji, kriterler, klasifikasyon belirsiz

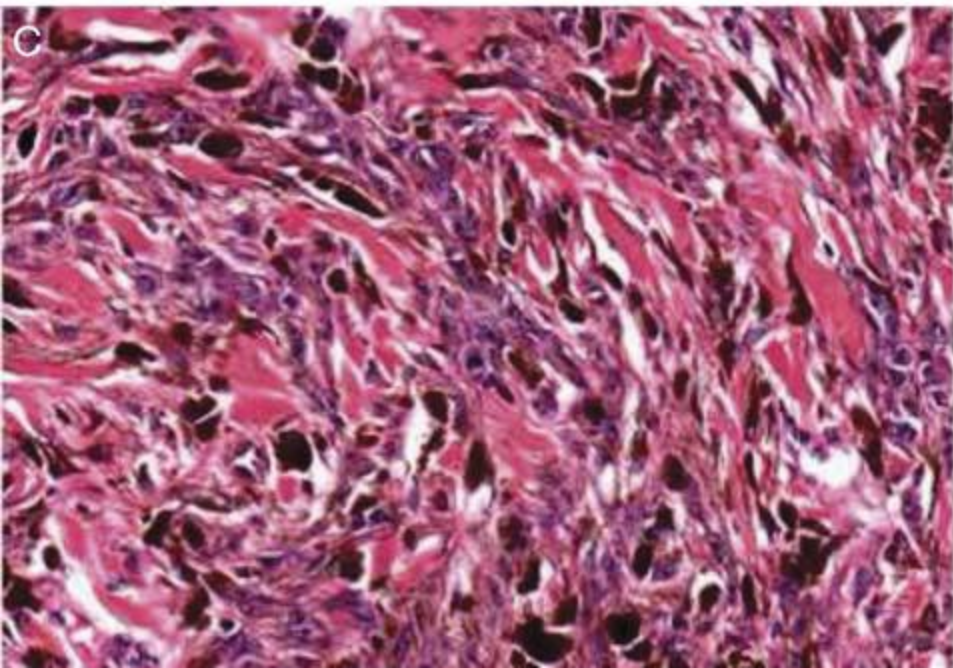
A



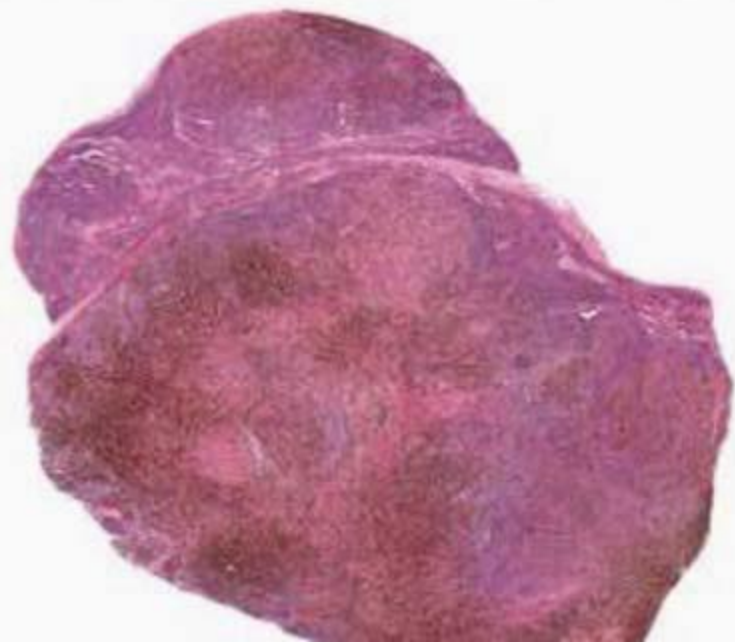
B



C

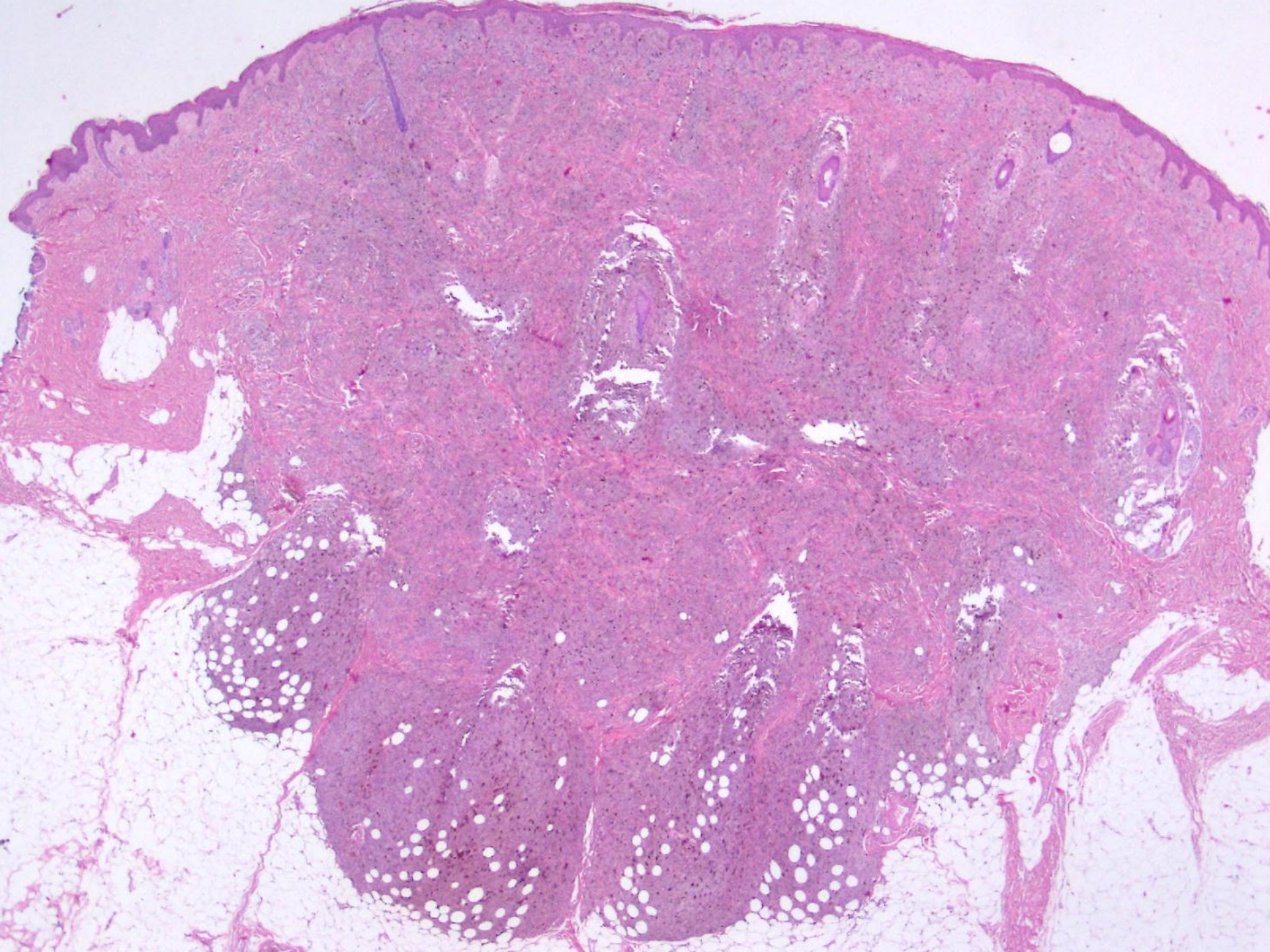


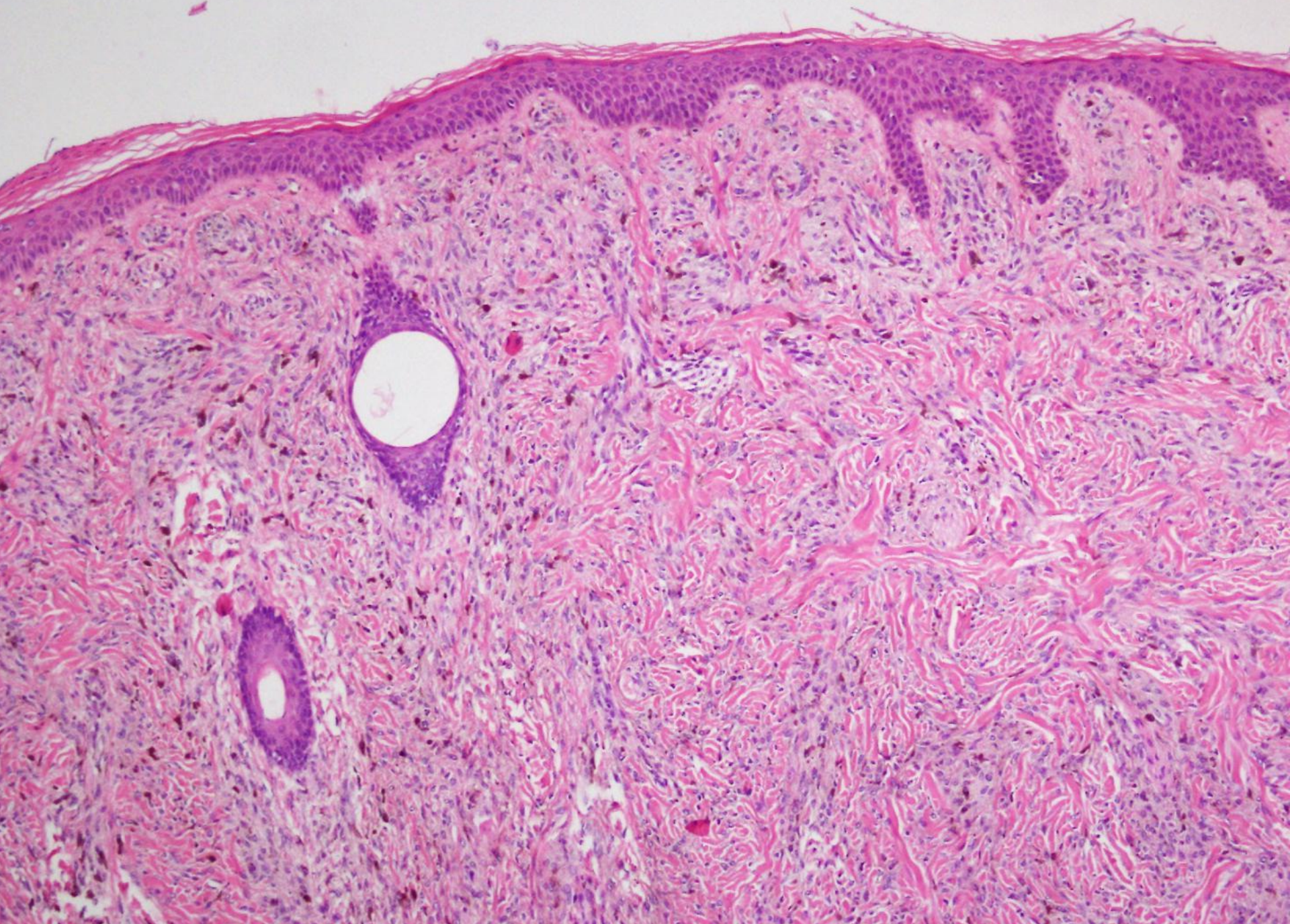
D

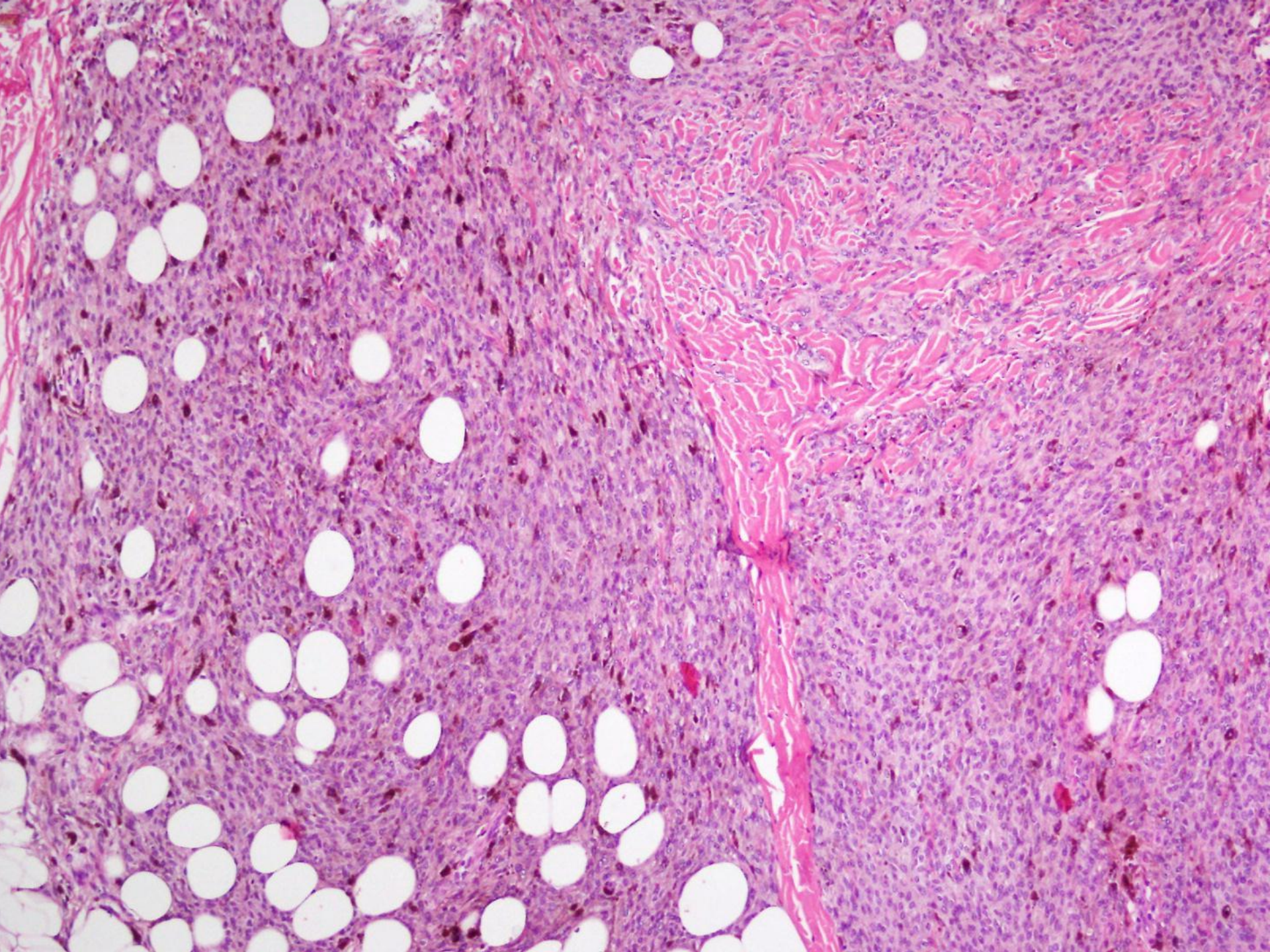


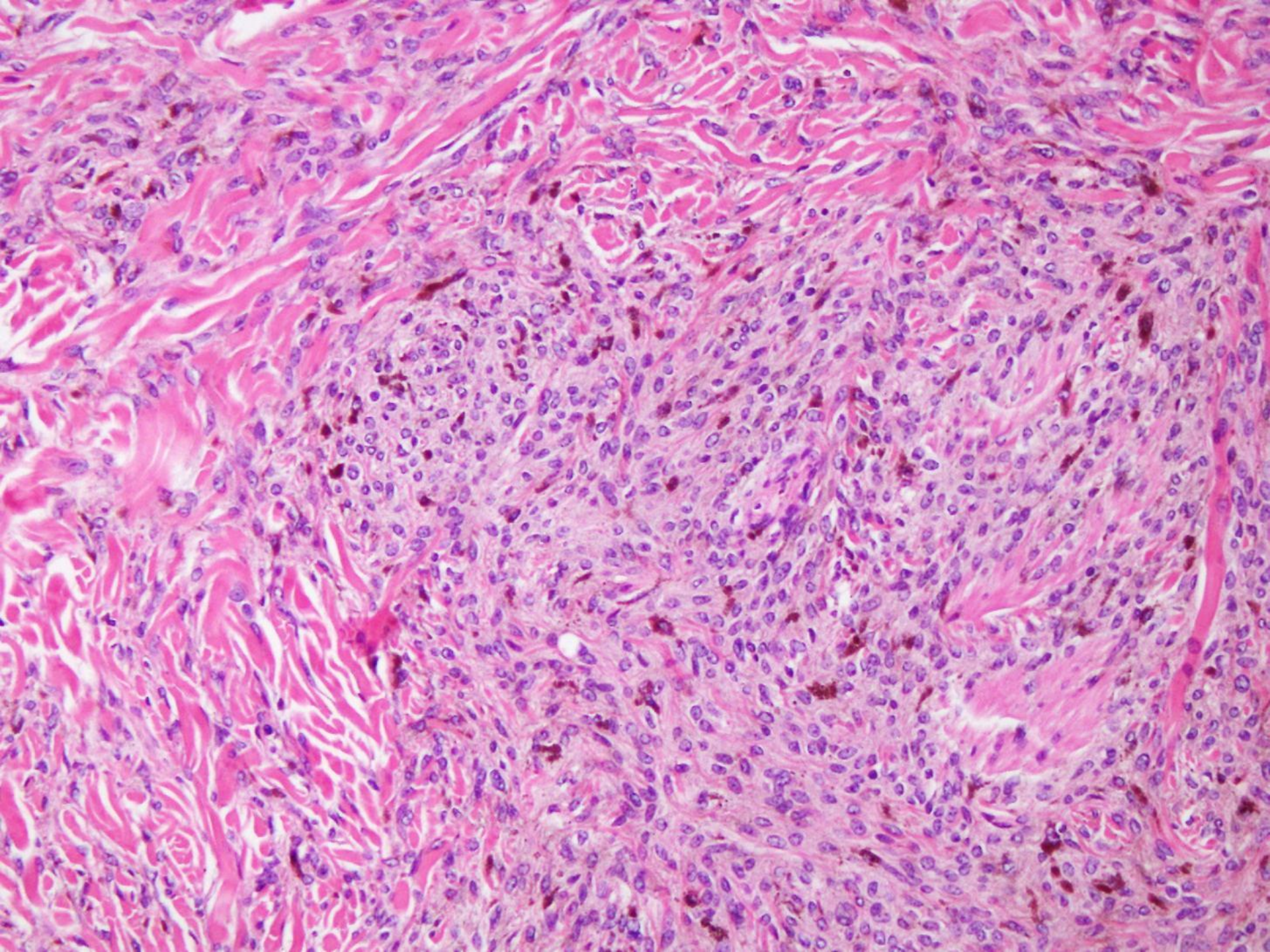
Atipik hücresel mavi nevus

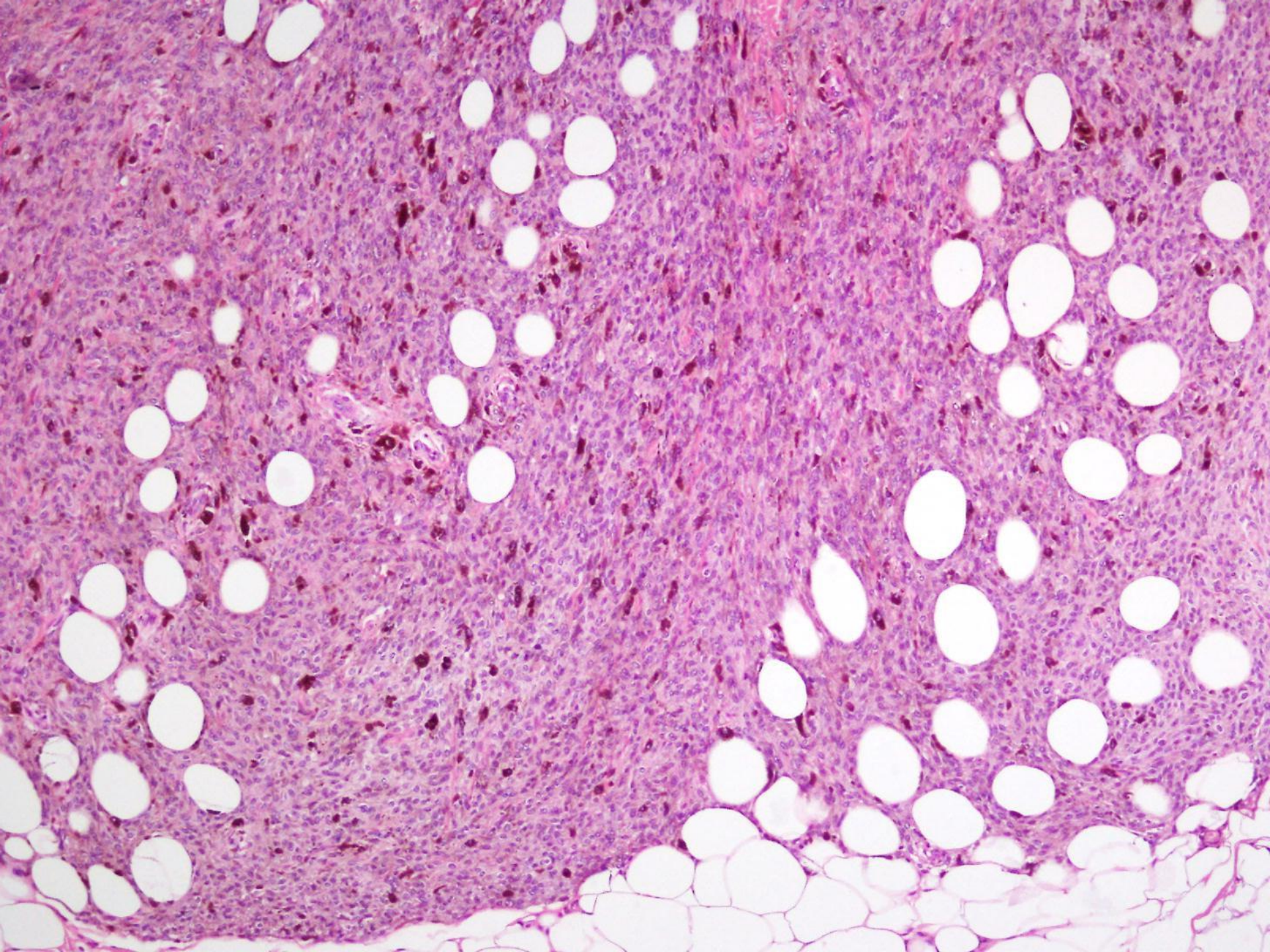
- Mitotik aktivite : mm^2 de $\leq 2-3$
- Asimetri
- Ülser
- İnfiltratif gelişim
- Büyük boyut ($> 3-5$ cm)
- Konfluent gelişim
- Hücresel atipi



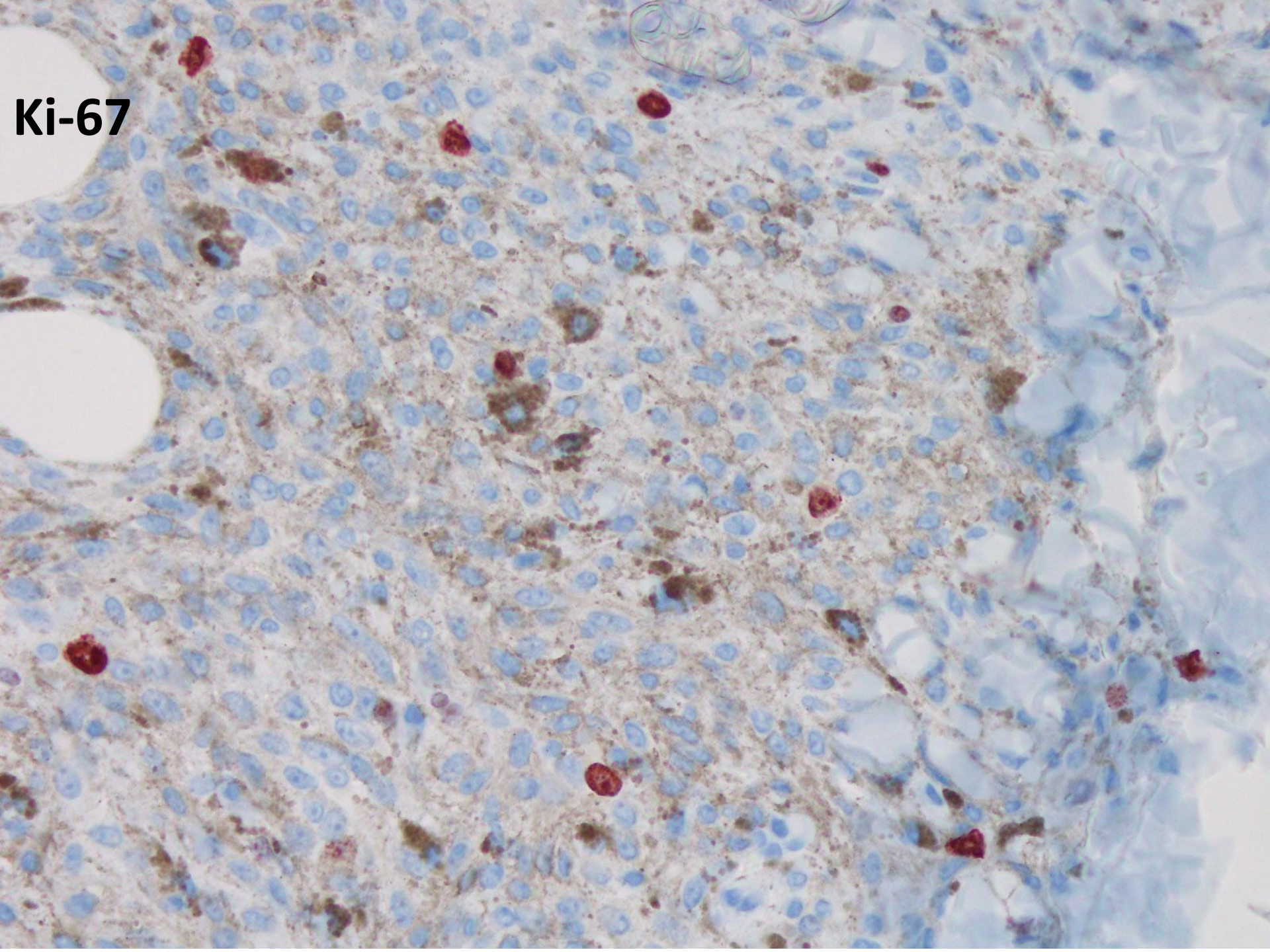


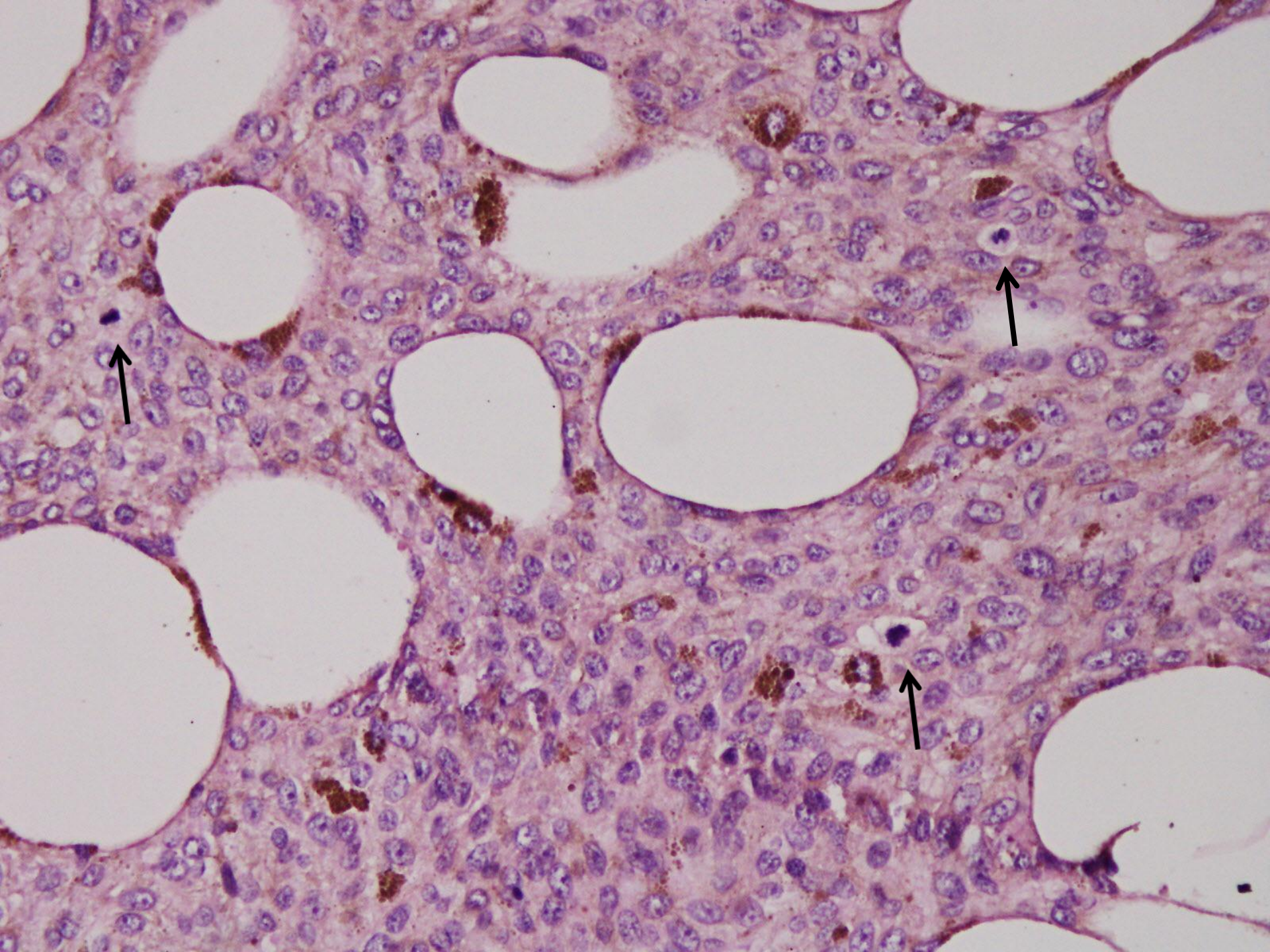


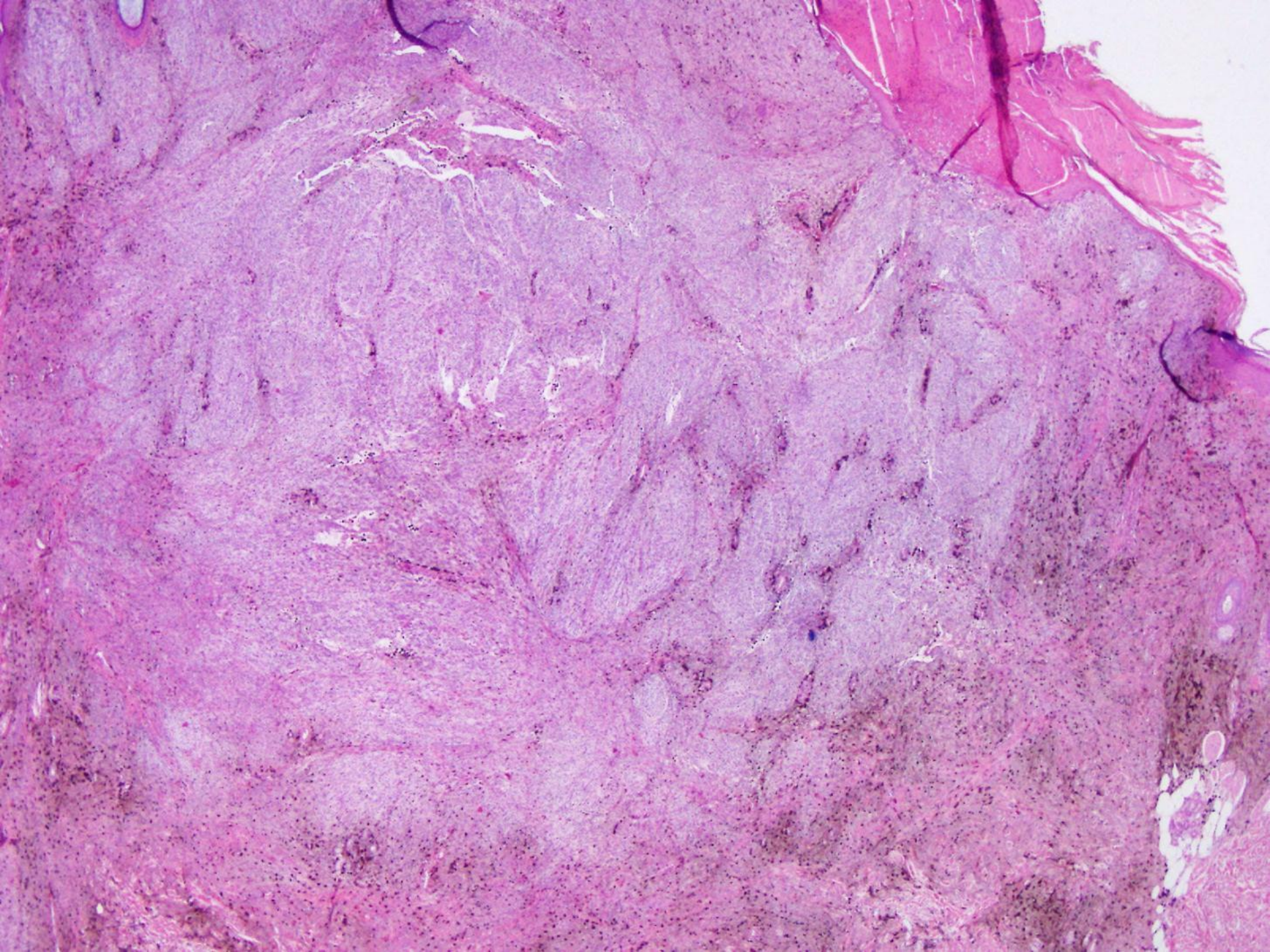


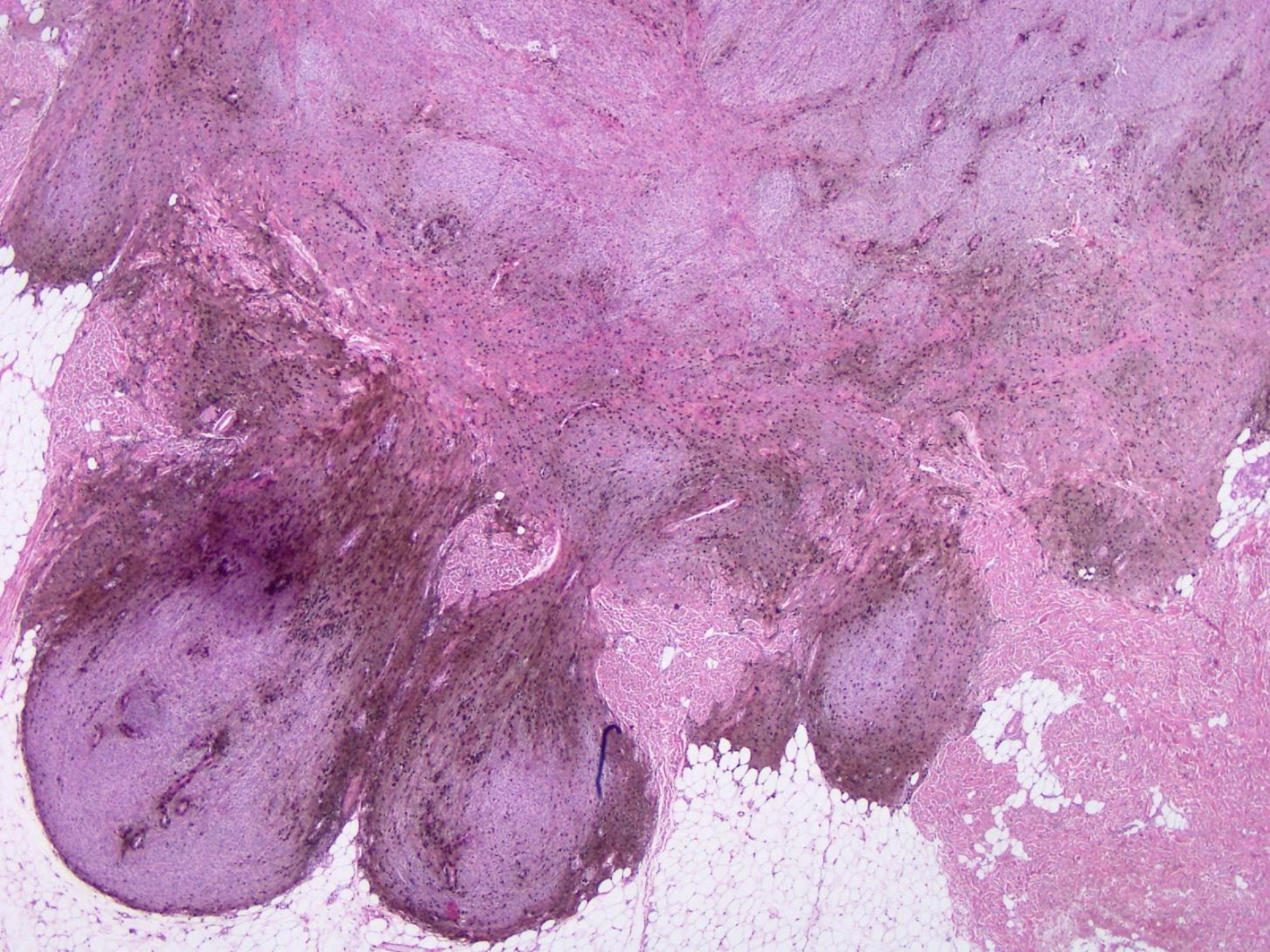


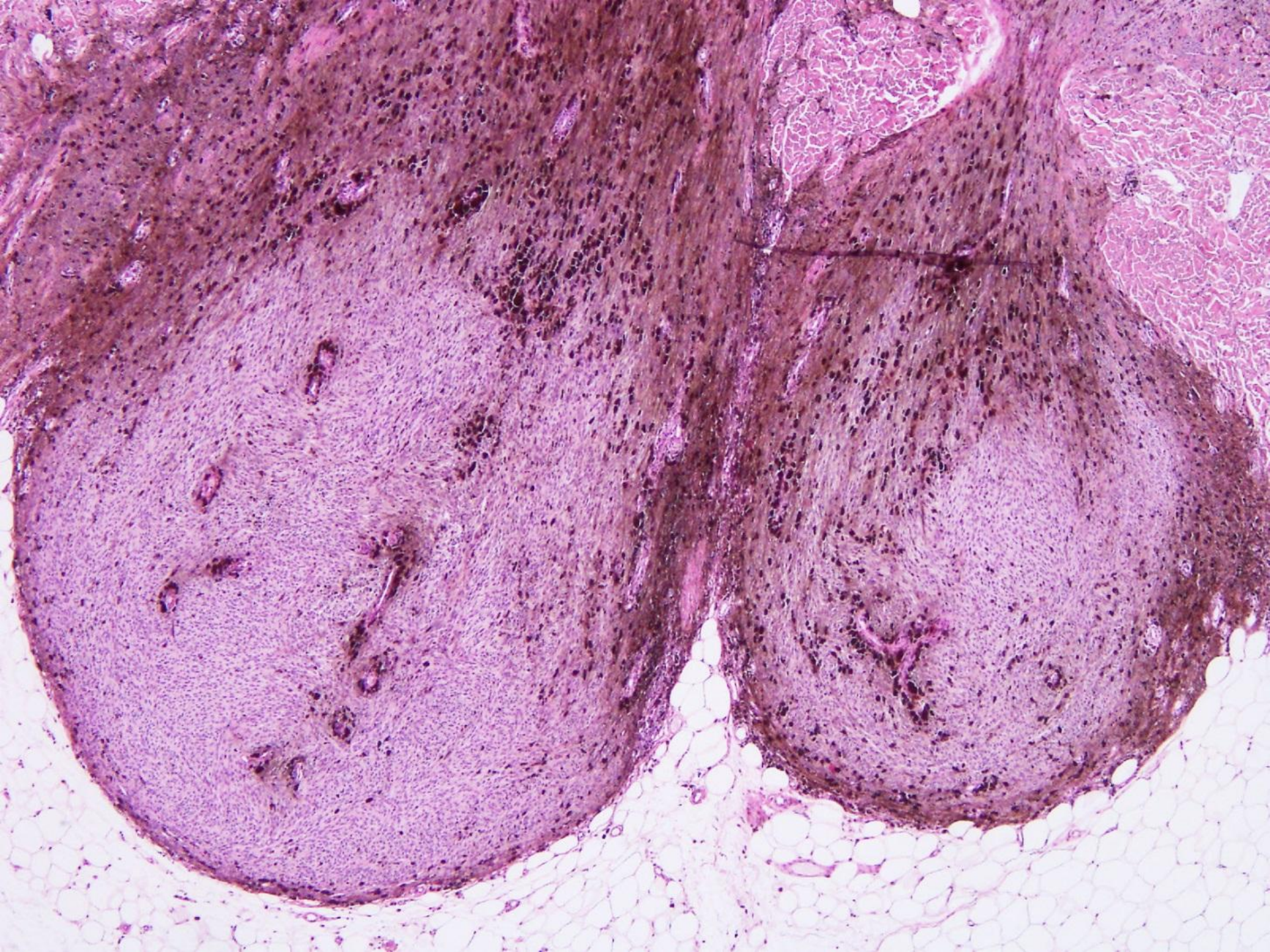
Ki-67

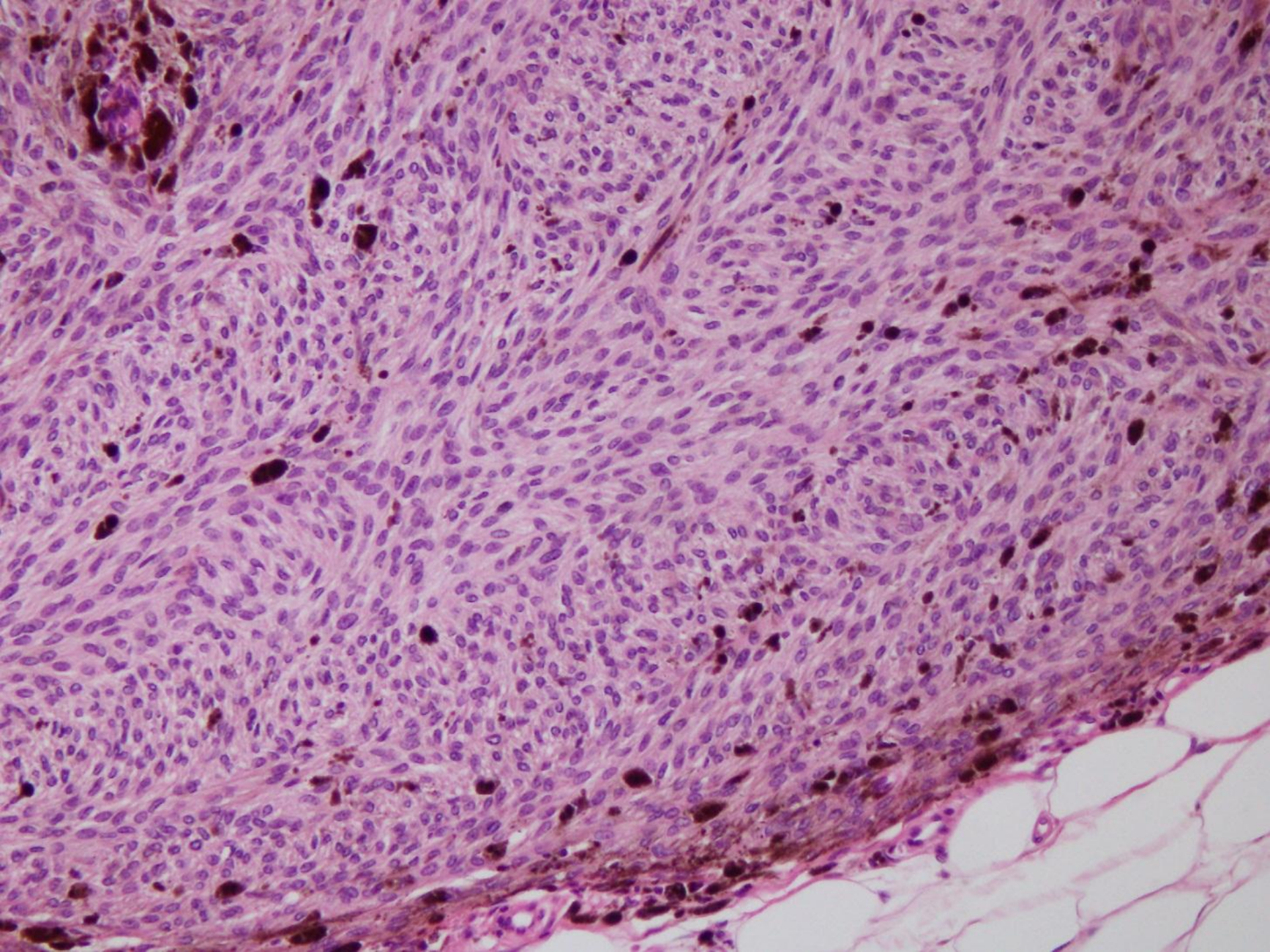


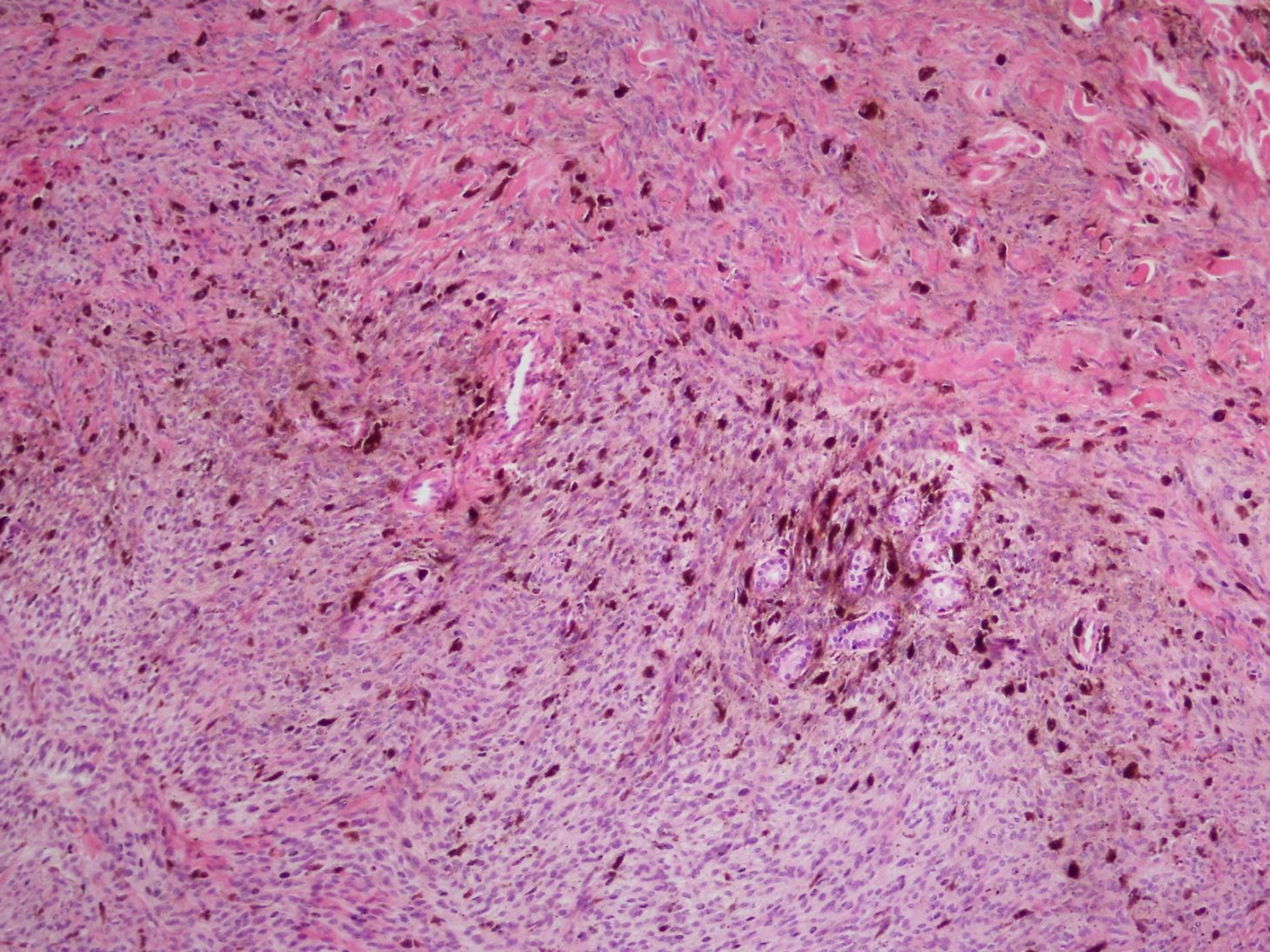


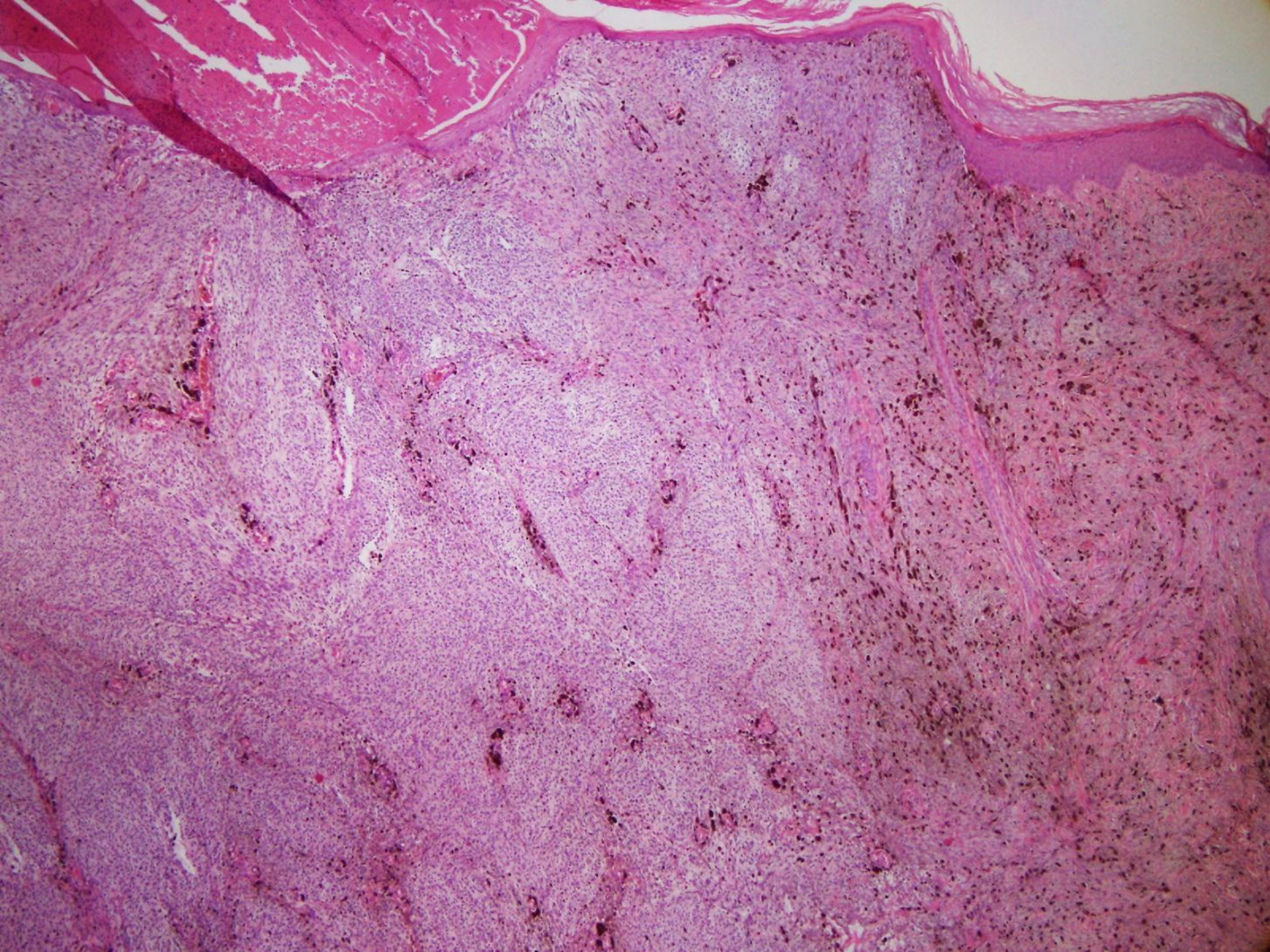

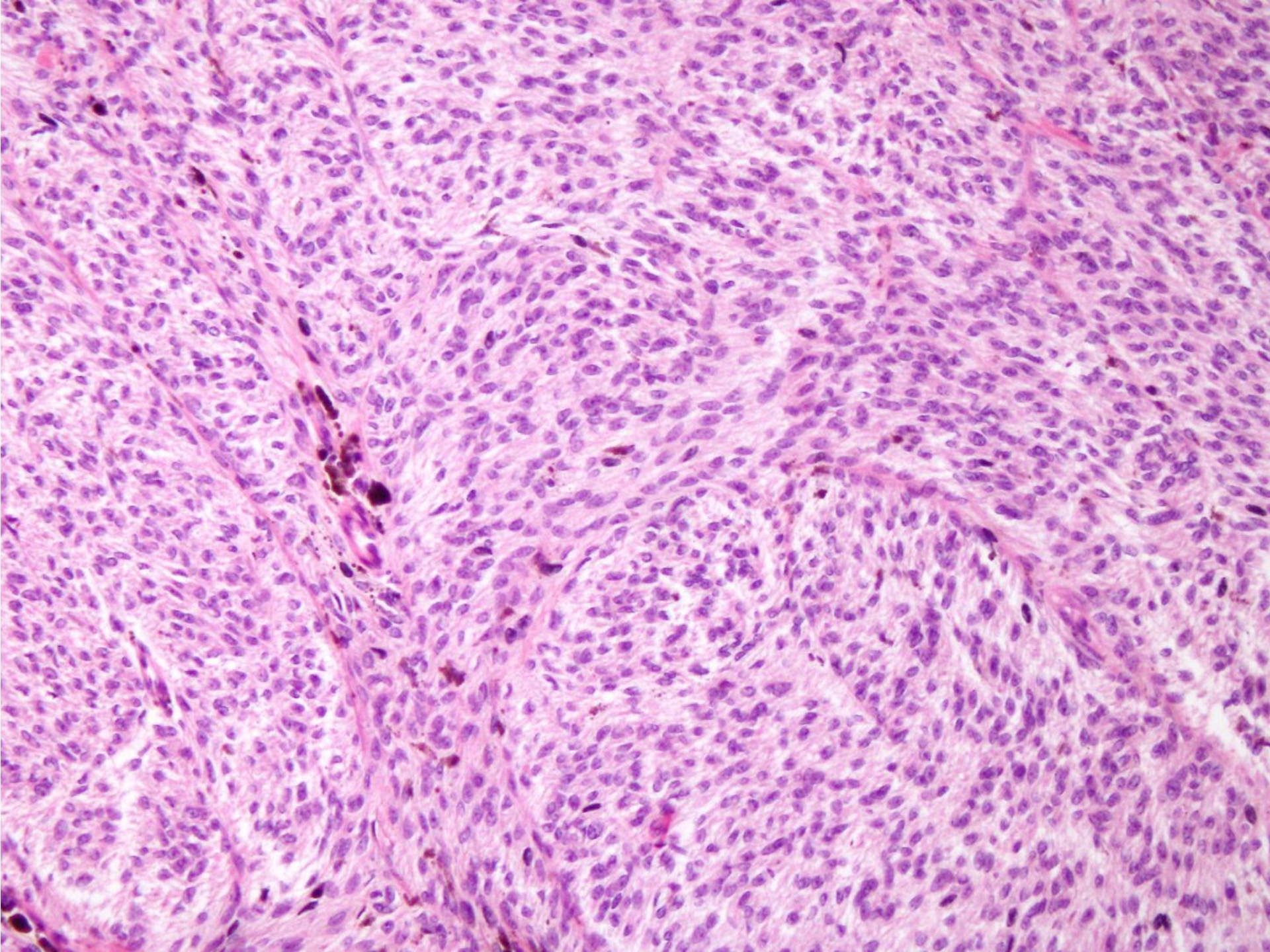












Malign blue nevus ?

- Eksize edilen blue nevus zemininde gelişmiş melanom
- Melanom + rezidüel hücresel mavi nevus
- Blue nevus benzeri melanom
- Hücresel mavineusa sitolojik ve yapısal benzerlikler gösteren melanom



