

ENDOKRİN PATOLOJİ SLAYT SEMİNERİ

Dr.Yeşim Ertan

Ege Üniversitesi Tıp Fakültesi Patoloji ABD

21. Ulusal Patoloji Kongresi, 16-20 Kasım 2011, İZMİR

Olgu 1

- 16 yaşında kız hasta
 - Trunkal obesite
 - Ay dede yüzü
 - Mor stria
 - Amenore
 - Glukoz intoleransı
 - Osteoporoz

Cushing Sendromu

Tetkikler

- Deksametazon supresyon testine cevapsız
- 24 saatlik serbest üriner kortizol: 208 mg

- USG&BT&MRG

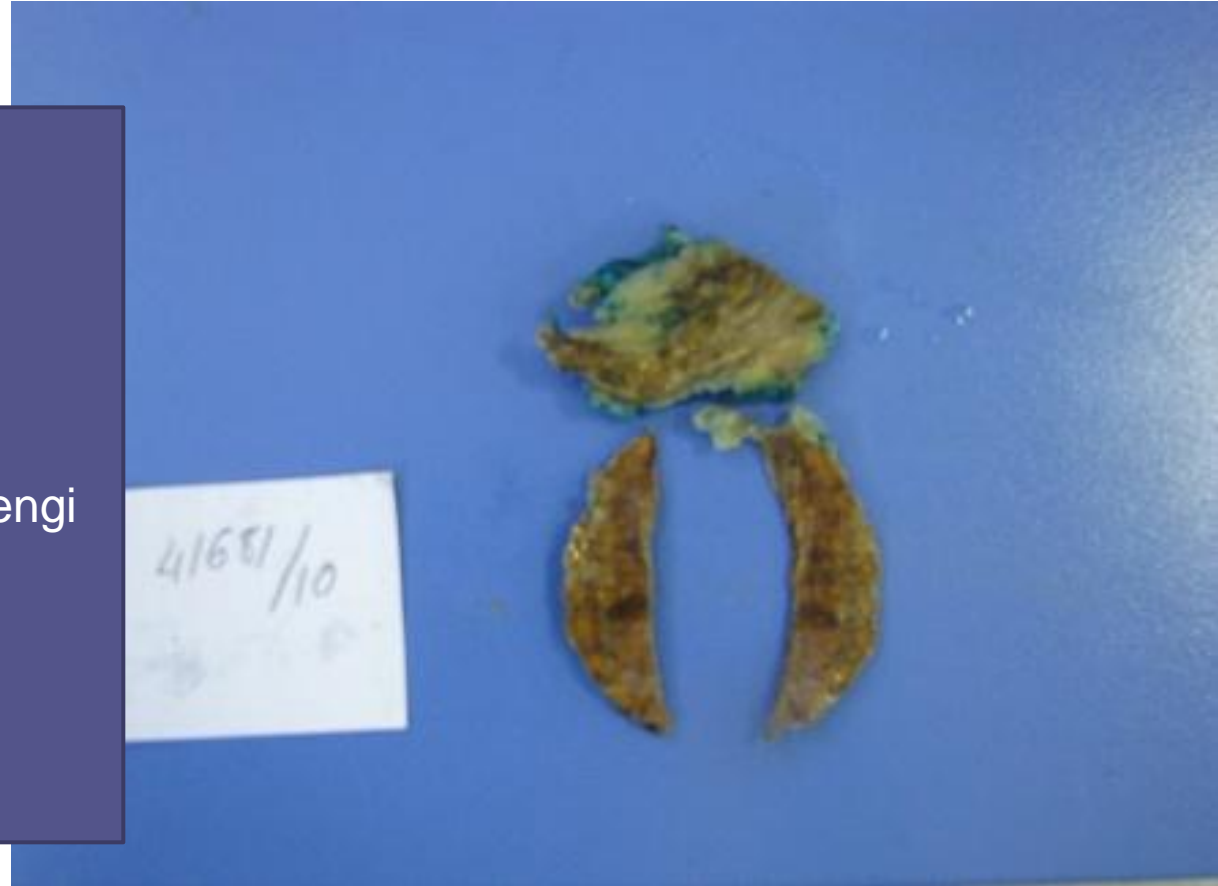Adrenal bezler normal, başka odak yok

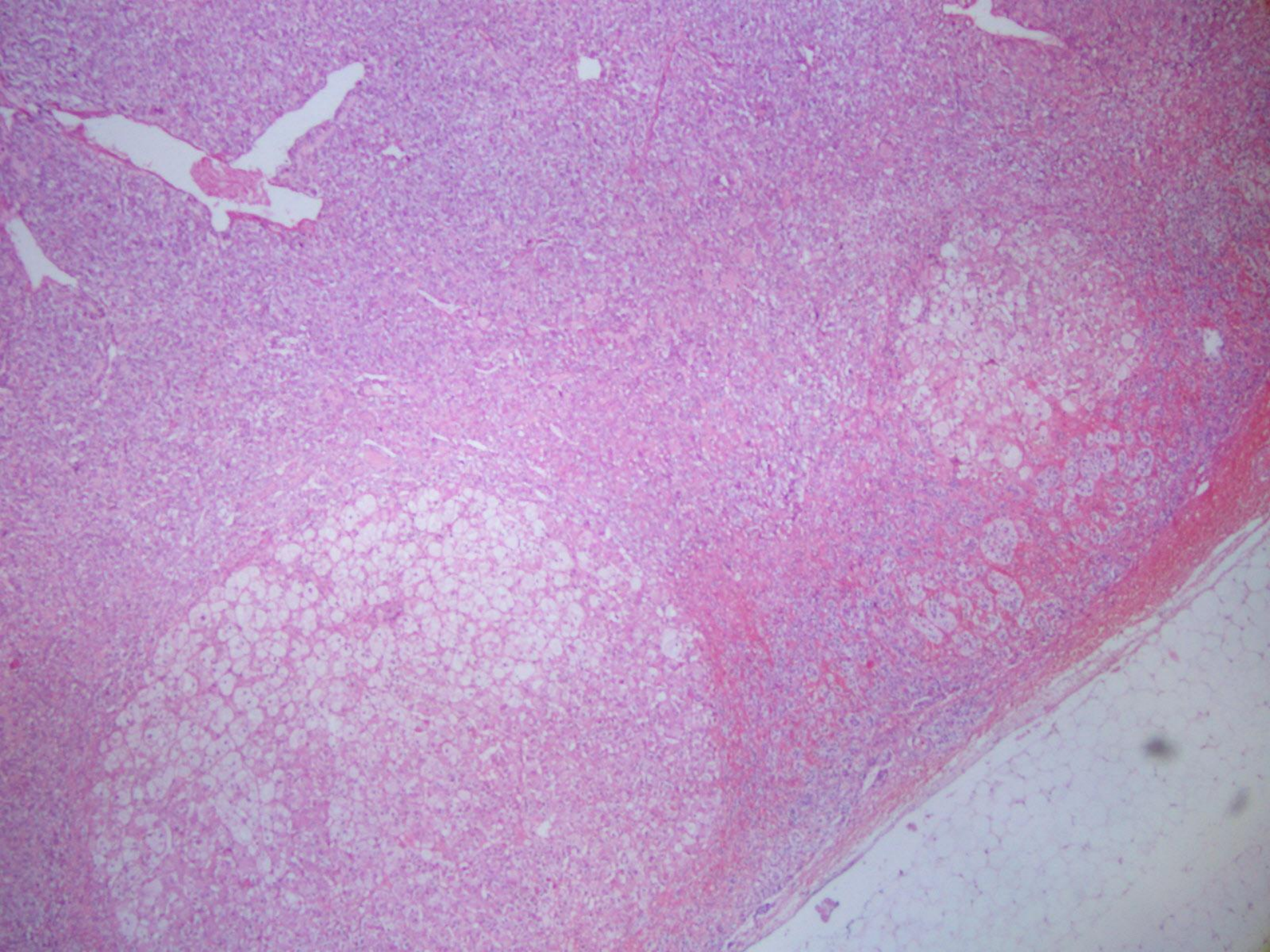
PPNAH?

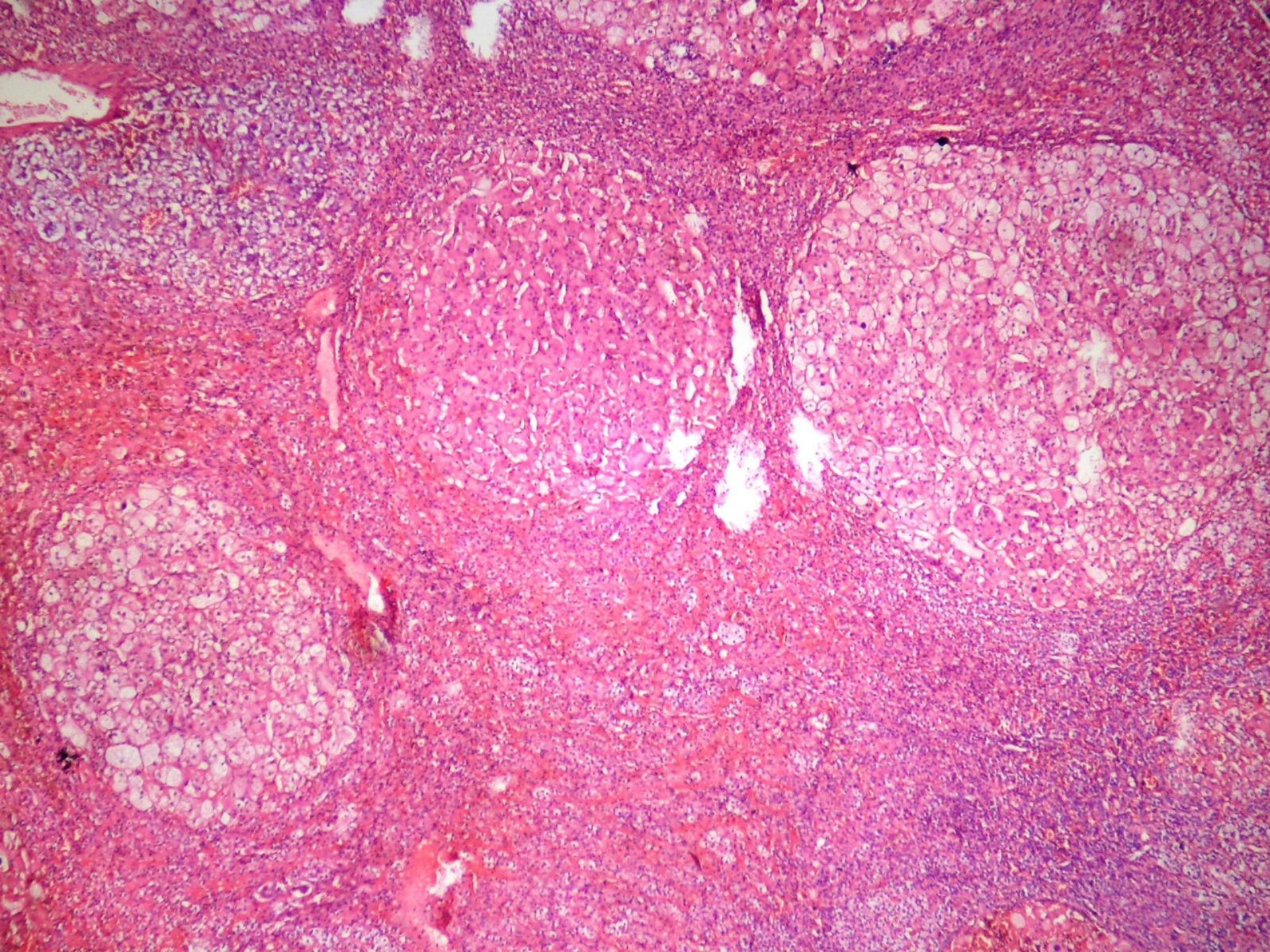
- İyodometilnorkolesterol sintigrafisi
Hiperplazi?

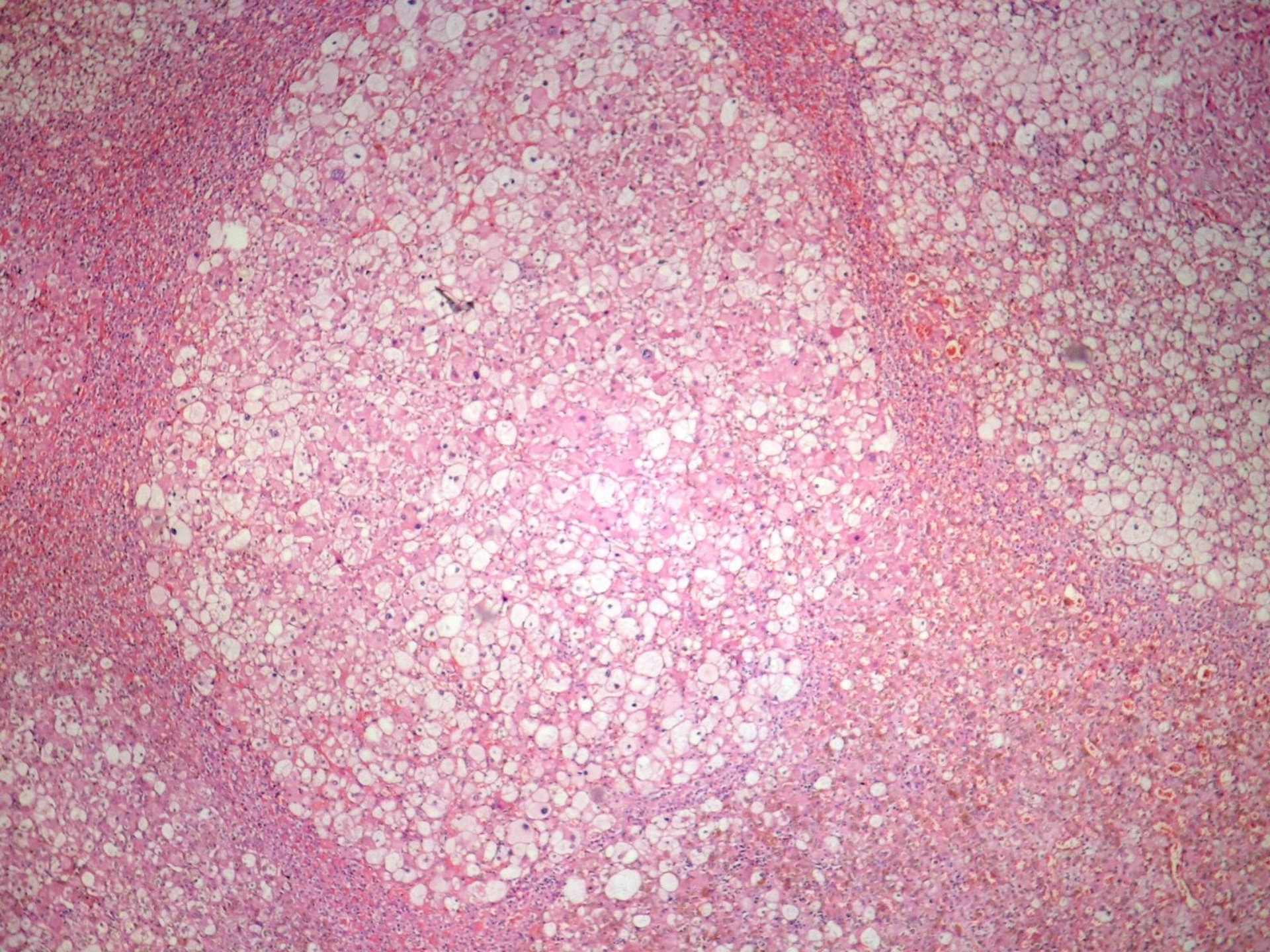
Makroskobik bulgular

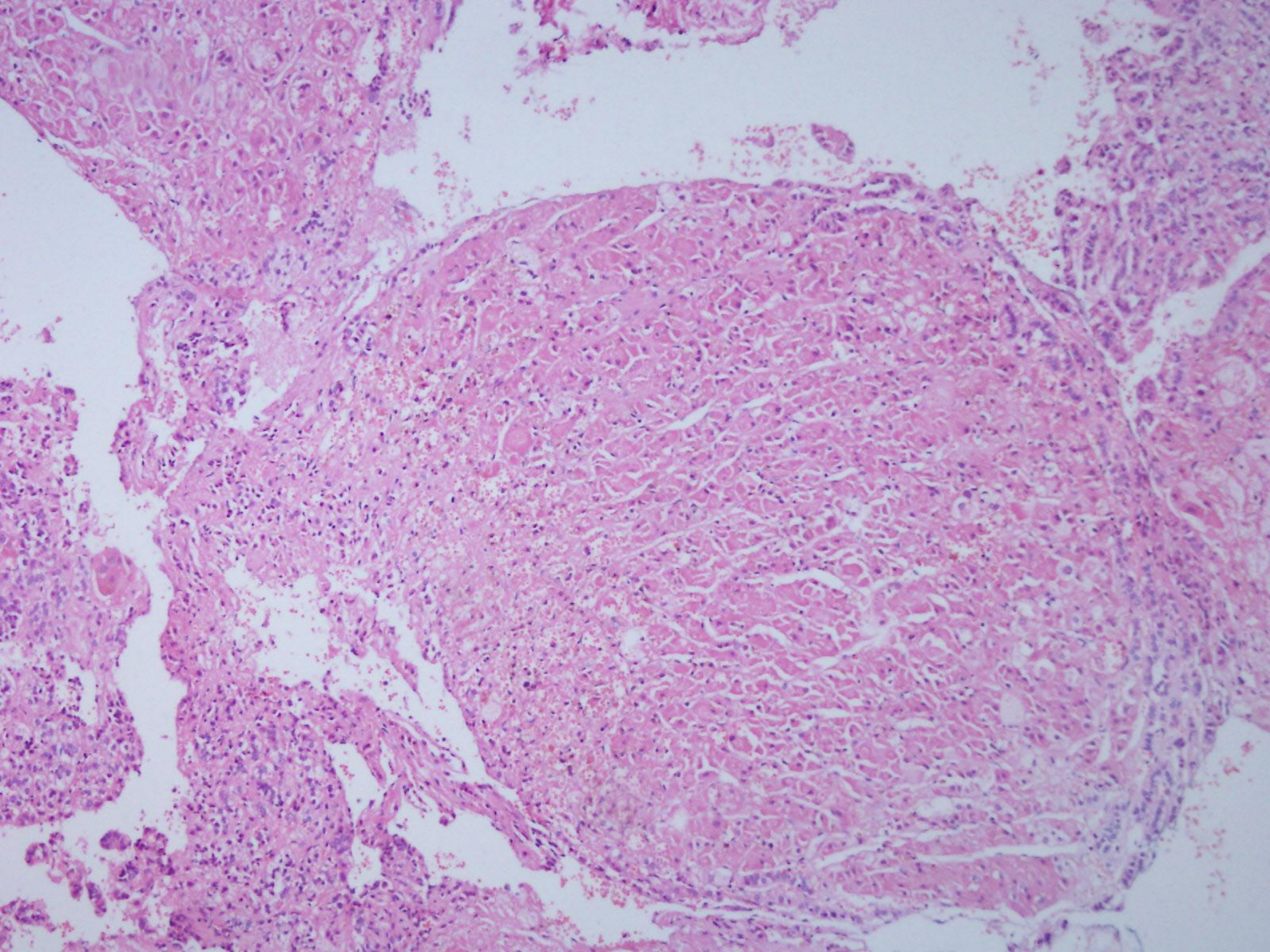
6x3,5x2 cm boyutlarda
adrenalektomi materyali
milimetrik sarı-turuncu, kahverengi
nodüller

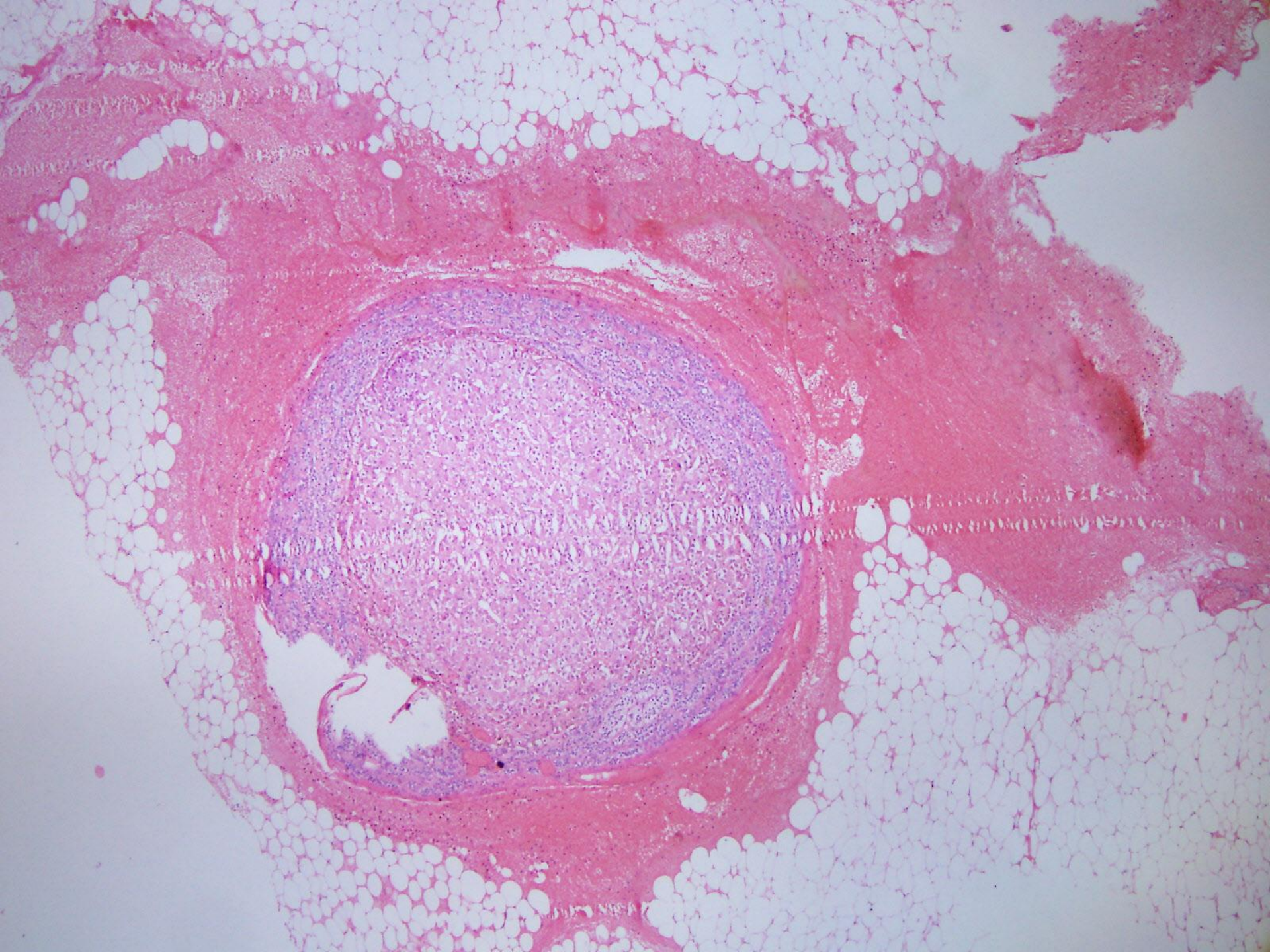


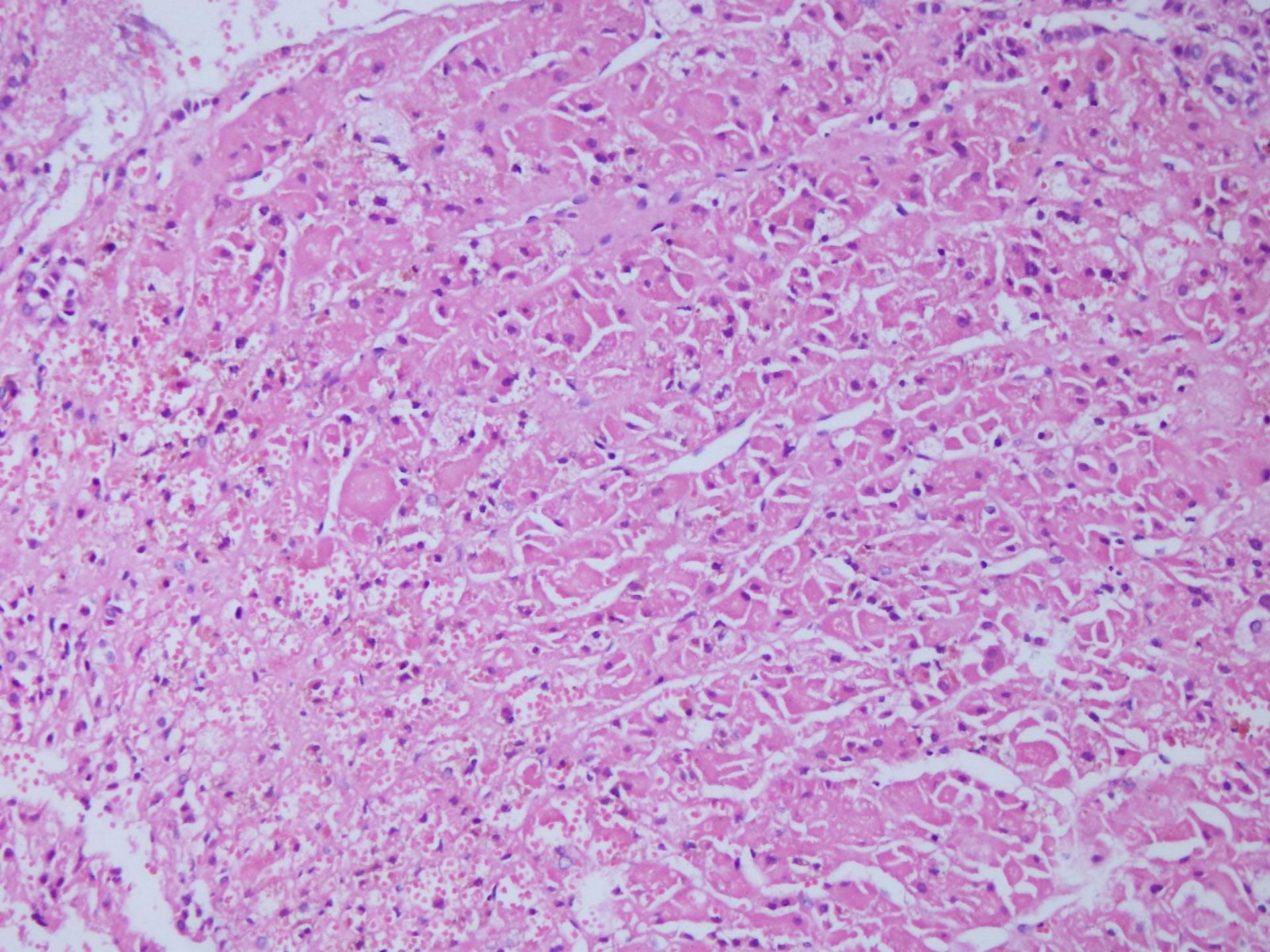


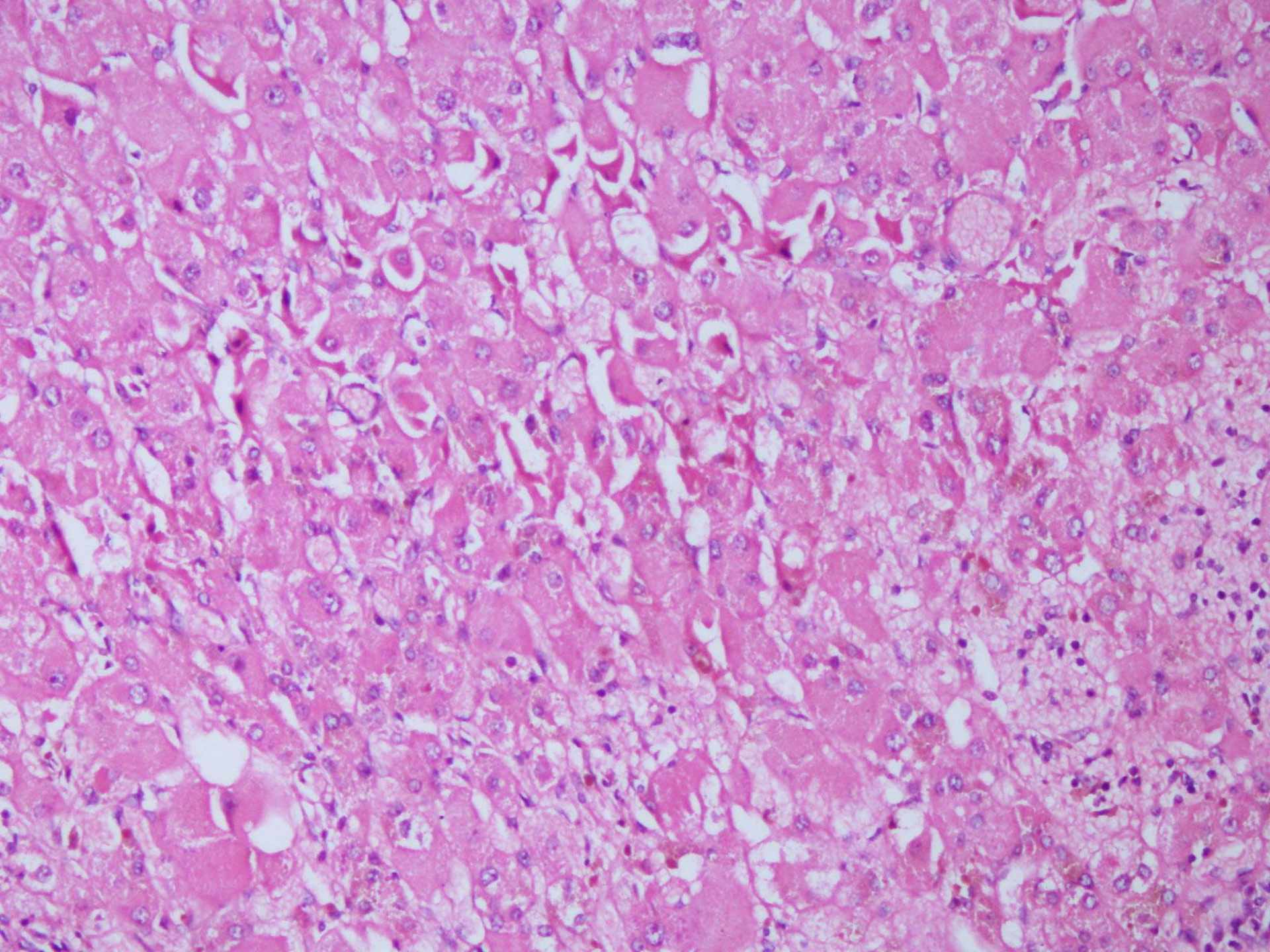


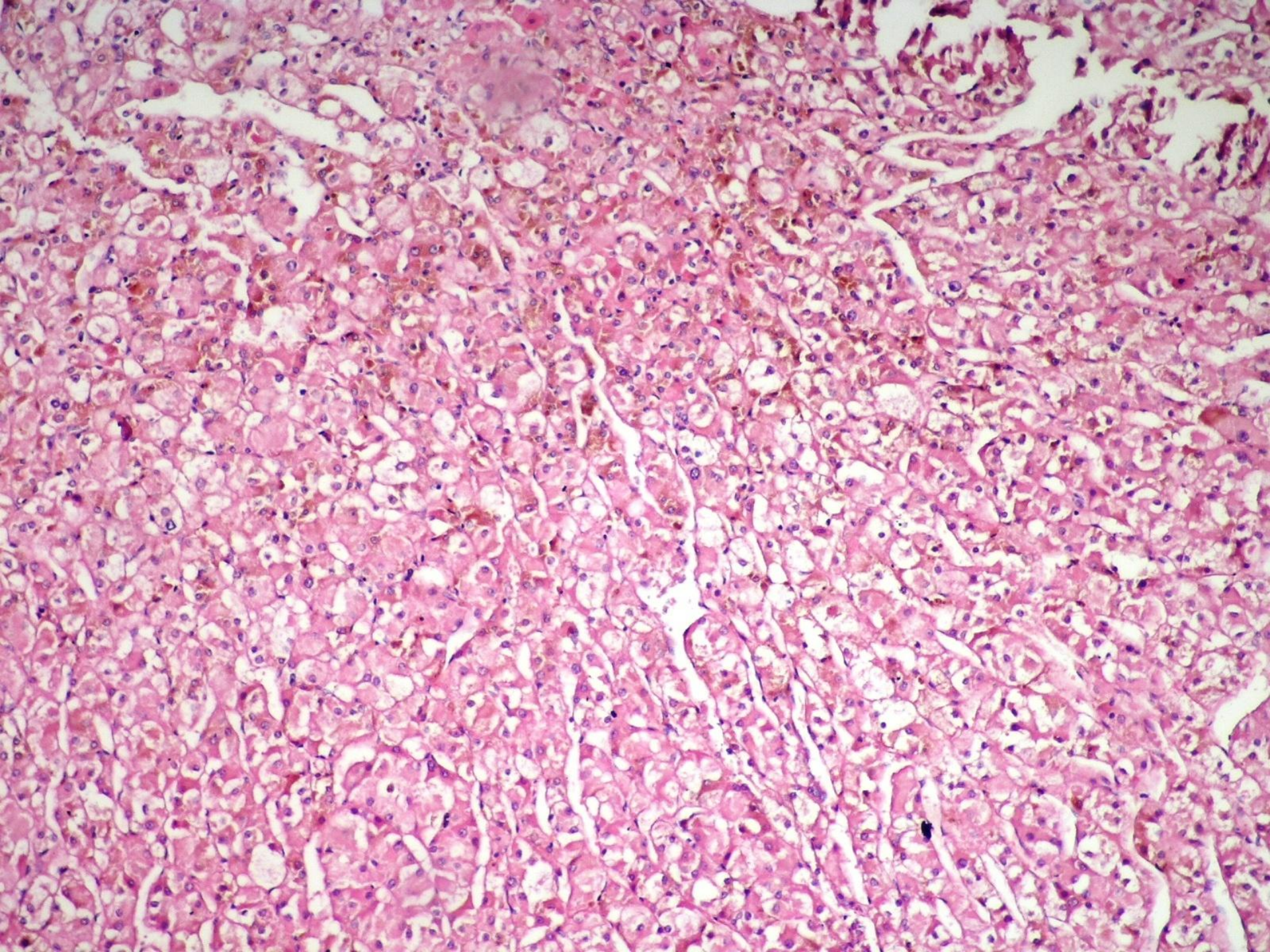


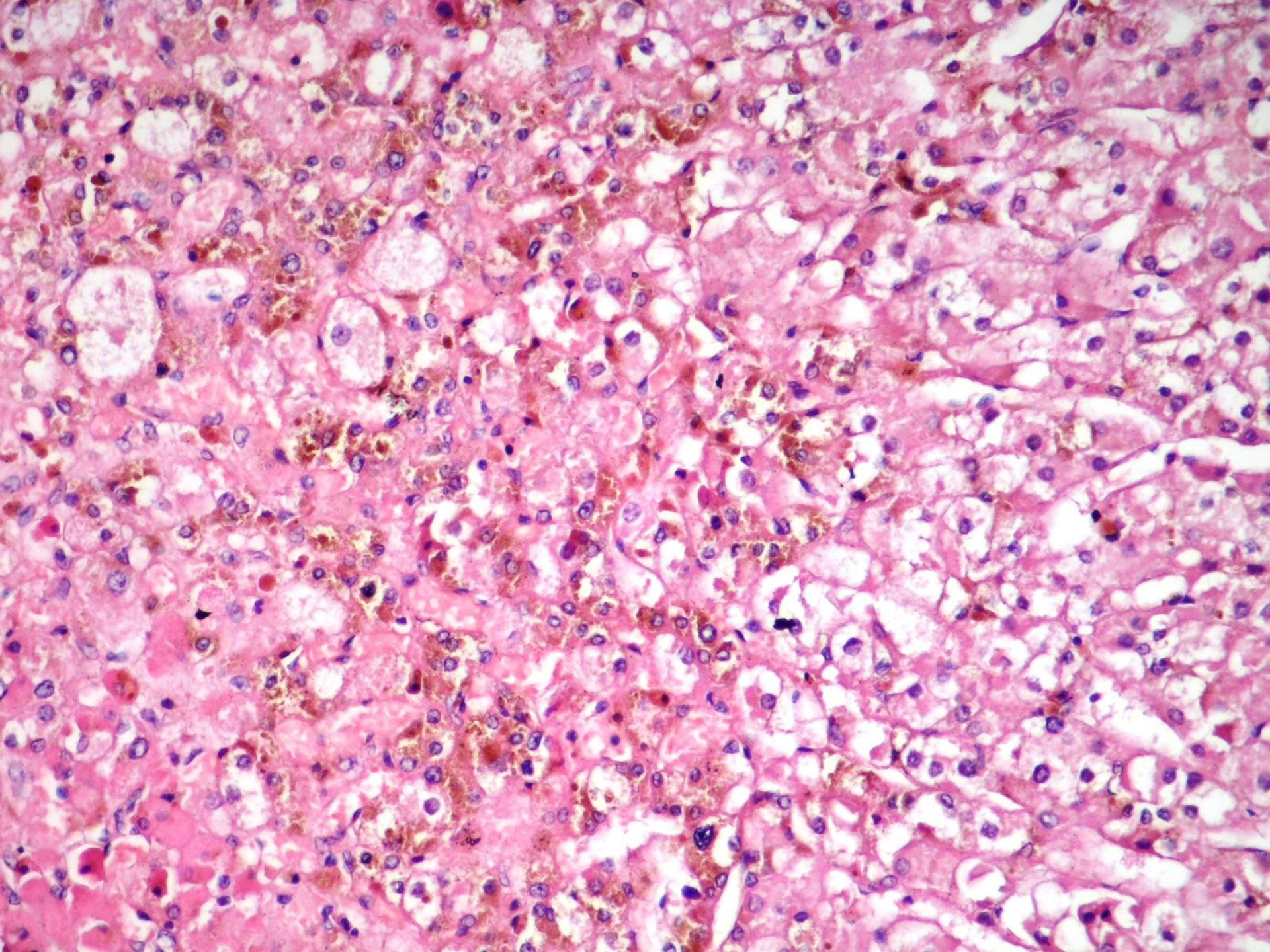


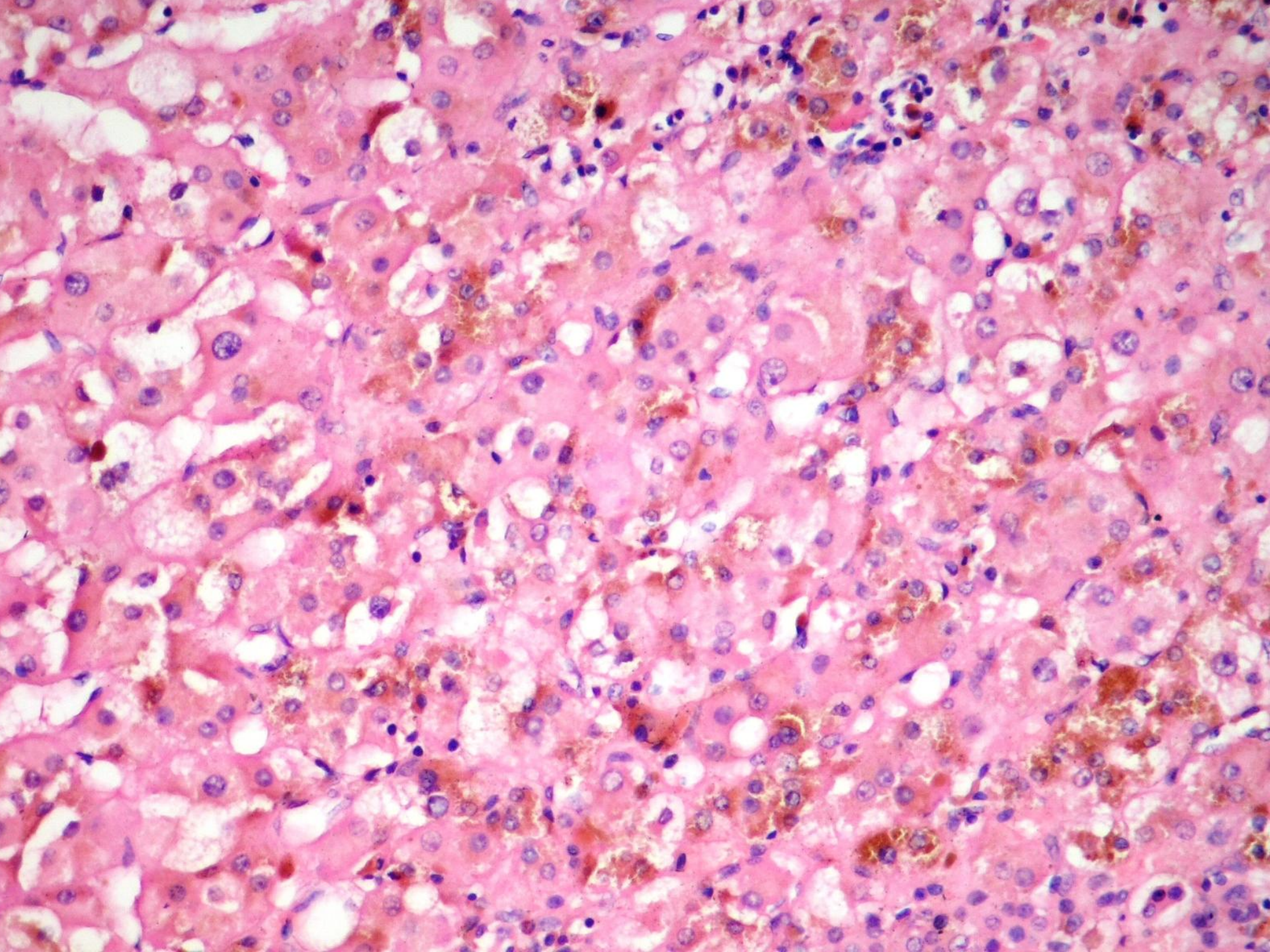


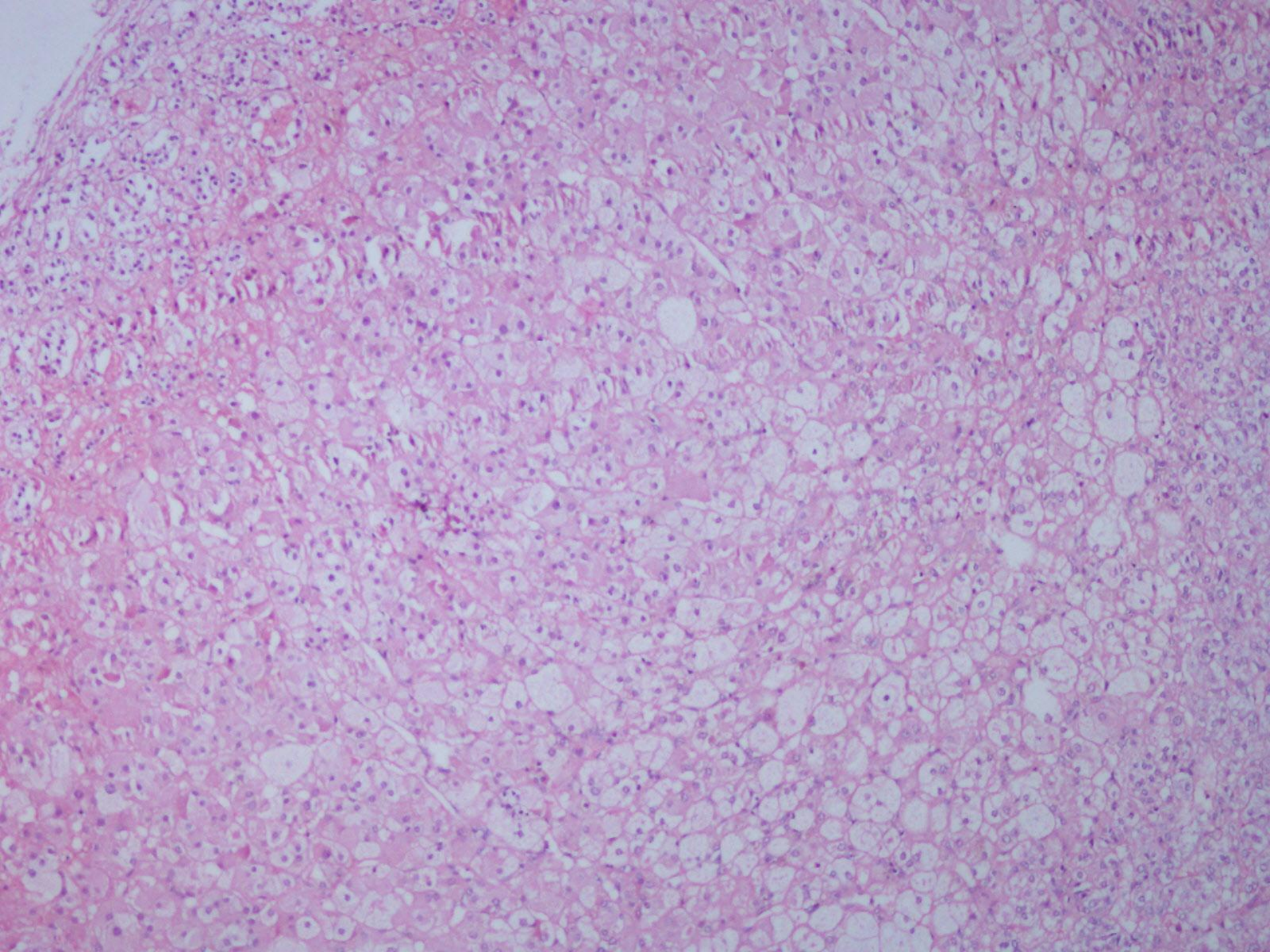


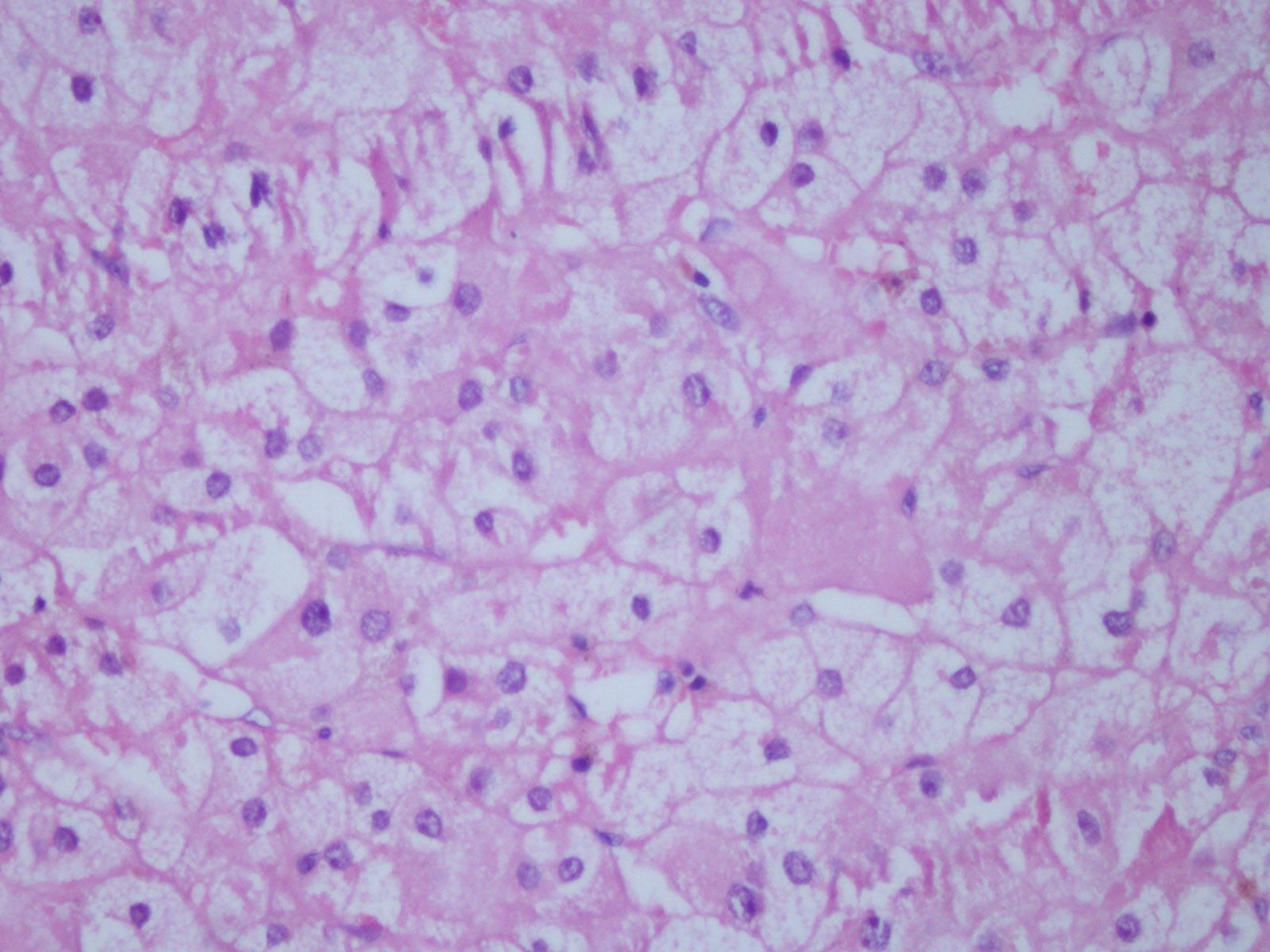












PRİMER PİGMENTE NODÜLER ADRENAL HİPERPLAZİ

PİGMENTE NODÜLER HİPERPLAZİ

- Çok nadir
- Çocuk ve gençlerde
- İzole veya Carney Sendromuyla birliktelik
- Cushing sendromu bulguları
- Plazma ve üriner kortizol yüksekliği
- Yüksek doz deksametazonla baskılanamama

CARNEY SENDROMU

- Kardiak miksoma
- Kutanöz miksoma
- Memede fibroadenom
- Noktasal mukokutanöz pigmentasyon
- Pigmente nodüler hiperpazi
- Testis tümörleri
- GH sekrete eden hipofiz adenomu

OLGU 2

- 1 haftalık erkek bebek
- Antenatal 26.haftada saptanan sol sürrenal kitle

Abdominal USG: Sol sürrenal lojda 5x4x3,5 cm vasküleritesi belirgin, hiperekojen solid kitle

Abdominal BT: Sol sürrenal lojda 48x37x33 cm santrali düşük dansiteli, kapsül komşuluğunda solid vasküler kitle

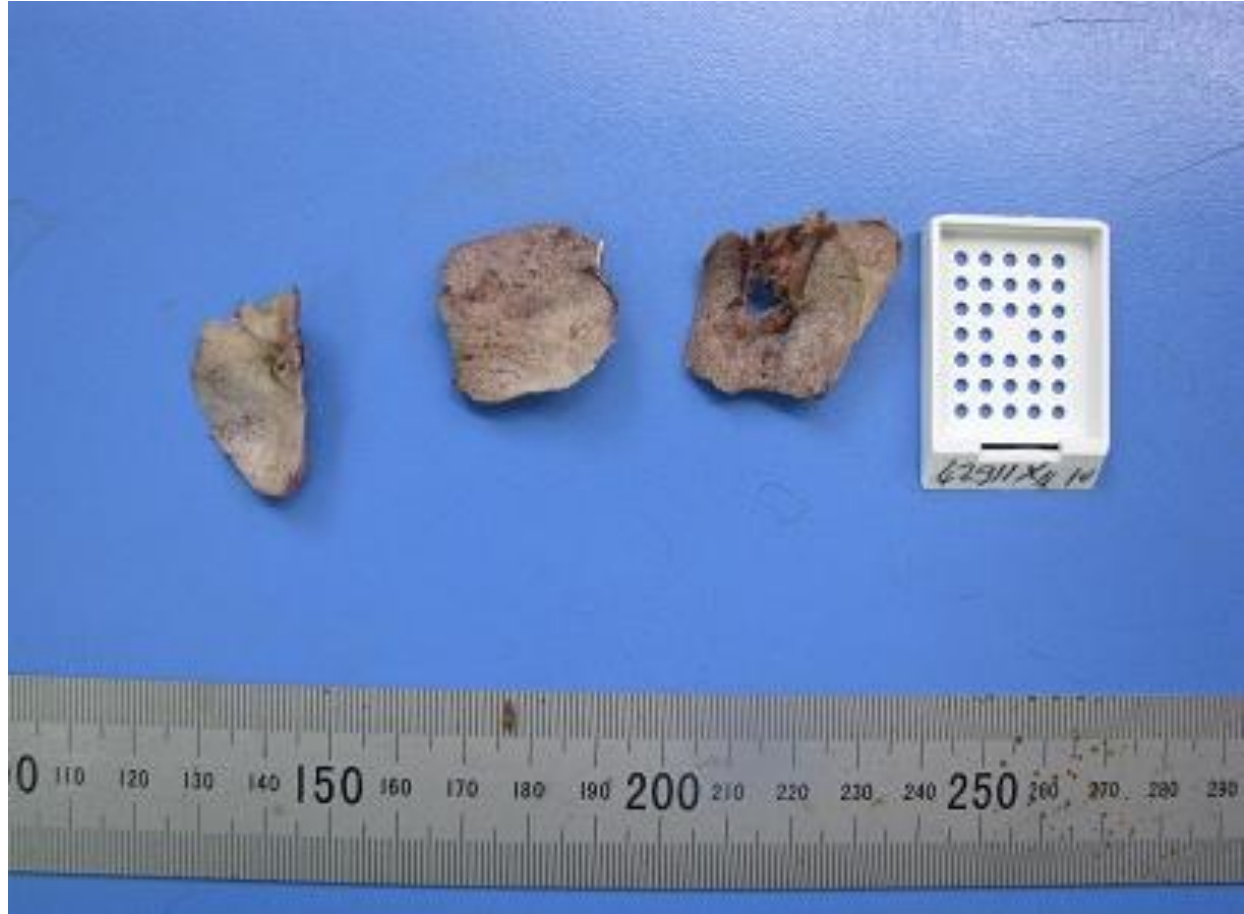Nöroblastom???

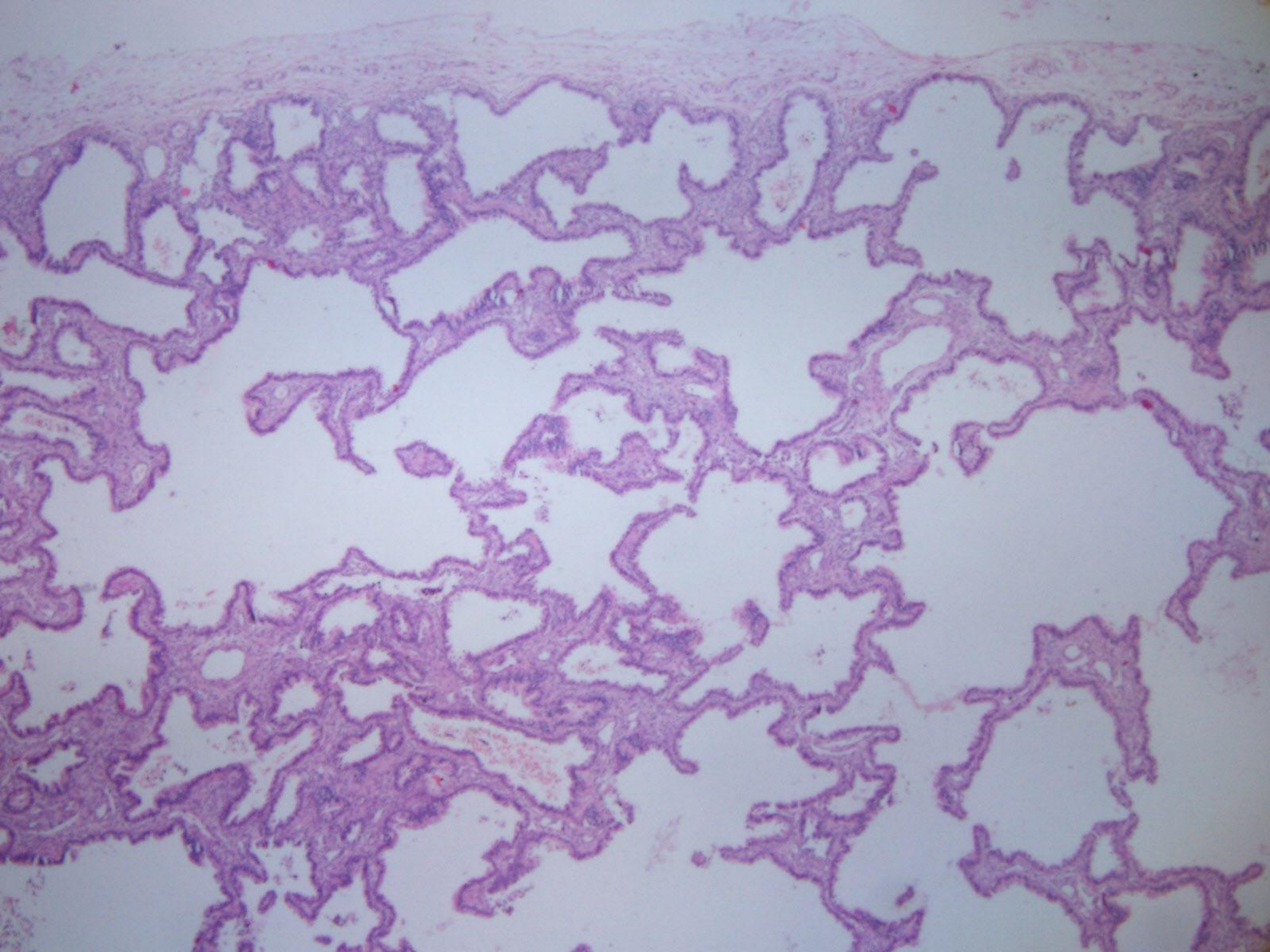
Cerrahi gözlem

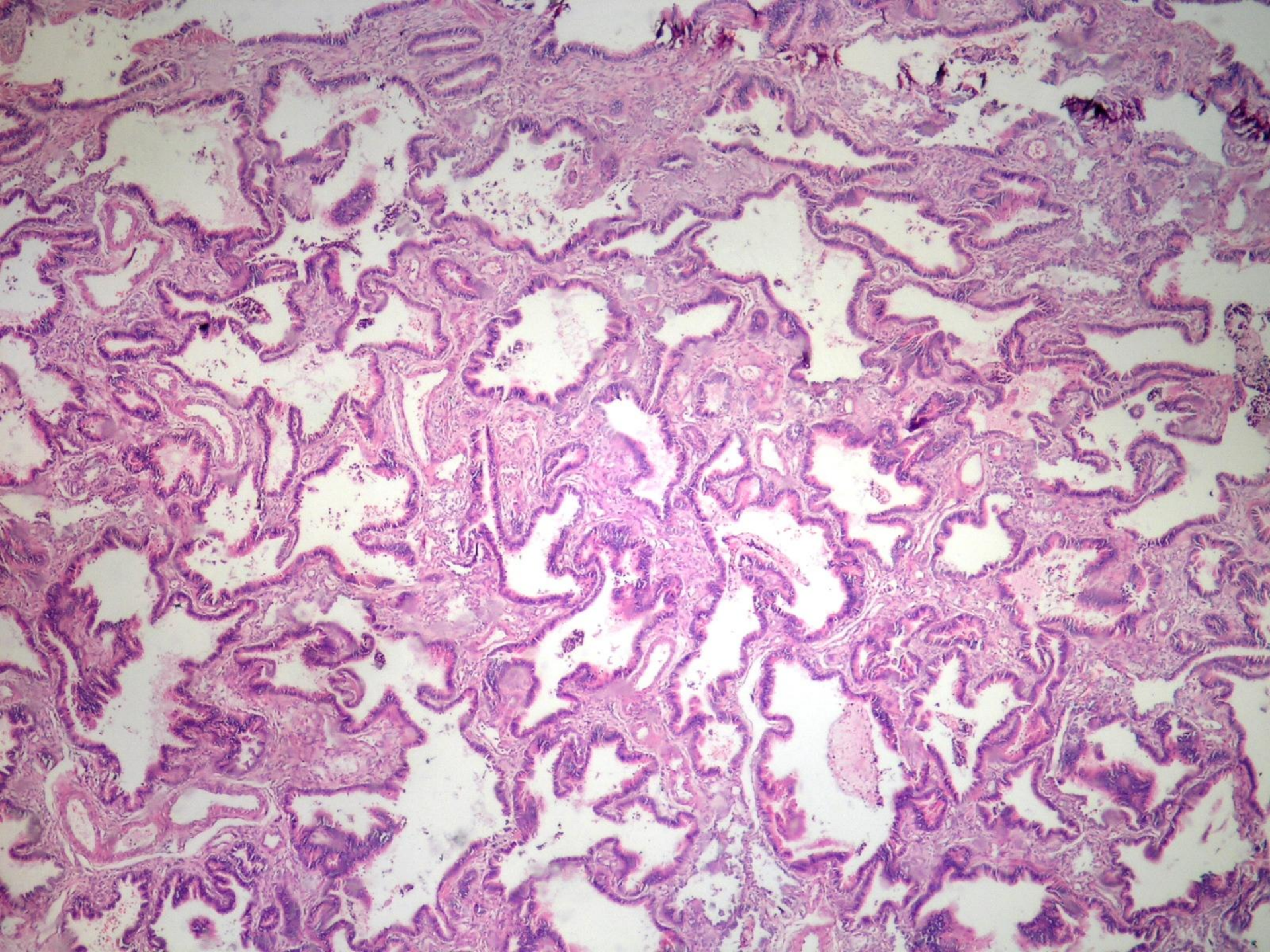
- 5x4 cm psödokapsüllü izlenimi veren büyük oranda kistik kitle
- Diafragmatik kas liflerine sıkıca yapışık
- Mobilizasyon sonrası kitleden seröz sıvı
- Aortadan kaynaklanan bir vasküler ağ ile periferik vaskülarizasyon

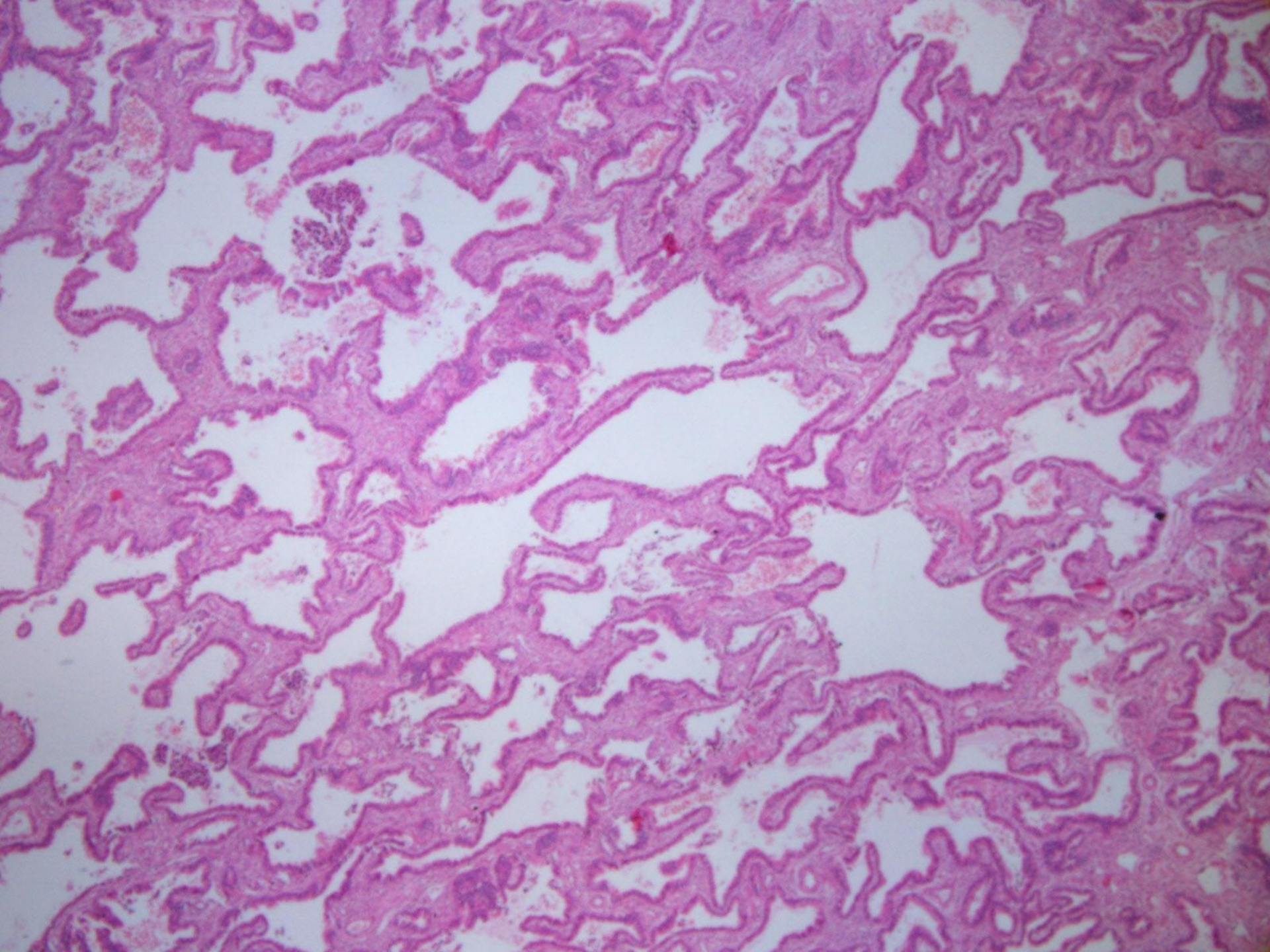
Makroskobik Bulgular

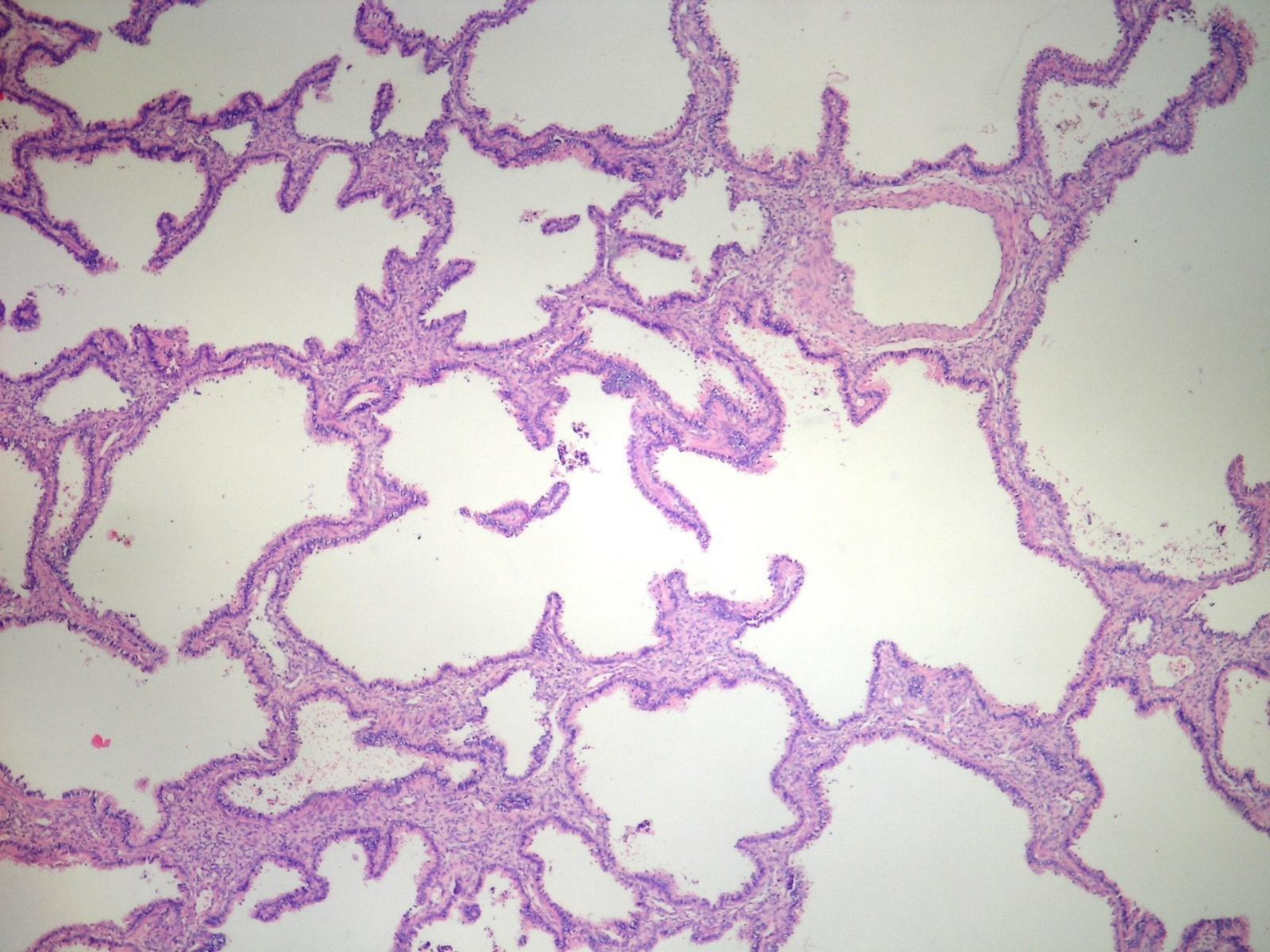
4x3x2,5cm boyutlarda
10 gr ağırlığında
Kesit yüzü süngerimsi
görünümde, kahverengi
renkte

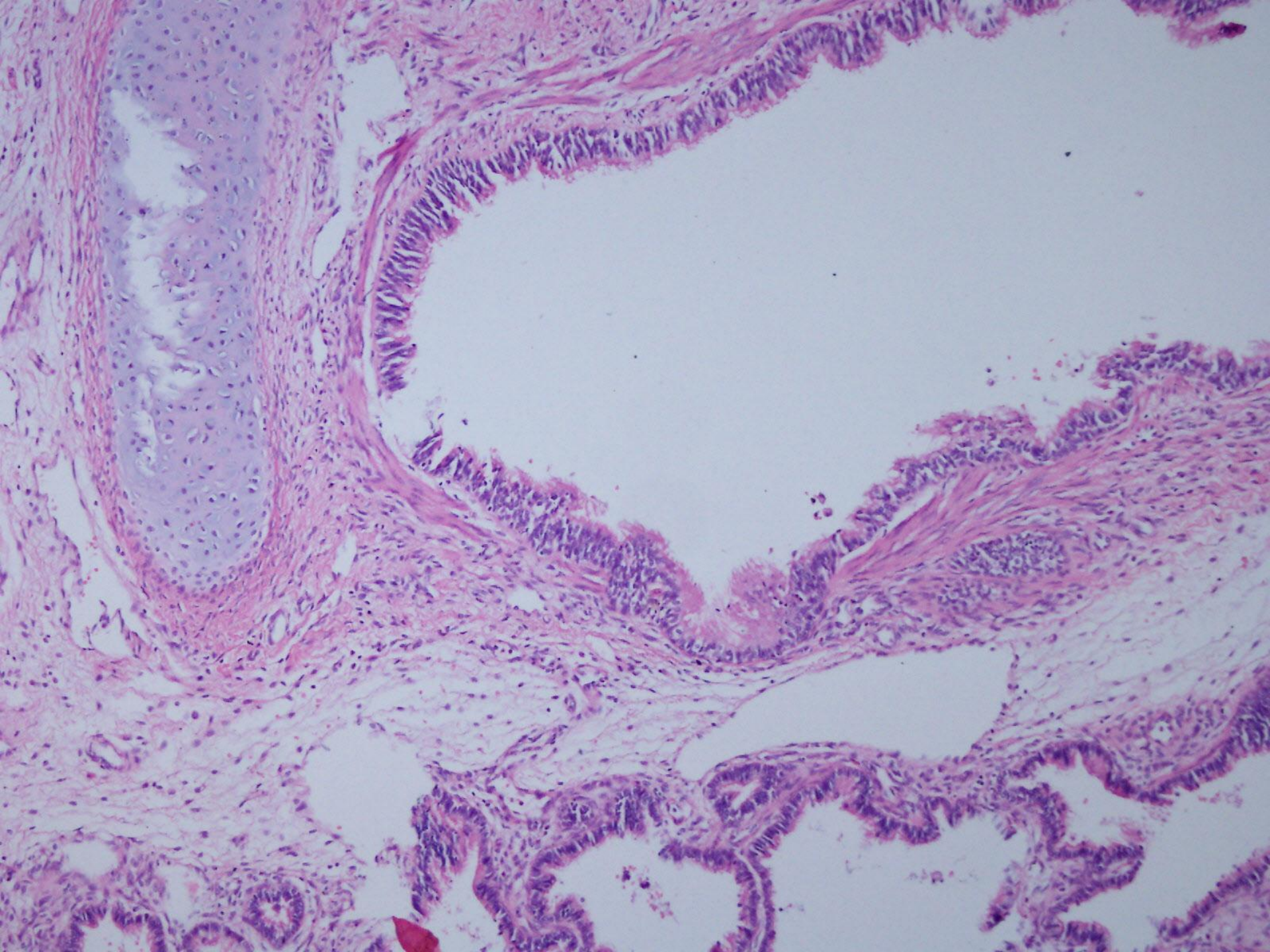


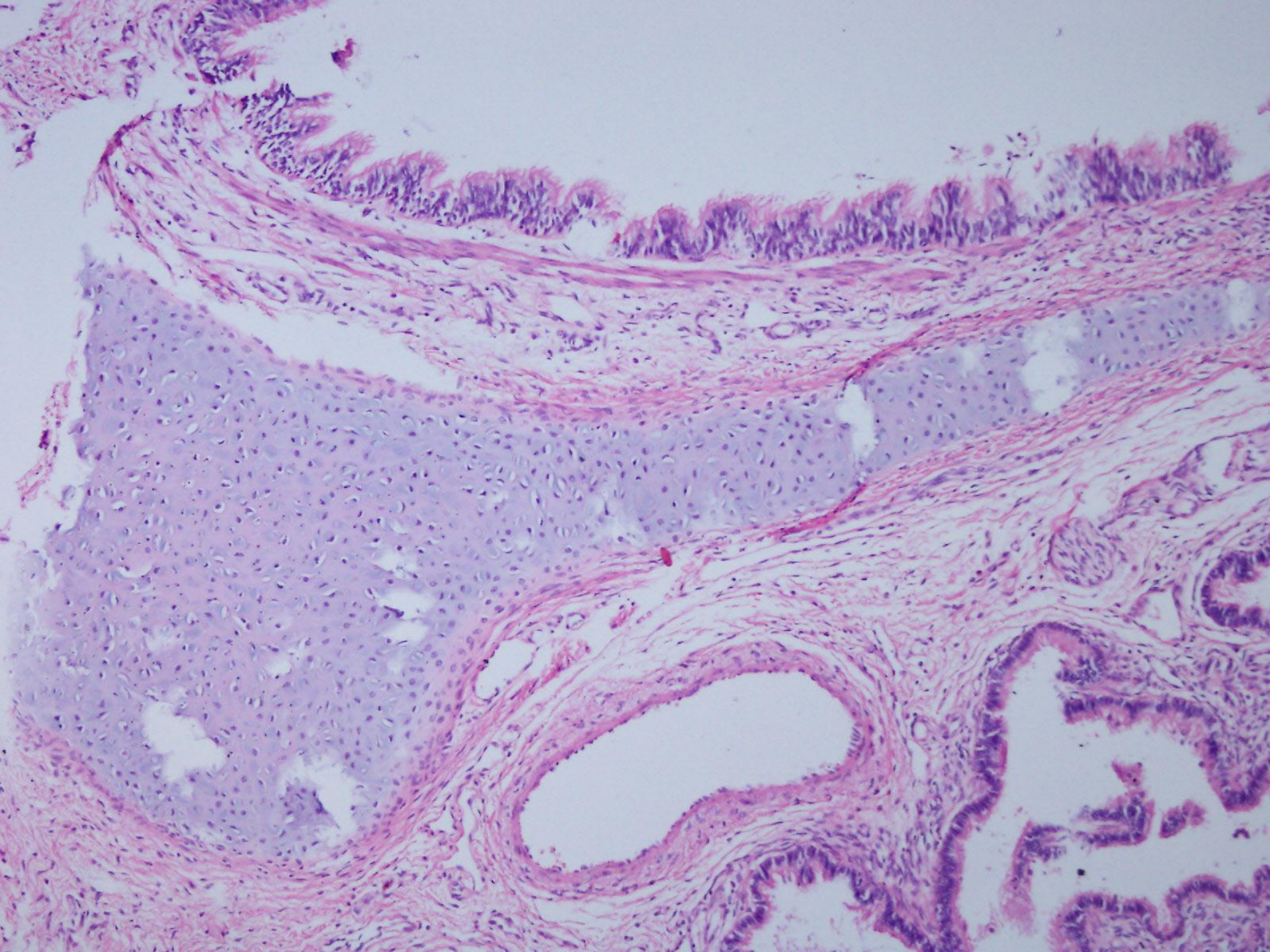


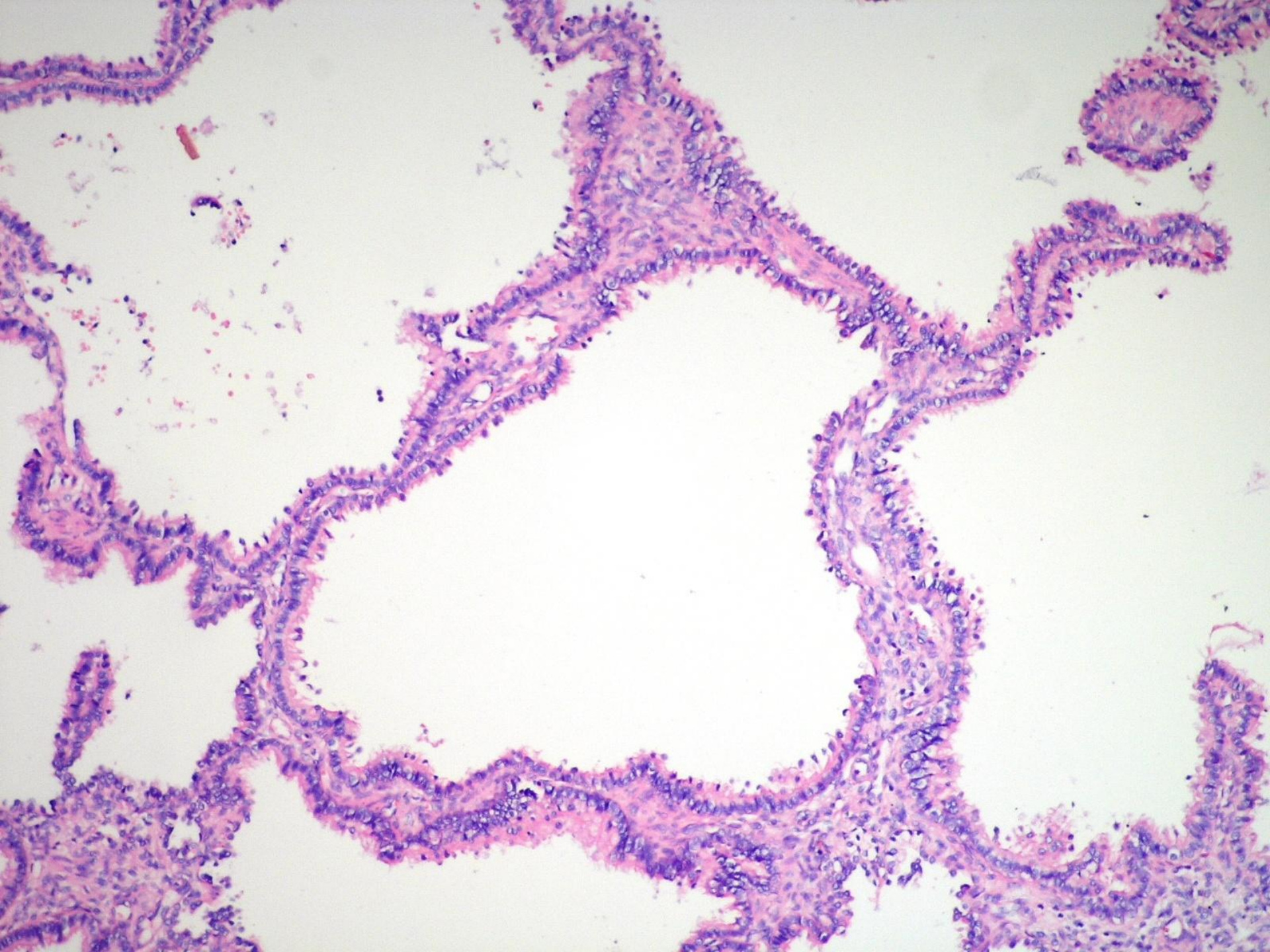


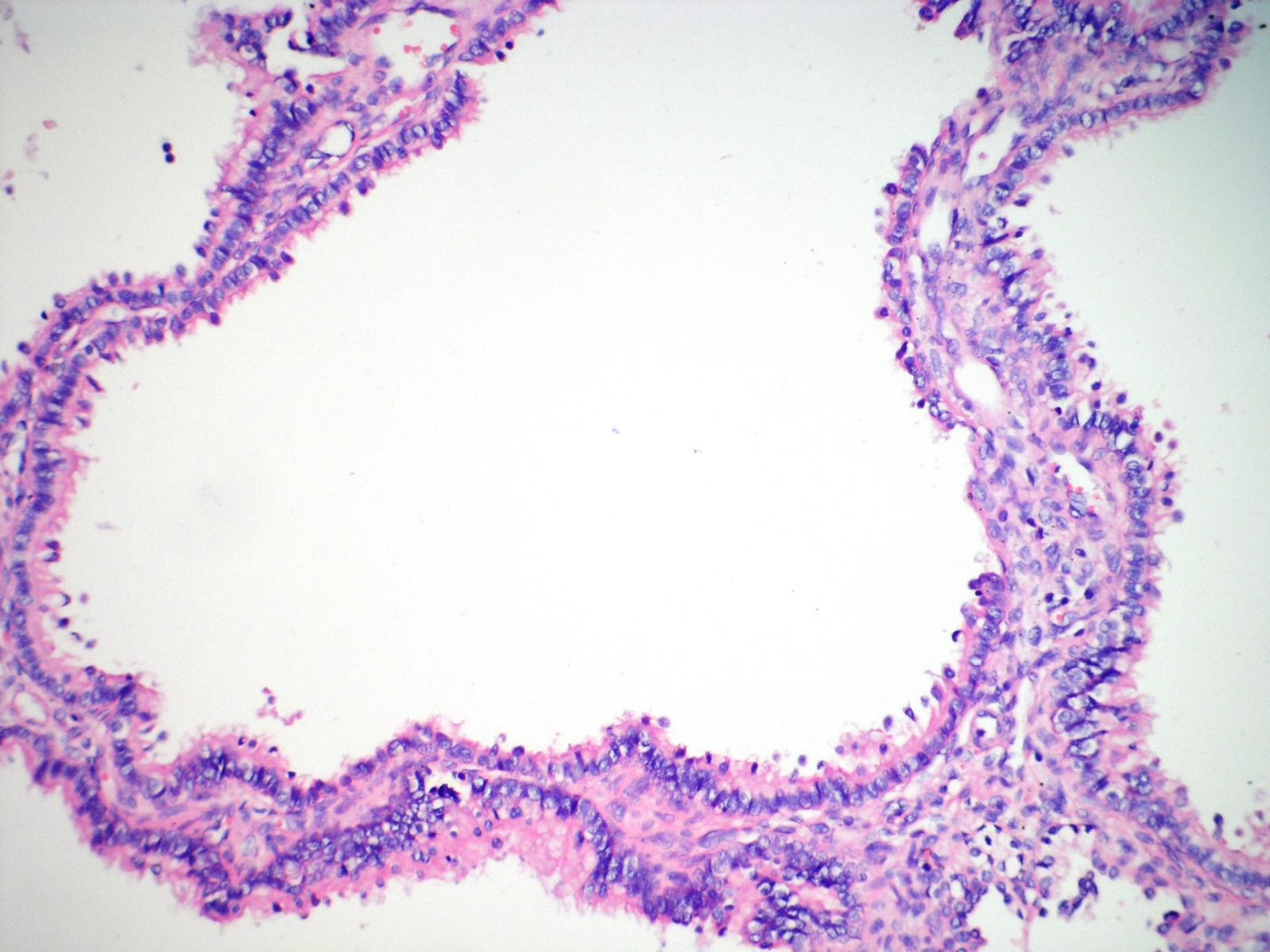


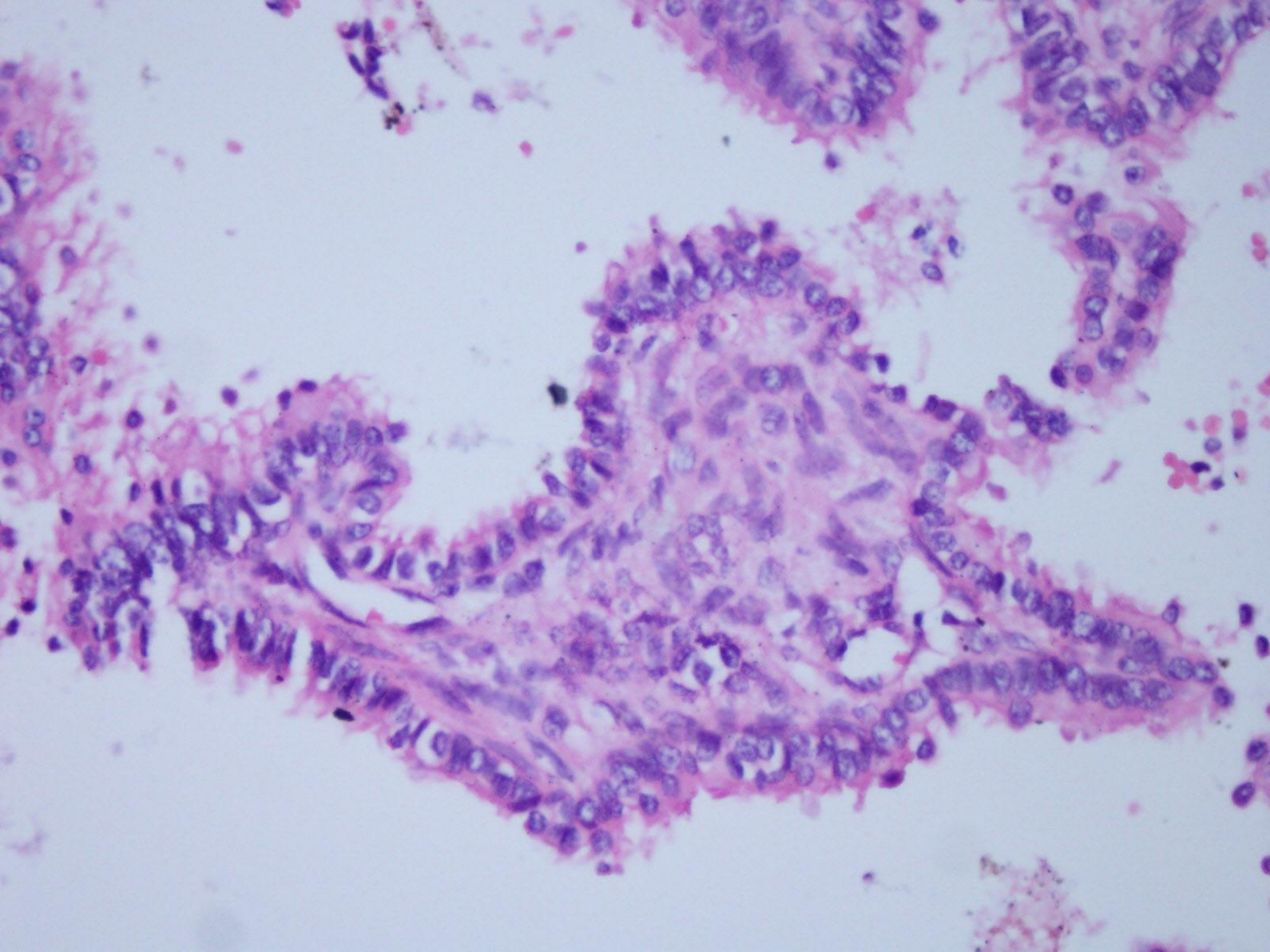


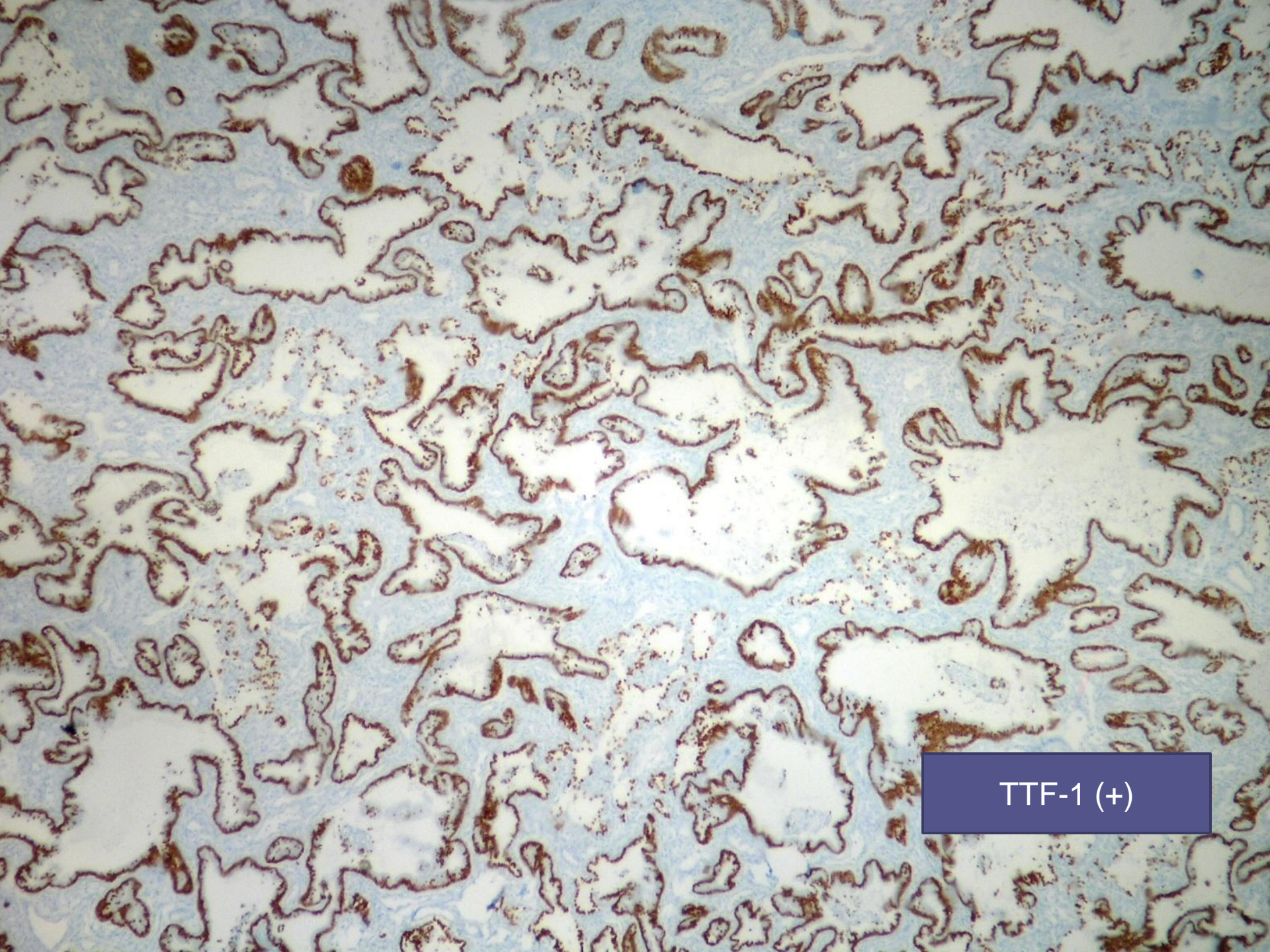




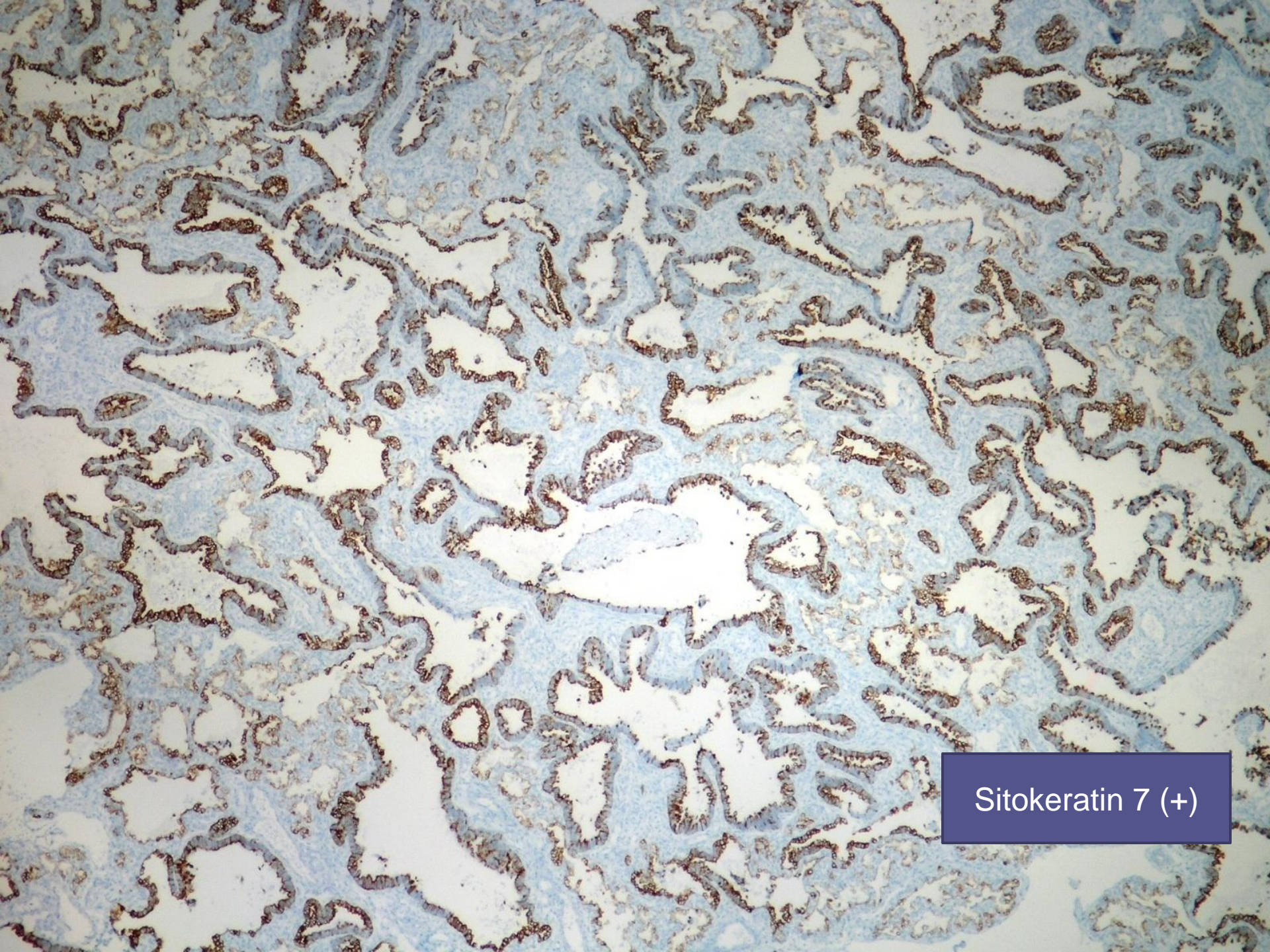




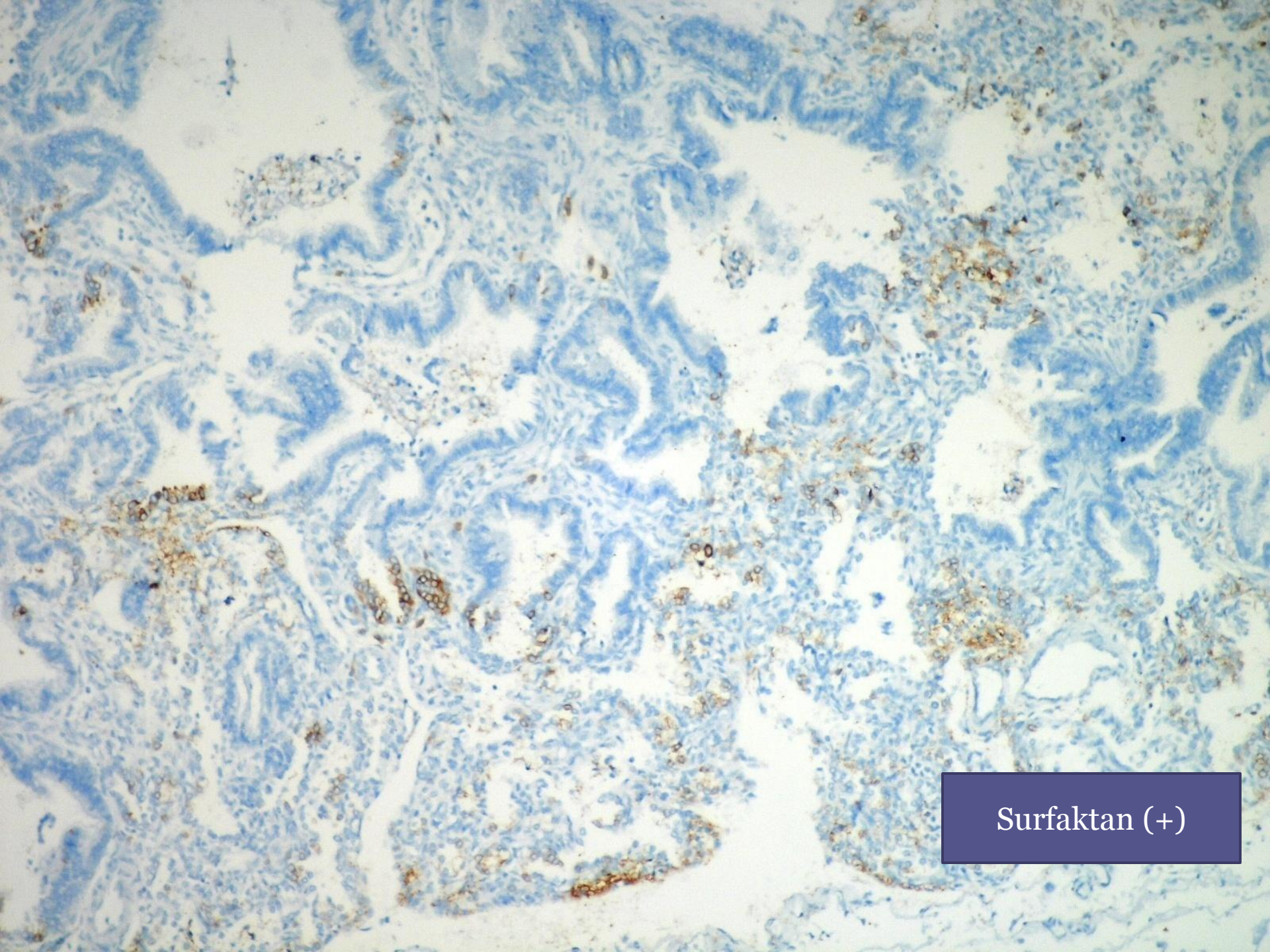




TTF-1 (+)



Sitokeratin 7 (+)



Surfaktan (+)

İNTRAABDOMİNAL EKSTRALOBAR PULMONER SEKESTRASYON

BRONKOPULMONER SEKESTRASYON

- Fokal bir alanda displastik ve nonfonksiyone pulmoner parankim alanı
- Trakeobronşial ağaçla ve pulmoner arterle bağlantısı yok
- Sistemik dolaşım

BRONKOPULMONER SEKESTRASYON

%75 intralobar

%25 ekstralobar



%90 toraks, mediasten



%10 intraabdominal