



Düşük dereceli B-hücreli Hodgkin-dışı lenfomalardan oluşan olgu sunumları

OLGU IV

Dr. Süheyla Uyar Bozkurt
Marmara Üniversitesi Tıp Fakültesi
Patoloji A.B.D





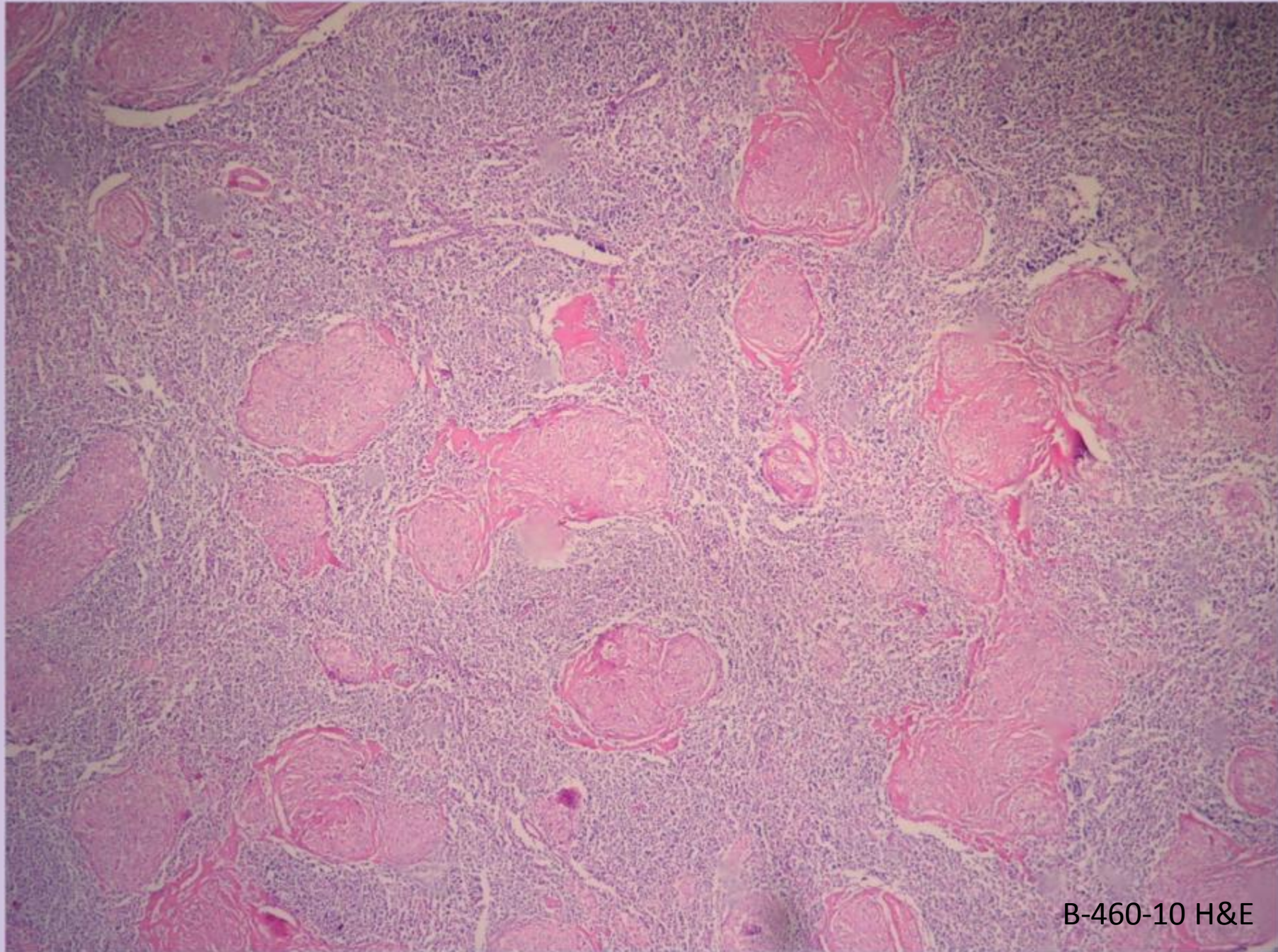
Olgu Sunumu

- 60 yaş, K
- Aksiller lenfadenopati
- Diğer sistem muayenesi normal
- Hepatomegali yok
- 26 yıl önce kronik piyelonefrit -sol nefrektomi ve splenektomi

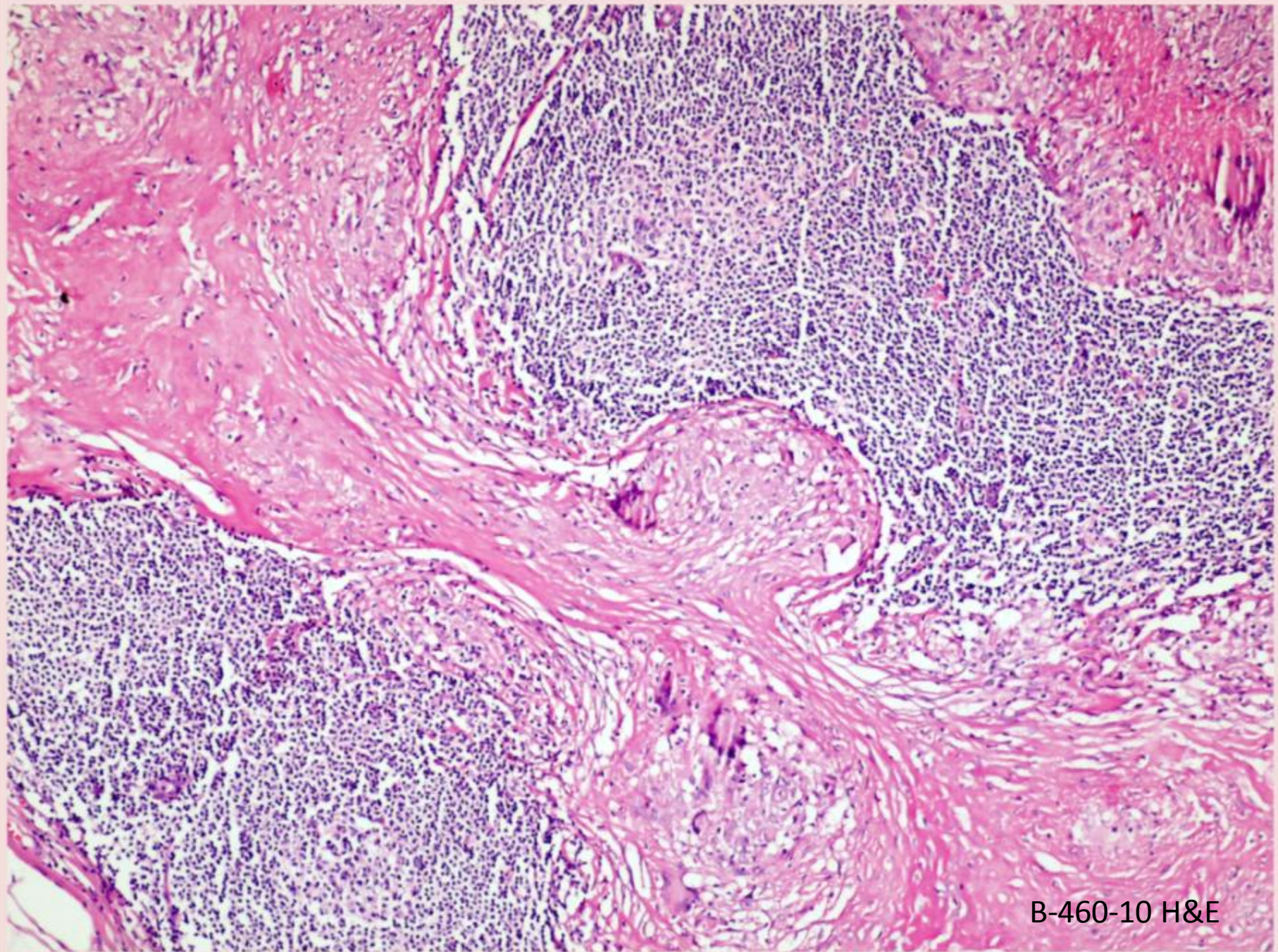


Olgu Sunumu

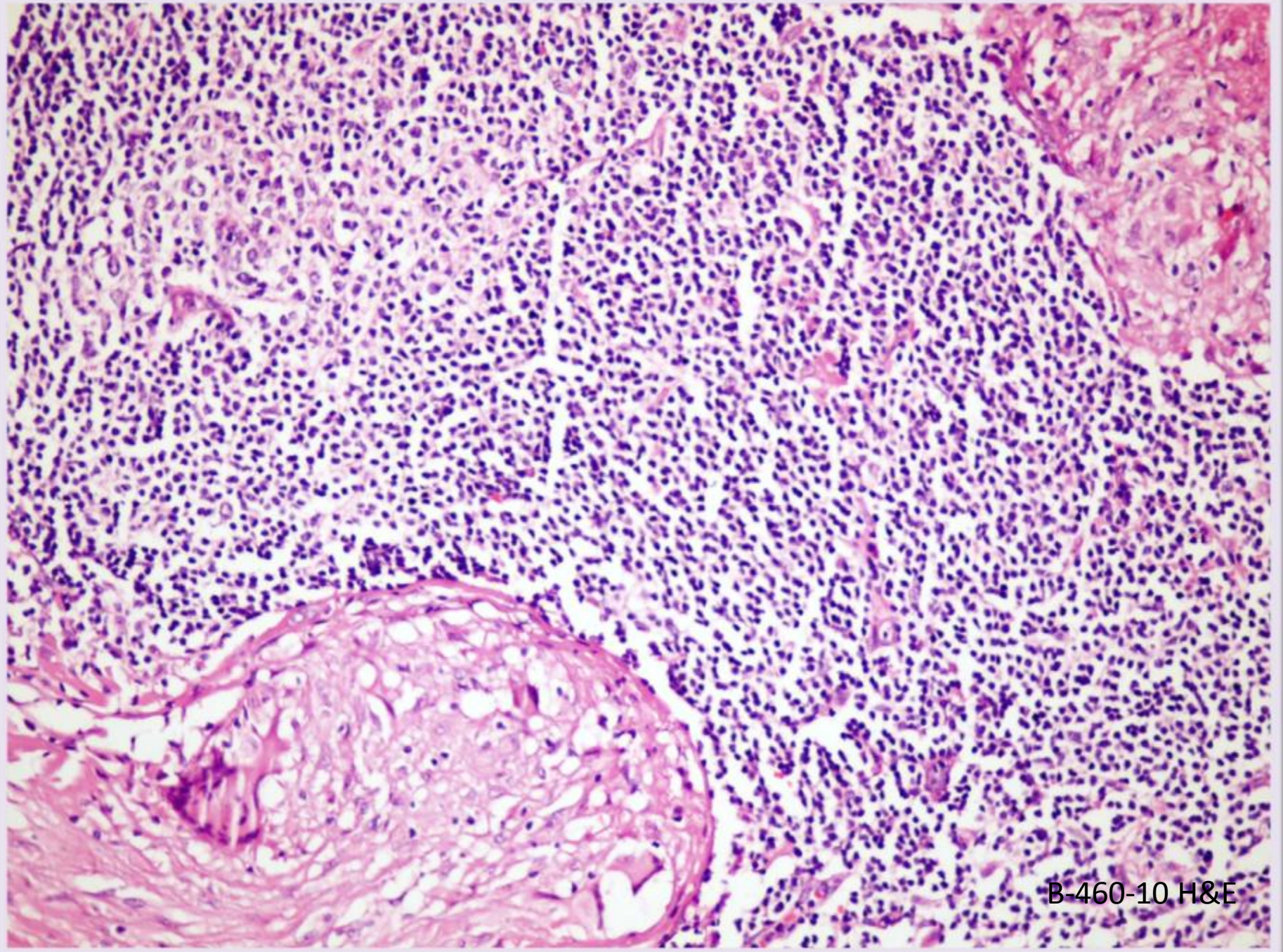
- Aksiller lenf nodu eksizyonu
- Makroskopi: 5x4x2 cm. beyaz-krem, dış yüzü düzgün, kesit yüzü beyaz renkli heterojen



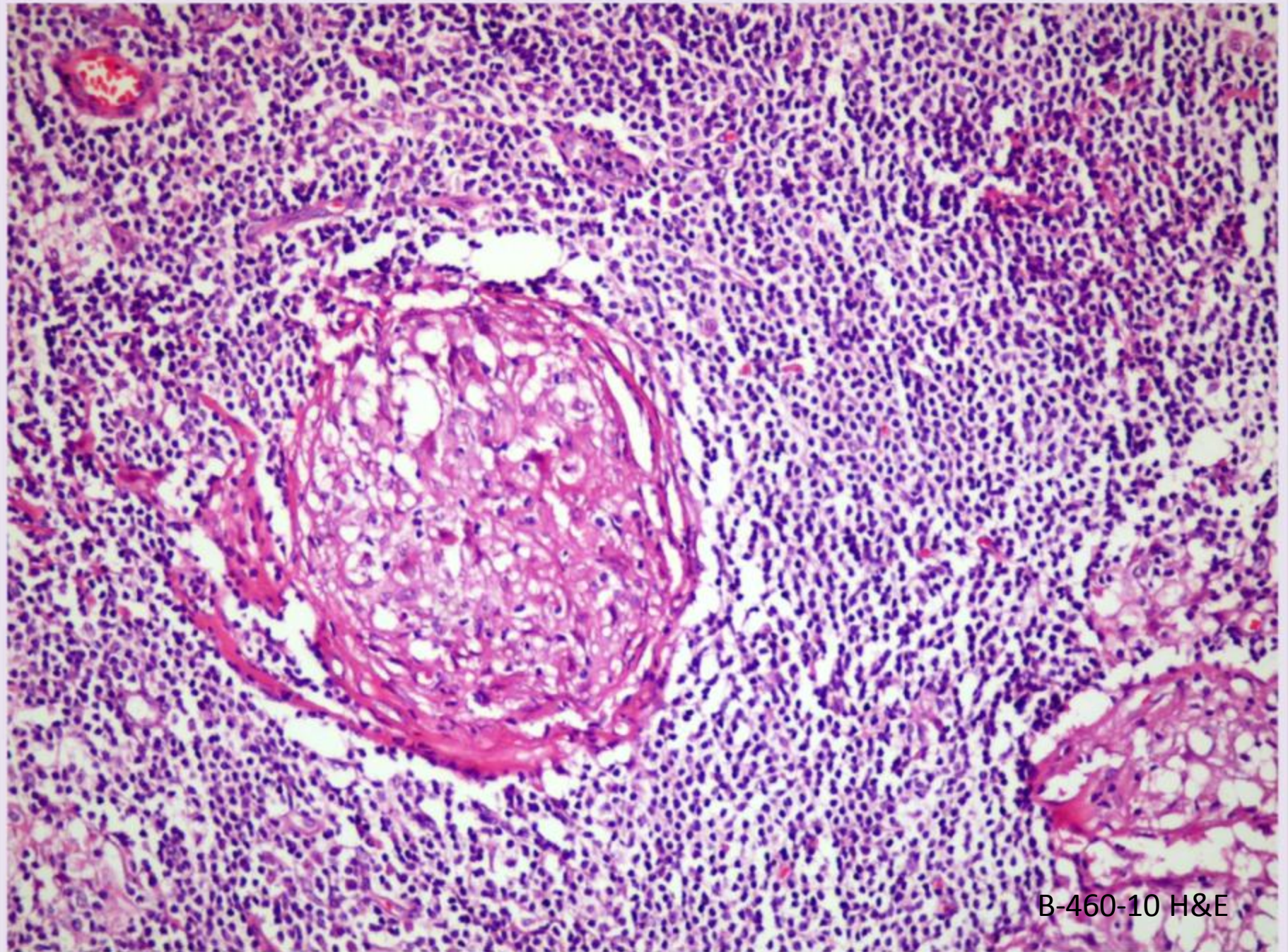
B-460-10 H&E



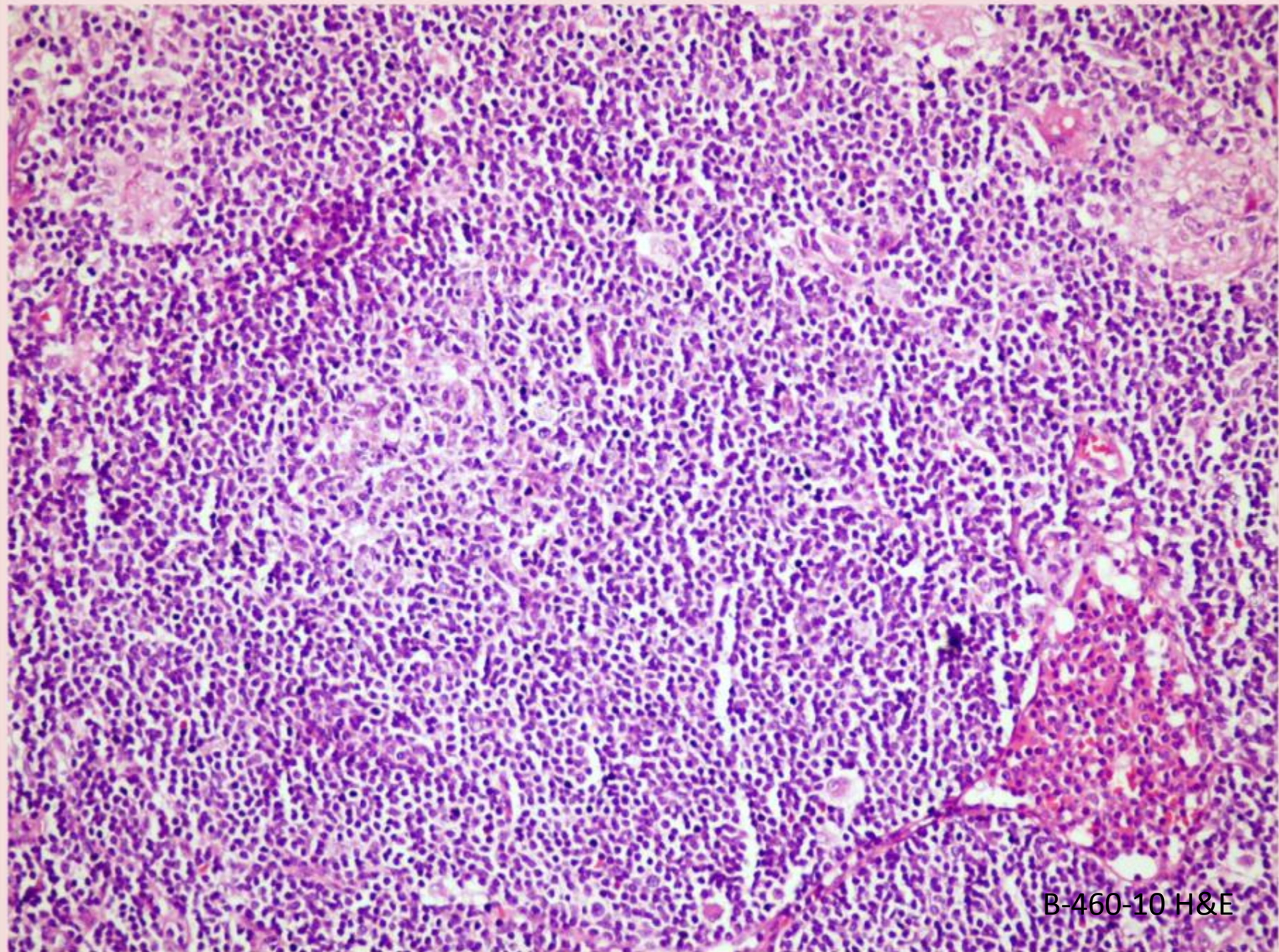
B-460-10 H&E



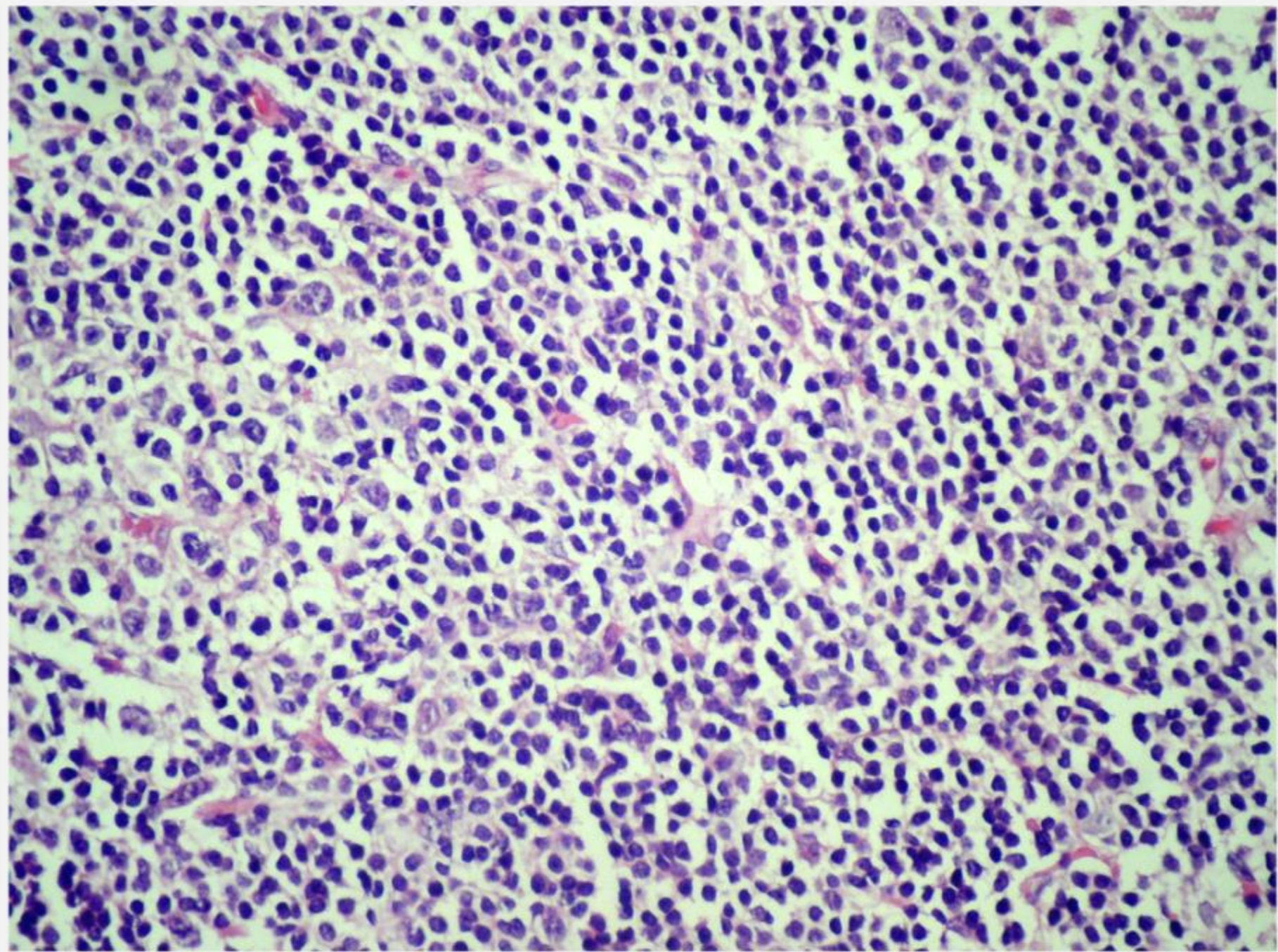
B-460-10 H&E

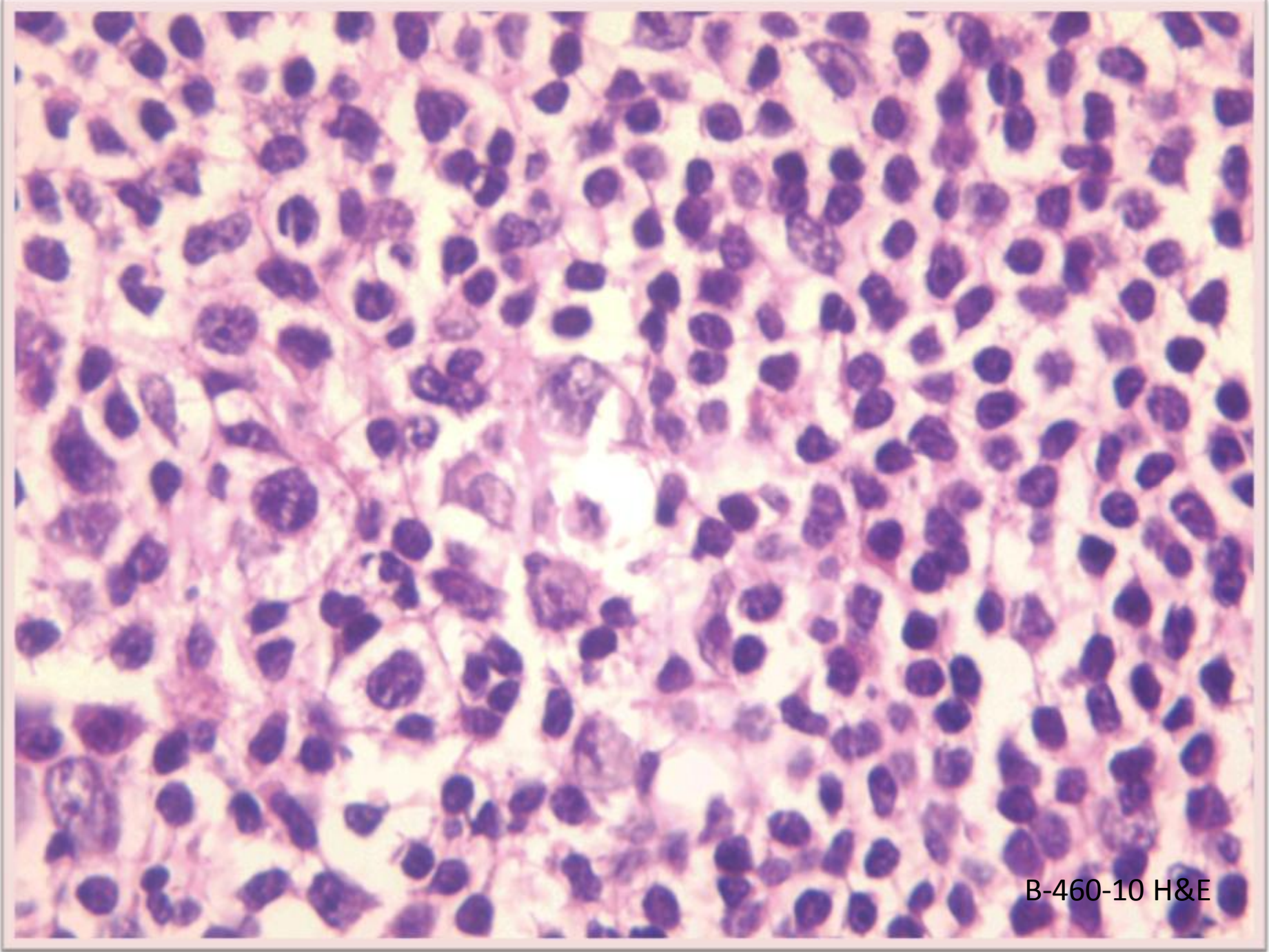


B-460-10 H&E

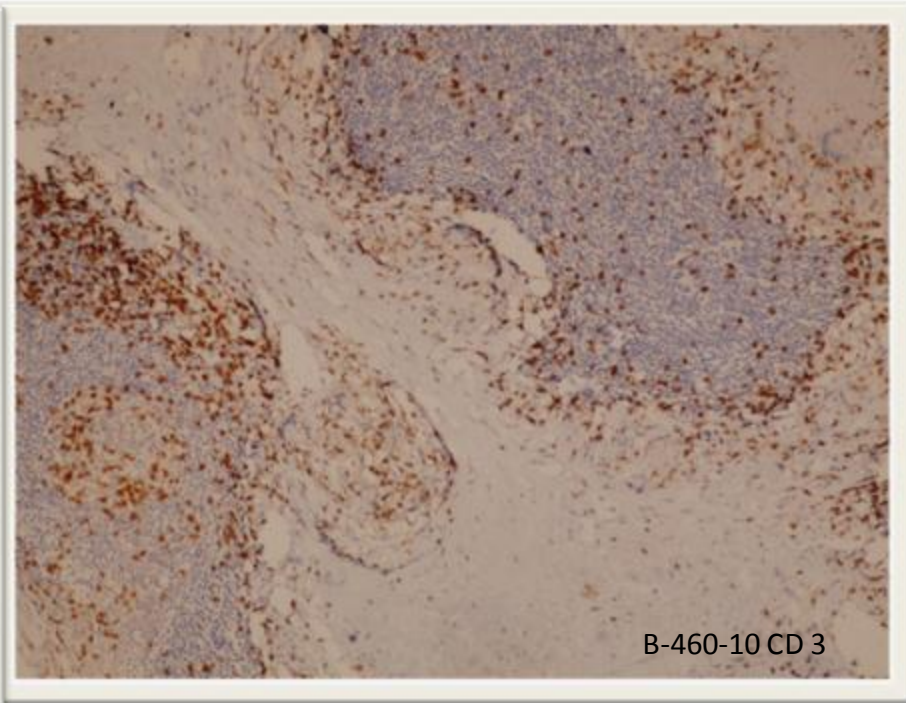
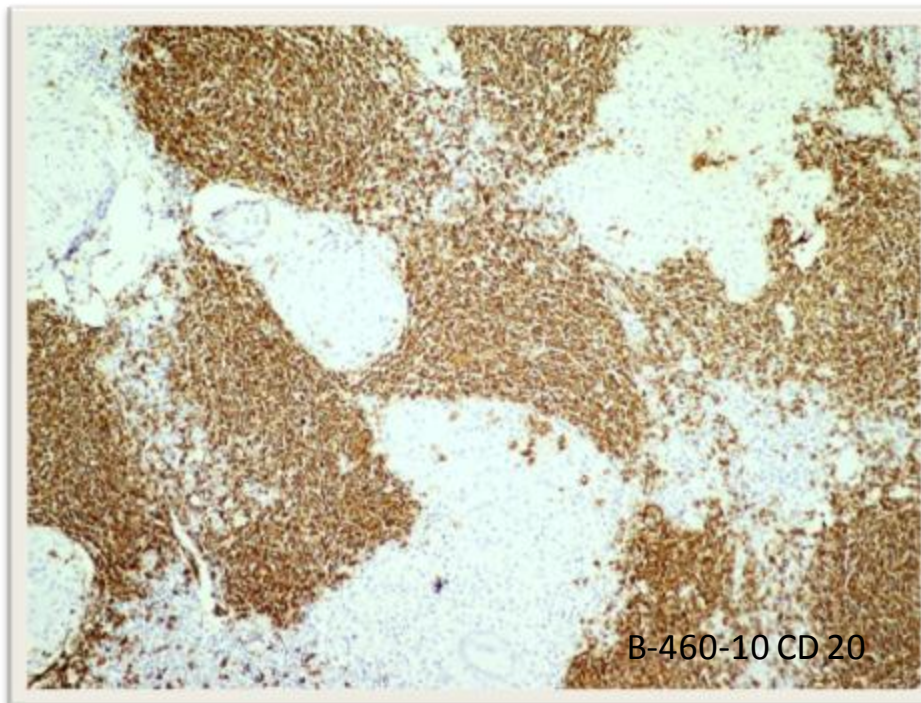


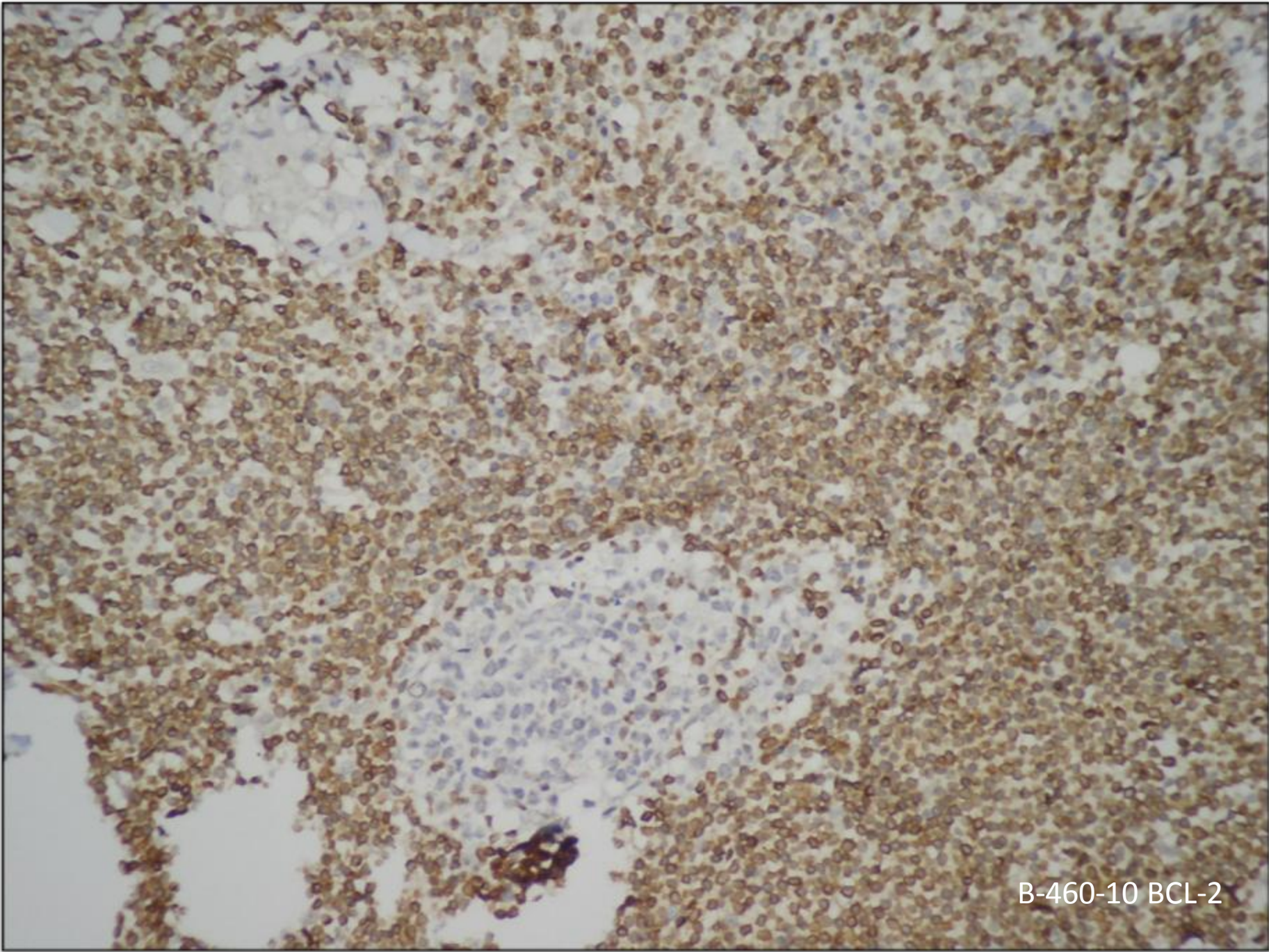
B-460-10 H&E



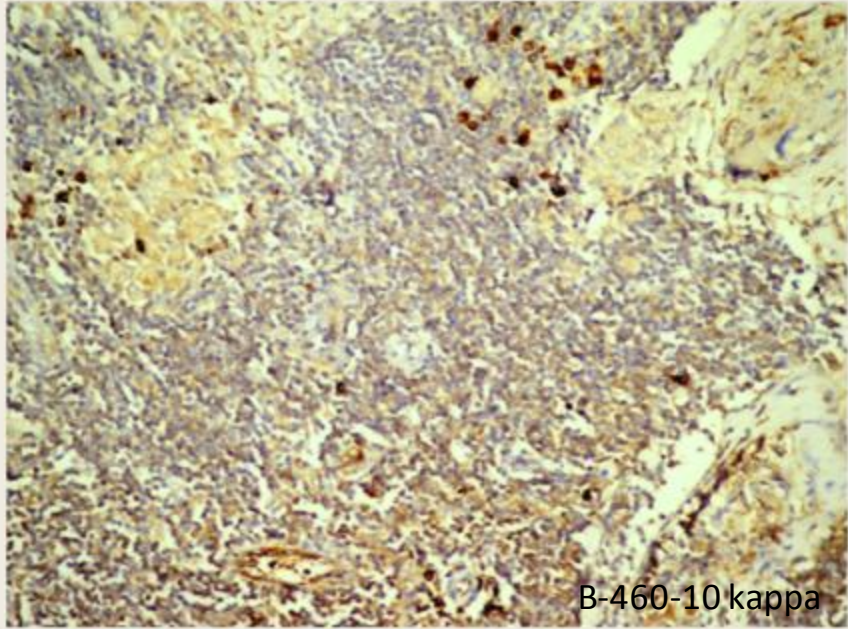


B-460-10 H&E

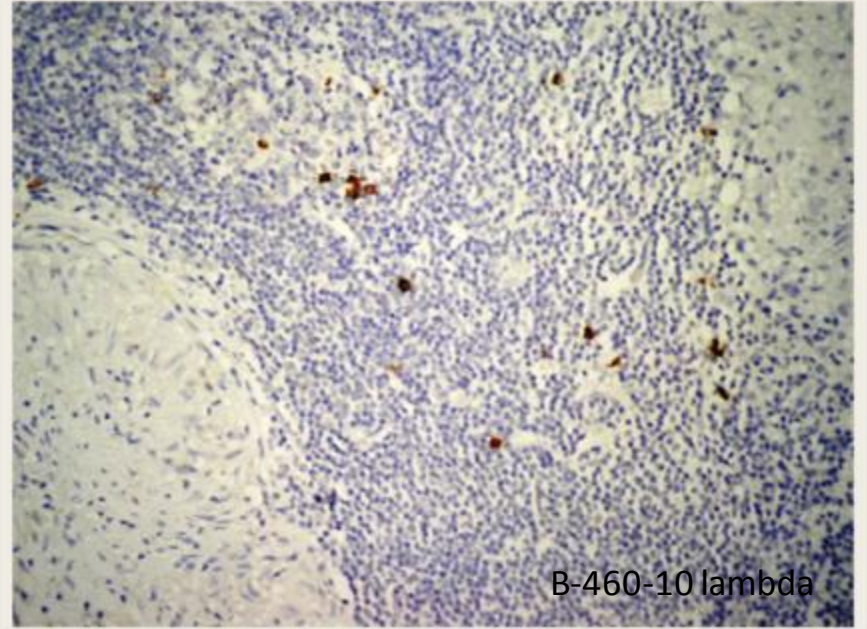




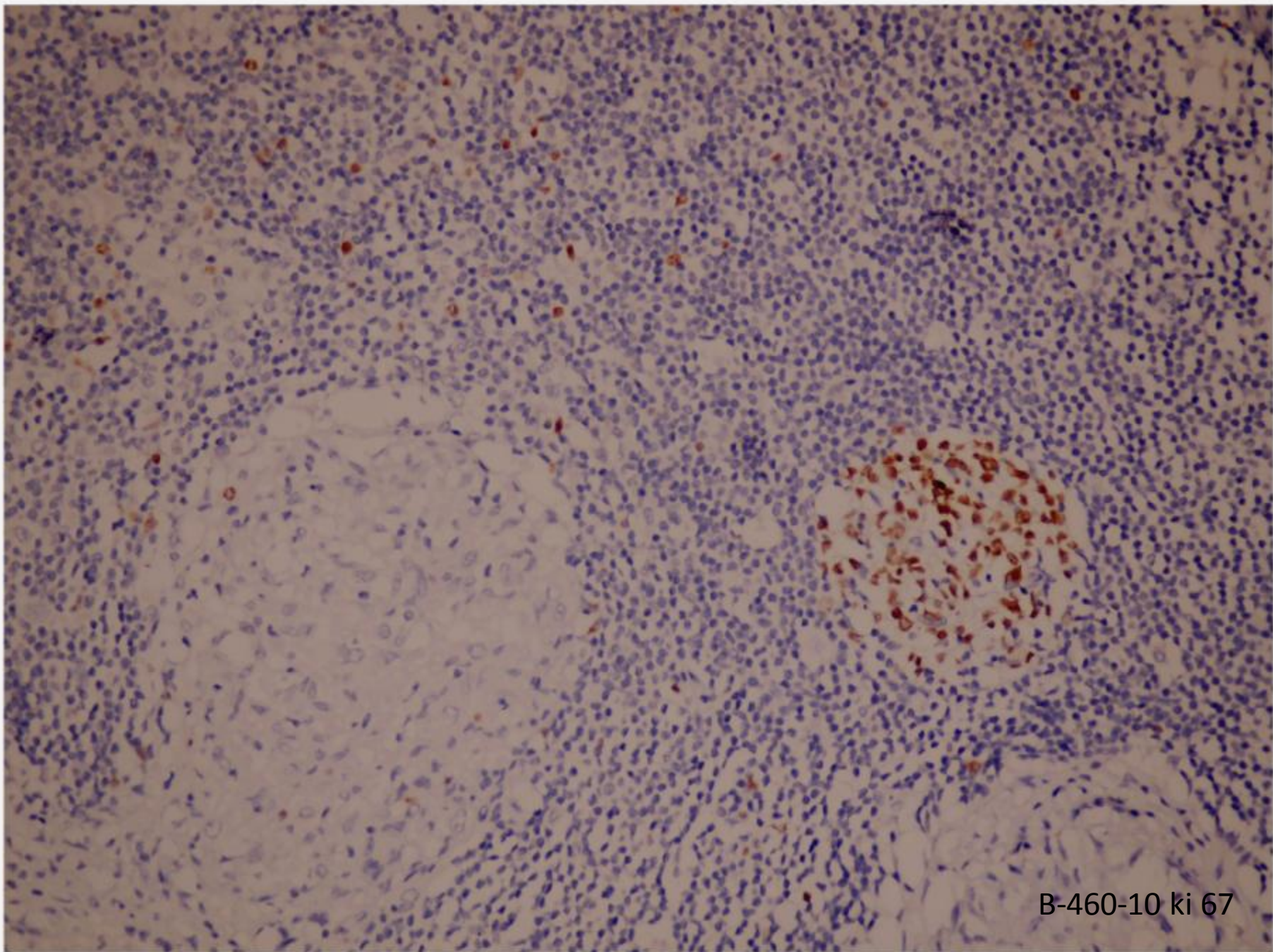
B-460-10 BCL-2



B-460-10 kappa

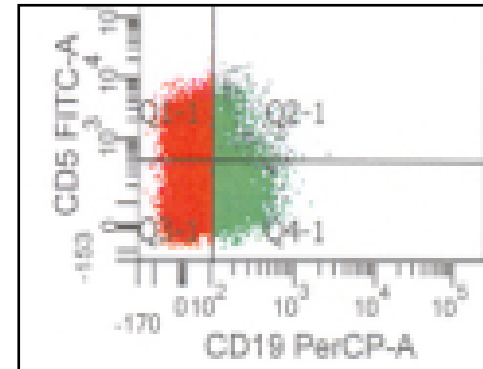
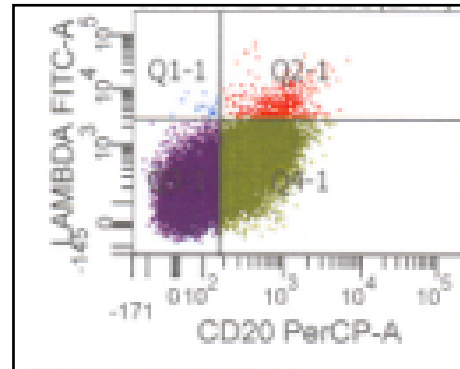
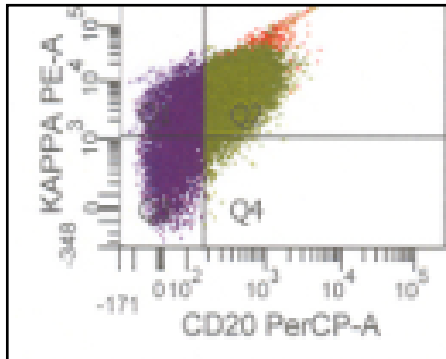
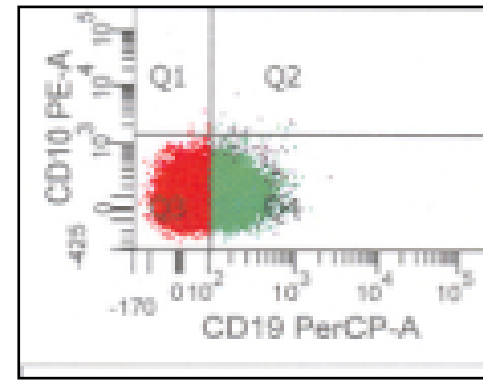
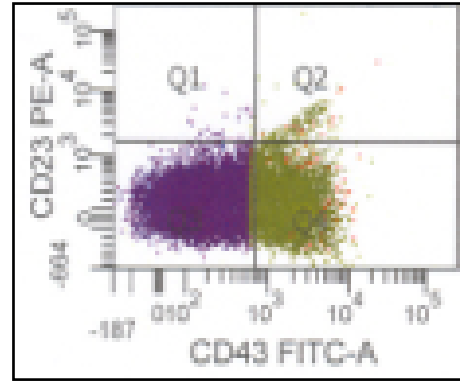
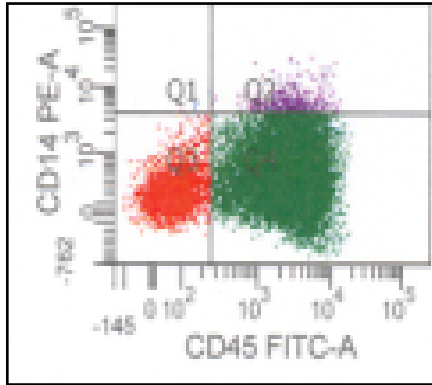


B-460-10 lambda



B-460-10 ki 67

Akım sitometrik inceleme



CD 45+, CD20+, CD19+, CD 3-, CD5-, CD 23-, CD10-, Kappa+, Lambda -



İmmunohistokimya

- CD 20+
- CD3-
- CD5-
- CD23-
- Siklin D1-
- Bcl-2+
- Kappa: Dağınık plasma hücresinde+, lenfoid hücrelerde zayıf +
- Lambda: Dağınık plasma hücresinde +, lenfoid hücrelerde -



Tanı: Nodal marginal zon
lenfoma-yaygın granulomatöz
reaksiyon



Hasta kemoterapi almadı.

Halen nüks yok-genel durumu iyi



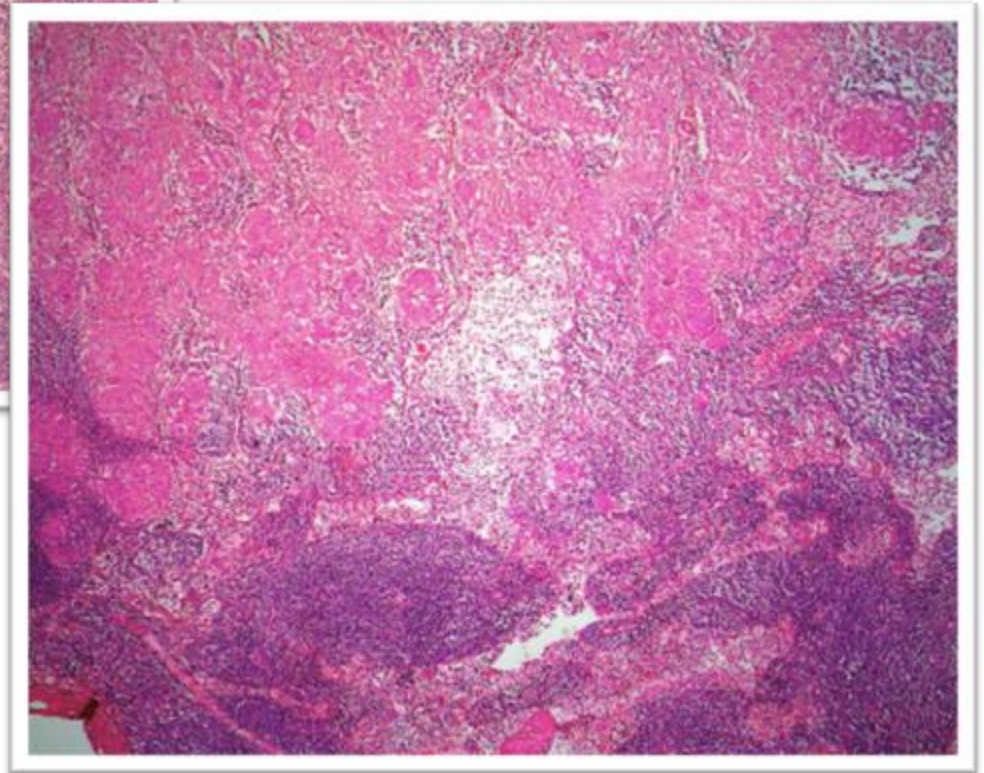
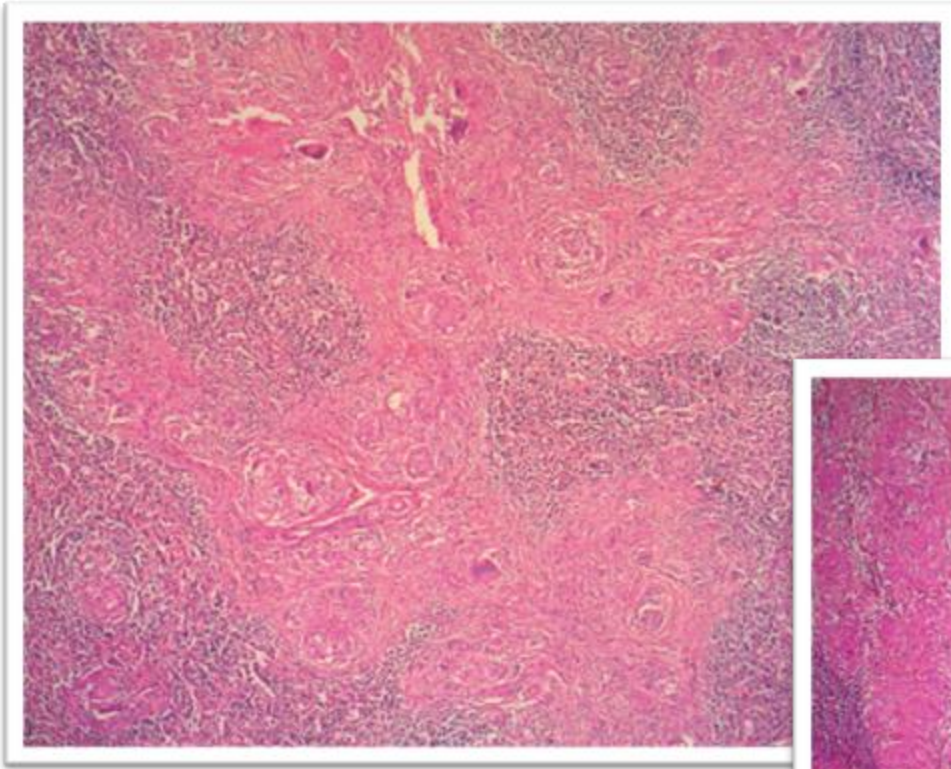
Epitelioid granulomlarla birliktelik gösteren durumlar

- Sarkoidoz
- Tümör ilişkili granulomatöz reaksiyon
- İnfeksiyonlar(Mikobakter, spiroket, mantar, protozoa)
- Gastrointestinal sistem hastalıkları(Crohn's, biliyer siroz)



Literatürde....

- Manipadam M,T et al. Primary splenic marginal zone lymphoma with florid granulomatous reaction-A case report and review of literature. Path Res Prac 2007, 203,239-243.
- Demellawy D et al.Gastric Lymphoma with Florid Granulomatous Reaction. J Gastrointestin Liver Dis 2009 Vol.18 99-101.



Manipadam M,T et al. Primary splenic marginal zone lymphoma with florid granulomatous reaction-A case report and review of literature. Path Res Prac 2007, 203,239-243.



Marginal Zon Lenfoma

- WHO 2008
- Ekstranodal Marginal zon lenfoma-MALT tip
- Nodal marginal zon lenfoma
- Pediatrik nodal marginal zon lenfoma
- Splenik marginal zon lenfoma



Nodal Marginal Zon Lenfoma

- Post-germinal merkez B hücrelerinden köken alan primer nodal B hücreli neoplazi
- Morfolojik ve immunofenotipik olarak diğer marginal zon lenfomalar ile benzerlikler içerir



Nodal Marginal Zon Lenfoma

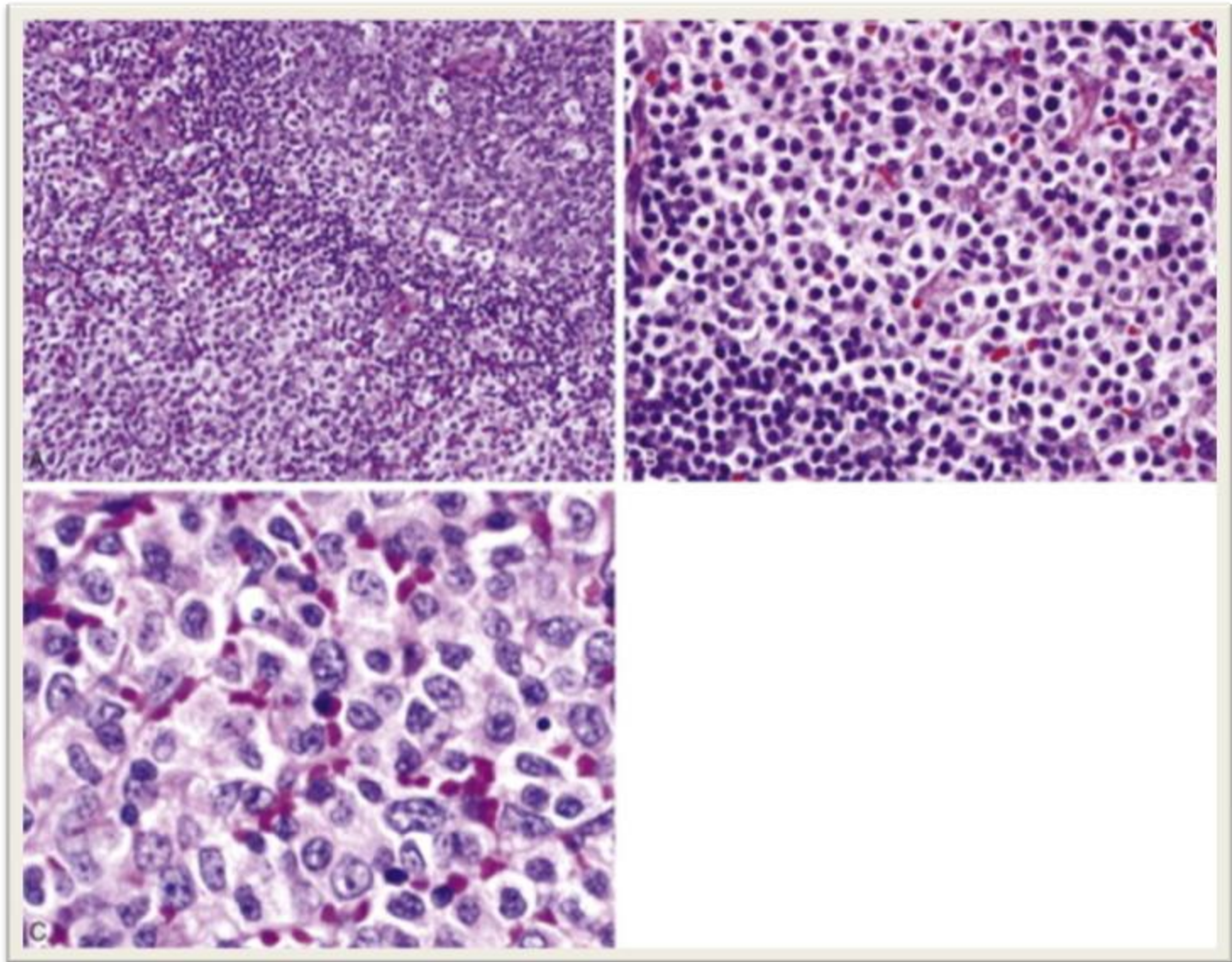
- Nadir görülür
- Tüm lenfomaların %1.5-1.8
- Erişkinlerde-pediyatrik formları var
- Ortalama yaş 50-60
- Hepatit C enfeksiyonu ile ilişkili %20-40
- Otoimmün hastalık ilişkisi?



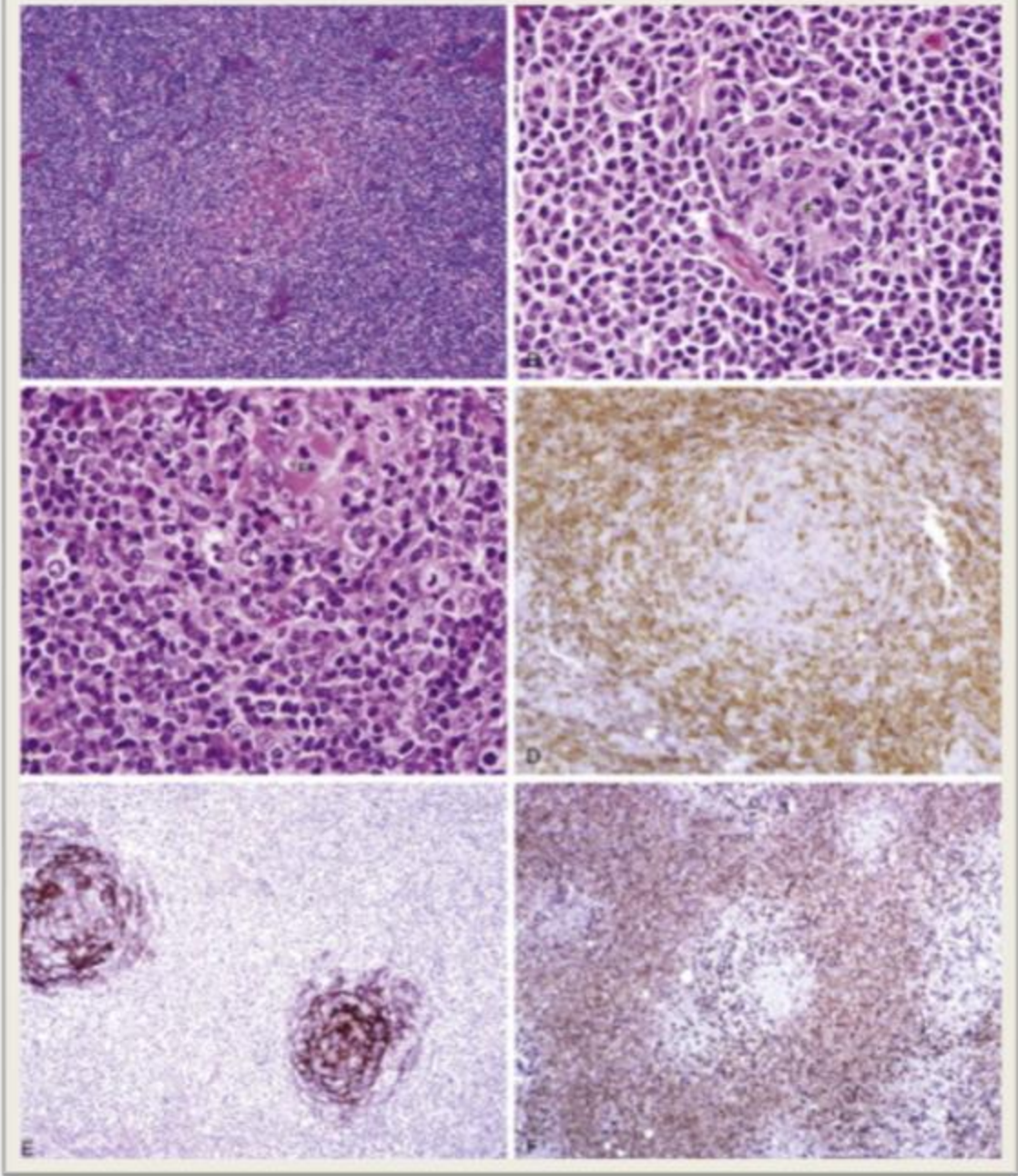
Nodal Marginal Zon Lenfoma

- **Sitoloji**
- Monositoid, sentrosit benzeri, plasmaitoid
- Değişken sayıda transforme yada blastik hücre ile karışık
- Epitelioid histiyositler nadir

Nodal marginal zon lenfoma, MALT tip.



**Splenik tip-
NMZL**





PEDİATRİK NODAL MARGİNAL ZON LENFOMA

- Farklı morfolojik-klinik özellikler
- Genişlemiş-irregüler konfigürasyonda hiperplastik germinal merkezler
- Germinal merkezlerin progresif transformasyonuna benzer
- Folikülün dış sınırı bozulmuş-neoplastik hücre infiltrasyonu



NODAL MARGINAL ZON LENFOMA

- Ayırıcı Tanı
- Marginal zon hiperplazisi
- Foliküler lenfoma-marginal zon diferansiyasyonu
- Lenfoplasmositik lenfoma
- KLL/SLL parafoliküler patern



NODAL MARGINAL ZON LENFOMA

- **İmmunofenotip**
- CD20, CD19, ve CD79a +
- CD5, CD23, CD10, ve BCL6 -
- CD43 + %50 olguda
- BCL2 zayıf +
- Ig D %25-50 olguda zayıf ekspresyon
- Hafif zincir ekspresyonu kappa>lambda



NODAL MARGİNAL ZON LENFOMA

- Klinik Davranış
- İndolent/ düşük dereceli tümör
- 5-yıllık sürvi %55- %75
- Tam remisyon %50



Referans

- 1-Arcaini L, Paulli M, Burcheri S, et al: Primary nodal marginal zone B-cell lymphoma: clinical features and prognostic assessment of a rare disease. Br J Haematol 2007; 136(2):301-304.
- 2-Camacho FI, Algara P, Mollejo M, et al: Nodal marginal zone lymphoma: a heterogeneous tumor: a comprehensive analysis of a series of 27 cases. Am J Surg Pathol 2003; 27(6):762-771.
- 3-Campo E, Miquel R, Krenacs L, et al: Primary nodal marginal zone lymphomas of splenic and MALT type. Am J Surg Pathol 1999, 23(1):59-68,.
- 4-Dina El Demellawy et al. Gastric Lymphoma with Florid Granulomatous Reaction. J Gastrointestin Liver Dis 2009 Vol.18 99-101.
- 5-Ioachim HL, Medeiros LJ: Ioachim's Lymph node Pathology. 4th ed. Philadelphia, 2009.



Referans

6-Jaffe ES, Harris NL, Vardiman JW, et al: Hematopathology. 1st ed. Philadelphia, 2011

7-Kojima M et al. Centroblastic/centrocytic lymphoma associated with prominent epithelioid granulomatous response: a clinicopathologic study of 50 cases. Mod Pathol 2002 15(7) 750-758

8-Manipadam M, T et al. Primary splenic marginal zone lymphoma with florid granulomatous reaction-A case report and review of literature. Path Res Prac 2007, 203, 239-243.

9-Swerdlow SH, Campo E, Harris NL, et al: WHO Classification of Tumours of Haematopoietic and Lymphoid Tissues. 4th ed. Lyon, France, International Agency for Research on Cancer, 2008.

10-Traverse-Glehen A, Felman P, Callet-Bauchu E, et al: A clinicopathological study of nodal marginal zone B-cell lymphoma. A report on 21 cases. Histopathology 2006; 48(2):162-173.